

Touro Scholar

NYMC Faculty Publications

Faculty

4-15-2016

Abdominal Skin Rash After TACE Due to Non-Target Embolization of Hepatic Falciform Artery

Prashant Nagpal
New York Medical College

Mitesh Bhalala
New York Medical College

Nisha Sharma
New York Medical College

Dhruv Mehta
New York Medical College

Sam McCabe
New York Medical College

See next page for additional authors

Follow this and additional works at: https://touro scholar.touro.edu/nymc_fac_pubs



Part of the [Neurology Commons](#)

Recommended Citation

Nagpal, P., Bhalala, M., Vidholia, A., Sao, R., Sharma, N., Mehta, D., . . . Bodin, R. (2016). Abdominal skin rash after TACE due to non-target embolization of hepatic falciform artery. *ACG Case Reports Journal*, 3(3), 217-220. doi:10.14309/crj.2016.55

This Article is brought to you for free and open access by the Faculty at Touro Scholar. It has been accepted for inclusion in NYMC Faculty Publications by an authorized administrator of Touro Scholar. For more information, please contact daloia@nymc.edu.

Authors

Prashant Nagpal, Mitesh Bhalala, Nisha Sharma, Dhruv Mehta, Sam McCabe, and Roxana Bodin

Abdominal Skin Rash After TACE Due to Non-Target Embolization of Hepatic Falciform Artery

Prashant Nagpal, MBBS, MD^{1,2}, Mitesh Bhalala, MD³, Aditi Vidholia, MBBS, DDVL⁴, Rahul Sao, MBBS², Nisha Sharma, MBBS², Dhruv Mehta, MBBS², Sam McCabe, MD⁵, and Roxana Bodin, MD³

¹Department of Radiology, University of Iowa Hospitals and Clinics, Iowa City, IA

²Department of Internal Medicine, Westchester Medical Center, New York Medical College, Valhalla, NY

³Department of Gastroenterology, Westchester Medical Center, New York Medical College, Valhalla, NY

⁴Department of Pathology, University of Iowa Hospitals and Clinics, Iowa City, IA

⁵Department of Radiology, Westchester Medical Center, New York Medical College, Valhalla, NY

Abstract

Transcatheter arterial chemoembolization (TACE) is a well-recognized procedure for management of hepatocellular carcinoma. We present a 54-year-old man who presented with a periumbilical maculopapular skin rash that developed after an otherwise uneventful TACE procedure. A retrospective review of imaging was consistent with non-target embolization of the hepatic falciform artery (HFA). He was treated with oral non-steroidal anti-inflammatory medication for 3 weeks with improvement, but had slight skin induration and an excoriated papule at 6-month follow-up. Non-target embolization of HFA is very rare, but clinicians and interventionalists should be aware of this complication, especially in patients predisposed to enlargement of HFA.

Introduction

Hepatocellular cancer (HCC) is the most common primary malignant tumor of the liver, the fifth most common cancer worldwide, and the third most common cause of cancer-related death.¹ Liver transplantation or surgical resection is the preferred treatment of HCC; however, many patients diagnosed with HCC are not surgical candidates. Transcatheter arterial chemoembolization (TACE) is central for management of intermediate BCLC-B stage HCC, as it has shown a survival benefit in these patients.¹ A myriad of complications related to TACE has been described, and more systemic complications have been reported with conventional TACE than with TACE using drug-eluting beads (DEB-TACE).^{2,3}

Case Report

A 54-year-old man with a history of cirrhosis secondary to non-alcoholic steatohepatitis (NASH) presented to hepatology clinic for management of cirrhosis. He complained of vague abdominal discomfort and subjective weakness for the prior 4 weeks. Abdominal examination showed mildly distended non-tender abdomen with normal bowel sounds. The laboratory work-up was unremarkable, with an alpha fetal protein level of 2.67 ng/mL. A triple-phase computed tomography (CT) showed a suspicious area of arterial enhancement in segment V of the liver (Figure 1). Triple-phase magnetic resonance imaging (MRI) confirmed a 2.6-cm arterially enhancing lesion in segment V that did not demonstrate portal venous phase washout, so the patient was managed with short-term imaging follow-up (Figure 1). A repeat triple-phase MRI obtained after 3 months showed interval increase in size of the lesion to 3.2 cm (Figure 1). After discussion by a multidisciplinary tumor board, the patient was scheduled for TACE.

ACG Case Rep J 2016;3(3):217-220. doi:10.14309/crj.2016.55. Published online: April 15, 2016.

Correspondence: Prashant Nagpal, University of Iowa Hospital and Clinics, Radiology, 200 Hawkins Dr, Iowa City, IA, 52242 (drprashantnagpal@gmail.com).



Copyright: © 2016 Nagpal et al. This work is licensed under a Creative Commons Attribution-NonCommercial-NoDerivatives 4.0 International License. To view a copy of this license, visit <http://creativecommons.org/licenses/by-nc-nd/4.0>.

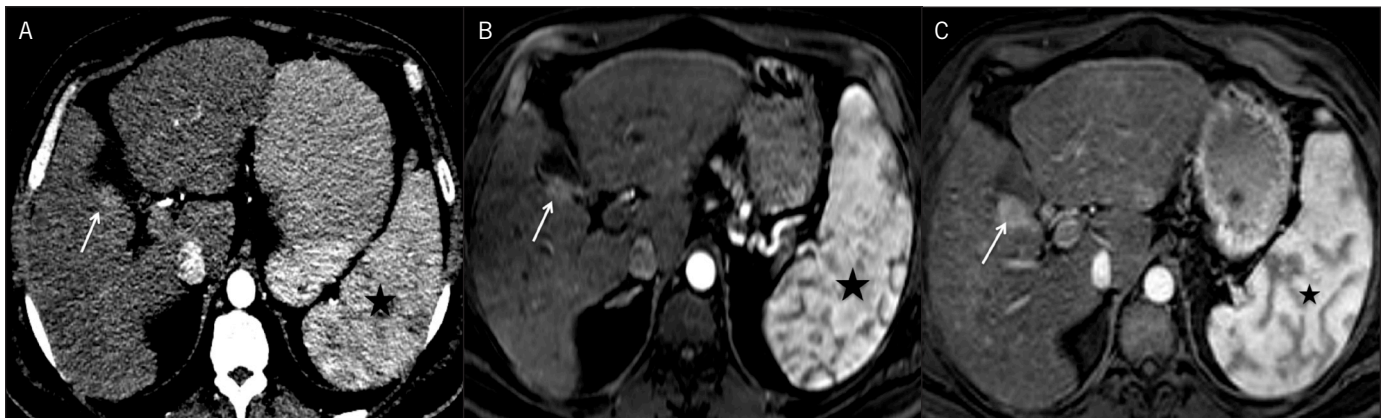


Figure 1. (A) Arterial phase contrast-enhanced CT image showing a faint area of arterialization (arrow) in the segment V of liver adjacent to the GB fossa, irregular liver outline, and splenomegaly (star). Arterial phase MRI images (B) at presentation and (C) at 3-month follow-up confirm the enlargement of a small arterially enhancing lesion in the right lobe (arrow).

Selective angiography of the middle hepatic artery showed a faint hypervascular focus corresponding to target lesion (Figure 2). The branch was subsequently embolized with 75 mg of doxorubicin loaded on 70-150 μ m LC beads (BTG International, West Conshohocken, PA). The postembolization angiogram confirmed occlusion of the branch. The patient tolerated the procedure well and was discharged the next morning.

He returned 1 week later complaining of a worsening 'red area' on his belly that he noticed 3 days after the procedure. He denied fever or pain. The initial examination showed a non-tender erythematous papular rash in the periumbilical area, predominantly on left side (Figure 3). A retrospective review of middle hepatic artery angiogram and cone beam CT obtained during

the TACE procedure showed a patent hepatic falciform artery (HFA) that was not recognized during the procedure (Figure 4). The clinical findings were consistent with non-target embolization of the HFA. The patient was started on non-steroidal anti-inflammatory medication for 3 weeks. His rash partially cleared at his 3-week follow-up visit, but there was interval development of an approximately 1-cm ulcer with indurated margins (Figure 5). There was a nearly complete resolution of rash at his 6-month visit, but the ulcer persisted with dry eschar, suggesting previous skin necrosis (Figure 5). The patient is currently doing well and is still on the liver transplant list.

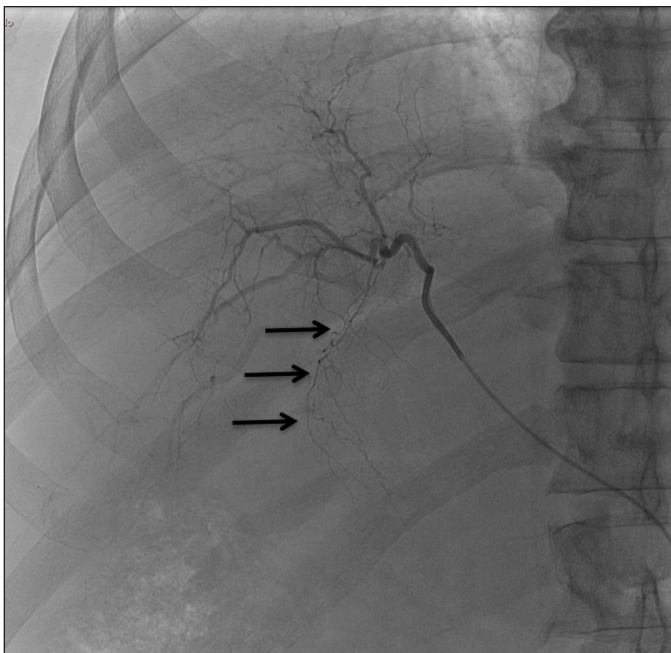


Figure 2. Selective middle hepatic artery angiogram showing the hepatic falciform artery (arrows) with typical arc and caudal course.

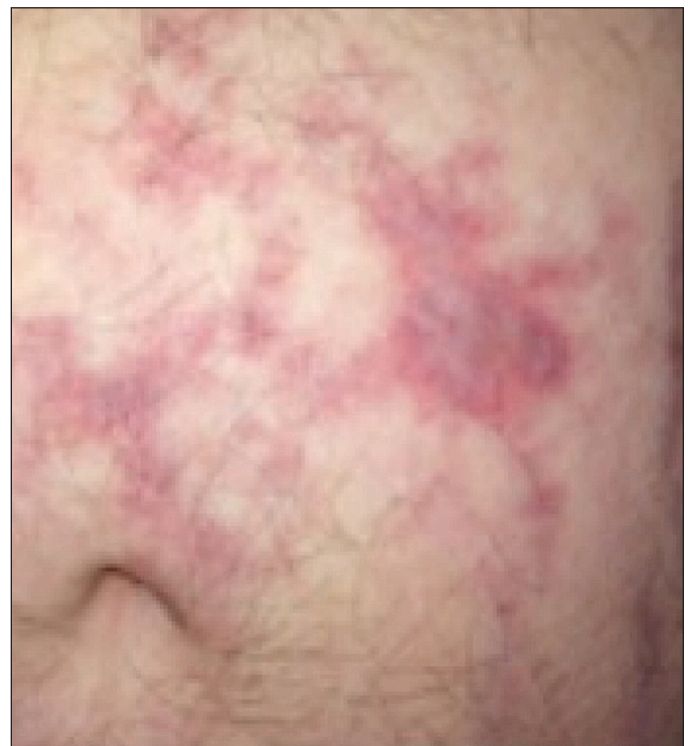


Figure 3. Irregularly coalescing erythematous papules and plaque around the left periumbilical area, visible 7 days after TACE.

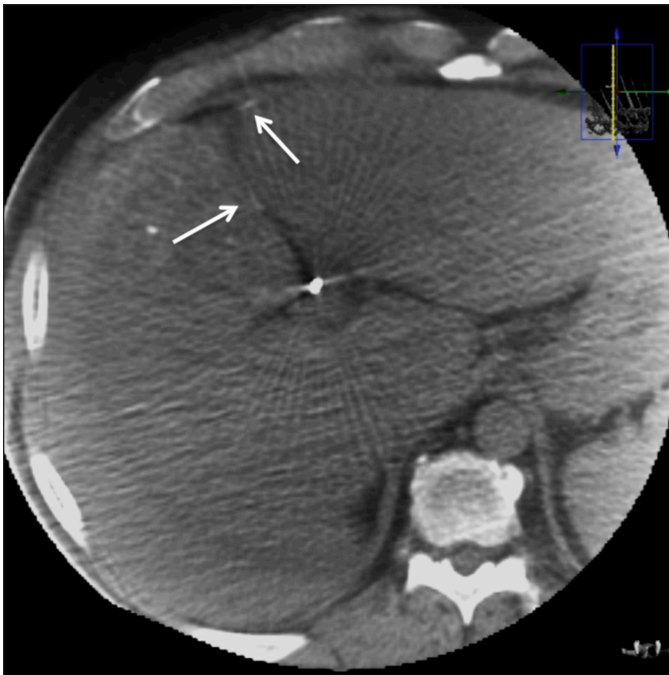


Figure 4. Immediate post procedure cone-beam CT image showing presence of hyperdense embolizing material (arrows) in the falciform ligament and coursing towards anterior abdominal wall consistent with course of the falciform artery.

Discussion

Non-target embolization is a recognized complication of TACE. Common vessels prone to non-target embolization include the gastroduodenal artery, cystic artery, right gastric artery, retro-duodenal artery, supraduodenal artery, accessory left gastric artery, and the HFA, which typically arises as a small terminal branch of the left or middle hepatic artery that courses through the falciform ligament. It supplies the skin around the umbilicus and terminally communicates with branches of the superior and inferior epigastric arteries.⁴ The HFA can be recognized at angiography by its characteristic inferomedial diagonal course. Although the reported incidence of HFA during angiography varies from 2–24.5%, very few cases of non-target embolization to the HFA leading to abdominal wall rash or necrosis have been reported in the literature.^{3,5-9} The HFA may be relatively enlarged in patients with adhesions around the anterior abdominal wall due to prior laparotomy or in patients with stenosis/occlusion of the hepatic artery, theoretically making them more prone to such complications.⁹ Of note, neither of these factors was present in our patient.

Two factors that have been shown to cause a higher incidence of skin injury after transcatheter therapy are smaller size of embolization agents and use of continuous arterial injection.^{5,9} The systemic complications are also less common with the use of DEB-TACE rather than conventional TACE.³ Typically, the biopsy of such a rash will show dermal sclerosis with fat necrosis and foreign body reaction. If large, these areas of fat

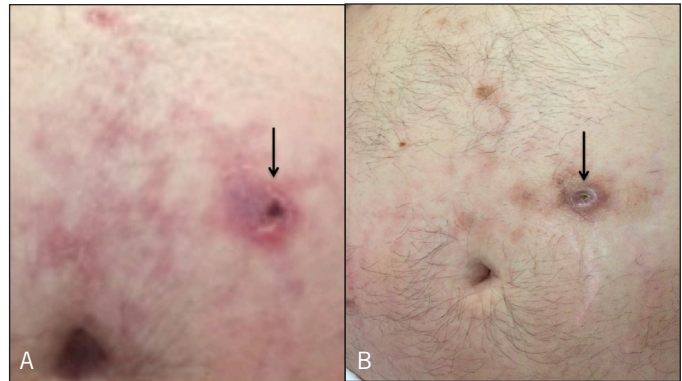


Figure 5. (A) Partial clearance of the rash with interval formation of a 1 x 1 cm ulcer (arrow) with indurated margins approximately 5 cm from the umbilicus at 21-day follow-up. (B) Near complete interval resolution of erythematous papules and plaques but the ulcer (arrow) persisted with dry eschar suggesting previous skin necrosis 6 months after TACE.

necrosis can be demonstrable even on CT scan.⁷ In our case, skin biopsy was not performed because the rash presented immediately after TACE and retrospective review of the images was compatible with non-target embolization of the patent falciform artery.

There is no consensus on the need of prophylactic embolization of the HFA if noticed at angiography. A study involving 127 patients, out of which 16 had patent HFA, showed that there is no need for prophylactic embolization of the HFA for prevention of skin rash prior to hepatic arterial chemoinfusion with or without subsequent embolization.¹⁰ Some reports have advocated prophylactic embolization with or without the use of ice packs on the upper abdomen for prevention of this rare complication.^{9,11} Due to its rarity, there is also no consensus regarding treatment of this complication. It is mostly treated with local warm compresses, non-steroidal anti-inflammatory drugs, and intralesional or oral steroids with or without anti-histamines.^{5,7,9} Pentoxifylline, which is known to improve microcirculatory perfusion, has also been successfully used to treat the skin rash after TACE.¹²

When the HFA is visualized on the angiogram, we propose that the operator place the tip of microcatheter distal to the origin of HFA to prevent this complication. If distal placement is not possible, it may be useful to perform prophylactic HFA embolization or place ice packs near umbilicus, especially in patients that have risk factors for relatively enlarged HFA.

Disclosures

Author contributions: P. Nagpal wrote the case report, prepared the images, and is the article guarantor. M. Bhalala, R. Sao, N. Sharma, and D. Mehta assisted with manuscript preparation. A. Vidholia reviewed the manuscript. S. McCabe provided the radiological images. R. Bodin revised the manuscript.

Financial disclosure: None to report.

Informed consent was obtained for this case report.

Received August 17, 2015; Accepted December 11, 2015

References

1. Raza A, Sood GK. Hepatocellular carcinoma review: Current treatment, and evidence-based medicine. *World J Gastroenterol*. 2014;20(15):4115–27.
2. Sueyoshi E, Hayashida T, Sakamoto I, Uetani M. Vascular complications of hepatic artery after transcatheter arterial chemoembolization in patients with hepatocellular carcinoma. *Am J Roentgenol*. 2010;195(1):245–51.
3. Kim HY, Bae SH, Park CH, et al. Supraumbilical subcutaneous fat necrosis after transcatheter arterial chemoembolization with drug-eluting beads: Case report and review of the literature. *Cardiovasc Intervent Radiol*. 2013;36(1):276–9.
4. Lee KH, Sung KB, Lee DY, et al. Transcatheter arterial chemoembolization for hepatocellular carcinoma: Anatomic and hemodynamic considerations in the hepatic artery and portal vein. *Radiographics*. 2002;22(5):1077–91.
5. Kanzaki H, Nouso K, Miyahara K, et al. A case of hepatocellular carcinoma with skin injury of the upper abdominal wall after transcatheter arterial chemoembolization: A case report. *Cases J*. 2009;2:7197.
6. Hama Y, Iwasaki Y, Kusano S. Supraumbilical skin rash after chemoembolization for hepatocellular carcinoma. *Eur Radiol*. 2000;10(8):1356.
7. Lin CC, Wu DK, Shih PM, et al. Supraumbilical skin rash and fat necrosis after transcatheter arterial chemoembolization: A case report. *Kaohsiung J Med Sci*. 2004;20(1):36–40.
8. Byun JW, Han SH, Song HJ, et al. A case of supraumbilical skin rash after chemoembolization for hepatocellular carcinoma. *J Eur Acad Dermatol Venereol*. 2009;23(12):1458–9.
9. Smith MT, Johnson DT, Gipson MG. Skin necrosis resulting from non-target embolization of the falciform artery during transarterial chemoembolization with drug-eluting beads. *Semin Intervent Radiol*. 2015;32(1):22–5.
10. Kim DE, Yoon HK, Ko GY, et al. Hepatic falciform artery: Is prophylactic embolization needed before short-term hepatic arterial chemoembolization? *AJR Am J Roentgenol*. 1999;172(6):1597–9.
11. Ueno K, Miyazono N, Inoue H, et al. Embolization of the hepatic falciform artery to prevent supraumbilical skin rash during transcatheter arterial chemoembolization for hepatocellular carcinoma. *Cardiovasc Intervent Radiol*. 1995;18(3):183–5.
12. Jang MS, Baek JW, Kang DY, et al. Supraumbilical skin rash after transcatheter arterial chemoembolization: Successful treatment with pentoxifylline. *J Dermatol*. 2011;38(12):1188–91.

Publish your work in ACG Case Reports Journal

ACG Case Reports Journal is a peer-reviewed, open-access publication that provides GI fellows, private practice clinicians, and other members of the health care team an opportunity to share interesting case reports with their peers and with leaders in the field. Visit <http://acgcasereports.gi.org> for submission guidelines. Submit your manuscript online at <http://mc.manuscriptcentral.com/acgcr>.