

Spring 3-1-2017

RMDO-2, Olig-2 and Synaptophysin Expression Is a Frequent Event in Malignant Melanoma: Diagnostic Pitfalls in Glial Tumor

Taliya Farooq

New York Medical College, taliya_farooq@nymc.edu

Esther C. Yoon

New York Medical College, esther_yoon@nymc.edu

Anas Mashlah

New York Medical College, anas_mashlah@nymc.edu

Sina Zomorrodian

New York Medical College

George Kleinman

New York Medical College, george_kleinman@nymc.edu

Follow this and additional works at: https://touro scholar.touro.edu/nymc_fac_posters



Part of the [Oncology Commons](#), and the [Pathology Commons](#)

Recommended Citation

Farooq, T., Yoon, E. C., Mashlah, A., Zomorrodian, S., & Kleinman, G. (2017). RMDO-2, Olig-2 and Synaptophysin Expression Is a Frequent Event in Malignant Melanoma: Diagnostic Pitfalls in Glial Tumor. Retrieved from https://touro scholar.touro.edu/nymc_fac_posters/17

This Poster is brought to you for free and open access by the Faculty at Touro Scholar. It has been accepted for inclusion in NYMC Faculty Posters by an authorized administrator of Touro Scholar. For more information, please contact daloia@nymc.edu.

1. Taliya Farooq MD1, 2. Esther C Yoon MD1, 3. Anas Mashlah M.D1, 4. Sina Zomorrodian D.O.1 and 5. George Kleinman MD1.
1. New York Medical College at Westchester Medical Center, Pathology, Valhalla, NY.

BACKGROUND:

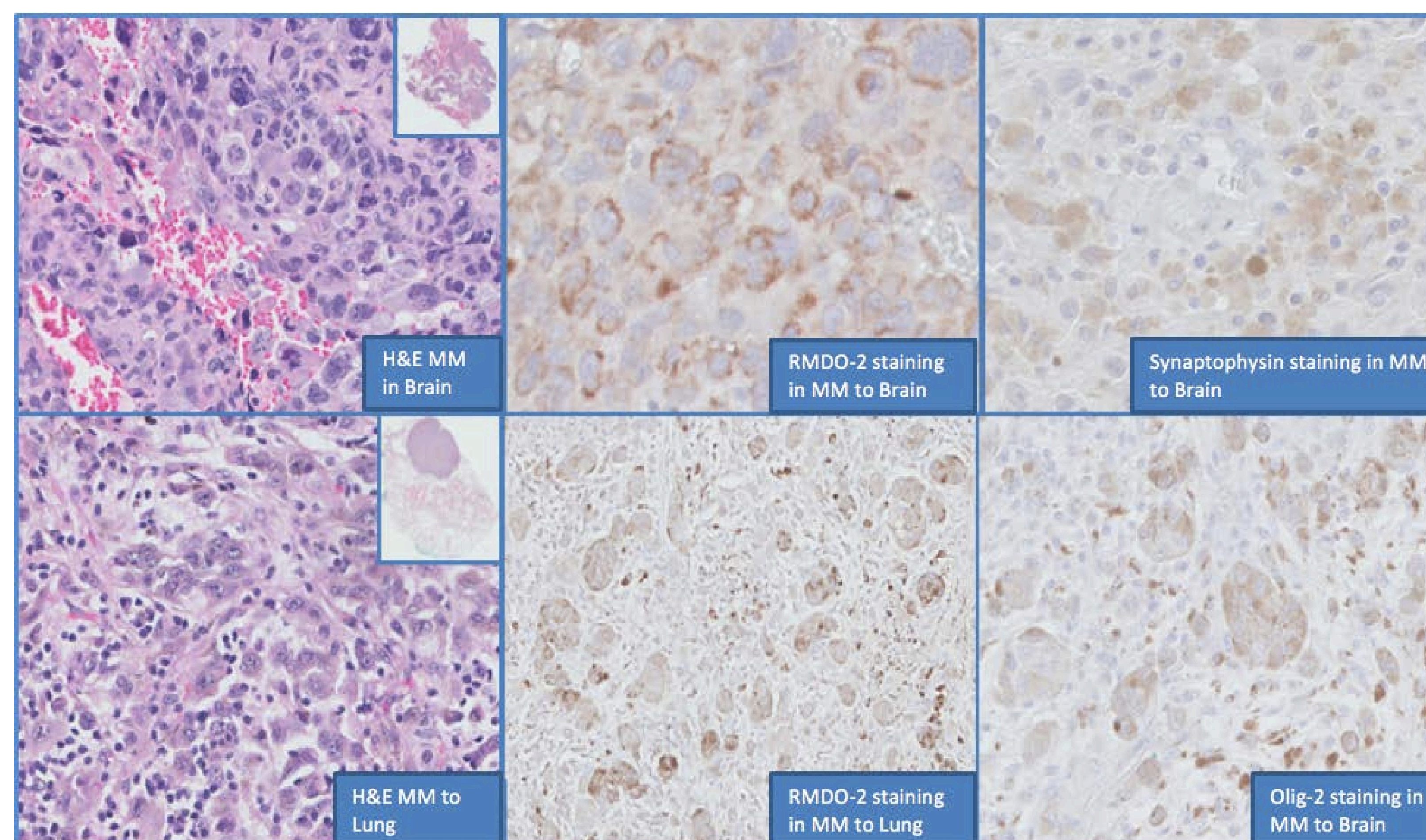
Malignant melanomas (MM) are known to express S-100, HMB-45 and Mart-1 and vimentin among intermediate filaments. RMDO-2 (non-phosphorylated Neurofilament, NF) expression by MM has never been reported in literature and this phenomenon is not well-known.

The diagnosis of MM can be challenging because melanoma is notorious for mimicking other tumors. Immunopositivity in MM for antigens associated with other tumors may further obscure the diagnosis, particularly when there is no prior history of melanoma. The purpose and aim of this study is to determine the frequency of positivity for antigens associated with primary central nervous system tumors; RMDO-2 protein (non-phosphorylated NF), CD 56, Synaptophysin and Olig-2 in MM.

DESIGN:

Twenty-four cases MM (N= 24) including Brain (N=14), MM other sites (N=10) were retrieved from LIS of Westchester Medical Center, Valhalla, NY; included 19 cases from males and 5 cases from females.

Prior diagnoses were confirmed by re-review of hematoxylin and eosin sections and relevant IHC studies (e.g., S100 protein, HMB45 and Melan-A). In addition, representative sections from each case were subjected for IHC stain for CD56 (Cell Marque, 1:100 dilution), RMDO-2 (Sigma, 1:100 dilution), Synaptophysin (Ventana, 1:100 dilution) and Olig-2 (Cell Marque, 1:100 dilution).



IMMUNOHISTOCHEMICAL STAINS	MM to Brain	MM to Other Sites	Total Cases
S100 protein	13/14 (93%)	7/10 (70%)	(20/24) 83%
RMDO-2	13/14 (93%)	1/10 (10%)	(14/24) 58%
Olig-2	1/14 (7%)	4/10 (40%)	(5/24) 21%
Synaptophysin	3/14 (21%)	4/10 (40%)	(7/24) 29%
CD-56	2/14 (14%)	5/10 (50%)	(7/24) 29%

RESULTS:

1) All cases were positive for S100 and at least one of the melanocytic markers (e.g. HMB-45 or Melan-A). IHC results for other antigens are shown in table below:

CONCLUSIONS:

- Heterogeneous expression of RMDO-2, Olig-2 and synaptophysin was found in significant subsets of MM in brain, representing potentially serious diagnostic pitfalls.
- MM showing anomalous RMDO-2 and synaptophysin expression may easily be mistaken for primary CNS gliomas and neuroendocrine tumors. Awareness of this phenomenon and an appropriate melanocytic iHC panel should facilitate the diagnosis of metastatic melanoma with unusual immunophenotypes.

REFERENCES:

Gray MH, Rosenberg AE, Dickersin GR *et al.* Cytokeratin expression in epithelioid vascular neoplasms. *Hum Pathol* 1990;21:212–217.

Gown AM, Boyd HC, Chang Y *et al.* Smooth muscle cells can express cytokeratins of 'simple' epithelium. Immunocytochemical and biochemical studies *in vitro* and *in vivo*. *Am J Pathol* 1988;132:223–232.