



**TOURO COLLEGE &
UNIVERSITY SYSTEM**

The Science Journal of the Lander
College of Arts and Sciences

Volume 6
Number 2 *Spring 2013*

1-1-2013

Alopecia Areata: An Overview

Chaya Gestetner
Touro College

Follow this and additional works at: <https://touro scholar.touro.edu/sjlcas>

 Part of the [Immune System Diseases Commons](#)

Recommended Citation

Gestetner, C. (2013). Alopecia Areata: An Overview. *The Science Journal of the Lander College of Arts and Sciences*, 6(2). Retrieved from <https://touro scholar.touro.edu/sjlcas/vol6/iss2/5>

This Article is brought to you for free and open access by the Lander College of Arts and Sciences at Touro Scholar. It has been accepted for inclusion in The Science Journal of the Lander College of Arts and Sciences by an authorized editor of Touro Scholar. For more information, please contact touro.scholar@touro.edu.

ALOPECIA AREATA: AN OVERVIEW

Chaya Gestetner

Abstract

This review seeks to find the most efficient treatment for alopecia areata. Alopecia is not very well understood as demonstrated by the unsatisfactory treatment options. The author reviewed many studies with different treatment options and concluded that treatment with Diphenylcyclopropenone (DPCP), a topical sensitizer, has the best results and that extensive research into the pathogenesis of alopecia areata is still necessary and may result in better treatment options for those afflicted with the disease.

Alopecia Areata: an Overview

Hair is an important part of the human presence; it is the crowning glory that sits upon one's temples. Therefore, hair loss of any sort is extremely painful and embarrassing. Most people automatically correlate hair loss with cancer treatments or old age. However, there is another less known mechanism of hair loss; alopecia areata, an autoimmune disease, causes partial or complete hair loss to occur. Alopecia areata affects approximately four and a half million people in the United States (Etzioni et.al. 2012). The prevalence of this disease raises many questions, namely: Why does this spontaneous hair loss occur? Does alopecia areata occur in response to stress, or is it due to genetic factors? How can it be treated?

The Hair Cycle

In order to understand the nuances of the pathogenesis of alopecia areata, it is necessary to be familiar with the normal hair cycle. Normal hair follicles go through several stages; the anagen or growth phase, the catagen or regression phase, and the telogen or rest phase. Then the follicle goes through a fourth, shedding phase, called the exogen phase.

The dermal papilla of the hair follicle consists of an oval cluster of mesenchymal cells. A substance that is full of acid mucopolysaccharides surrounds the mesenchymal cells. The whole structure is at the very bottom of the follicle, and is surrounded by the matrix cells. The dermal papilla is responsible for initiating and directing hair growth (Alaiti, 2011). Figure 1 depicts the location of the dermal papilla on a healthy hair follicle.

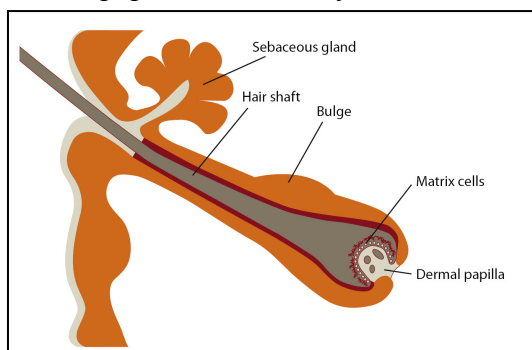


Figure 1- structure of hair follicle (Promocell).

During the anagen phase, the dermal papilla grows (Botchkarev, Cotsarelis 2012). The hair matrix, of the follicle, consists of many epidermal cells that then proliferate rapidly into six different types of cells. These daughter cells move upward and become part of the Inner Root Sheath (IRS) and the Hair Shaft (HS). The HS cells shed their organelles and become stratified with bundles of cysteine-rich hair keratin filaments. The IRS also keratinizes by forming trichohyalin granules. Soon the matrix cells cannot proliferate any further, and the follicle enters the catagen stage (Alonso, Fuchs 2006).

In Catagen, the epithelial cells in the outermost epithelial layer undergo apoptosis (Botchkarev et.al. 1997). The Hair bulb becomes keratinized forming a club hair. This cuts the follicle off from its blood supply. The club hair then travels upwards, pushed forward by a column of epithelial cells. At first the column of cells is thick but soon begins to shrink upward becoming secondary follicular germ cells (Alonso, Fuchs 2006) (Alaiti, Samer 2011).

After the club hair is formed, the telogen phase begins. The follicle prepares to shed the hair from the scalp (Botchkarev, Cotsarelis 2012). The dermal papilla and secondary germ cells form the telogen germinal unit.

Exogen is the shedding phase. In this phase, the old hair is shed after the new anagen phase begins.

Figure 2 illustrates the four stages of the normal hair cycle.

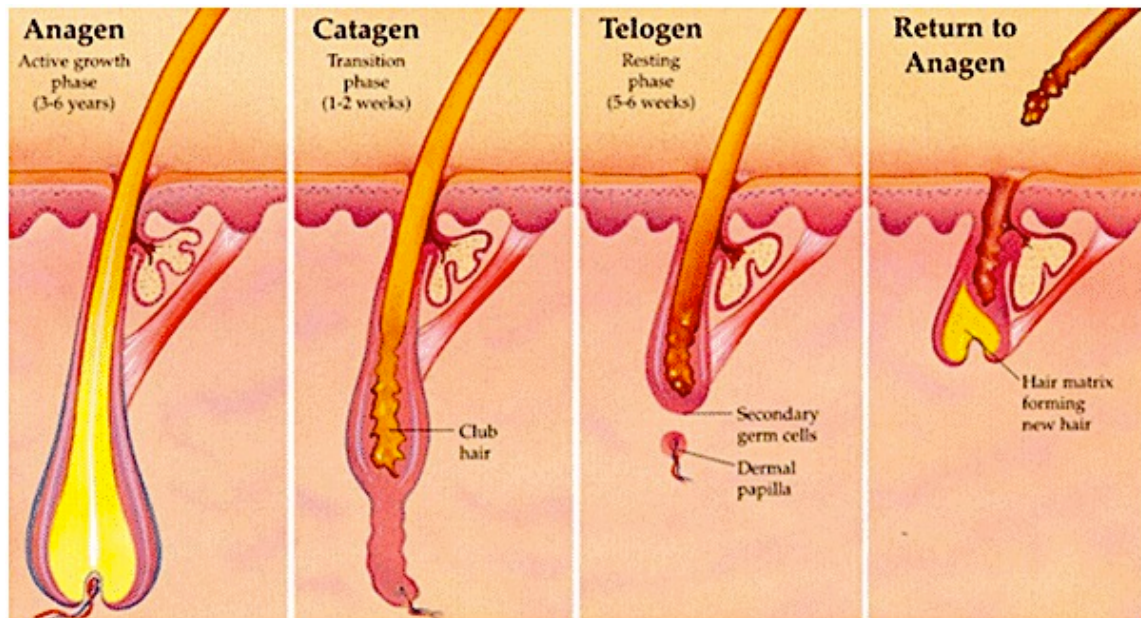


Figure 2 - The Stages of the Normal Hair Cycle (Australian Skin Clinics).

In alopecia areata, the general hair cycle is disrupted and disfigured. The follicles show signs of dystrophy in the anagen phase. This is caused by an inflammatory infiltrate that surrounds the hair bulb, the base of the hair follicle. The infiltrate is mainly composed of T-cells, but it also includes eosinophils, mast cells, plasma cells and Langerhans cells. There is also some penetration of lymphocytes to intrafollicular areas (McElwee, Wang 2011). Most cells enter and attack the dermal

papilla and hair matrix, causing apoptosis and necrosis of the follicle's epithelium. The inflammation cripples the hair shaft, eventually forming the exclamation-point hairs that are associated with alopecia areata (Dy, Whiting 2011).

Although old hair is only shed after the new growth begins in healthy hair follicles, in follicles with alopecia areata, exogen commonly occurs before anagen begins. This results in a state where no visible hair fiber is left in the follicle. This state is called kenogen (McElwee, Wang 2011).

In the most severe form of alopecia areata, all body hair is lost. This condition is referred to as alopecia universalis. This condition is rare.

Diagnosis Of Alopecia Areata

The first step in treating any disease is to diagnose it. Alopecia areata is identified through a physical examination. In its general form, alopecia areata is recognized by its typical hair loss pattern-causing round or oval, smooth patches of hair loss that are most noticeable on the scalp and eyebrows (Etzioni et.al. 2012). Figures 3a and 3b depict the pattern of hair loss triggered by alopecia areata.

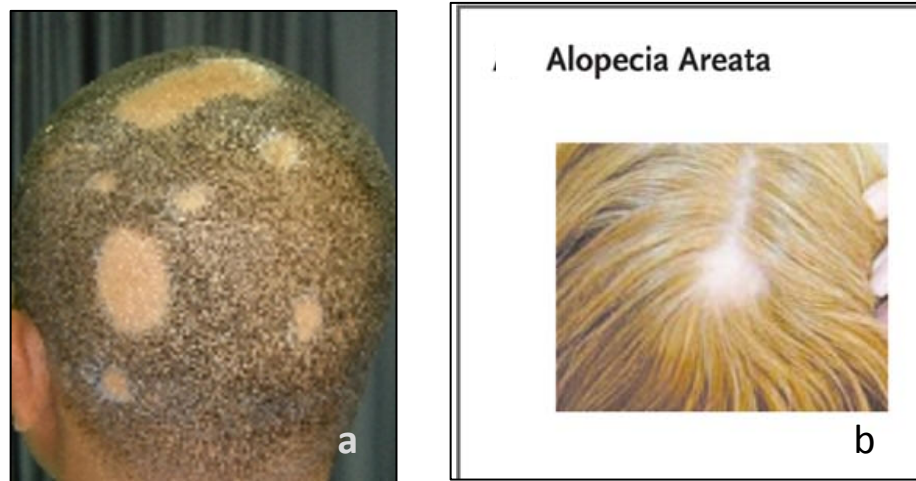


Figure 3a- alopecia areata symptoms <http://www.curespotbaldness.com>

Figure 3b- alopecia areata symptoms <http://www.curespotbaldness.com>

First, the dermatologist will perform the “hair pull” test. The doctor will use his/her thumb and index fingers to gently tug at hairs in various areas of the scalp. On a healthy scalp, between 2 and 6 hairs will detach. If more hairs fall out, that indicates excessive shedding. The dermatologist will then proceed to study the hairs underneath a microscope. This is done to determine the growth phase of the hair. Normally, the hairs that fall out easily are in the telogen phase. Anagen roots are stronger, younger and still growing. If the pulled roots are in the anagen phase, this is indicative that there is a serious health problem (Tosti, Gray 2007)

A newer diagnostic tool is known as videodermoscopy; it involves a high-definition video camera allowing for a direct, magnified examination of the scalp (Ross et.al. 2006). Videodermoscopy is a helpful diagnostic tool when trying to differentiate between similar diseases. In the case of alopecia, videodermoscopy can be used to differentiate alopecia areata from other causes of patchy alopecia. Use of the technology shows that in cases of alopecia areata, numerous yellow dots, known as degenerate follicular keratinocytes, are found on the scalp surface (Tosti, Gray 2007). Figure 4 shows the exclamation mark hairs and yellow dots found on patients with alopecia areata.

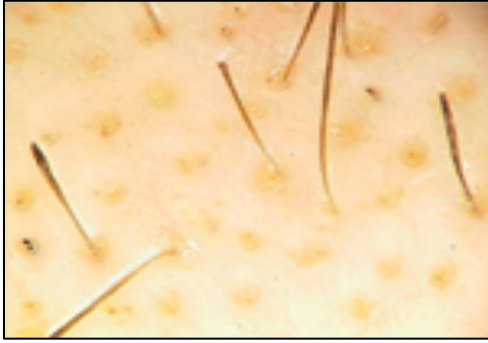


Figure 4- Alopecia areata- standard exclamation mark hairs (Tosti, Gray .2007)

The dermatologist will also examine the patient's nails, as alopecia areata is thought to be associated with nail dystrophy (Bergfeld, 2009). At times, nail distortion is one of the first signs of alopecia areata. Symptoms include; tiny dents on nails, white spots, lines, roughness, loss of natural shine, and splitting.

Causes

The etiology of alopecia areata is complex: determinants of the disease include genetic factors, psychological factors, autoimmune processes, and infectious factors. Despite active research on alopecia areata, investigators still have a limited understanding of its pathogenesis and etiology.

Genetics

A genetic basis for alopecia areata was indicated by statistical studies which showed that relatives of a patient diagnosed were more likely to have the condition themselves. For example, in one study of 206 patients with alopecia areata, 5.5% of their immediate family members (parents, siblings, children) were also stricken with alopecia. Of the 206 patients, forty-five had at least one immediate family member with the disease (Blaumeiser et.al. 2006).

After early statistical studies of alopecia areata showed high family-linked prevalence for the disease, researchers began searching for genes linked to its outbreak. In 2011, researchers performed the first genome-wide association study of alopecia areata. This identified 139 significant single nucleotide polymorphisms (SNPs) in eight sections throughout the genome, which implicated genes of the immune system and the hair follicle. For example, one important find was the involvement of chromosome 2q33.2 (CTLA4). CTLA4 becomes displayed following T cell activation (Petukhova et.al 2011). It is assumed that CTLA4 plays a critical role in the onset and maintenance of alopecia areata. CTLA4 binds CD80 and CD86 on antigen-presenting cells. One study injected monoclonal antibodies (mAb's) against antigen presenting cell (APC) surface markers CD80 and CD86 as well as a monoclonal anti-CTLA4 antibody into mice that were predisposed to develop alopecia areata in an attempt to interfere with the interactions between T cells and antigen presenting cells that involve CTLA4. The treatment prevented the onset of the disease, proving that CTLA4 plays a big role in the pathogenesis of the disease (Sundberg et al. 2011).

Psychological Factors

In a group of 45 patients with alopecia areata, 31 identified stressful events, including death of a parent, family disputes, and exams. Most events occurred less than three months before the onset of the disease (Manolache, Benea 2007). Another study investigated the effects of a heat treatment, a stressful

event, on mice that were predisposed to develop alopecia areata. Petroleum jelly was applied to the mural skin to improve conductance. Then, heat was applied with a copper cylinder connected to a precision water bath (119.3°F) for twenty minutes daily for 12 consecutive days. Researchers then used an icepack to cool the area (Wikramanayake et.al. 2012). While the mice generally begin to show signs of alopecia at 18 months, mice that underwent the treatment developed signs of the disease at least ten months earlier than normal. This study suggests that stress does not cause alopecia areata to occur, but it may help promote onset of the disease (Wikramanayake et.al. 2010).

One question arises from this study: Perhaps the heat itself destroys the hair follicle, and that's what caused the hair loss. The study used a control; forty mice were treated with room temperature water. Of these mice, only 7% developed the disease. Was the higher hair loss rate in heat-treated mice due to the stress or to the heat itself? While it is possible that some of the hair loss was due to the heat itself, the presence of alopecia areata was confirmed when histological studies showed that there were leukocyte infiltrates in anagen hair follicles (Wikramanayake et.al. 2010).

Autoimmunity

Research results overwhelmingly point to the conclusion that alopecia areata is an autoimmune disease. There are many indications supporting this belief:

Firstly, as mentioned previously, a thick cluster of lymphocytic cells surrounds alopecia areata-affected hair follicles. These include antigen presenting cells (APCs) such as macrophages and Langerhans cells, which are sometimes even found within the hair follicle.

Another reason is that alopecia areata is associated with other autoimmune diseases such as thyroid disorders and vitiligo (Thomas et.al. 2008). Alopecia areata also responds to immunomodulatory treatments such as corticosteroids, light phototherapy, and non-specific irritants such as anthralin and inducers of contact dermatitis (Lu et.al. 2006).

One proposed hypothesis is that the follicles' immune-privileged state is compromised in alopecia areata. Thus, normally innocuous hair-follicle-specific proteins are exposed to activated antigen-presenting cells. The antigen-presenting cells capture and process these proteins, which are then expressed on major histocompatibility complexes class II and I as antigens (Lu et.al. 2006). These antigens originate in the body and are known as autoantigens (Hordinsky, Ericson 2004). The exposed antigens activate T cells; they proliferate and travel to the skin forming the infiltrate around anagen-stage hair follicles, disrupting hair growth and the hair follicle dystrophy. As a result, the anagen phase is cut short and the follicles enter an early telogen phase. This cycle continues and hair loss occurs (Lu et.al. 2006).

A few questions arise from the previous paragraph. The first question is: what stimulates the breakdown of immune privilege in the hair follicle? The second question is: What causes the dysfunction of immunoregulation that is supposed to delete autoreactive T cells? A third question is: which proteins function as the autoantigens in alopecia areata?

These questions are important because their answers can give insight on how to treat the disease. For example, if the disease initiation were caused by loss of immune privilege in the follicle, a possible therapeutic mechanism would be to replace or reinforce immune privilege. This can be done through

promoting immune-protective cytokines and cell ligands, which reduce the exposure of follicular antigens (Lu et.al. 2006).

The first two questions can be explained by genetic studies, as discussed previously. The third question is the subject of a lot of current research on alopecia areata. If the autoantigens involved in alopecia areata were identified, new treatment strategies can be developed. It could be possible to modify or inhibit autoantigen presentation. Another method mentioned by Lu and his co-authors would be to expose the immune system to such large amounts of antigen polypeptides that would then overload the receptors of pathogenic, autoreactive lymphocytes and could theoretically cause anergy or death of these cells (Lu et.al. 2006).

However, Hordinsky and Ericson (2004), mention that an autoantibody has yet to be implicated in alopecia areata. Gilhar and Kalish (2006), came to the logical conclusion that the autoantigen involved should be melanocyte derived. This is because generally alopecia areata affects only pigmented hair.

In a separate experiment, researchers used immunoperoxidase stains to test scalp samples for melanocyte density. They found that scalp samples from alopecia areata patients had a decreased number of follicular melanocytes. The researchers did not know if the decrease in melanocyte density is caused by the immune attack or by the rapid hair cycles that characterize the disease (Trautman et.al. 2009). Although these results are not conclusive, they do back the theory that autoantigens in alopecia areata may be derived from melanocytes.

Another recent study isolated a structural protein, trichohyalin, as a potential autoantigen involved in alopecia areata, as well as Keratin 16. Researchers used mass spectrometry on ten samples; these showed strong reactivity to the protein trichohyalin in all alopecia areata sera (Leung et.al. 2010). Trichohyalin is a 200-kDa protein of the IRS. It is a doublet in some animals but is a single polypeptide in humans (O'Keefe et.al. 1993). Moreover, immunofluorescence studies with alopecia areata sera and a monoclonal antibody to trichohyalin supported the theory as the immunoreactivity in the alopecia areata sera was in the same location as the trichohyalin in the inner root sheath of the hair follicle (Leung et.al. 2010). IgG tightly binds the inner root sheath and reacts with a 200/220kDa doublet by immunoblotting in all species studied, including canines affected by alopecia areata (Tobin et.al. 2003).

With further research, one of the above possibilities may be implicated as the definitive autoantigen in alopecia areata. This would promote new treatments directed toward the autoantigen itself or toward the lymphocytic cells that respond to it.

Hair-follicle-specific autoantibodies are found in the peripheral blood of individuals with the disease. Although some are found in normal individuals, autoantibodies such as hair-follicle specific IgGs are found in higher concentrations in alopecia areata patients than in non-affected individuals (Lu et.al. 2006). These appear to be targeting intracellular antigens. Abnormal deposits of complement and immunoglobulin IgG and IgM were also found in 92% of 12 patients with alopecia areata (Bystryń et.al. 1979). These findings indicate that autoimmune processes are responsible for the hair loss associated with alopecia areata.

One study questions this theory. In this study forty nude mice were grafted with scalp skin transplants from patients with alopecia areata. One group of mice was given intravenous injections of

serum from patients, and the other group was given normal serum. Although deposition of immunoreactants such as immunoglobulins and complement was noted in hair follicles of mice who received patients' serum, hair growth was observed in most cases. The researchers concluded that immunoreactants do not inhibit hair growth in alopecia areata (Gilhar, Pillar 1992).

Although hair follicle-specific antibodies may not be responsible for the initiation of alopecia areata, their production and presence in the hair follicle may stimulate extra damage or even maintain the disease. Tobin and his colleagues performed a study to further understand the pathogenic potential of these antibodies. They conducted the passive transfer of serum from horses affected by alopecia areata into the anagen skin of C57BL/ 10 mice. Although normal hair regrowth was observed in mice injected with the normal serum, hair did not regrow in the area around the injection site of the alopecia areata serum even 13 weeks after the injection (Tobin et.al. 1998). The evidence shown here supports the idea that anti-hair follicle autoantibodies promote the pathogenesis of alopecia areata.

Infectious Factors

The theory that alopecia areata was caused by an infectious disease was the leading theory until recently. In 1899, sixty-three out of sixty-nine teenage girls in a homeless shelter found bald patches on their heads (Bowen 1899). In 1971, there were reports of a widespread breakout of alopecia areata (Messenger, McDonagh 1997). Scientists of the time believed that alopecia areata was a contagious disease.

After one study where scientists tested ten scalp biopsies for the presence of cytomegalovirus DNA, alopecia areata was thought to be associated with the viral infection. Out of ten samples, nine tested positively- leading to the belief that CMV infection leads to alopecia areata. However, in 1996, when the above study could not be replicated, it was determined that the first samples were contaminated, and that CMV has no connection to alopecia areata (Tosti et.al. 1996). The results of a study in year 2000 support the idea that CMV is neither a triggering factor for the immune response in alopecia areata nor an activator of the autoimmunity (Offidani et.al. 2000). Perhaps the teenage girls and other hair loss patients had another non-related disease whose side effects include hair loss.

The etiology of alopecia areata is complex and involves many factors. It appears to have both a genetic and autoimmune basis. While scientists once believed that alopecia areata was itself, or was associated with, an infectious disease, that belief is insignificant today. Evidence of strong family history trends indicates that alopecia areata is, indeed, genetically based. Additionally, there are many studies that support the hypothesis that alopecia areata is an autoimmune disease and lead to the conclusion is that alopecia areata is mediated by autoimmune processes caused by chromosomal mutations in the genome.

Current Treatment Methods

Available treatments for alopecia areata include: corticosteroids, topical anthralin, topical minoxidil solution and contact sensitizers. Most of these therapies "bandage" the disease, stimulating hair growth instead of solving the immune problem.

Corticosteroids

Corticosteroids have an anti-inflammatory and immunomodulatory effect. Immunomodulators lessen the immune system's ability to produce antibodies that recognize and react with the antigen that

stimulated their production. Corticosteroids weaken the T-cell mediated immune attack on the hair follicle (Kumaresan M. 2010). Based on the theory that alopecia areata is carried out through attack of follicular autoantigens, treatment with corticosteroids should be successful at lessening the severity of the disease.

Corticosteroids are heavily used in the treatment of alopecia areata. However, their efficacy remains uncertain.

In one case study, eighteen patients with severe alopecia areata were given an oral dose of prednisone daily. Terminal hair growth (satisfactory growth- over 50% of the scalp) occurred in seven patients. Upon discontinuation of the drug, all the patients had a relapse. The researchers concluded that although initial growth was observed, this therapy does not produce lasting effects. Moreover, it was determined that the only way growth is retained after tapering the dosage or discontinuing the treatment is if spontaneous remission occurs (Alabdulkareem et.al. 1998). Oral corticosteroid therapy is also not recommended because of the adverse side effects (Nakajima et.al. 2007). Based on these results, one can state that corticosteroid treatment mitigates disease symptoms while undergoing treatment but does not cure the disease in one case.

The use of topical corticosteroid treatments yield slightly better results. In one study, five out of twenty-eight patients (17.8%) had almost complete hair renewal after being treated with 0.05% Clobetasol ointment. Eleven participants experienced painful folliculitis on the treated scalp (Tosti et.al. 2003). Although these results aren't excellent, the researchers noted that all participants had already undergone and failed to respond to topical immunotherapy. Therefore, they conclude that clobetasol propionate under occlusion should be listed as an effective treatment (Tosti et.al. 2003). Patients apply the ointment and then cover the area with plastic wrap, securing it to the skin with tape. Occlusion holds perspiration close to the skin, hydrating the top layer of the epidermis. Topical medications are absorbed into moist skin much more efficiently than with dry skin (Brannon, 2010).

Intralesional corticosteroids have an advantage over the oral and topical treatment options; this treatment maximizes the effect of the corticosteroids by penetrating the skin and injecting its contents straight into the affected tissue (Gregoriou et.al. 2011).

Doctors prescribe steroids with low solubility, this allows maximum action at the injection site for they absorb very slowly (Kumaresan, M. 2010). The most common drugs used are triamcinolone acetonide and betamethasone (Gregoriou et.al. 2011).

This method of treatment works best in groups of patients who have experienced less than 75% scalp hair loss, who have had a shorter duration of hair loss, and in children (Kumaresan M. 2010). However, a study using ten participants with over 50% loss showed that the treatment does work well for patients with extensive loss. Six of the ten participants responded to treatment of intralesional triamcinolone acetonide. The researchers concluded that the reason intralesional corticosteroids are not generally used on patients with extensive loss is because it is painful and time consuming for the patient. This study also mentions that the average length of the episode of alopecia areata was the same in responders and non-responders (Chang et.al. 2009). From this it can be determined that the treatment is not curative, but can interfere with the pathogenesis of the disease while in use.

Another faster, less painful option is now being used to treat extensive alopecia areata. Instead of

using conventional needles to apply the steroids, doctors use a multi-injection plate. There are several advantages to this method. Firstly, it allows for the simultaneous injection in five to seven different points at a fixed distance. This leads to uniformity in application, which may prevent skin atrophy. Treatments are followed by a gentle massage, also to help spread the steroids evenly. Another advantage is that the needle is long and the tip can reach the desired depth of the hair bulb where the drug is delivered. The disadvantage to this treatment is that the needles are large, and if not handled gently, can cause pain (Ferrando, Moreno-Arias 2000).

Although the aforementioned studies indicate that the intralesional treatment of alopecia areata is beneficial to those with excessive hair loss, this method is still considered the best option for patients with less than 50% loss (Kumaresan, M. 2010).

Minoxidil

Minoxidil is an antihypertensive vasodilator known to slow the onslaught of alopecia areata and promote hair regrowth. Minoxidil's exact mechanism is not known. However, tissue studies showed that treatment with minoxidil causes an increase of follicles in anagen and a reduction of follicles in telogen. This is indicated by the fact that after treatment, increased hair length is found on the forehead and other areas of the body that do not usually grow long hairs. The abnormal growth, referred to as hypertrichosis, suggests that the anagen phase of these follicles is of a longer duration (Messenger, Rundegren 2003).

Cellular uptake studies in murine follicles showed that minoxidil and minoxidil sulphate converged in the melanocytes and pigmented epithelial cells of the hair follicle. This is interesting because previously mentioned studies implicate melanocytes as a possible source of autoantigens in alopecia areata. If minoxidil binds to melanocytes, and then is observed to cause an increase in hair growth, this observation can then serve as proof as to the role of melanocytes in the pathogenesis of alopecia areata.

However, in this case, the researchers believed the reaction of minoxidil and melanin had no bearing on the growth that resulted, as there was no evidence of minoxidil binding to non-pigmented follicles although there was noted growth in both pigmented and non-pigmented follicles (Messenger, Rundegren 2003). This was a significant realization, as alopecia areata does not affect non-pigmented hair follicles.

Perhaps the mechanism that minoxidil uses does not include or affect the melanocytes but causes growth in a way that both interferes with the pathogenesis of the disease and enhances growth of healthy follicles as well. Or, maybe the minoxidil and melanin connection does exist and does reverse the pathogenesis of the disease, as well as it enhances healthy, non-pigmented follicular growth by other mechanisms. This would explain why there was excessive growth noted in non-pigmented hair follicles as well.

The concentration of the active ingredient in minoxidil treatment can be varied. However, study results imply that the treatment is more effective when higher concentrations of minoxidil are used. In one experiment, forty-seven patients were treated with topical 1% minoxidil and forty-six patients were treated with topical 5% minoxidil. Patients with extensive hair loss showed a response rate of 38% with 1% minoxidil, while those who received 5% minoxidil showed an 81% response rate (Fiedler-Weiss,

1987).

In one double blind, placebo controlled study, researchers divided patients into two groups; eleven patients received 3% topical minoxidil while fourteen other patients received a placebo. Hair growth was observed in seven of the eleven patients (63.6%) in the minoxidil group and in five of the placebo group (35%). Furthermore, 27% of the minoxidil group showed cosmetically acceptable hair growth compared with 7.1% in the placebo group (Price, 1987). This study showed that treatment with 3% minoxidil results in hair growth, even though the dosage is not as strong as 5% minoxidil drugs.

Although the topical 5% minoxidil treatment plan yields better results than the versions with lower concentrations, it is also known to cause hypertrichosis on the face and neck, especially in children (Wang et.al. 2012). Several patients also reported contact dermatitis as another adverse side effect. This may be the reason that most treatment plans for alopecia areata include a low concentration of topical minoxidil along with other drugs such as corticosteroids.

Studies also suggest that patients with minimal hair loss have a better chance of hair renewal with this treatment than those patients with more hair loss. An early double-blind study observed that patients with severe hair loss responded more weakly to treatment of topical 1% minoxidil than those with moderate hair loss. Those with localized alopecia areata gained cosmetically acceptable hair regrowth (Gregoriou et.al. 2011).

Anthralin

Treatment with anthralin is another possible option for achieving hair regrowth. In one study, patients with extensive alopecia areata were treated with 0.5%- 1.0% anthralin cream. As a result of the treatment, 25% had cosmetically acceptable hair renewal. All patients suffered from the same side effects: intense itchiness, scaling, and erythema on the treated area (Fiedler-Weiss, Buys 1987).

However, in another study, only five of fifty-one patients treated with a mixture of 5% minoxidil and 0.5% anthralin had cosmetically acceptable hair growth (Alsantali, 2011). While it is possible that the co-treatment of minoxidil and anthralin has undesirable effects, it is more likely that there are other factors involved. More research must be done on treatment of alopecia areata with anthralin in order to render this treatment worthy.

Topical Immunotherapy

Diphenylcyclopropenone (DPCP) is a topical sensitizer used in the treatment of alopecia areata. DPCP is a novel therapy because of its high success rate. It has a response rate of 60% in severe alopecia areata and about 88 to 100% in patients with patchy alopecia areata (Singh, Lavanya 2010).

Perhaps its success rate is due to the fact that contact sensitization agents may modify antigen presenting cells. The antigen presenting cells then have trouble recognizing autoantigens. This stops the alopecia areata cycle (Hordinsky, Ericson 2004).

Generally, treatment is performed on the scalp. A cotton-tipped applicator soaked with 2% acetone solution of DPCP is applied to an area on the scalp. Two weeks later, a 0.001% solution of DPCP is applied. The solution should be retained on the scalp for forty-eight hours. The application is repeated weekly, increasing the concentration each time until a mild dermatitis is observed (Singh, Lavanya 2010). If the patient does not respond after six months, the patient should terminate DPCP treatment.

Out of fifty-four Greek alopecia areata patients that underwent immunotherapy, 83% responded. All research participants had extensive alopecia, or long lasting alopecia. Twenty patients experienced re-growth of terminal hair on the whole scalp; fifteen achieved re-growth of most terminal hair with some remaining patches of alopecia; nine had sparse regrowth of pigmented, terminal hair; and one patient observed regrowth of vellus hair. Terminal hair is dark, thick and long, while vellus hair is described as short, fine and barely noticeable hair. Overall, the treatment was very successful. Thirty-one patients had a relapse after conclusion of the treatment and underwent immunotherapy again (Avgerinou et.al. 2007). The relapse rate is high, but according to the researchers, this may be due to the failure of patients to undergo maintenance therapy once they experience cosmetically adequate regrowth (Gregoriou et.al. 2011).

Topical immunotherapy can cause side effects such as persistent dermatitis, swollen lymph nodes and contact leukoderma (Singh, Lavanya 2010).

Conclusions

Although some patients with alopecia areata have positive hair growth as a result of treatment, most are disappointed. Many patients who respond to treatment initially experience a relapse as soon as they taper the dosage or stop treatment. This is because most of the treatments that are currently available to patients do not rectify the problems that cause alopecia areata. Rather, they are general hair growth treatments that are nonspecific to alopecia areata. The best treatment option on the market today is immunotherapy with DPCP. This is because the mechanism that DPCP uses actually alters the cells that promote pathogenesis of alopecia areata. If more research is done into the etiology of alopecia areata, newer treatments can be developed that target the disease's pathogenic development.

References

- Alabdulkareem, A., Abahussein, A., & Okoro, A. (1998). Severe alopecia areata treated with systemic corticosteroids. *International Journal of Dermatology*, 622-624. Retrieved from EBSCO database.
- Alaiti, S. (2011, August 5). Hair anatomy. Retrieved December 18, 2012, from MedscapeReference website: <http://emedicine.medscape.com/article/835470-overview#aw2aab6b4>
- Alonso, L., & Fuchs, E. (2006). The hair cycle. *Journal of Cell Science*, 391-393.
- Alsantali, A. (2011). Alopecia areata: A new treatment plan. *Clinical, Cosmetic and Investigational Dermatology*, (4), 107-115. doi:10.2147/CCID.S22767
- Avgerinou, G., Gregoriou, S., Rigopoulos, D., Stratigos, A., Kalogeromitros, D., & Katsambas, A. (2007). Alopecia areata: Topical immunotherapy treatment with diphenylpyrone [PDF]. *Journal of the European Academy of Dermatology and Venereology*, 22(3), 320-323. doi:10.1111/j.1468-3083.2007.02411.x
- Bergfeld, W. F. (2009, January). Hair disorders. Retrieved December 10, 2012, from The Cleveland Clinic Foundation website: <http://www.clevelandclinicmeded.com/medicalpubs/diseasemanagement/dermatology/hair-disorders/>

- Blaumeiser, B., Van Der Goot, I., Fimmers, R., Hanneken, S., Ritzman, S., Seymons, K., . . . Nothen, M. M. (2006). Familial aggregation of alopecia areata. *American Academy of Dermatology*, *54*(4), 627-632. Retrieved from ScienceDirect database.
- Botchkarev, V., & Cotsarelis, G. (2012). Biology of hair follicles. In L. Goldsmith, P. Gilchrist, & D. Leffell (Authors), *Fitzpatrick's dermatology in general medicine*. 8th ed. New York: McGraw-Hill.
- Botchkarev, V. A., Botchkareva, N. V., Lindner, G., Ling, G., Paus, R., & Van Der Veen, C. (1997). Analysis of apoptosis during hair follicle regression (Catagen). *The American Journal of Pathology*, *151*(6), 1601-1617. Retrieved from PMC database.
- Bowen, J. T. (1899.). Archives a Century Ago: Two epidemics of alopecia areata in an asylum for girls. *Journal of Cutaneous and Genito-Urinary Diseases*, *135*(9), 1038.
- Brannon, H. (2010, March 1). How to use topical steroids. Retrieved December 31, 2012, from About.com Dermatology website: <http://dermatology.about.com/cs/medications/a/howtosteroid.htm>
- Bystryn, J.-C., Orentreich, N., & Stengel, F. (1979). Direct immunofluorescence studies in alopecia areata and male pattern alopecia. *Journal of Investigative Dermatology*, *73*(5), 317-320. Retrieved from <http://www.nature.com/jid/journal/v73/n5p1/full/5616150a.html>
- Chang, K. H., Goldberg, L. J., & Rojhirunsakool, S. (2009). Treatment of severe alopecia areata with intralesional steroid injections. *Journal of Drugs in Dermatology*, *8*(10), 909. Retrieved from Academic OneFile database.
- Dy, L. C., & Whiting, D. A. (2011). Histopathology of alopecia areata, acute and chronic: Why is it important to the clinician? *Dermatologic Therapy*, *24*(3), 369-374. Retrieved from Academic Search Complete database.
- Etzioni, A., Gilhar, A., & Paus, R. (2012). Medical progress: Alopecia areata. *The New England Journal of Medicine*, *366*(16), 1515-1525. Retrieved from Proquest Central database.
- Ferrando, J., & Moreno-Arias, G. A. (2000). Multi?Injection plate for intralesional corticosteroid treatment of patchy alopecia areata. *Dermatologic Surgery*, *26*(7), 690-691. Retrieved from Academic Search Complete database.
- Fiedler-Weiss, V. C. (1987). Topical minoxidil solution (1% and 5%) in the treatment of alopecia areata. *Journal of the American Academy of Dermatology*, *16*(3), 745-748. Retrieved from ScienceDirect database.
- Fiedler-Weiss, V. C., & BuysPu, C. M. (1987). Evaluation of anthralin in the treatment of alopecia areata. *Archives of Dermatology*, *123*(11), 1491-1493. Abstract retrieved from PubMed database.
- Gilhar, A., & Kalish, R. S. (2006). Alopecia areata: A tissue specific autoimmune disease of the hair follicle. *Autoimmunity Reviews*, *5*(1), 64-69. Retrieved from ScienceDirect database.
- Gilhar, A., Pillar, T., Assay, B., & David, M. (1992). Failure of passive transfer of serum from patients with alopecia areata and alopecia universalis to inhibit hair growth in transplants of human scalp skin grafted onto nude mice. *British Journal of Dermatology*, *126*(2), 166-171.

- Gregoriou, S., Kazakos, C., & Rigopoulos, D. (2011). Treatment options for alopecia areata. *Expert Review of Dermatology*, 6(5), 537-548. Retrieved from ProQuest Science Journals database.
- Hordinsky, M., & Ericson, M. (2004). Autoimmunity: Alopecia areata. *The Journal of Investigative Dermatology*, 9(1), 73-78. Retrieved from ProQuest Science Journals database.
- Kumaresan, M. (2010). Intralesional steroids for alopecia areata. *International Journal of Trichology*, 2(1), 63-65. Retrieved from ProQuest Science Journals database.
- Leung, M. C., Sutton, C. W., Fenton, D. A., & Tobin, D. J. (2010). Trichohyalin is a potential major autoantigen in human alopecia areata. *Journal of Proteome Research*. Abstract retrieved from <http://www.bionity.com/en/publications/36882/trichohyalin-is-a-potential-major-autoantigen-in-human-alopecia-areata.html>
- Lu, W., Shapiro, J., Barekatin, A., Lo, B., Finner, A., & McElwee, K. (2006). Alopecia areata: Pathogenesis and potential for therapy. *Expert Reviews in Molecular Medicine*, 8(14), 1. doi:10.1017/S146239940601101X
- Manolache, L., & Benea, V. (2007). Stress in patients with alopecia areata and vitiligo. *Journal of the European Academy of Dermatology & Venereology*, 21(7), 921-928. Retrieved from Academic Search Complete database.
- McElwee, K. J., & Wang, E. (2011). Etiopathogenesis of alopecia areata: Why do our patients get it? *Dermatologic Therapy*, 24(3), 337-347. Retrieved from Academic Search Complete database.
- Messenger, A. G., & McDonagh, A. J.G. (1997). Alopecia areata: Aetiology and pathogenesis [PDF]. *Korean Journal of Investigative Dermatology*, 4(2), 109-118.
- Messenger, A. G., & Rundegren, J. (2003). Minoxidil: Mechanisms of action on hair growth [PDF]. *British Journal of Dermatology*, 150(2), 186-194.
- Nakajima, T., Inui, S., & Itami, S. (2007). Pulse corticosteroid therapy for alopecia areata: Study of 139 patients. *Dermatology*, 215(4), 320-324. Retrieved from ProQuest Health and Medical Complete database.
- Promocell [Normal Hair Follicle Structure]. (n.d.). Retrieved from http://www.promocell.com/fileadmin/promocell/Kapitelbilder/Follicle_Dermal_Papilla_Cells_2.jpg
- Offidani, A., Amerio, P., Bernardini, M. L., Feliciani, C., & Bossi, G. (2000). Role of cytomegalovirus replication in alopecia areata pathogenesis. *Journal of Cutaneous Medicine and Surgery*, 4(2), 63-65. Retrieved from PubMed database.
- O'Keefe, E. J., Hamilton, E. H., Lee, S.-C., & Steinert, P. (1993). Trichohyalin: A structural protein of hair, tongue, nail, and epidermis. *Journal of Investigative*
- Petukhova, L., Cabral, R. M., Mackay-Wiggan, J., Clynes, R., & Christiano, A. M. (2011). The genetics of alopecia areata: What's new and how will it help our patients. *Dermatologic Therapy*, 24(3), 326-336. Retrieved from EbscoHost database.
- Price, V. H. (1987). Double-Blind, placebo-controlled evaluation of topical minoxidil in extensive alopecia areata. *Journal of the American Academy of Dermatology*, 16(3), 730-736. Retrieved from ScienceDirect database.

- Ross, E. K., Vincenzi, C., & Tosti, A. (2006). Videodermoscopy in the evaluation of hair and scalp disorders. *Journal of the American Academy of Dermatology*, *55*(5), 799-806. Retrieved from ScienceDirect database.
- Singh, G., & Lavanya, M. (2010). Topical immunotherapy in alopecia areata. *International Journal of Trichology*, *2*(1), 36-39. Retrieved from ProQuest Science Journals database.
- [The Stages of the Normal Hair Cycle]. (n.d.). Retrieved from <http://ozskin.wordpress.com/2012/06/01/the-science-of-laser-hair-removal/>
- Sundberg, J. P., McElwee, K. J., Carroll, J. M., & King, L. E., Jr. (2011). Hypothesis testing: CTLA4 co-stimulatory pathways critical in the pathogenesis of human and mouse alopecia areata. *Journal of Investigative Dermatology*, *131*(11), 2323-2324. Retrieved from ProQuest Science Journals database.
- Thomas, E. A., & Kadyan, R. S. (2008). Alopecia areata and autoimmunity: A clinical study. *Indian Journal of Dermatology*, *53*(2), 70-74. Retrieved from PMC database.
- Tobin, D. J., Alhaidari, Z., & Olivry, T. (1998). Equine alopecia areata autoantibodies target multiple hair follicle antigens and may alter hair growth. A preliminary study. *Experimental Dermatology*, *7*(5), 289-297. Retrieved from PubMed database.
- Tobin, D. J., Gardner, S. H., Luther, P. B., Dunston, S. M., Lindsey, N. J., & Olivry, T. (2003). A natural canine homologue of alopecia areata in humans. *British Journal of Dermatology*, *149*(5), 938-950.
- Tosti, A., & Gray, J. (2007). Assessment of hair and scalp disorders. *Journal of Investigative Dermatology Symposium Proceedings*, *12*(2), 23-27. Retrieved from ProQuest Science Journals database.
- Tosti, A., La Placa, M., Placucci, F., Gentilomi, G., Venturoli, S., Zerbini, M., & Musiani, M. (1996). [Letter to the editor]. *Journal of Investigative Dermatology*, 443. Retrieved from <http://www.nature.com/jid/journal/v107/n3/pdf/5610419a.pdf>
- Tosti, A., Piraccini, B. M., Pazzaglia, M., & Vincenzi, C. (2003). Clobetasol propionate 0.05% under occlusion in the treatment of alopecia totalis/universalis. *Journal of the American Academy of Dermatology*, *49*(1), 96-98. Retrieved from ScienceDirect database.
- Trautman, S., Thompson, M., Roberts, J., & Thompson, C. T. (2009). Melanocytes: A possible autoimmune target in alopecia areata. *Journal of the American Academy of Dermatology*, *61*(3), 529-530. Retrieved from ScienceDirect database.
- Wang, E., Lee, J., & Tang, M. (2012). Current treatment strategies in pediatric alopecia areata. *Indian Journal of Dermatology*, *57*(6), 459-465.
- Wikramanayake, T. C., Alvarez-Connelly, E., Simon, J., Mauro, L. M., Guzman, J., Elgart, G., . . . Jimenez, J. J. (2010). Heat treatment increases the incidence of alopecia areata in the c3h/hej mouse model. *Cell Stress & Chaperones*, *15*(9), 985-991. Retrieved from PMC database.
- Wikramanayake, T. C., Villasante, A. C., Mauro, L. M., Perez, C. I., Schachner, L. A., & Jimenez, J. J. (2012). Prevention and treatment of alopecia areata with quercetin in the c3h/hej mouse model. *Cell Stress Chaperones*, *17*(2), 267-274. doi:10.1007/s12192-011-0305-3