



**TOURO COLLEGE &
UNIVERSITY SYSTEM**

Touro Scholar

Touro College of Osteopathic Medicine (New York) Publications and Research

Touro College of Osteopathic Medicine (New York)

2017

Pseudomembranous Tracheitis Caused by *Aspergillus Fumigatus* in the Setting of High Grade T-Cell Lymphoma

Prashant Malhotra

Karan Singh

Paul Gill

Sonu Sahni

Touro College of Osteopathic Medicine (New York), sonu.sahni@touro.edu

Mina Makaryus

See next page for additional authors

Follow this and additional works at: https://touro scholar.touro.edu/tcomny_pubs



Part of the [Hemic and Lymphatic Diseases Commons](#), and the [Respiratory Tract Diseases Commons](#)

Recommended Citation

Malhotra, P., Singh, K., Gill, P., Sahni, S., Makaryus, M., & Talwar, A. (2017). Pseudomembranous tracheitis caused by *Aspergillus fumigatus* in the setting of high grade T-cell lymphoma. *Respiratory Medicine Case Reports*, 21, 42-45.

This Article is brought to you for free and open access by the Touro College of Osteopathic Medicine (New York) at Touro Scholar. It has been accepted for inclusion in Touro College of Osteopathic Medicine (New York) Publications and Research by an authorized administrator of Touro Scholar. For more information, please contact Timothy J Valente timothy.valente@touro.edu.

Authors

Prashant Malhotra, Karan Singh, Paul Gill, Sonu Sahni, Mina Makaryus, and Arunabh Talwar



Case report

Pseudomembranous tracheitis caused by *Aspergillus fumigatus* in the setting of high grade T-cell lymphoma

Prashant Malhotra, M.D.^a, Karan Singh, MBBS^b, Paul Gill, B.S.^b, Sonu Sahni, M.D.^b, Mina Makaryus, M.D.^b, Arunabh Talwar, M.D., FCCP^{b,*}

^a Northwell Health, Department of Infectious Diseases, 400 Community Drive, Manhasset, NY 11030, United States

^b Northwell Health, Department of Pulmonary, Critical Care and Sleep Medicine, 410 Lakeville Rd., New Hyde Park, NY 11040, United States

ARTICLE INFO

Article history:

Received 15 December 2016

Received in revised form

22 March 2017

Accepted 24 March 2017

Keywords:

Pseudomembranous tracheitis

Aspergillus

Bronchoscopy

Immunocompromised

Chronic cough

T-cell lymphoma

ABSTRACT

Pseudomembranous tracheitis (PMT) is a rare condition most commonly caused by fungal or bacterial infection that is characterized by a pseudomembrane that partially or completely covers the tracheo-bronchial tree. PMT is most commonly found in immunocompromised patient populations, such as post-chemotherapy, AIDS, post-transplant and hematological malignancies. Due to its rarity, PMT is often not included in the differential diagnosis. This case describes a 65 year old male with persistent fever and refractory cough despite high dose empiric antibiotics. Subsequent bronchoscopy with biopsy revealed pseudomembranous tracheitis due to *Aspergillus fumigatus* in the setting of T-cell lymphoma. PMT should be considered in the differential diagnosis of refractory cough in the immunocompromised population. However, it has been described in patients with nonspecific respiratory symptoms such as dyspnea, cough, and other airway issues.

© 2017 Published by Elsevier Ltd. This is an open access article under the CC BY-NC-ND license (<http://creativecommons.org/licenses/by-nc-nd/4.0/>).

1. Introduction

Pseudomembranous tracheitis (PMT) is a rare condition most commonly caused by fungal or bacterial infection that is characterized by a pseudomembrane that partially or completely covers the tracheobronchial tree. PMT is most often found in immunocompromised patient populations, such as post-chemotherapy, AIDS, post-transplant, and hematological malignancies [1,2]. Fungal infections of the trachea can cause this rare phenomenon which may potentially lead to necrosis [3]. The pathogens known to cause this pseudomembranous infection are: *Aspergillus*, *Candida*, *Cryptococcus*, *Rhizopus*, and *Mucorales* [4,5]. In more rare cases, pseudomembranous tracheitis may be caused by invasive bacterial pathogens such as *Bacillus cereus* [6]. PMT should be considered in the differential diagnosis of refractory cough in the immunocompromised population. However, it has been described in patients with nonspecific respiratory symptoms such as dyspnea, cough, and other airway issues [7]. Herein, we present a case of

pseudomembrane tracheitis in the setting of high grade T-cell lymphoma.

2. Case report

A 65 year old male with a past medical history of non-obstructive coronary artery disease, urothelial cancer (status post resection), abdominal aortic aneurysm (status post repair), hypothyroidism, and 50 pack-year history of smoking, was admitted presenting with recurring fevers and a 30-pound weight loss over the past several months. A Chest x-ray (CXR) revealed a right mid-lung consolidation. Computer tomography (CT) showed a left supraclavicular/lower cervical mass, hilar lymphadenopathy as well as enlargement of the subcarinal and mediastinal lymph nodes. Subsequent lymph node biopsy revealed high grade T-cell lymphoma.

The patient was started up on empiric antibiotic therapy but continued to be febrile. He subsequently underwent bronchoscopy which revealed a pseudomembrane extending from the bronchus intermedius down to the right lower lobe (Fig. 1). Bronchoscopy was negative for any masses, abscesses, erosions or areas of bleeding.

Both an endobronchial biopsy as well as culture of the bronchoalveolar lavage revealed *Aspergillus fumigatus* (Fig. 2).

* Corresponding author.

E-mail addresses: pmalhotr@northwell.edu (P. Malhotra), ksingh11@northwell.edu (K. Singh), paulgill9112@gmail.com (P. Gill), sahni.sonu@gmail.com (S. Sahni), mmakaryus1@northwell.edu (M. Makaryus), arunabhtalwar1@gmail.com (A. Talwar).

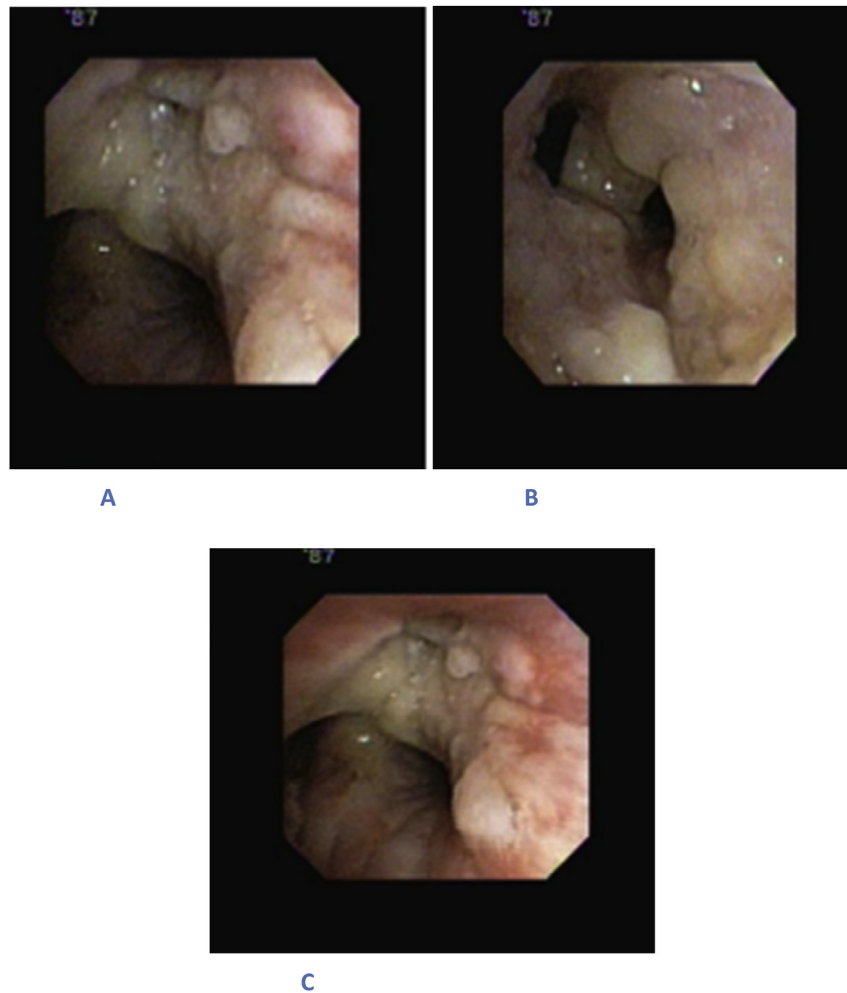


Fig. 1. Bronchoscopy shows mucous-like layer in the bronchotracheal tree. A) Right upper lobe apico-posterior B) Bronchus intermedius C) Secondary carina right side.

Patient was initiated on Voriconazole. Repeat bone marrow biopsy was negative for *Aspergillus*. The patient was discharged on Voriconazole and oxygen. Despite treatment the patient died of progressive pulmonary infiltrates and respiratory failure.

3. Discussion

Pseudomembranous tracheitis (PMT) is commonly caused by fungal or bacterial infection that is characterized by

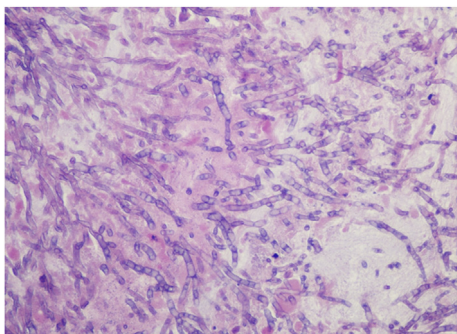


Fig. 2. Microscopic view of biopsy shows strains of *Aspergillus fumigatus* with characteristic hyphae.

pseudomembrane formation in the large airways [1,2]. Here we described a case of a 65-year-old male with undiagnosed malignancy that had developed *Aspergillus*-related PMT. PMT is a rare condition that manifests with different symptoms and etiologic microorganisms. Previously reported cases of PMT have been outlined in Table 1.

Invasive pulmonary aspergillosis (IPA) is the most common form of disease caused by *Aspergillus* species infection. In addition, a rare form of IPA is an infection of the tracheobronchial tree, called *Aspergillus* Tracheobronchitis (AT) [17]. Four types of AT: ulcerative tracheobronchitis, obstructive bronchial aspergillosis, *Aspergillus* bronchitis, and pseudomembranous necrotizing bronchial aspergillosis, or PMT have been described [1,2]. The pseudomembrane is thought to be derived from fibrin, hyphae, and necrotic tissue [12]. Other fungi such as *Rhizopus*, *Cryptococcus* and *Candida* can also form a pseudomembrane via similar mechanisms [4,5]. Rarely viruses may be implicated in PMT. Known causes of PMT have been outlined in Table 2.

Patients with pseudomembranous tracheitis typically present symptoms of dyspnea, fever, non-resolving cough, and chest pain. Dyspnea, as one of the presenting symptoms, is usually caused by the pseudomembrane obstructing the airways to the lungs [11]. Colonies of fungi create plaques that line the bronchi which leads to a necrotizing bronchitis. Most common signs and symptoms of PMT are outlined in Table 3.

PMT is a rare condition, therefore a strong clinical suspicion is

Table 1
Cases of PMT.

Author	Primary disease	Causes	Organism	Signs/Symptoms	Treatment	Outcomes
Williams et al. [5]	Leukemia	Stem cell transplantation secondary to pancytopenia	<i>Aspergillus</i>	Progressive cough, nausea	Amphotericin B (IV), Amphotericin B (inhaled), caspofungin (IV)	Deceased
Strauss et al. [6]	Unknown	Aplastic Anemia	<i>Bacillus cereus</i>	Petechiae, weakness, dyspnea	Broad-spectrum antibiotic, anti-viral, antifungal therapy	Deceased (multiple organ failure)
Chang et al. [8]	Pt. 1: Diabetes mellitus Pt. 2: Diabetes	Diabetic ketoacidosis Diabetic ketoacidosis	<i>Aspergillus</i> <i>Aspergillus</i>	Chest pain, cough, dyspnea, wheeze Non-productive cough, right side chest pain, fever	Parental amphotericin B amphotericin B	Deceased (septic shock) Improved
Tait et al. [7]	Pt. 1: Non-Hodgkin's lymphoma Pt. 2: Systemic lupus erythematosus-like disorder	Neutropenia Neutropenia	<i>Aspergillus</i> <i>Aspergillus</i>	Weight loss, anorexia, non-productive cough, and pyrexia Weight loss, polyarthralgia, night sweats, pyrexia	amphotericin B intravenous amphotericin B (1 mg/kg/day), flucytosine (120 mg/kg/day), and oral itraconazole (600 mg/day) commenced,	Deceased Deceased (respiratory failure)
Hines et al. [9]	Pt.1: COPD Pt.2: Hodgkin's lymphoma Pt. 3 Myelodysplastic syndrome Pt. 4 Hepatic lesions	Respiratory arrest Neutropenia Bone marrow transplant Neutropenia	<i>Aspergillus</i> <i>Aspergillus</i> <i>Aspergillus</i> <i>Aspergillus</i>	Fever, wheezing Fever Fever, hypotension Epigastric and lower back pain	Vancomycin, Clindamycin, Amikacin Amphotericin B Amphotericin B Broad spectrum antibiotics	Deceased Deceased (respiratory failure) Deceased (progressive respiratory insufficiency) Deceased
Pornsuriyasak et al. [10]	Tuberculous	Tuberculous tracheal stenosis	<i>Aspergillus</i>	Fever, Dyspnea, Chest pain	Oral voriconazole Nebulized amphotericin B	Cured
Huang et al. [11]	16 cases: 56.3% (9/16) Pulmonary malignancies 31.3% (5/16) Bronchial involvement secondary to non-pulmonary tumor 12.5% (2/16) Lung transplant	62.5% (10/16) Radiotherapy 43.8% (7/16) Repeated chemotherapy 25.0% (4/16) Recurrent intervention therapy by bronchoscope	<i>Aspergillus</i>	87.5% (14/16) Progressive dyspnea 75.0% (12/16) Irritable cough	100% Amphotericin B (inhalation and infusion)	68.8% (11/16) Deceased
Putnam et al. [3]	Leukemia	Bone marrow transplantation secondary to aplastic anemia	<i>Aspergillus</i>	Weakness, fatigue, dyspnea	Amphotericin B (IV)	Deceased
Patel et al. [12]	Leukemia	Pancytopenia	<i>Aspergillus</i>	Shortness of breath, cough, pleuritic chest pain	Amphotericin B (IV)	Deceased (progressive leukemia and sepsis)
Williams et al. [5]	Type 2 Diabetes and leukemia	allogeneic stem cell trans-plantation.	<i>Rhizopus</i> sp.	Progressive cough, dyspnea, nausea and emesis	intravenous liposomal amphotericin B, inhaled amphotericin B, intravenous caspofungin	Deceased (respiratory failure)
Le et al. [13]	Acute lymphoblastic leukemia.	chemotherapy	<i>Aspergillus</i> .	Cough, fever, and hoarseness.	Intravenous voriconazole G-CSF	Improved
Argüder et al. [14]	Diabetes mellitus	Inconsistent use of insulin	<i>Aspergillus</i>	Cough, chest pain, hoarseness, fever, dyspnea	liposomal amphotericin B	Deceased
Ramos et al. [15]	Cardiac amyloidosis	Heart transplant	<i>Aspergillus</i>	Fever, dyspnea, wheezing, and a cough	IV voriconazole IV caspofungin	Improved
Shah et al. [16]	Stillbirth	Pulmonary edema	<i>Aspergillus</i>	Dyspnea, stridor	Voriconazole	Improved, then lost to follow up

needed to diagnose this condition. Bronchoscopy is essential to discover pseudomembrane in the airways. A pseudomembrane has the potential to form and constrict the airways, thus causing the symptoms that are associated with PMT [7]. Based on pathological tissue, brush smear, and fluid from bronchial that are obtained by a bronchoscopy, the results can lead to a diagnosis of airway aspergillus infection and the type of *Aspergillus* as well [11]. In our case non resolution of infiltrates despite adequate antibiotic therapy prompted us to perform a bronchoscopy.

Since pseudomembranous tracheitis is mostly caused by fungal

infection, a range of antifungal treatments would deem most effective towards the condition. Table 1 suggests that amongst health care providers intravenous Amphotericin B is the initial treatment of choice [11]. Other treatments such as voriconazole, itraconazole, and echinocandins (caspofungin) [5,12] However recently, Voriconazole has been administered to patients with PMT due to its better prognosis, as shown in Table 1.

PMT has a high morbidity and mortality in immunosuppressed patients. This in itself lends to a high morbidity and mortality that is associated with opportunistic infections. It has been reported that

Table 2
Causes of Pseudomembranous tracheitis.

Infectious Causes	Noninfectious Causes
<i>Fungal</i>	Smoke inhalation
• Aspergillus species	Endotracheal intubation
• Candida	Crohn disease
• Cryptococcus	Stevens-Johnson syndrome
• Rhizopus	Agents of bioterrorism
• Mucorales	Ligneous conjunctivitis
<i>Bacterial</i>	Paraquat ingestion
• Pseudomonas aeruginosa	
• Haemophilus influenza	
• Corynebacterium diphtheriae	
• Staphylococcal infections	
• a-hemolytic Streptococcus species	
• Moraxella catarrhalis	
• Bacillus cereus	
• Chlamydia species	
• Mycoplasma bovis	
• Pseudomembranous croup	
<i>Viral</i>	
• Bovine herpes virus1	
• Adenovirus	
• Influenza (co-infection)	

Adapted from Patel et al. [12].

Table 3
Common symptoms of PMT.

Fever
Dyspnea
Cough
Chest pain
Fatigue
Unilateral wheeze

death usually ensues between 1 and 6 weeks after diagnosis [18]. Majority of cases of PMT have resulted in demise as demonstrated in Table 1. Some causes for death include respiratory failure, septic shock, or other organ failure. Respiratory failure in PMT may result from the pseudomembrane constricting the airways and can even dislodge thus creating a ball valve that leads to obstruction [6,12].

4. Conclusion

PMT is a rare condition that is mostly caused by fungal, and sometimes, bacterial infection. It usually requires a high index of suspicion for diagnosis. The prognosis depends on timely diagnosis and initiation of antifungal therapy.

Funding source

The author(s) received no financial support for the research, authorship and/or publication of this article.

Financial disclosure

The authors have no financial relationships relevant to this case report to disclose.

Conflict of interest

The authors have no potential conflicts of interest to disclose.

References

- [1] D.W. Denning, Invasive aspergillosis, Clin. Infect. Dis. Off. Publ. Infect. Dis. Soc. Am. 26 (4) (1998), 781–803; quiz 804–5.
- [2] M.R. Kramer, D.W. Denning, S.E. Marshall, D.J. Ross, G. Berry, N.J. Lewiston, D.A. Stevens, J. Theodore, Ulcerative tracheobronchitis after lung transplantation. A new form of invasive aspergillosis, Am. Rev. Respir. Dis. 144 (3 Pt 1) (1991) 552–556.
- [3] J.B. Putnam Jr., C. Dignani, R.C. Mehra, E.J. Anaisse, R.C. Morice, H.I. Libshitz, Acute airway obstruction and necrotizing tracheobronchitis from invasive mycosis, Chest 106 (4) (1994) 1265–1267.
- [4] D. Karnak, R.K. Avery, T.R. Gildea, D. Sahoo, A.C. Mehta, Endobronchial fungal disease: an under-recognized entity, Respir. Int. Rev. Thorac. Dis. 74 (1) (2007) 88–104.
- [5] K.E. Williams, J.M. Parish, P.J. Lyng, R.W. Viggiano, L.J. Wesselius, I.T. Ocal, H.R. Vikram, Pseudomembranous tracheobronchitis caused by Rhizopus sp. After allogeneic stem cell transplantation, J. Bronchol. Intervent. Pulmonol. 21 (2) (2014) 166–169.
- [6] R. Strauss, A. Mueller, M. Wehler, D. Neureiter, E. Fischer, M. Gramatzki, E.G. Hahn, Pseudomembranous tracheobronchitis due to Bacillus cereus, Clin. Infect. Dis. Off. Publ. Infect. Dis. Soc. Am. 33 (5) (2001) E39–E41.
- [7] R.C. Tait, B.R. O'Driscoll, D.W. Denning, Unilateral wheeze caused by pseudomembranous aspergillus tracheobronchitis in the immunocompromised patient, Thorax 48 (12) (1993) 1285–1287.
- [8] S.M. Chang, H.T. Kuo, F.J. Lin, C.Y. Tzen, C.Y. Sheu, Pseudomembranous tracheobronchitis caused by Aspergillus in immunocompromised patients, Scand. J. Infect. Dis. 37 (11–12) (2005) 937–942.
- [9] D.W. Hines, M.H. Haber, L. Yaremko, C. Britton, R.W. McLawhon, A.A. Harris, Pseudomembranous tracheobronchitis caused by Aspergillus, Am. Rev. Respir. Dis. 143 (6) (1991) 1408–1411.
- [10] P. Pornsuriyasak, S. Murgu, H. Colt, Pseudomembranous aspergillus tracheobronchitis superimposed on post-tuberculosis tracheal stenosis, Respirology 14 (1) (2009) 144–147.
- [11] H.D. Huang, Q. Li, Y. Huang, C. Bai, N. Wu, Q. Wang, X.P. Yao, B. Chen, Pseudomembranous necrotizing tracheobronchial aspergillosis: an analysis of 16 cases, Chin. Med. J. 125 (7) (2012) 1236–1241.
- [12] N. Patel, A. Talwar, A. Stanek, M. Epstein, Tracheobronchial pseudomembrane secondary to Aspergillus, J. Bronchol. 13 (3) (2006) 147–150.
- [13] X. Le, P. Jain, S. O'Brien, Aspergillus pseudomembranous necrotizing tracheitis, Am. J. Hematol. 88 (3) (2013) 242.
- [14] E. Arguder, A. Senturk, H.C. Hasanoglu, I. Hasanoglu, A. Kanbay, H.T. Dogan, Unique case of pseudomembranous Aspergillus tracheobronchitis: tracheal perforation and Horner's syndrome, Mycopathologia 181 (11–12) (2016) 885–889.
- [15] A. Ramos, J. Segovia, M. Gomez-Bueno, C. Salas, M.T. Lazaro, I. Sanchez, L. Pulpon, Pseudomembranous Aspergillus tracheobronchitis in a heart transplant recipient, Transpl. Infect. Dis. Off. J. Transplant. Soc. 12 (1) (2010) 60–63.
- [16] M. Shah, P. Singhal, Rare case: invasive pseudomembranous Aspergillus tracheobronchitis in a postpartum patient presenting with stridor, J. Bronchol. Intervent. Pulmonol. 22 (3) (2015) 248–250.
- [17] M. Fernandez-Ruiz, J.T. Silva, R. San-Juan, B. de Dios, R. Garcia-Lujan, F. Lopez-Medrano, M. Lizasoain, J.M. Aguado, Aspergillus tracheobronchitis: report of 8 cases and review of the literature, Medicine 91 (5) (2012) 261–273.
- [18] L.P. Koh, Y.T. Goh, Y.C. Linn, J. Hwang, P. Tan, Pseudomembranous tracheobronchitis caused by Aspergillus in a patient after peripheral blood stem cell transplantation, Ann. Acad. Med. Singap. 29 (4) (2000) 531–533.