

2018

# Common Sports Related Injuries with a Focus on the Ankle and Knee Joints

Felipe Inostroza Millas

Long Island University, Felipe.InostrozaMillas@my.liu.edu

Follow this and additional works at: [https://digitalcommons.liu.edu/post\\_honors\\_theses](https://digitalcommons.liu.edu/post_honors_theses)

---

## Recommended Citation

Inostroza Millas, Felipe, "Common Sports Related Injuries with a Focus on the Ankle and Knee Joints" (2018). *Undergraduate Honors College Theses 2016-*. 34.

[https://digitalcommons.liu.edu/post\\_honors\\_theses/34](https://digitalcommons.liu.edu/post_honors_theses/34)

This Thesis is brought to you for free and open access by the LIU Post at Digital Commons @ LIU. It has been accepted for inclusion in Undergraduate Honors College Theses 2016- by an authorized administrator of Digital Commons @ LIU. For more information, please contact [natalia.tomlin@liu.edu](mailto:natalia.tomlin@liu.edu).

Common Sports Related Injuries with a Focus on the Ankle and Knee Joints

An Honors Program Thesis

by

Felipe Inostroza Millas

Spring, 2018

Health Sciences

Alan I. Hecht, D.C.

Faculty advisor

Stacy Gropack, Ph.D., P.T.

Reader

May 2<sup>nd</sup> 2018

## Abstract

Injuries can counter the beneficial aspect of sports due to residual effects of injury. This can cause an athlete to stop participating in the sport. A literature search was conducted on peer-reviewed journals of many databases to search for common sports related injuries in the ankle and knee joints. The joints focused on have been written in separate chapters to not confuse the reader of the location of the injury. Each injury has been given its own section to provide as much information as possible. The anatomy of each body region is also explained and pictures have been included to give the reader a visual representation of where the injuries occur. Through this literature based research, the most common sports related injuries have been found with respect to the ankle and the knee.

**Table of Contents**

<b>Chapter II: Basic Information</b> .....	<b>1</b>
<b>What is a Sprain?</b> .....	<b>1</b>
<b>What is a Strain?</b> .....	<b>2</b>
<b>What are Fractures?</b> .....	<b>3</b>
<b>What are Ruptures?</b> .....	<b>4</b>
<b>What is Tendonitis?</b> .....	<b>5</b>
<b>Chapter III: Ankle Injuries</b> .....	<b>6</b>
<b>Anatomy of the Ankle and Foot</b> .....	<b>6</b>
<b>Ankle Sprain</b> .....	<b>17</b>
<b>Strain Around the Ankle</b> .....	<b>22</b>
<b>Ankle Fracture</b> .....	<b>25</b>
<b>Ankle Rupture</b> .....	<b>27</b>
<b>Ankle Tendonitis</b> .....	<b>29</b>
<b>Chapter IV: Knee Injuries</b> .....	<b>31</b>
<b>Anatomy of the Knee</b> .....	<b>31</b>
<b>Knee Sprain</b> .....	<b>39</b>
<b>Strain Around the Knee</b> .....	<b>43</b>
<b>Knee Fracture</b> .....	<b>45</b>
<b>Knee Rupture</b> .....	<b>47</b>
<b>Knee Tendonitis</b> .....	<b>50</b>
<b>Chapter V: Conclusion</b> .....	<b>52</b>
<b>References</b> .....	<b>53</b>

## **Chapter I: Introduction**

Injuries are inevitable when participating in any kind of physical activity. Athletes experience different injuries ranging from mild sprains to complete rupture of a ligament and even a fracture of a bone. The injuries documented all occurred in sports that require the use of the lower leg. The frequency of these injuries increases as the intensity of the sport increases. Therefore, college athletes are more vulnerable to sports injuries than a child that is first being introduced to the sport. Since there are hundreds of injuries that can occur to an athlete, for the purpose of the paper, the injuries have been narrowed down to the ankle and the knee and their surrounding anatomical structures. The paper will discuss common injuries to the knee and ankle, the anatomy of the joints and surrounding structures, as well as the possible treatment options that are necessary for each injury.

## **Chapter II: Basic Information**

There are many injuries that occur in athletes. This paper will consist of five common injuries that may occur while playing a sport. The five injuries are sprains, strains, fractures, ruptures, and tendonitis. This chapter will explore specific injuries and their location, and the basics of each injury that will be specified.

### **What is a Sprain?**

A sprain is an injury to a ligament in any joint of the body. The main purpose of a ligament is to provide stability and limit the movement within a joint. There are hundreds of joints in the human body so a sprain can occur in many places. Ligaments are made up of tough fibrous connective tissue. These tough bands are not high in elasticity, which

## Common Sports Related Injuries with a Focus on the Ankle and Knee Joints

causes them to overstretch due to trauma resulting in a sprain. Ligamentous injuries may take many weeks to heal because ligaments do not have a good blood supply. Sprains are common because they can happen in many different ways. For example, a person might experience a sprain while walking down stairs or stepping onto or off of the sidewalk. These kinds of sprains will most likely not be serious and will heal within days or maybe a couple of weeks. In athletes, sprains may occur when a basketball player is landing from a dunk or jump shot, when a soccer player is slide tackled, or when a football player is trying to pivot quickly away from the defending players. These sprains result in more serious injuries with longer recovery periods. Sprains have been categorized into different grades ranging from 1 to 3. A grade 1 sprain is a mild sprain, which includes minimal functional loss. A grade 2 sprain is a moderate sprain, which causes moderate functional loss, pain and swelling. A grade 3 sprain is a severe injury most likely resulting from a tear in the ligament (Polzer et al., 2012).

### **What is a Strain?**

A strain is often confused with a sprain. Often these terms are used interchangeable, but they are very different. A strain is an injury that involves a muscle or a tendon that connects to a bone versus a sprain, which is an insult to a ligament. Since the human body is made of hundreds of muscles and tendons, a sprain can really occur anywhere in the body. A strain is more likely to be observed in sports that involve sprinting and jumping. Soccer, football, and basketball players are most likely to experience a strain sometime in their athletic careers. From this, we can predict that a majority of strains occur in the muscles of the leg, more specifically the hamstring and quadriceps muscle. A strain is one of the most common injuries seen in a physician's

## Common Sports Related Injuries with a Focus on the Ankle and Knee Joints

office. There are different ways that a strain injury can occur. It can occur by the contraction of the muscle, a result of excessive stretch or stretch while the muscle is activated. In more serious situations, a muscle can tear and this is most common near the muscle-tendon junction. After a muscle tear, the muscle becomes weakened and is more vulnerable to experience recurrent injuries (Garrett, 1996). In fact, despite thorough testing and clinical evaluations before returning to play, these injuries often reoccur, giving the impression that the healthcare provider did not do his or her job correctly by allowing the athlete to return to the sport too early (Orchard et al., 2002).

### **What are Fractures?**

The adult human body contains 206 bones. Bones are rigid, calcified structures that make up the skeleton and serves many functions. They serve as levers for muscles, protect certain vital organs, contain marrow, which is essential for the creation of blood cells, and store calcium. Just like many other structures of the body, if enough pressure is applied, one can injure a bone. Direct contact such as a slide tackle or a full body tackle in soccer or football may increase the risk of a bone injury and even cause a break. A break along the surface of the bone is called a fracture. There are many different types of fractures that can occur to bones but to simplify things only two types will be mentioned; complete fractures and stress fractures (Mirkin & Hoffman, 1998).

A complete fracture is a serious injury where the bone is severed completely and the ends of the bones become separated. This is the most painful of all athletic injuries. The jagged edges caused by the break come in contact with nerves and other tissues, which can cause extreme pain. In extreme cases, the broken bone can protrude through the skin, leaving a portal of entry for bacteria. The pain and swelling caused by complete

## Common Sports Related Injuries with a Focus on the Ankle and Knee Joints

injuries can last for weeks therefore those suffering from this kind of injury will most likely be prescribed pain medications. Complete fractures of small bones of the hands and feet heal by themselves and usually do not need specific medical treatments. Fractures of long bones such as the ulna, radius, tibia, and fibula will need immediate medical attention for the best treatment and path to recovery. They usually take one to several months to heal depending upon the severity of the injury and the treatment (Mirkin & Hoffman, 1978).

Stress fractures are thin cracks on the surface of bones, most commonly found on the bones of the hands, feet, and legs. Stress fractures are common injuries found in sports that involve running. According to Milner et al., (2006) “They are consistently among the five most common running injuries and account for 50% of all injuries sustained by runners.” The overall incidence of this kind of bone injury can range anywhere from 1.5% to 31%. The tibia is the most common site for stress fractures, accounting for 33 to 55% of stress fractures.

### **What are Ruptures?**

Ruptures are one of the more serious injuries that can happen to an athlete. A rupture is another word for a tear and can occur in almost any part of the body. This includes muscles, ligaments, and tendons. These are the tissues of the body that are ruptured most often in sports. According to Resch & Breitfuss, (1995) in some sports, ruptures are not spontaneous (recurrent microtrauma resulting from continuous loading in a critical zone) or degeneration induced (due to weakening of the tendon), but may occur as a result of powerful forces that are involved in the activity. The location of injury varies with each sport. For example, in soccer, football, and basketball there will be more



## Common Sports Related Injuries with a Focus on the Ankle and Knee Joints

ruptures in the lower extremity while in sports like baseball or throwing events like javelin or shot-put, the athlete will experience more ruptures in the shoulder. These injuries can be very disabling and will not allow an athlete to return to sports or their normal daily routine for weeks or even months.

Athletes will come across most of these injuries, if not all, throughout their participation in sports. Although many of these injuries can occur anywhere in the body, we will focus on two major body parts; the knee and the ankle. The lower extremities are one of the most important body parts when playing a sport, thus, many sports related injuries occur in the legs.

### **What is Tendonitis?**

Tendons are very important structures of the body because they are responsible for transferring mechanical force from muscles to bones. This allows us to move our limbs and also provides joint stability. This is only possible because of the complex macrostructure and microstructure of tendons. Collagen fibrils make up collagen fibers, which are the basic units of tendons. These structures are produced by fibroblasts that reside between the collagen fibers and are arranged in a systematic way that forms the tendon properly. When the body is performing different kinds of movements, the tendons are exposed to different kinds of forces such as rotational, longitudinal, and transverse forces (Kannus, 2000).

Tendons are reliant on muscles for contractions. This means that without muscles attaching to tendons, there would be no movement of a body part. Tendons cannot contract on their own and when a muscle contracts, it pulls on the tendon to create

movement. For example, when the calf muscle of the lower leg contracts, it pulls on the Achilles tendon, which is attached to the calcaneus, causing the heel to rise and forcing the front part of the foot down. Muscles have a wider cross sectional area than tendons, which can cause tendons to become injured more easily if there is a strong force acting on it. As a result, the excessive pulling on tendons by muscles can cause a well-known injury called tendonitis. Tendonitis is an inflammation of the tendon causing the injured site to swell. According to Dr. Don O'Donoghue, "Tendinitis is one of the worst recurring problems in sports medicine. Because the pain decreases with exercise, the athlete won't stop exercising. He goes right back to performing the same thing that caused the problem in the first place" (Mirkin & Hoffman, 1998). Each sport has its most common site for a tendon injury. For example, the Achilles tendon is injured most often in soccer, basketball, football, and track.

### **Chapter III: Ankle Injuries**

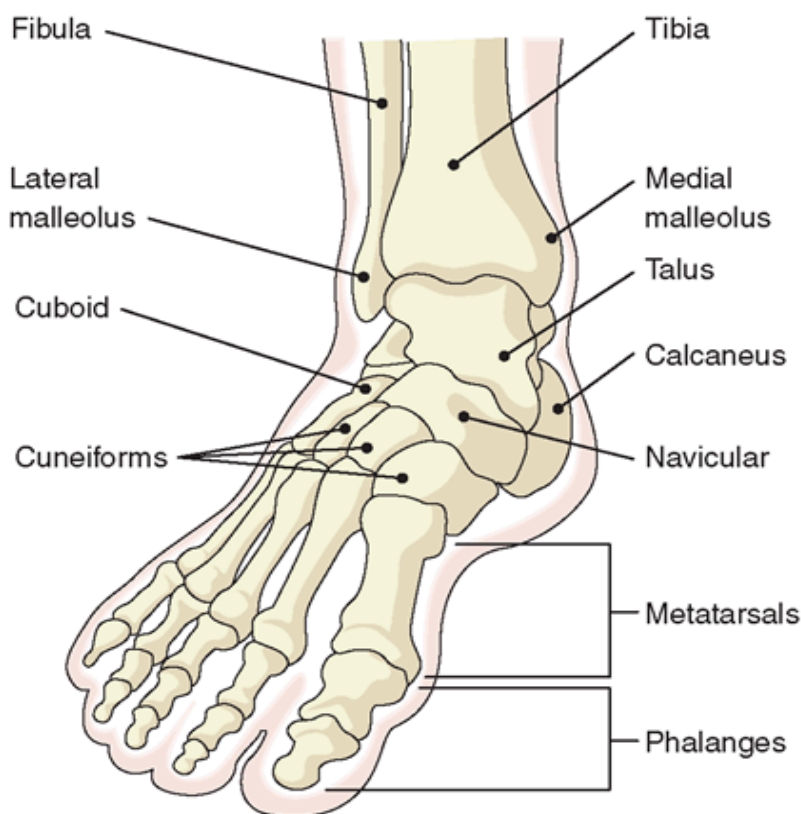
#### **Anatomy of the Ankle and Foot**

In order to understand the different types of injuries that occur on the ankle, we first must understand the anatomy. The ankle is a very complex area of the body that is formed by many different bones, ligaments and tendons. Since bones provide structural support for the entire body and a framework for attachment of many tissues, we will begin by discussing the bony anatomy of the ankle joint.

The distal end of the tibia and fibula of the lower leg is where the ankle begins. The malleoli can be found on both the medial side and lateral sides of the ankle. They are the bony projections that are visible on either side of the ankle. The medial malleolus is

## Common Sports Related Injuries with a Focus on the Ankle and Knee Joints

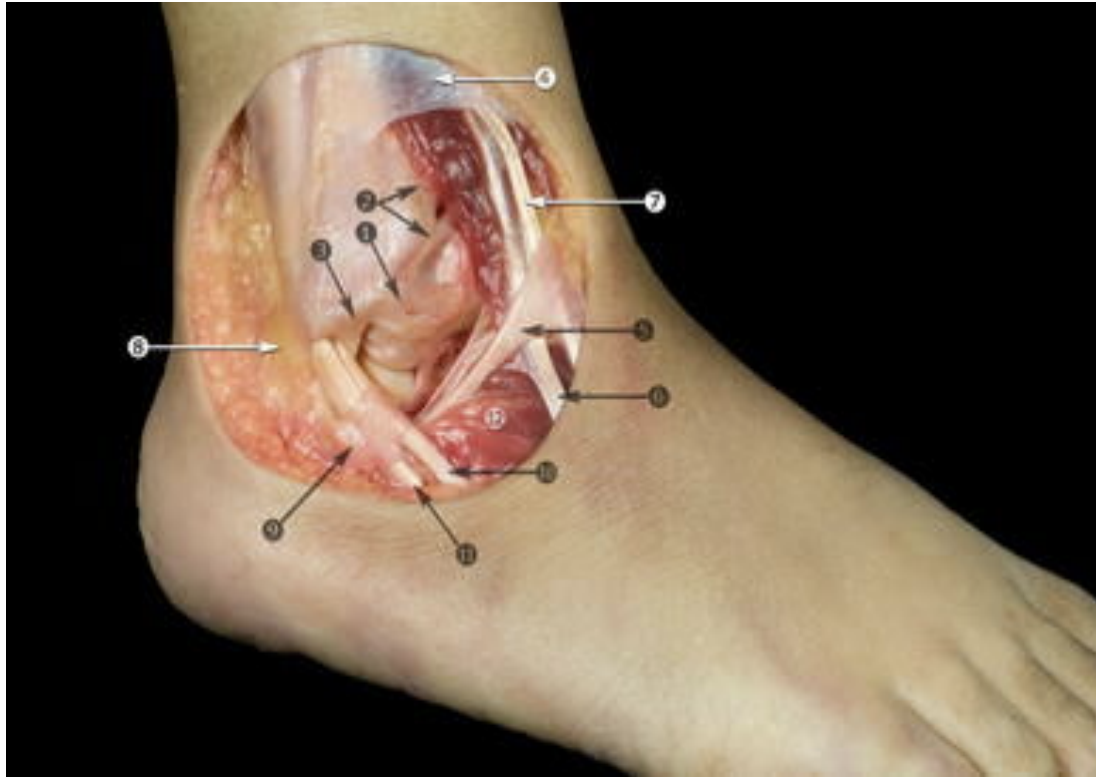
formed by the anterior and posterior colliculus. Each colliculus has an attachment point for a ligament in the ankle joint. The talus bone is found lodged between the distal tibia and fibula. The talus is wider on its anterior surface than its posterior by about 4.2 millimeters. The lateral process of the talus forms an articular surface with the distal fibula. The talar neck slopes medially away from the talar body and which allows articulation of the talar head with the navicular, one of the tarsal bones. The calcaneus is the largest bone in the foot and is more commonly known as the heel bone (Altchek, 2013). Many of the bones mentioned can be seen in figure 1.



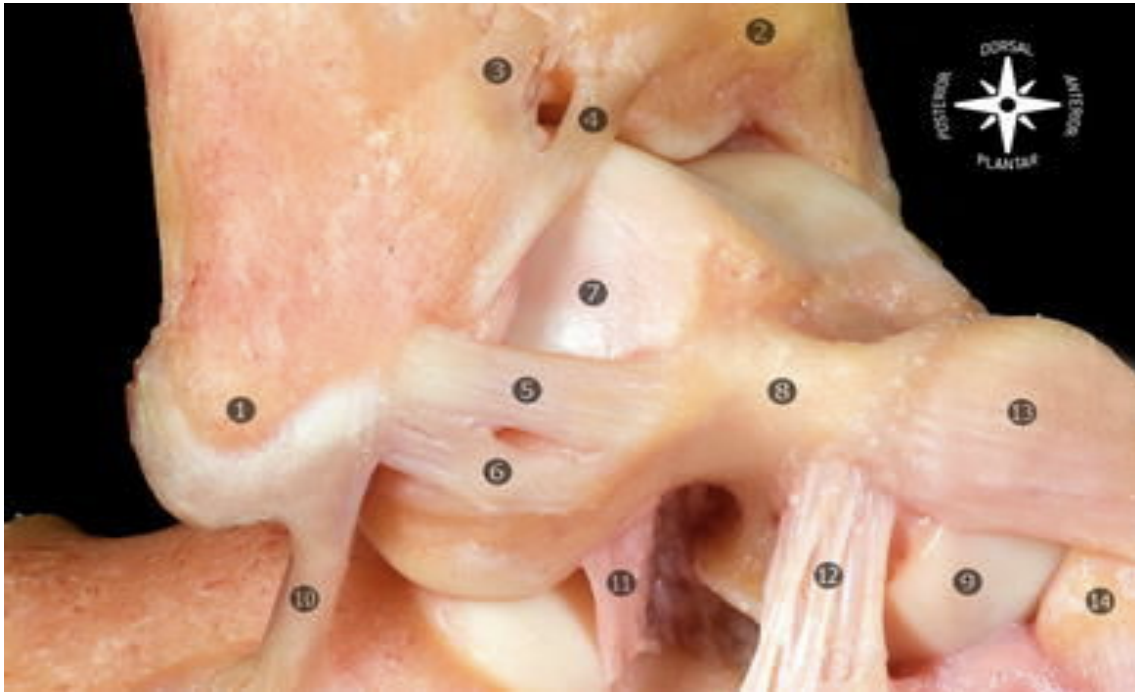
**Figure 1: Bones of the ankle and surrounding structures. Retrieved from <https://www.pinterest.com/pin/335518240975415565/>.**

## Common Sports Related Injuries with a Focus on the Ankle and Knee Joints

The ankle joint is surrounded by the lateral collateral ligaments and medial collateral ligaments just like the knee joint. The lateral collateral ligament complex is made up of the anterior talofibular ligament, the calcaneofibular ligament, and the posterior talofibular ligament. The anterior talofibular ligament plays an important role in limiting anterior misalignment of the talus and plantar flexion of the ankle. This ligament originates at the anterior margin of the lateral malleolus. From here, the ligament runs diagonally onto the talar body. The anterior talofibular ligament is horizontal to the ankle when the ankle is in its neutral position. The ligament slopes upward during dorsiflexion, toes pointing upward, and slopes downward during plantar flexion, toes pointing downward. In plantar flexion, the inferior band of the ligament stays relaxed while the superior band gets tight. Inversely, in dorsiflexion, the upper band stays relaxed and the inferior band becomes taut (Golanó, 2010). Bones and ligaments of the ankle joint can be seen in figure 2 and figure 3.



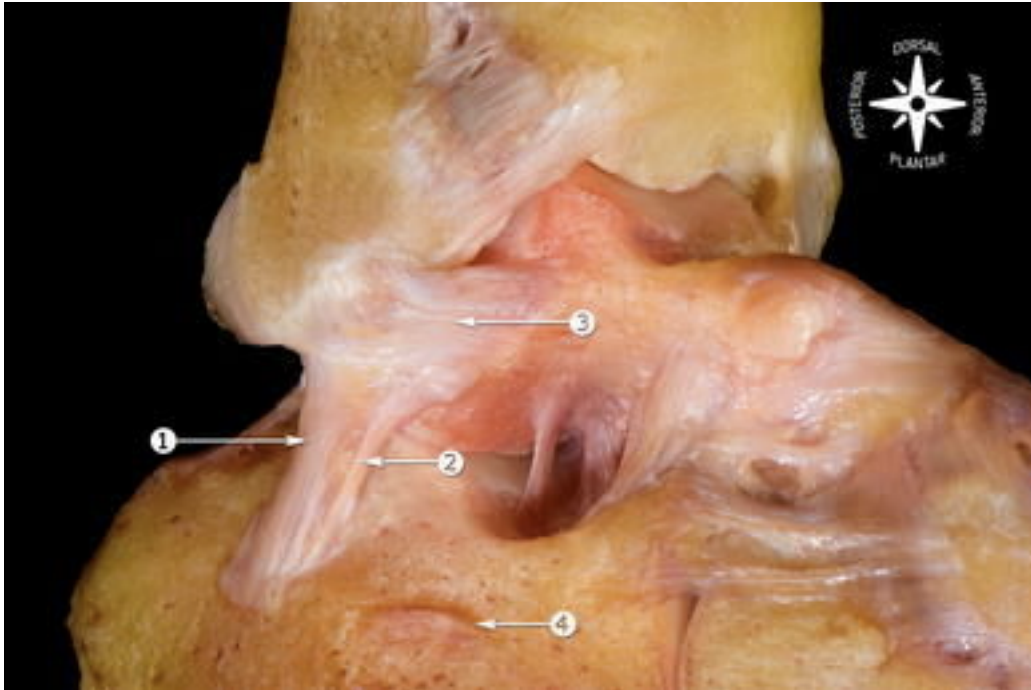
**Figure 2: Number 1 is the anterior talofibular ligament running horizontally (Golanó, 2010).**



**Figure 3: This is a close-up of the previous picture. Number 5 is the superior band of the talofibular ligament. Number 6 is the inferior band of the talofibular ligament (Golanó, 2010).**

The calcaneofibular ligament originates from the anterior surface of the lateral malleolus. This ligament is about 20 millimeters in length and has a diameter of about 7 millimeters. It is positioned just below the anterior talofibular ligament. It runs diagonally downwards and attaches to the posterior side of the lateral calcaneal surface. The calcaneofibular ligament is the only ligament that spans over both the talocrural joint and the subtalar joint. The significance of this ligament is that it allows flexion and extension of the talocrural joint, which is more commonly known as the ankle joint. During ankle extension, the calcaneofibular ligament becomes horizontal and during flexion it becomes vertical. In a varus position, the ligament is tense and is relaxed in a valgus position. A varus position is when the ankle has an inward angulation and a valgus

position is an outward angulation of the ankle. These positions have an impact on the angle formed by the ligament and the longitudinal axis of the fibula (Golanó, 2010). The calcaneofibular ligament can be seen in figure 4.

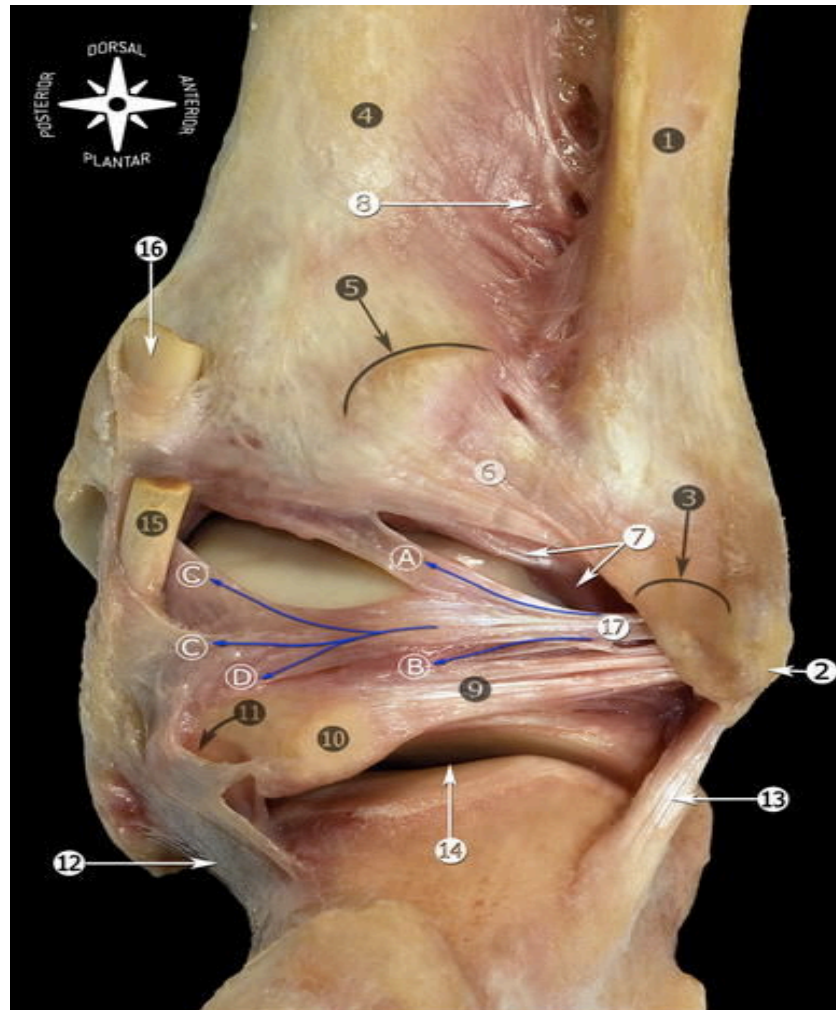


**Figure 4: Number 1 is the calcaneofibular ligament (Golanó, 2010).**

The posterior talofibular ligament can be found on the posterior region of the ankle and it originates from the malleolar fossa, or depression, and it runs horizontally to a tubercle on the posterior surface of the talus. The ligament is relaxed in plantar flexion and in the neutral ankle position. Plantar flexion is a movement in which the foot points downward such as when standing on your toes. The posterior talofibular ligament is tightened in dorsiflexion. Dorsiflexion is the opposite of plantar flexion in which the foot points upwards. A group of fibers from the posterior talofibular ligament fuse with the posterior intermalleolar ligament. The posterior intermalleolar ligament can be found between the transverse ligament and the posterior talofibular ligament and runs

## Common Sports Related Injuries with a Focus on the Ankle and Knee Joints

diagonally from lateral to medial. The shape of this ligament varies on the number of fiber bundles and how compact those bundles are. It relaxes during plantar flexion and tightens up during dorsiflexion (Golanó, 2010). The posterior aspect of the ankle joint and the posterior talofibular ligament can be seen in figure 5.

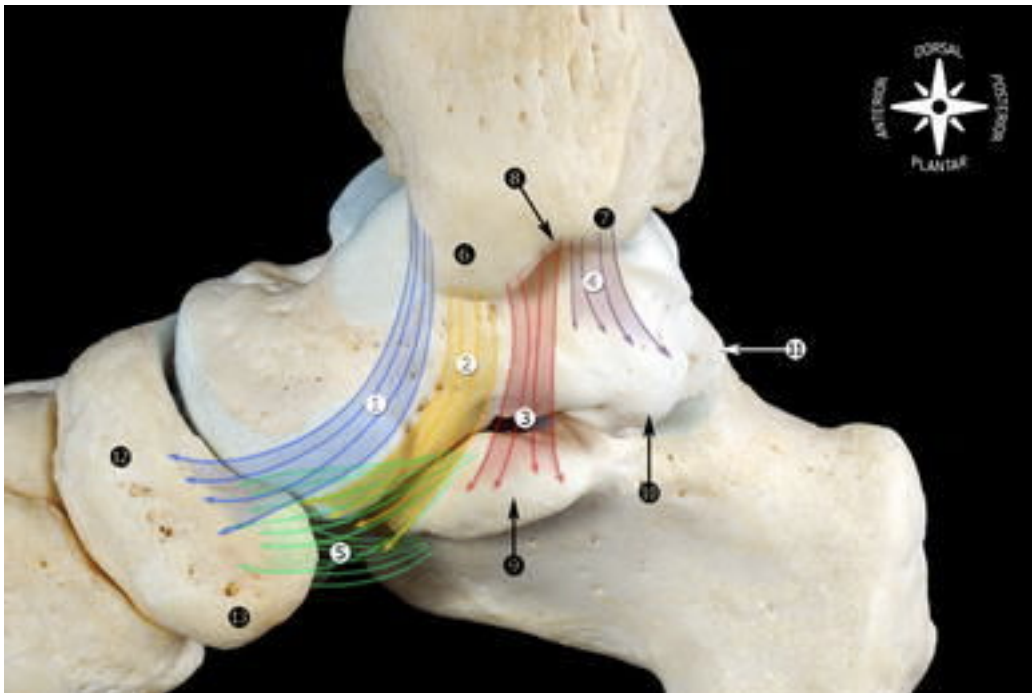


**Figure 5: Number 9 is the posterior talofibular ligament (Golanó, 2010).**

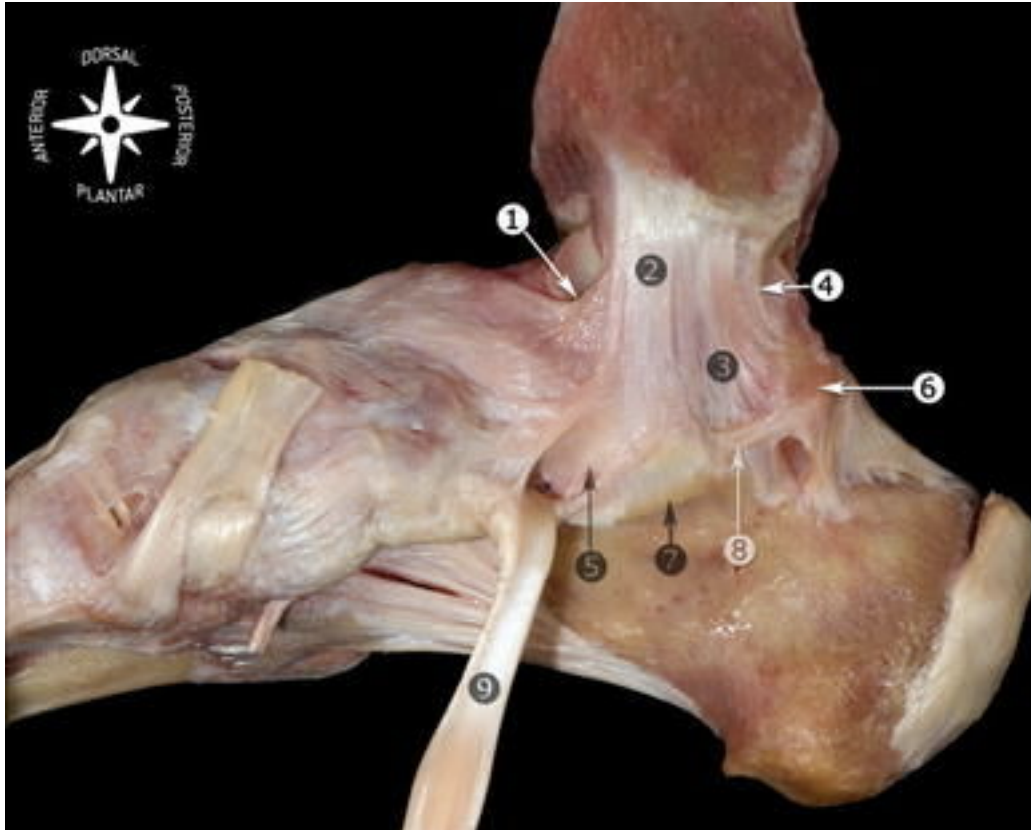
The medial collateral ligament of the ankle is described in different ways but the most general anatomical description is that it is composed of a superficial layer and a deep layer. It originates from the medial malleolus and links with the calcaneus, talus, and navicular bone. According to Milnder and Soames, the most commonly accepted



description of the medial collateral ligament is that it has six bands. The tibiospring ligament, tibionavicular ligament, and the deep posterior tibiotalar ligament are three out of the six that are always present. The other three that include the superficial posterior tibiotalar ligament, tibiocalcaneal ligament and the deep anterior tibiotalar ligament may not always be present in the ankle (Golanó, 2010). The medial collateral ligaments can be seen in figure 6 and figure 7.

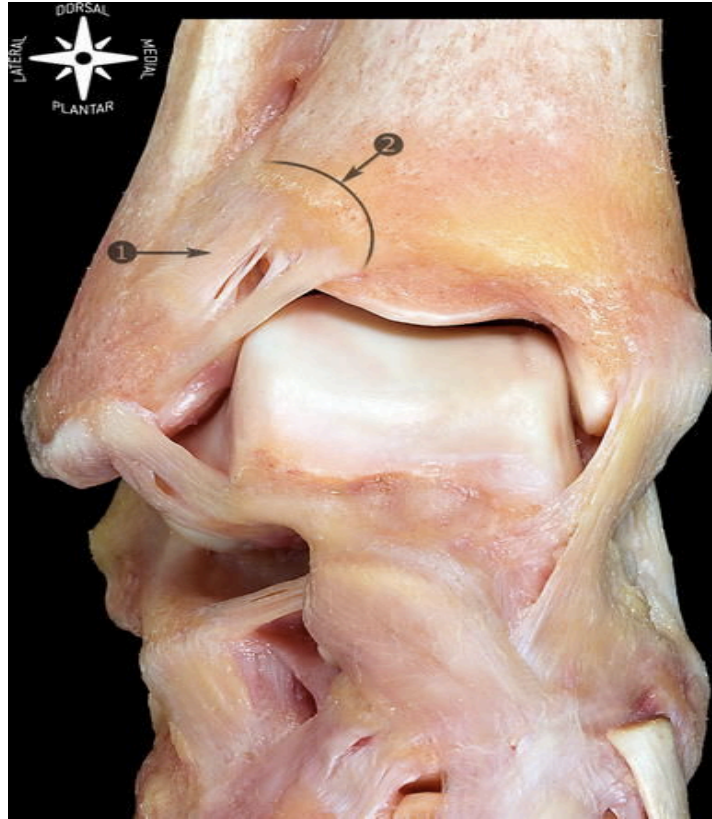


**Figure 6: This is a schematic representation of where the medial collateral ligaments are located. Numbers 1-5 (Golanó, 2010).**

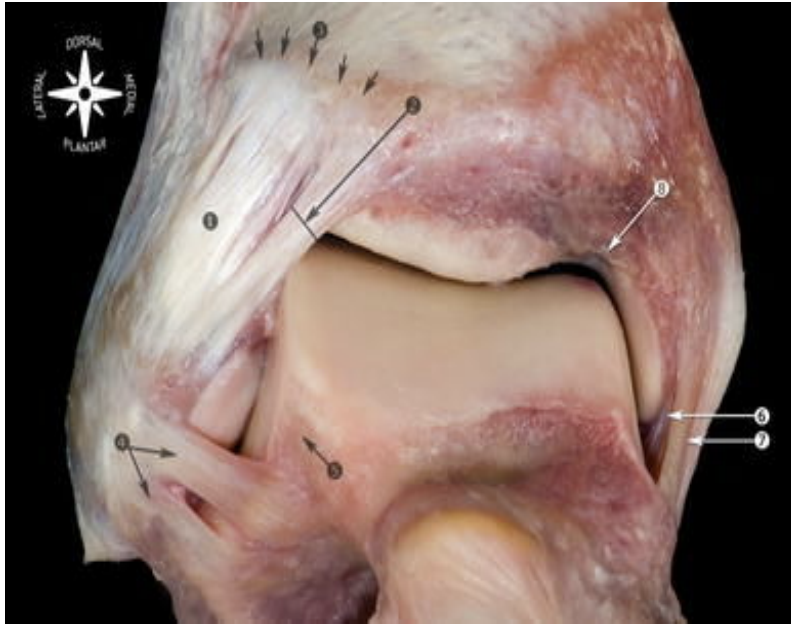


**Figure 7: This is a medial view of the main components of the medial collateral ligaments (Golanó, 2010).**

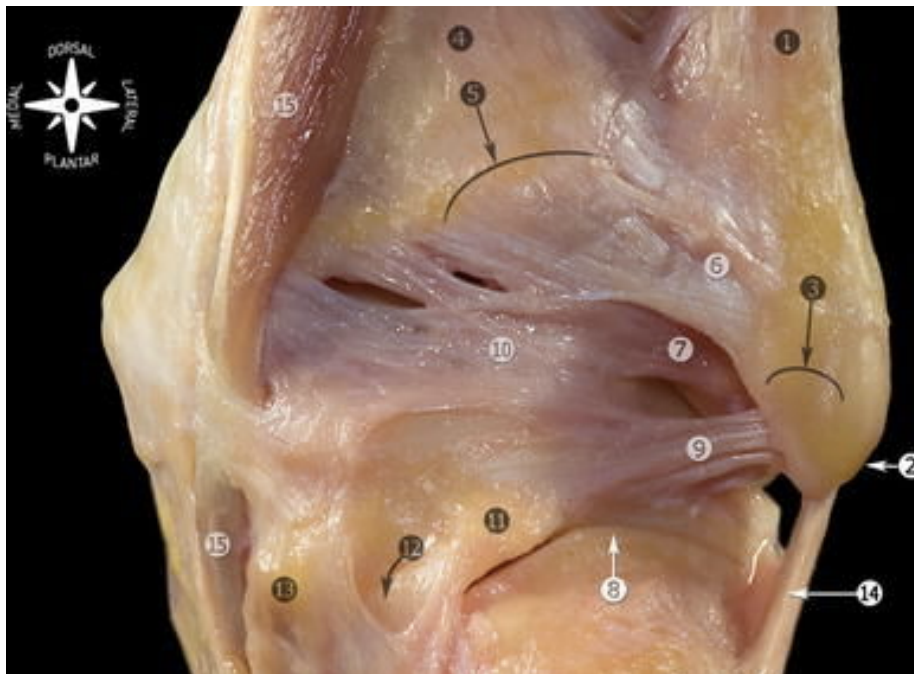
The talocrural joint is a syndesmotomic joint (fibrous joint between two bones linked by ligaments) that allows the tibia and fibula to act as one to prevent separation from one another. The main role of the ligaments within this joint is to stabilize the distal tibia and the fibula and also resist the rotational forces that try to separate the two bones apart. The anterior tibiofibular ligament, the posterior tibiofibular ligament and the interosseous tibiofibular ligament are the three ligaments that ensure stability between the tibia and the fibula (Golanó, 2010). The anterior tibiofibular ligament can be seen in figure 8 and 9. The posterior tibiofibular ligament can be seen in figure 10.



**Figure 8: Number 1 is the anterior tibiofibular ligament. It connects the fibula and the tibia from left to right (Golanó, 2010).**



**Figure 9:** This is a close up of the ankle joint. The white tissue on the left side of the image labeled as 1 is the anterior tibiofibular ligament (Golanó, 2010).



**Figure 10:** Number 7 is the posterior tibiofibular ligament. This is a posterior view of the ankle (Golanó, 2010).

### **Ankle Sprain**

A study performed by the Orthopaedic Research Society states that an ankle ligament injury is the most common injury in recreational and athletic activity. The purpose of their study was to determine the risk factors that are associated with ankle sprains. Over two million individuals are diagnosed with ankle sprains each year in the United States but little is known about the factors that leave these individuals vulnerable to this specific injury. The cost of treating this injury has totaled about two billion dollars per year. A way of reducing this number and the number of ankle ligament sprains is to learn about the environmental factors that may have an impact on the athlete and individual characteristics including body weight and height. When height and weight were expressed as a mass moment of inertia, there was a correlation with ankle sprains. Anatomic alignment of the foot and ankle, postural sway, and muscle reaction time were some of the factors that were evaluated in the study (Beynnon et al., 2001).

In this study, 118 Division 1 college athletes participated, 50 males and 68 females. The number of ankle injuries per 1000 days of exposure to the activity was 1.6 for men and 2.2 for women. Thirteen percent of the men experienced an ankle injury and nineteen percent of the women experienced an ankle injury. Women who played soccer had an increased risk of an ankle injury compared to those of other field sports like lacrosse or field hockey. Ten of the thirteen injuries in women occurred in the right leg while three of the seven injuries in men occurred in the right leg. The dominant leg of each athlete was not taken into consideration but that may have an influence on which leg was injured. Most of the injuries occurred during practice and not during a game. Every athlete was exposed to the same conditions. This means that every participant played on

## Common Sports Related Injuries with a Focus on the Ankle and Knee Joints

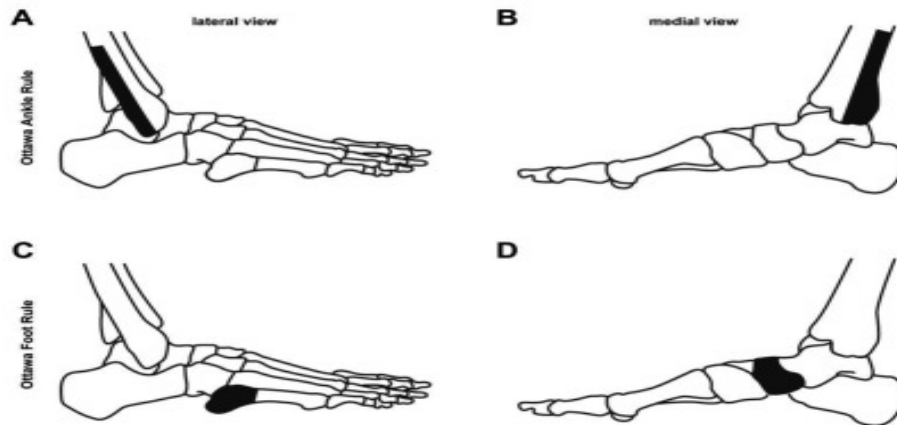
the same turf field at the same time. The athletes were monitored throughout the season and their progress was documented. If an athlete sustained an ankle injury, he or she was immediately seen by an orthopaedic surgeon to determine if the injury was a sprain. If the injury was diagnosed as an ankle sprain, it was named as a grade I, II, or III. A grade I ankle sprain was described as no loss of function, no loss of ligamentous stability, and little or no hemorrhage. A grade II ankle sprain was described as showing some loss of function, a decrease in motion, a positive anterior drawer test and negative talar tilt test, swelling and point tenderness. The ankle drawer test is used to assess instability of the ankle. The talar tilt test is used to test for injury to the lateral ligaments of the ankle. Grade III injuries demonstrated nearly total loss of function, positive anterior drawer test and a positive talar tilt test, swelling, and tenderness of the specific area (Beynon et al., 2001).

In their study, they concluded that individuals with an increased calcaneal eversion rotation and muscle strength imbalances had a higher prevalence of inversion ankle sprains. They found that among women, ankle injuries were related to increased calcaneal eversion range of motion. Their study demonstrated that the risk factors that predispose an athlete to ankle ligament injury are different between men and women. Women with increased tibial varum rotation and an increase calcaneal eversion range of motion sustained more injuries. Men with an increased talar tilt sustained the most injuries.

In order to determine if someone has a sprained ankle, doctors will usually take images of the bones and tissue to see what is going on under the skin. According to a study performed by the Munich University Hospital, a number of different

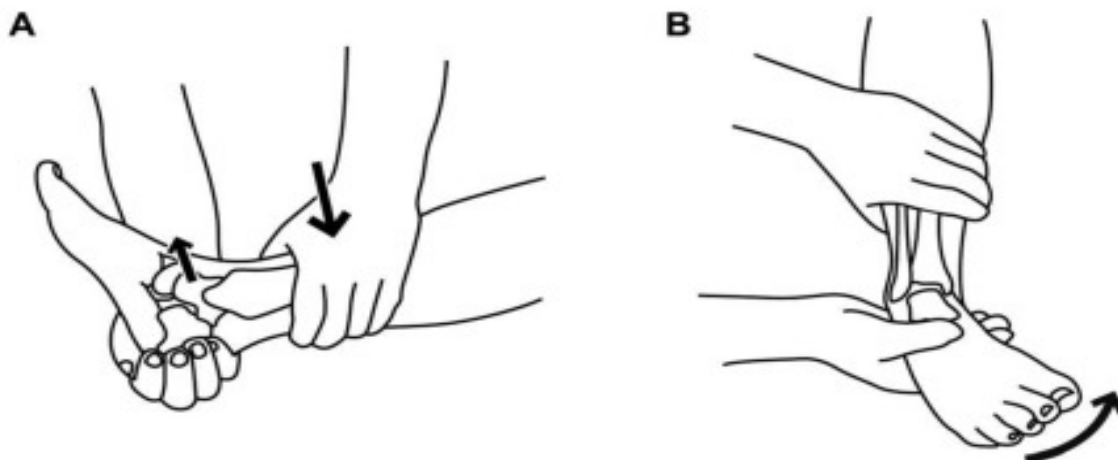
recommendations have been made in order to develop an algorithm for the diagnosis and treatment of ankle sprains. This includes the Ottawa Ankle and Foot Rule to rule out fractures. Physical examination is sufficient for diagnosing injuries to the lateral ligament complex. The squeezed, crossed legged and external rotation tests are indicative for injuries of the ankle syndesmosis. Magnetic resonance imaging is recommended to verify injuries of the syndesmosis. Early functional treatment leads to the fastest recovery and the least rate of reinjury, and supervised rehabilitation reduces reinjuries. Through these recommendations and with evidence to support them, they have formed a pathway for the diagnosis and treatment of acute ankle injuries (Polzer et al., 2012).

In order for a patient to have an extended physical examination, fractures must be excluded. The Ottawa Ankle Rule (OAR) and Ottawa Foot Rule (OFR) were developed in order to avoid unnecessary X-rays. An X-ray of the ankle should be taken if there is pain in the following areas: Bone tenderness along the distal posterior edge of the tibia or tip of the lateral malleolus, pain along the distal posterior edge of the fibula or tip of lateral malleolus with inability to bear weight. After a fracture has been ruled out, a precise physical examination should be performed to look for swelling, deformity and bruising, as they are signs of acute injury (Polzer et al., 2012).



**Figure 11: Ottawa foot and ankle rule. The shaded regions are the areas examined for bone tenderness (Polzer, 2012).**

The anterior drawer test is used to assess the integrity of the anterior talofibular ligament (ATFL). The talar test can also be used for the examination of the anterior talofibular ligament and also the calcaneofibular ligament. If there is pain while performing these tests then the patient should be treated with protection, rest, ice, compression, and elevation (PRICE) and a physical examination should be performed again after three to five days (Polzer et al., 2012).



**Figure 12: (A) Represents the anterior drawer test for the anterior talofibular ligament. (B) Represents the talar tilt test for the anterior talofibular ligament and calcaneofibular ligament (Polzer, 2012)**



## Common Sports Related Injuries with a Focus on the Ankle and Knee Joints

Since injury to the lateral ligament complex is very common, the method of treatment for such an injury is very important to know. Treatment options differ between sprains depending on the severity of the injury. For stable injuries, or grade I, the lateral complex recovers quickly with non-surgical management and have an excellent prognosis. They are usually just treated with elastic bandages and protection, rest, ice, compression, and elevation (PRICE). Treatment for unstable injuries like grades II and III are very different. The three treatment options are surgery, immobilization, and functional treatment. The main goal of treatment is to prevent reoccurring symptoms and to provide the fastest recovery without harming the patient (Polzer et al., 2012).

There are debates as to whether or not surgery is better than conservative treatment. According to Kerhoffs, surgery seemed better for objective stability, there were no differences in subject instability, range of motion was reduced compared with conservative treatment, and no significant differences were observable. Most of the trials reported a shorter time in return to normal activity after receiving conservative treatment. Kannus also reported a shorter time in return to sport and work, and a better range of motion in early follow up for conservative treatment. Almost all of complications in their systematic review occurred in patients that had gone through surgery. The recommendation is that conservative treatment should be favored over surgery due to comparable results with fewer complications after conservative treatment and significantly lower costs. Surgery should be reserved for patients with persistent symptoms (Polzer et al., 2012).

According to Polzer et al., (2012) another study was done comparing functional treatment with immobilization. These are the two approaches to conservative treatment:

## Common Sports Related Injuries with a Focus on the Ankle and Knee Joints

Immobilization is usually achieved by using a cast and functional treatment is performed with a short protection using tape, a bandage, or a brace, and exercises of the ankle.

Kerkhoff published a study of 21 trials that compared functional treatment and immobilization. They found no results concerning outcome in favor of immobilization. However, seven measurements of outcomes produced significantly better results in favor of functional treatment. These measurements included: time to return to sport and work, patient satisfaction, objective instability, persistent swelling, and amount of patients returning to sports and work. Through these measurements they believe that immobilization should not be the choice of treatment for ankle sprains.

Other treatments that can be used to aid with the recovery of an ankle sprain include cryotherapy and certain drug treatments. Cryotherapy is the use of low temperatures to reduce swelling and pain from injured soft tissue. In a study, cryotherapy seemed to be the main type of therapy that helped the most to treat swelling caused by an ankle sprain (Coté, Prentice, Hooker, & Shields, 1988). Non-steroidal anti-inflammatory drugs (NSAIDS) were shown to decrease the recovery time as well as significantly lowering the pain caused by ankle sprains. Laser therapy, ultrasound, and electrotherapy were not effective with treating acute ankle injuries. These three treatments should not be considered as part of the standard regime in treating acute ankle sprains (Ogilvie-Harris & Gilbert, 1995). These two treatments are widely known and many people rely on them when they do not have access to a medical facility.

### **Strain Around the Ankle**

Lower leg muscle strains are common injuries in sports though the mechanism of how they are caused is not very clear. It is thought that strains of the lower leg occur

## Common Sports Related Injuries with a Focus on the Ankle and Knee Joints

during eccentric contractions. An eccentric contraction is a type of muscle activation that increases tension on a muscle as it lengthens during exercise. Calf muscle strains are thought to occur during acceleration movements (Orchard et al., 2002). For ankle strain, we will focus more on the surrounding anatomical structures because those muscles are more likely to be injured.

The gastrocnemius is one of the muscles of the calf that is often injured the most. This muscle is considered to be at higher risk for strain injuries because it crosses two joints, the ankle and the knee. This muscle has type two fast twitch muscle fibers, which are useful for powerful movements such as sprinting. A combination of being between two complex joints and forceful contractions of type two muscle fibers is what causes a strain. Strains of the gastrocnemius have been called snap of the whip because the mechanism of injury looks as if someone is cracking a whip (Dixon, 2009).

Just like sprains, strains also have different grades of injury. All muscle strains are graded from one to three based on function, pathologic correlation, and symptoms. A grade one strain is considered a mild strain, which causes sharp pain at the time of injury or pain with activity. Mild swelling can develop but there is minimal or no loss of strength and range of motion of the athlete. This means that a grade one strain does not cause the athlete to lose many days of training or competing. When it comes to the muscle fibers, less than 10% of the fibers are damaged. A grade two strain is considered a moderate strain and athletes are usually not able to continue their activity from this injury. There is clear loss of strength and range of motion. There are roughly less than 50% of the muscle fibers damaged from this injury. A grade three strain is considered a severe injury, which causes severe pain and immediate disability. There is complete loss

## Common Sports Related Injuries with a Focus on the Ankle and Knee Joints

of function within the muscle because more than 50% of the muscle fibers are damaged. This strain would cause the longest loss of time from sports compared to the other strains (Dixon, 2009).

An accurate diagnosis is necessary in order to provide the appropriate treatment. It is encouraged to completely recover from the injury before returning to participating in sports. This means having full strength and flexibility. Returning to sports before completely recovering from the injury can lead to a prolonged recovery period. Treatment for acute strains is aimed at decreasing pain and other complications. Like other injuries, strains are treated with rest to limit muscle contraction and movement, cryotherapy, compression with tape, and elevation of the leg. These recommendations are known as RICE. After successful acute treatment, rehabilitative exercises can begin to strengthen the muscle and increase range of motion. This can be accomplished through passive stretching of the injured muscle. Strengthening of the muscle can also be accomplished through isometric exercises, which are exercises that involve the contraction of the muscle without lengthening or shortening the muscle. Other physical therapy modalities such as massages, ultrasound, and electric stimulation can be applied after the exercises are completed without pain. In the case of a grade three strain, surgery should be considered (Dixon, 2009). After surgery, the same protocol as mentioned above should be followed to allow for a smooth recovery.

Strains can have a huge impact on an athlete's way of living. Although a grade one strain does not impact the athlete in a great way, a grade two or three can leave someone completely debilitated. The good thing about a strain injury being so common is that there are more treatment options available since doctors often encounter this injury.

## Common Sports Related Injuries with a Focus on the Ankle and Knee Joints

Whether someone experiences a grade one or grade three strain, that person should seek treatment as soon as possible to allow the best recovery.

### **Ankle Fracture**

Ankle fractures are one of the most common musculoskeletal injuries worldwide. Although this injury can be debilitating, it is considered to be a lesser injury in comparison to other major fractures such as the hip or axial skeleton. Due to its high incidence, treatment for this injury has improved greatly and rehabilitation will bring the athlete back to competing. Long term effects of ankle fractures have been reported to include physical, psychological, and social consequences (McPhail, Dusten, Canning, & Haines, 2012). The following studies show the estimated rate of incidence as well as treatment and the process that the athlete undergoes in order to return to play.

A study was performed at the National Football League Combine to evaluate intercollegiate football players' injuries in relation to their position on the field. In 2006, a total of 320 college football players were examined for foot and ankle pathologies. It was reported that 72%, or 231 out of 320 college athletes had a history of ankle injuries. Most of the athletes experienced ankle sprains and 25 of the athletes had experienced a fibular fracture. Foot and ankle injuries were most common in punters with 100% of athletes experiencing an injury. Fibular fractures were highest in quarterbacks equaling 16% of all foot and ankle injuries (Kaplan et al., 2011).

Another study was performed in Belgium to record the incidence of lower leg fractures in soccer players. Soccer is the most popular sport in Belgium with more than 400,000 active players. This study was done over two seasons so 833,396 players were

## Common Sports Related Injuries with a Focus on the Ankle and Knee Joints

evaluated. A total of 56,364 injuries were reported and 1,600 of those injuries were fractures of the lower leg. Ankle fractures were the most common fracture of the lower leg impacting 583 athletes. Tibial fractures accounted for 22% and fibular fractures accounted for 9% of all fractures. Seventy five percent of all the fractures occurred in a competitive match (Vanlommel, 2013). In any sport, injuries usually occur during competitive matches because athletes are performing at their peak to win.

The last study that will be mentioned is a study of fractures among United States high school athletes. There were a total of 568 fractures reported, which represented 10.1% of all injuries sustained by high school athletes in the United States. Football was the sport that had the highest rate of fractures. Basketball was the second sport with the highest rate of ankle fractures and soccer was the third sport with the highest rate. Ankle fractures represented 9.3% of all of the fractures that were recorded. Most of the fractures resulted in more than three weeks' time lost from participating in the sport (Swenson et al., 2010).

There are different methods of treatment depending on the type of fracture an athlete might experience. For example, an avulsion fracture will most likely not require surgery because the injury heals well with just a cast. An avulsion fracture is defined as one where a small piece of bone attached to a ligament or tendon is pulled away from the surface of the bone. The cast is usually taken off within six to seven weeks and then an ankle brace is utilized (Haraguchi, Toga, Shiba, & Kato, 2007). Some serious fractures will require surgery and will also require the patient to wear a cast for six weeks. If there are no complications after six weeks, the cast will be removed and the patient will begin active exercises to restore functional movement and strengthen the area. These exercises

can include isometric contractions, toe raises, and rotational movements (Lehtonen et al., 2003). Ankle fractures can have a huge impact on an athlete's career and should be treated as soon as possible for the best outcomes.

### **Ankle Rupture**

An Achilles tendon rupture is a common sports-related injury that has been increasing in incidence. This tendon attaches to the gastrocnemius and soleus muscles as well as to the calcaneum to allow plantar flexion of the foot. The Achilles tendon is subject to great amounts of weight from the body, especially in intense sports that require constant running and jumping. Such forces can take a toll on the body, leaving the tendon susceptible to injuries.

The number of Achilles tendon ruptures has been estimated to be around 6 to 37/100,000 per year. The increase in recreational sports and exercise participation has led to more incidences of this injury (Scott, Grewal, & Guy, 2014). According to a case report by Ramelli, (2003) a 25 year-old male student arrived at a chiropractic clinic complaining of lower leg pain. His symptoms began after he collapsed while lunging for a ball. He characterized the immediate pain as sharp and stabbing and it was accompanied by a loud snapping sound. The patient rated the pain a seven out of ten and it was consistent for 24 hours. Any type of ankle movement such as walking up and down stairs only made the pain worse. During the examination, it was noted that dorsiflexion and planter flexion of the injured foot was limited due to pain. The patient did not have any trouble with eversion and inversion movements and they elicited no pain. A muscle strength test presented a weak plantar flexion with a rating of three out of five. The Achilles reflex test could not be performed due to extreme pain. The patient underwent

## Common Sports Related Injuries with a Focus on the Ankle and Knee Joints

surgery and the report indicated that the Achilles tendon had been completely torn, with the separation of the two ends of the tendon measuring eight to ten centimeters apart.

Treatment after the surgery was started with a below the knee cast, with the foot in 30 degrees plantar flexion to prevent the tendon from being pulled. At four weeks post-surgery, the cast was changed and the foot was elevated to 10-15 degrees of plantar flexion. This was done to allow adaptation of the tendon to its natural position. One week after the cast was changed, the foot was put in a natural position in another cast. At six weeks, a different cast was given to the patient in order to begin putting weight on the foot. After seven weeks, the cast was removed and the patient followed a seven to twelve week program that included the use of a 1cm heel lift. This was essential to help strengthen the tendon and bring back some motion of the foot. The patient underwent several other treatments including ultrasound therapy, soft tissue massage, and cryotherapy. Passive treatment was then begun in order to increase the range of motion of the foot. This active exercise program included muscle stretches, cardiovascular training, isometrics, and sensorimotor training. Cardiovascular training is an important part of rehabilitation because a higher level of fitness has been associated with faster healing at the cellular level. The late stage of rehabilitation consisted of running, squatting, and jumping to allow for a smooth transition to normal life activities. Full active weight bearing activities were only recommended after four to five months following rest and rehabilitation to avoid the risk of injuring the tendon again (Ramelli, 2003).

Conservative treatment and surgical treatment of an Achilles tendon injury is a topic that is still being debated by many professionals. Regardless of whether a person receives surgical or non-surgical treatments, the Achilles tendon is still susceptible to



## Common Sports Related Injuries with a Focus on the Ankle and Knee Joints

rupture again. Conservative treatment has been shown to have a faster return time to work than surgical treatment. There are always concerns that arise when undergoing surgery such as infection, wound breakdown, and injury to nerves. Irrespective of the treatment of choice, choosing a treatment as quickly as possible as well as diagnosing the injury as quickly as possible will result in the best outcome. If treatment was delayed for more than a week due to a late diagnosis, the results were much poorer (Ramelli, 2003).

An Achilles tendon rupture injury is a serious injury that can impact on an athlete's performance and way of life in a significant way. This study showed the different stages that an athlete experienced during his recovery from an Achilles tendon injury. As one can see, the rehabilitation process is broken down into stages in order to allow the tendon to heal quickly in the safest way possible. Conservative treatment and surgical treatment both have their pros and cons. For example, a surgical repair may lower the risk of rupturing the tendon again compared to conservative care but surgical care is definitely more expensive and is associated with more possible complications. Athletes will always have to face injuries, especially in physical sports like football and soccer, but there will always be treatments available to help bring the athlete back to his or her full potential.

### **Ankle Tendonitis**

An injury to the Achilles tendon is one of the most common injuries of the ankle. Insertional Achilles tendinopathy falls under the category of common ankle injuries from sports. This injury has been shown to impact 6-18% of recreational athletes. The initial recommendation of treatment is conservative treatment, which includes exercise, heel lifts, and activity modification. The downside of conservative treatment is that it is not as

effective. It has been shown in studies that around 50% of patients that received conservative treatment for an average of twelve months ended up receiving surgery to treat the injury (Nicholson, Berlet, & Lee, 2007). Due to certain risks that can result from surgery, many patients would rather want to maximize the use of conservative treatment (Chimenti et al., 2016).

A study was done to test the effectiveness of platelet-rich plasma and shock wave therapy as conservative treatments for insertional Achilles tendinopathy. The study consisted of 45 patients, which were divided to achieve a fairly equal number receiving the two different therapies. 24 patients were treated with shock wave therapy and 21 patients received platelet rich plasma as treatment. The patients that underwent shock wave therapy received three sessions. Each session was administered weekly and the intensity of the therapy was determined by each patient's tolerance. Gel was applied to the area receiving the treatment to prevent the loss of shock wave energy entering the skin. The patients that received the platelet rich plasma treatment were given two injections over two weeks. Patients were allowed full loading of the limb and were able to perform everyday activities. After the last session with platelet rich plasma injections and shock wave therapy, the patients were given an exercise program to follow at home daily for eight weeks until the first follow up and then twice a week for the following four weeks. These exercises mainly consisted of triceps surae training (Erroi et al., 2017).

The patients were assessed at three follow up time points; at two, four, and six months after the end of treatment. Here, they asked each patient about their recovery and their satisfaction with the treatment. Patient satisfaction increased after each follow up point. There was no significant difference of satisfaction when comparing platelet rich

plasma and shock wave therapy. Overall, at the two-month follow up, 40.9% of the patients were satisfied. At four months, it was reported that 56.2% of patients felt satisfied and at the six months follow up 77.8% of patients felt satisfied. This is a significant increase with almost double the amount that felt satisfied at the first follow up (Erroi et al., 2017).

This study confirmed that both platelet rich plasma injections and shock wave therapy are effective and safe when treating insertional Achilles tendinopathy in physically active individuals. A considerable amount of patients were satisfied through these two treatment options. The Achilles tendon is used every day with almost every activity that a person performs. This is why the recovery process can take a bit longer than a person might want but in order for someone to return to being as active as before the injury, they must follow the protocol for the best possible outcomes.

## **Chapter IV: Knee Injuries**

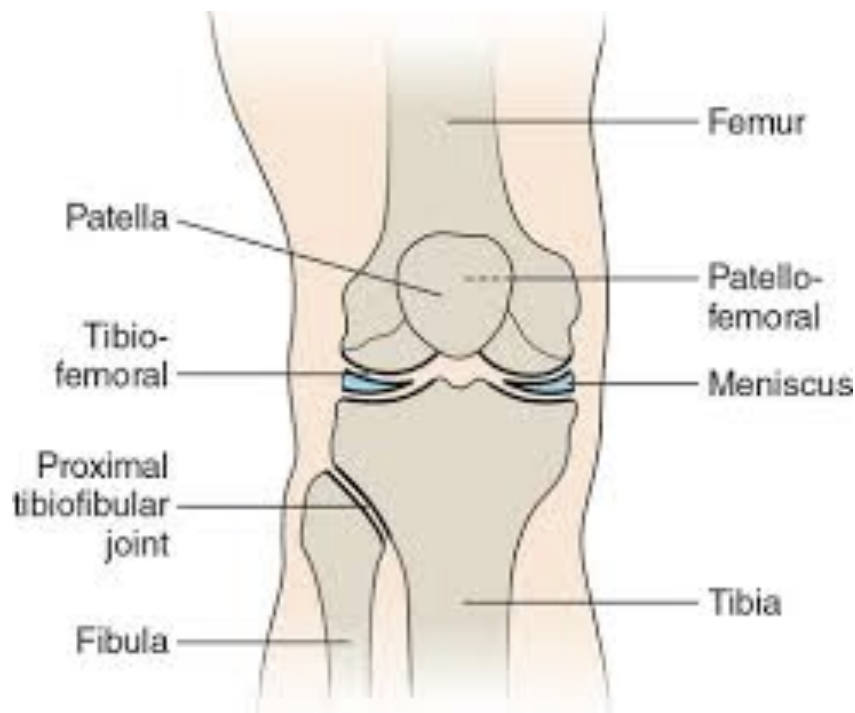### **Anatomy of the Knee**

The knee is the largest and most complicated joint in the body as well as one of the most vulnerable. A joint is an intersection between two bones. The knee is a synovial joint, which is the only kind of joint that can move freely. A layer of hyaline cartilage covers the end of each bone that forms a synovial joint. The smooth cushion provided by the cartilage can absorb the shock of running, jumping, and other activities involving the lower limbs. A thin layer of synovial fluid nourishes and lubricates the cartilage. Holding the bones of a synovial joint together is the joint capsule, a structure whose outer layer consists of dense, flexible connective tissue. The inner layer is made up of a thin synovial

## Common Sports Related Injuries with a Focus on the Ankle and Knee Joints

membrane. The capsule entirely encloses the joint, forming a sac like structure that extends from one of the bones of the joint to the other bone (Feinber, 1993).

The knee provides flexible movement while bearing enormous loads. For example, when walking, each knee supports up to one and a half times a persons body weight. Just normal every day activities place a large amount of stresses on the joint. The knee is the point where the femur meets the tibia. It is made up of two separate joints, the tibiofemoral joint and the patellofemoral joint. Each joint connects the two bones in its name. The tibiofemoral joint links the femur to the tibia. The top of the tibia is made up of two plateaus and a protuberance, or knuckle like projection, known as the tibial tubercle. Between the femur and tibia, lie two crescent shaped pads of shock absorbing stabilizing cartilage called menisci. The patellofemoral joint links the femur to the patella, the bone that covers and protects the anterior surface of the joint. The patella glides along the bottom front surface of the femur in a groove between two protuberances called femoral condyles. Smooth articular cartilage covers the surface of the tubercle and condyle. Together, the two separate joints form a modified hinge joint, a type of synovial joint, allowing the knee to bend and straighten as well as a slight rotational movement in a semicircular motion. In addition to each joint, ligaments hold the bones in each joint together (Moffat, 1999). The following image shows exactly where these joints are located within the knee.

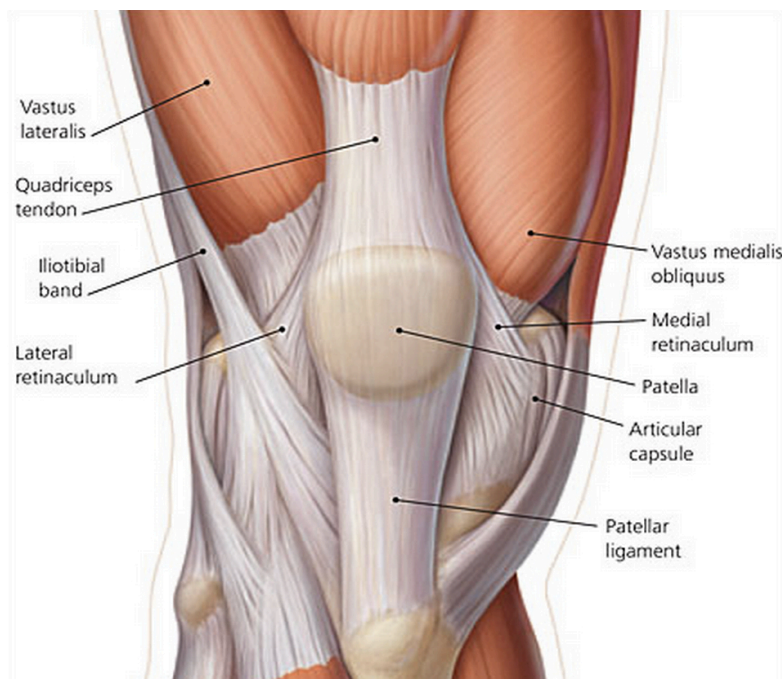


**Figure 13: Location of certain joints within the knee. Retrieved from <http://healthfixit.com/tibiofemoral-joint/>**

Muscles and ligaments of the lower extremity work together to keep the knee stable and moving. The more important muscle groups of the lower extremity are the quadriceps, a group of four muscles that run down the anterior side of the thigh. All four of the muscles extend the knee and only one of these muscles flexes the hip. The quadriceps muscles all have a common tendon of insertion, the patellar tendon, which inserts on the tibial tuberosity. The most superficial muscle of the thigh is the rectus femoris. The rectus femoris runs straight down the femur. This muscle crosses the hip joint; therefore it is the only quadriceps muscle that flexes the hip. The other three quadriceps muscles are called the vastus muscles. The vastus lateralis earned its name from its lateral position. The vastus intermedius is deep to the rectus femoris. Lastly, the vastus medialis is the most medial muscle of the vastus muscle. The hamstrings are a group of three muscles that run down the posterior side of the thigh. These three muscles

## Common Sports Related Injuries with a Focus on the Ankle and Knee Joints

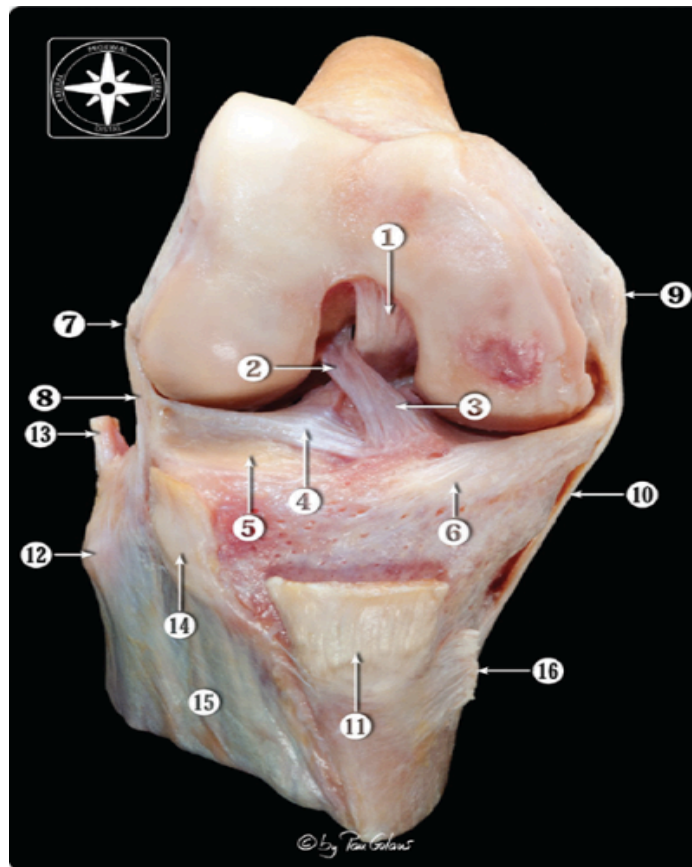
include the biceps femoris, the semitendinosus, and the semimembranosus. All three of these muscles cross the hip joint, are extensors of the hip and flexors of the knee. The biceps femoris is a two-headed muscle that inserts on the femur. One head originates from the ischial tuberosity along with the other hamstring muscles. The other head originates on the femur. The semitendinosus muscle originates on the ischial tuberosity, and it can be distinguished by its long and thin appearance. As opposed to the biceps femoris, the semitendinosus inserts medially. The semimembranosus also originates on the ischial tuberosity and has a flat membranous tendon on the proximal end of the muscle (“Muscles of the Lower Extremity,” 2016). The following image shows the muscles that surround the knee.



**Figure 14: Muscles surrounding the knee. Retrieved from <https://humananatomyly.com/leg-muscle-over-knee/>.**

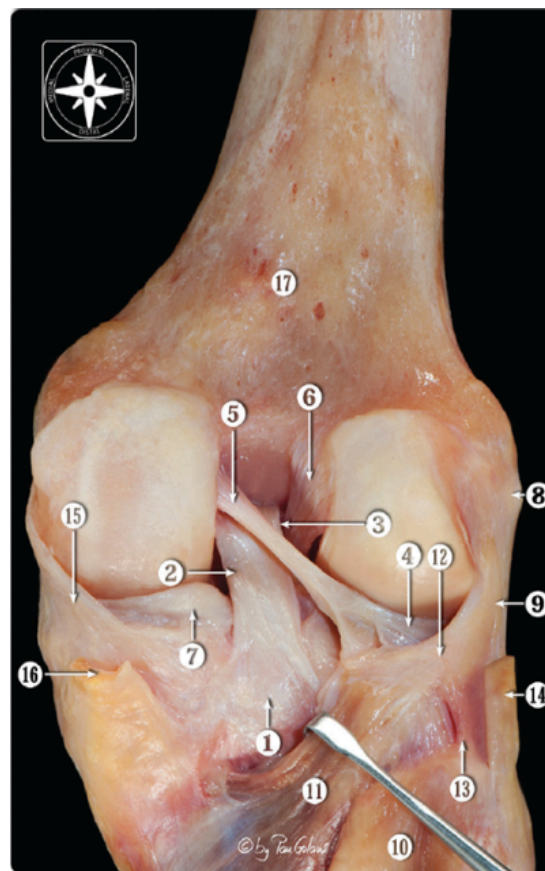
There are two sets of ligaments: cruciate ligaments and collateral ligaments that surround the knee. The Anterior Cruciate Ligament (ACL) is one of the two cruciate

ligaments. It is the primary stabilizer of the knee. It originates from the medial femoral condyle at the posterior side of the intercondylar notch. The ACL then travels anteriorly and in a diagonal direction towards the tibia. The ligament is twisted through 90 degrees and both the length and tension of the fibers in the ligaments are altered as the knee flexes and extends. The anterior aspect of the ligament becomes tightened when the knee is flexed at 90 degrees and the posterior side of the ligament is tightened during full extension (Scuderi, 20120). The following image clearly shows the anterior cruciate ligament.



**Figure 15: Number 2 points to the anterior cruciate ligament (Golanó, n.d).**

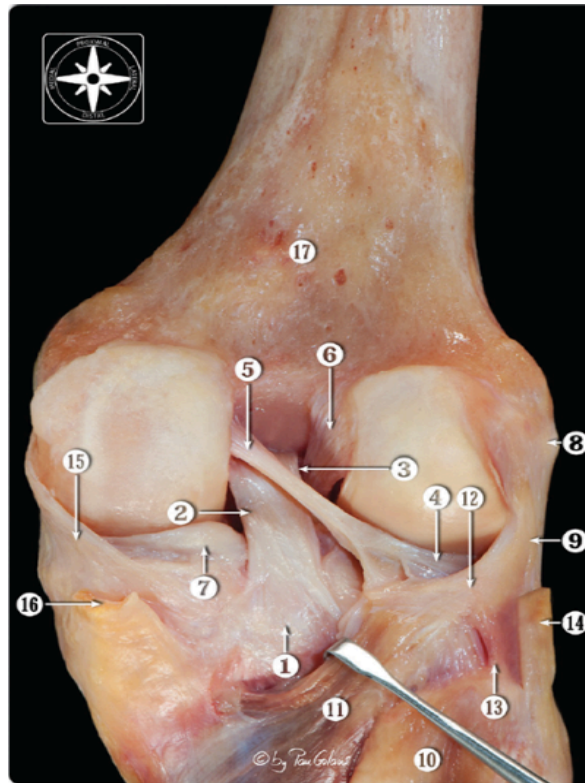
The Posterior Cruciate Ligament (PCL) is said to be the most important ligament of the knee because of its cross sectional area, strength, and location in the central axis of the knee joint. This ligament originates posteriorly in the intercondylar notch off the medial femoral condyle. It travels posteriorly to attach to the intercondyloid area of the tibia just posterior to the lateral meniscus. The tensile strength of the posterior cruciate ligament is almost twice that of the anterior cruciate ligament. Similar to the ACL, the anterior aspect of the PCL tightens when it is flexed, and the posterior side of the ligament tightens when it is extended (Scuderi, 2010). **Error! Bookmark not defined.** The posterior cruciate ligament is shown in the following image.



**Figure 16: Number 2 points to the posterior cruciate ligament (Golanó, n.d).**

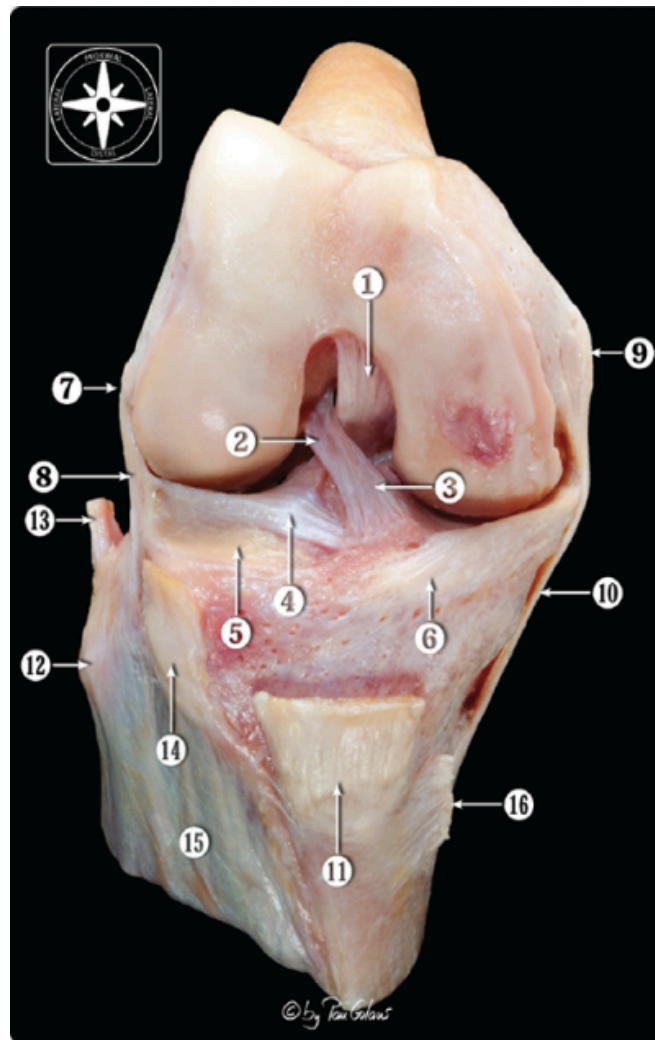


The Medial Collateral Ligament (MCL) is located on the medial side of the knee joint. The proximal attachment site is circular and is on the medial femoral epicondyle, near the center of rotation of the knee. The distal attachment is on the upper part of the medial surface of the tibia. This ligament restrains valgus stress and resists external rotation of the tibia. The lateral collateral ligament is a strong fibrous chord that originates on the lateral femoral condyle and attaches to the lateral fibular head (Scuderi, 2010). The medial collateral ligament and lateral collateral ligament are shown in the following image.

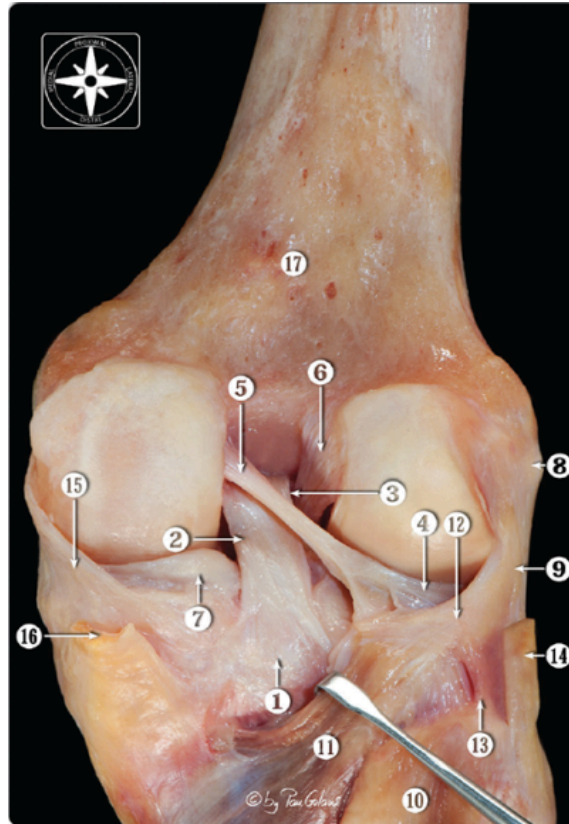


**Figure 17: Number 15 points to the medial collateral ligament. Number 9 points to the lateral collateral ligament (Golanó, n.d).**

The menisci consist of two separate dense cartilaginous tissues. Each meniscus covers approximately two thirds of the surface of the tibia. Their function is to deepen the articular surface of the tibia to fit more nearly with the femoral condyles. They also work as shock absorbers when forces are applied onto the knee. The medial meniscus is semicircular and is attached to the medial ligament of the knee and the lateral meniscus is nearly circular and is not attached to a ligament of the knee joint (Scuderi, 2010). The lateral and medial menisci are shown in the following images.



**Figure 18: Number 4 points to the lateral meniscus (Golanó, n.d).**



**Figure 19: Number 7 points to the medial meniscus (Golanó, n.d).**

### **Knee Sprain**

Knee injuries are very common in contact sports such as football, soccer and basketball. Football is one of the most popular sports in the United States, with 670 National Collegiate Athletic Association (NCAA) teams and 72,788 collegiate participants. Though football is thought to have a higher incidence of head related injuries such as concussions, the proportion of injuries to the knee is still very high (Swedler et al., 2015). Knee injuries have also been reported to represent the second and third most common injury of high school and collegiate football players. Also, fifty-four percent (179) of 332 players who attended a National Football League predraft combine were reported to have a history of knee injuries. Out of these elite athletes, the most

## Common Sports Related Injuries with a Focus on the Ankle and Knee Joints

common injuries were medial collateral ligament injury (MCL), meniscal injury, and anterior cruciate ligament injury (ACL) (Bradley et al., 2008). Participation restriction time also played a factor after each injury. This is defined as the difference between the injury event date and the date on which the athlete returned to full sport participation. Some injuries were considered time-loss injuries because they required at least 24 hours of participation restriction.

Clifton et. al., (2017) analyzed the data to assess the rates and patterns of knee sprains in different competition levels of football. They first calculated knee-sprain rates, overall and by event. These rates were calculated for a specific type of knee sprain such as the anterior cruciate ligament (ACL), posterior cruciate ligament (PCL), medial collateral ligament (MCL), lateral collateral ligament (LCL), and capsular sprain. A total of 374 knee sprains were reported in collegiate football players. Most of these players suffered a time-loss injury, which meant that they had to take time off from the sport in order to make sure the injury would not be exacerbated. Knee-sprains were more likely to occur in a competition rather than during practice because of the intensity put into play by each player. They also found that collegiate football players were more likely to experience a knee sprain when compared to high school athletes and youth athletes. This makes sense because competition is much greater at the collegiate level than at the high school level. College athletes are very focused on trying to move up in the rankings in order to be drafted by professional NFL teams. Thus, they give everything they can on the field to give the best impression to the scouts. Also, college athletes are much bigger than high school athletes so there will be a greater force on impact, which could cause

## Common Sports Related Injuries with a Focus on the Ankle and Knee Joints

more injuries to occur. They found that the risk of suffering a knee sprain in collegiate football was greater than that in high school by as much as 4.2%.

Medial collateral ligament injuries appeared to be the most common injury of the knee representing 61.5% of all knee sprains. Injury to the anterior cruciate ligament (ACL) accounted for 22.2% of knee sprains in the college football athletes. Player contact accounted for the largest proportion of knee sprains; 72.5% of college football athletes were injured from player to player contact and 16.3% of college football athletes suffered a knee sprain from noncontact mechanisms. Many people may think that all of these injuries occur from tackling, but according to this research study that is not the case. In college football, general play was responsible for the greatest number of knee sprains accounting for 24.1% of the knee sprains. Tackling was not even the second greatest cause of knee sprains. In college football, blocking had the second greatest number of knee sprains representing 19.5% of football players. Tackling only accounted for 9.1% of knee sprains experienced by college football players. An explanation of this could be that college athletes have such high skill and strength that they may absorb the impacts better. After years of practice and competitive matches, football players develop the best techniques for tackling an opponent while also minimizing the chances of receiving an injury. The same idea is applied when the football player is being tackled (Clifton et al., 2017).

They concluded that the number of knee injuries increased as the level of competition increased as well. In their study, college level football was the level of competition that reported the most knee injuries, with the medial collateral ligament (MCL) being the most common knee injury throughout. Also, they found that the

## Common Sports Related Injuries with a Focus on the Ankle and Knee Joints

majority of the injuries occurred not while tackling an opposing team member, but by blocking. This can mean that athletes have begun to develop a strategy on how to tackle without causing any injuries.

A different study by Ada & Yavuz, (2015) was performed in order to test the effectiveness of prolotherapy when treating medial collateral ligament injuries. Prolotherapy is an injection based therapy used to treat connective tissue injuries. Their test subject was a 21-year-old male rugby player who had a grade 2 sprain of the medial collateral ligament. During the examination, they found that his pain increased dramatically when bearing any weight, tenderness was observed over the MCL, and swelling around the knee was also found. The patient was given three prolotherapy treatments, one treatment per week for three weeks. Injections were given to the tibial and femoral attachment points of the medial collateral ligament consisting of 15% dextrose and 0.2% lidocaine per injection session. After the first injection session, an exercise program was developed to increase range of motion and to increase the speed of recovery. By the 10<sup>th</sup> day postinjection, the athlete was able to walk without any knee pain and began to use an exercise bicycle. By day 21 postinjection, the athlete was pain free and had full range of motion of the knee being treated. He was able to perform all movements necessary in rugby such as sprinting, accelerations and decelerations without any problems. The athlete was able to play in a rugby match 12 weeks after the start of prolotherapy without any symptoms. The average duration for recovery of a medial collateral ligament tear is usually between four to eight weeks. This study showed that prolotherapy is effective as an alternative treatment option for medial collateral ligament injuries.

### **Strain Around the Knee**

When it comes to strain injuries of the knee, it is easier to focus on the anatomical structures that surround the particular joint. Hamstring strain injuries are a challenge for both athletes and clinicians due to their high rate of incidence, slow recovery, and long lasting symptoms. Around one third of hamstring strains reoccur within the first year of returning to competitive play, which usually leads to an even more serious injury than the first. The incidence rate can mean that the traditional and commonly used rehabilitation programs may not be the best methods for this injury (Heiderscheit et al., 2015). Since this injury is common in athletes, there have been many studies to find out more about it.

A hamstring muscle strain is defined as posterior thigh pain. It is most commonly observed in sports that involve high speed springing and kicking such as soccer and football. Dadebo, White, & George, (2004) reported that hamstring strains represented 11% of all injuries in competitive soccer in Europe. A review of the medical database of the National Football League between 1987 and 2000 showed that 10% of all injuries in college football players that were likely to play in the National Football League were hamstring injuries. Studies have also shown that hamstring muscle strain injuries frequently occur in individual sports like track and field and cross-country. In competitive soccer, hamstring strain reoccurred in 12% to 48% of the athletes (Liu, Garrett, Moorman, & Yu, 2012).

Hamstring muscle strains usually have different grades of severity. Through a combination of physical examinations, ultrasounds and imaging, the severity of the muscle strain can generally be characterized. A grade I strain is a mild strain injury with minimum tear of the musculotendinous tissue and only a small amount of strength loss. A

## Common Sports Related Injuries with a Focus on the Ankle and Knee Joints

grade II strain is a moderate strain injury with a partial tear of the musculotendinous tissue and a decrease in function. A grade III strain is a severe injury associated with a complete tear of the musculotendinous tissue and complete functional disability. Around 97% of all strains that occur in soccer are either grade I or grade II injuries. Grade III strain injuries only occur in about 1% of all strain injuries (Liu, Garret, Moorman, & Yu, 2012).

A study was performed on Australian Football League athletes and track and field athletes to study subjects with a history of hamstring strains compared to athletes that do not have a history of hamstring strains. Two groups were created. The previously injured group included nine athletes who all had a history of multiple hamstring strains over the past years. They defined a hamstring strain as one that caused the athlete to miss at least one week from training or competing. Their strains ranged from grade I to grade III. The second group that consisted of athletes with no previous history of hamstring strain included 18 Australian Football Players (Brockett, Morgan, & Proske, 2003).

The rehabilitation programs set up for the athletes with previous injuries included the use of ice packs, compression bandages, heat treatments, massage, stretches, and many days of rest. Once the pain subsided, non-weight-bearing exercises such as swimming and cycling were performed. Later, weight-bearing exercises were allowed such as knee flexion and extension exercises (Brockett, Morgan, & Proske, 2003).

After measuring the muscle torque around the knee, they concluded that the athletes with previous injuries were at higher risk of another hamstring strain than an athlete without a strain history. Their prediction of hamstring strains showing evidence of



a greater susceptibility for microscopic damage from eccentric exercises was proven.

Hamstring strains are not injuries that should be taken lightly. This injury has the ability to change the entire life of an athlete.

### **Knee Fracture**

The knee is a joint where the femur, tibia, fibula, and patella bones meet. Any one of these bones can become injured if a strong enough force is applied to the area.

Fractures are typically serious injuries that should be treated as soon as possible if an athlete wants to return to the competitive scene. Although the knee is more known for having ligament injuries, there have been reports of athletes obtaining a knee fracture, which not only affects their participation in sports but also their everyday life.

A randomized control study was done in different Swedish football clubs where acute knee injuries were examined. Soccer is one of the sports that have been shown to cause many knee injuries due to its intense use of the legs. After 278,298 football hours, a total of 96 injuries were recorded. Most of the injuries were injuries to the ligaments of the knee, but one other knee injury that was reported was a tibial plateau fracture. This was considered one of the most severe knee injuries reported due to its impact on the athlete's performance (Kraus, Martetschlager, & Muller, 2012).

A tibial plateau fracture is an injury to the upper part of the tibia. A study was done to see the impact that a tibial plateau fracture has on an athlete. There were a total of 89 patients that participated in the study. The patients were asked about their sporting activity three different times; at the time of injury, one year postoperatively, and at the time of the survey. At the time of injury, 79 out of the 89 patients were engaged in a

## Common Sports Related Injuries with a Focus on the Ankle and Knee Joints

sport. Around 60 patients out of the 89 engaged in sports one year after surgery and 65 patients out of the 89 were involved in sports during the time of the surgery. There were eleven professional athletes at the time of injury and only two returned to competitive play around the time the survey was taken. The frequency of participation in sport each week decreased from 2.8 sessions and 4.5 hours at the time of injury to 2.4 sessions and 3.8 hours at the time the survey was taken. It was shown that the majority of the patients did not return to the same activity level as before the injury. Thus showing that this injury can be a career ender for competitive athletes and also impact the sporting activity of an athlete (Walden et al., 2011).

Intra articular fractures of the proximal end of the tibia called “plateau fractures”, are serious and complex injuries to treat. The mechanism of injury is based on the initial load on the knee, which does damage to the tibial articular surface causing it to fracture. In most cases, the initial load is combined with angular forces, which leads to the crushing of the metaphysis as well (Babis et al., 2011). This injury is usually treated with surgery. Injuries that mostly require surgery tend to be serious injuries that can have a great impact on an athlete’s life. It is recommended to have the injury diagnosed as soon as possible to prevent complications from developing. The principles for the treatment of tibial plateau fractures include anatomic reduction of the articular surface, maximum protection of the soft tissue, and early functional exercise. Successful surgical treatment of tibial plateau fractures requires restoration of both articular surface and the line of force of the lower limb. The patient will have x-rays taken and will undergo a CT scan for examination of the knee before the surgery (Zhang et al., 2015). Arthroscopy is crucial in the treatment of tibial plateau fractures as it is useful for controlling articular

surface reduction (Liu, Zhou, & Liu, 2017). A tibial plateau fracture can be a serious injury and should be treated as soon as possible.

### **Knee Rupture**

The anterior cruciate ligament (ACL) is a complex three-dimensional structure that controls forward movement of the tibia relative to the femur (Cowling, Steele, & McNair, 2003). Anterior cruciate ligament injuries are common in sports, particularly in soccer. The likelihood of an anterior cruciate ligament injury ranges from 0.06-3.7 per 1000 hours of participation in soccer. It is estimated that between 50,000 to 100,000 anterior cruciate ligament reconstructive surgeries are performed every year. Just like any other surgery, reconstructive surgery of the anterior cruciate ligament can result in certain complications. These complications can include infection, wound complications, stiffness, and graft failure. Many precautions are taken and precise rehabilitation programs are designed in order to prevent complications and allow for the best recovery (Wong & Muir, 2013).

It is reported that female athletes are more likely to experience an anterior cruciate ligament injury than men. In fact, female soccer players are at six times greater risk than males to tear their anterior cruciate ligament. A report was done on a female athlete that ruptured her anterior cruciate ligament while playing soccer. The rupture occurred during a soccer game when an opposing player came in contact with the medial side of her knee while her foot was planted on the ground. This is considered a varus force to the knee because it is impacting the knee on its medial side. Immediately after the impact occurred, the athlete was not able to bear any weight on her knee. Swelling of the injured knee was noticed right away and the patient needed crutches in order to move

## Common Sports Related Injuries with a Focus on the Ankle and Knee Joints

around. The diagnosis was a full thickness anterior cruciate ligament tear and suspected partial lateral collateral ligament tear. The patient followed an immediate treatment of the tissue injury called RICE, which stands for Rest, Ice, Compression, and Elevation. Prior to receiving surgery on the knee, the patient was treated with mild rehabilitation exercises and laser therapy two times per week for four weeks to prevent the injured area and surrounding muscles from becoming weaker. The patient wanted to return to playing sports, so an anterior cruciate ligament reconstruction surgery using a hamstring autograft was the method that was agreed on. There were no complications with the surgery and the patient was discharged with a follow up appointment in three to five weeks (Wong & Muir, 2013).

Although anterior cruciate ligament injuries are more common in female athletes, males are also experiencing this debilitating injury. In this next case, a young athlete ruptured his anterior cruciate ligament but also had some tears in his left meniscus. Studies have shown that meniscal injuries occur in about 69-78% of all anterior cruciate ligament injuries. Meniscal injuries also account for 23% of all knee injuries. This shows that meniscal tears are also very common. This injury is common among amateur athletes and professional athletes typically from a non-contact mechanism such as a sudden rotation of the knee as well as rapidly accelerating and decelerating, which will result in tearing. The young male athlete reported to a chiropractor that he was running on the soccer field and when he changed directions, his foot was placed on an uneven part of the ground and caused him to collapse. The athlete was unable to bear weight on the left leg and the injured knee began to swell soon after. The MRI showed a full thickness anterior

## Common Sports Related Injuries with a Focus on the Ankle and Knee Joints

cruciate ligament rupture and medial and lateral complex bucket handle tears of the left menisci (Menta & Howitt, 2014).

After undergoing reconstructive anterior cruciate ligament surgery, the patient followed a rehabilitation program to facilitate return to play. The successful program had the athlete developing full range of motion, however he was still experiencing pain, swelling, and tenderness on the medial and lateral sides of the knee. This led to a second reconstructive procedure to repair both menisci. The patient was again put into a rehabilitation program to get him back into playing soccer. The rehabilitation program ended early because of some returning symptoms that made it painful to exercise which led to a third surgical procedure to partially remove the lateral meniscus. The athlete returned to play with full strength but complained his knee “did not feel right” as it had before the injury. This led to a fourth surgical procedure that resulted in a lateral meniscal allograft. This procedure involves replacing the injured meniscus with a new one. The athlete was able to return to play after a few months with periodic treatments for the next three years. The last surgical procedure reduced pain and feeling of instability leaving the patient very satisfied (Menta & Howitt, 2014).

As one can see, knee injuries are very debilitating. It can take weeks before an athlete is able to perform everyday activities and even months to return to competition. A different approach might be taken during the treatment process depending on the severity of the injury. Some tissues like the menisci take longer to heal because they are mostly avascular which limits their ability to heal naturally. Whether it is an anterior cruciate ligament rupture or a tear of the menisci, the athlete will most likely never feel 100% as before the injury and will most likely encounter other knee injuries in the future.

### **Knee Tendonitis**

Jumper's knee is a condition of pain and subsequent dysfunction in the patellar tendon and bony attachments (Cook et al., 2001). This word can be used interchangeably with terms that refer to the histopathology of the condition such as patellar tendinopathy, tendinitis, and tendinosis. This condition is diagnosed by the patient's history, knee examination, and palpation of the patellar tendon. This injury affects a substantial amount of athletes involved in jumping or kicking activities such as basketball, soccer, and jumping events. Patellar tendinopathy results from constant overload of the patellar tendon caused by internal and external factors. A study shows that there is a linear relationship between training volumes in that the harder the floor type on which training is done, the higher the amount of patellar tendinopathy injuries. Their main focus was on volleyball players but the same can be said about basketball players because they are always jumping throughout a match. In a recent study among elite level athletes, 44% of basketball players experienced symptoms of patellar tendinopathy. Their symptoms lasted for an average of two years and the athletes impacted by the injury reported pain and a decrease in function. Also, studies on internal forces indicate that athletes who increase their loads on tendons are at higher risk of tendinopathy (Lian et al., 2007).

A study was performed to test the effectiveness of platelet-rich plasma to treat an elite athlete with patellar tendinopathy. Platelet-rich plasma has been rising in popularity over the past decades for treatments of certain musculoskeletal injuries. Platelet-rich plasma has been used safely for 20 years and has been documented in fields such as sports medicine, orthopedics, neurosurgery, wound healing, and dentistry (Sampson, Gerhardt, & Mandelbaum, 2008). It contains growth factors and bioactive proteins that

speed up the recovery process of injured tendons, ligaments, muscles, and bones (Foster et al., 2009). Therefore it is injected into the injured area with the hope that the body will heal naturally with its assistance. One patient was a 23-year-old track and field athlete with a history of chronic undiagnosed knee pain and obtained an injury to her left knee while performing drills for the high jump. A magnetic resonance image was taken and patellar tendinosis was the injury diagnosed by the sport-specialist physician. At first, the patient began treatment with laser therapy and massage therapy. After one month of complete rest, the athlete was pain free with minimal pain when palpating the patellar tendon. This encouraged the athlete to return to training for two months before joining a minor competition. Her knee pain returned during the competition and a second magnetic resonance image showed that there was an increase in the patellar tendon defect. After months of the previous plan of management and prescribed painkillers, the patient's symptoms showed no signs of improvement (Rowan & Drouin, 2013).

After no signs of healing, the patient was given one injection of platelet-rich plasma with a fat graft. The patient was told not to bear weight for the next two weeks and then slight weight bearing for the third week. The next four weeks consisted of rehabilitation exercises. Once these sessions were over, the patient followed a three-week routine of rehabilitation and aqua jogging. Two months after the platelet-rich plasma an ultrasound was taken of the previously injured area and it was confirmed that there was complete healing of the injury and the patient did not have any symptoms. The athlete gradually returned to training and was back to competing within six months of the first injection (Rowan & Drouin, 2013).

Patellar tendinopathy is an injury that impacts an athlete's performance and quality of life. It is a common injury that is most likely to occur in sports that require athletes to jump constantly throughout their performance. The study emphasized the effectiveness of using platelet-rich plasma protein injections as a complementary therapy as well as hands on therapy. Other therapies such as shock therapy, cryotherapy, and eccentric exercises were also implemented but did not seem to heal the injured area. Patellar tendinopathy does not have an ideal treatment plan, but platelet-rich plasma has definitely shown great results in a reasonable amount of time (Rowan & Drouin, 2013).

### **Chapter V: Conclusion**

As can be seen, injuries often occur to athletes. Injuries to the ankle and knee are quite debilitating and should be taken seriously as soon as they occur. Sprains, strains, fractures, ruptures, and tendonitis are all common sports injuries that an athlete will most likely experience throughout his or her athletic career. If the athlete is hoping to return to sport, he or she should seek medical attention as soon as possible to minimize exacerbation or further injury. There are a variety of treatments available. For example, surgery is usually the choice of treatment for complete rupture of a ligament compared to a mild strain that only requires rest, ice, compression, and elevation to treat. Athletes are going to face injuries throughout their careers, but they should know that healthcare providers will try their best to get them back to competitive play. It is crucial that athletes should not see injuries as a career ender, but as obstacles to overcome.



### References

- Ada, A. M., and Yavus, F. (2015). Treatment of a medial collateral ligament sprain using prolotherapy: a case study. *Alternative Therapies in Health & Medicine*, 21(4), 68-71. Retrieved from <https://0-search-ebshost-com.liucat.lib.liu.edu/login.aspx?direct=true&db=awh&AN=109741458&site=ehost-live>
- Altchek, D. W. (2013). *Foot and Ankle Sports Medicine*. Philadelphia, Pennsylvania: Lippincott Williams & Wilkins.
- Babis, G. C., et al. (2011). High energy tibial plateau fractures treated with hybrid external fixation. *Journal of Orthopaedic Surgery and Research*, 6(35), Retrieved from <https://josr-online.biomedcentral.com/articles/10.1186/1749-799X-6-35>
- Beynon, B. D., et al. (2001). Ankle ligament injury risk factors: a prospective study of college athletes. *Journal of Orthopaedic Research*, 19, 212-220. Retrieved from <https://onlinelibrary.wiley.com/doi/epdf/10.1016/S0736-0266%2800%2990004-4>
- Bones of the foot and ankle*. Retrieved from <https://www.pinterest.com/pin/335518240975415565/>
- Bradley, J.P., et al. (2008). Incidence and variance of knee injuries in elite college players. *American Journal of Orthopedics*, 37(6), 310-314. Retrieved from <https://www.ncbi.nlm.nih.gov/pubmed/18716695>
- Brockett, C. L., Morgan, D. L., & Proske, U. (2003). Predicting Hamstring Strain Injury in Elite Athletes. *Journal of the American College of Sports Medicine*, 379- 386. Retrieved from <https://www.mvclinic.es/wp-content/uploads/Brockett-et-al-2004.pdf>
- Chimenti, R. L., et al. (2016). Insertional achilles tendinopathy associated with altered transverse compressive and axial tensile strain during ankle dorsiflexion. *Journal of Orthopaedic*

## Common Sports Related Injuries with a Focus on the Ankle and Knee Joints

*Research*, 35(4), 910-915. Retrieved from

<https://onlinelibrary.wiley.com/doi/abs/10.1002/jor.23338>

Clifton, D. R., et al. (2017). Epidemiology of knee sprains in youth, high school, and collegiate

American football players. *Journal of Athletic Training*, 52(5), 464+. Retrieved from

http://0-

link.galegroup.com.liucat.lib.liu.edu/apps/doc/A498943292/HRCA?u=nysl\_li\_liu&sid=HRCA&xid=8497ad45

Cook, J.L., et al. (2001). Reproducibility and clinical utility of tendon palpation to detect patellar

tendinopathy in young basketball players. *British Journal of Sports Medicine*, 35(1), 65.

Retrieved from http://0-

link.galegroup.com.liucat.lib.liu.edu/apps/doc/A77059746/PPSM?u=nysl\_li\_liu&sid=PPSM&xid=ef9ee48b

Coté, D. J., Prentice, W. E., Hooker, D. N., & Shields, E. W. (1988). Comparison of three

treatment procedures for minimizing ankle sprain swelling. *Physical Therapy*, 68(7),

1072-1076. Retrieved from <https://www.ncbi.nlm.nih.gov/pubmed/3133668>

Cowling, E.J., Steele, J. R., & McNair, P. J. (2003). Effect of verbal instructions on muscle

activity and risk of injury to the anterior cruciate ligament during landing. *British Journal*

*of Sports Medicine*, 37(2), 126+. Retrieved from http://0-

link.galegroup.com.liucat.lib.liu.edu/apps/doc/A100140820/PPSM?u=nysl\_li\_liu&sid=PPSM&xid=5dd29c03

Dadebo, B., White, J., & George, K.P. (2004). A survey of Flexibility training protocols and

hamstring strains in professional football clubs in England. *British Journal of Sports*

*Medicine*, 38(4), 388-394. Retrieved from

[https://www.ncbi.nlm.nih.gov/pubmed/?term=Dadebo%20B%5BAuthor%5D&cauthor=true&cauthor\\_uid=15273168](https://www.ncbi.nlm.nih.gov/pubmed/?term=Dadebo%20B%5BAuthor%5D&cauthor=true&cauthor_uid=15273168)

- Dixon, B. J. (2009). Gastrocnemius vs. Soleus strain: how to differentiate and deal with calf muscle injuries. *Current Reviews in Musculoskeletal Medicine*, 2(2), 74-77. Retrieved from <https://link.springer.com/article/10.1007%2Fs12178-009-9045-8>
- Erroi, D., et al. (2017). Conservative treatment for Insertional Achilles Tendinopathy: platelet-rich plasma and focused shock waves. A retrospective study. *Muscle, Ligaments and Tendons Journal*, 7(1), 98-106. Retrieved from <https://www.ncbi.nlm.nih.gov/pmc/articles/PMC5505601/#b51-98-106>
- Feinber, B. (1993). *The Musculoskeletal System*. New York, New York: Chelsea House Publishers.
- Foster, T.E., et al. (2009). Platelet-rich plasma: from basic science to clinical applications. *The American Journal of Sports Medicine*, 37(11), 2259-2272. Retrieved from <https://www.ncbi.nlm.nih.gov/pubmed/19875361>
- Garrett, W. E. (1996). Muscle Strain Injuries. *The American Journal of Sports Medicine*, 24(6) Retrieved from <http://europepmc.org/abstract/med/8947416>
- Golanó, P. (2010). Anatomy of the Ankle Ligaments: A Pictorial Essay. *Knee Surgery, Sports Traumatology, Arthroscopy*, 18(5), 557-569. Retrieved from <https://link.springer.com/article/10.1007%2Fs00167-010-1100-x>
- Golanó, P. *Anterior view of the osteoarticular dissection of the right knee joint*. Retrieved from <http://www.aspetar.com/journal/viewarticle.aspx?id=13#.WuatKiMrLR2>

- Golanó, P. *Dissection showing the posterior structures of the right knee joint after removing the joint capsule.* <http://www.aspetar.com/journal/viewarticle.aspx?id=13#.WuatKiMrLR2>
- Haraguchi, N., Toga, H., Shiba, N., & Kato, F. (2007). Avulsion fracture of the Lateral Ankle Ligament Complex in Severe Inversion Injury. *The American Journal of Sports Medicine*, 35(7), 1144-1151. Retrieved from [file:///Users/felipeinostroza/Downloads/Avulsion\\_fracture\\_of\\_the\\_later.PDF](file:///Users/felipeinostroza/Downloads/Avulsion_fracture_of_the_later.PDF)
- Heiderscheit, B. C., et al. (2010). Hamstring Strain Injuries: Recommendations for Diagnosis, Rehabilitation, and Injury Prevention. *Journal of Orthopaedic & Sports Physical Therapy*, 40(2), 67-81. Retrieved from <https://www.jospt.org/doi/abs/10.2519/jospt.2010.3047>
- Kannus, P. (2000). Structure of the tendon connective tissue. *Scandinavian Journal of Medicine & Science in Sports*, 10(6), 312-320. Retrieved from <https://www.ncbi.nlm.nih.gov/pubmed/11085557>
- Kaplan, L. D., et al. (2011). Incidence and variance of foot and ankle injuries in elite college football players. *American Journal of Orthopedics*, 40(1), 40-44. Retrieved from <https://www.ncbi.nlm.nih.gov/pubmed/21720586>
- Kraus, T. M., Martetschlager, F., Muller, D. (2012). Return to Sports Activity After Tibial Plateau Fractures. *The American Journal of Sports Medicine*, 40(12), 2845-2852. Retrieved from <http://journals.sagepub.com/doi/abs/10.1177/0363546512462564>
- Lehtonen, H., et al. (2003). Use of a cast compared with a functional ankle brace after operative treatment of an ankle fracture: a prospective, randomized study. *The Journal of Bone & Joint Surgery*, 85(2), 205-211. Retrieved from

[https://journals.lww.com/jbjsjournal/subjects/Foot%20and%20Ankle/Fulltext/2003/02000/Use\\_of\\_a\\_Cast\\_Compared\\_with\\_a\\_Functional\\_Ankle.4.aspx](https://journals.lww.com/jbjsjournal/subjects/Foot%20and%20Ankle/Fulltext/2003/02000/Use_of_a_Cast_Compared_with_a_Functional_Ankle.4.aspx)

- Lian, O., et al. (2007). Excessive apoptosis in patellar tendinopathy in athletes. *The American Journal of Sports Medicine*, 35(4), 605+. Retrieved from [http://0-link.galegroup.com.liucat.lib.liu.edu/apps/doc/A165767388/PPSM?u=nysl\\_li\\_liu&sid=PPSM&xid=32627b11](http://0-link.galegroup.com.liucat.lib.liu.edu/apps/doc/A165767388/PPSM?u=nysl_li_liu&sid=PPSM&xid=32627b11)
- Liu, H., Garrett, W. E., Moorman, C. T., & Yu, B. (2012). Injury rate, mechanism, and risk factors of hamstring strain injuries in sports: A review of the literature. *Journal of Sport and Health Science*, 1(2), 92-101. Retrieved <https://www.sciencedirect.com/science/article/pii/S2095254612000452>
- Liu, Y. K., Zhou, Z. Y., Liu, F. (2017). New Developments in Treatments of Tibial Plateau Fractures. *Chinese Medical Journal*, 130(21), 2635. Retrieved from [http://0-link.galegroup.com.liucat.lib.liu.edu/apps/doc/A511076560/HRCA?u=nysl\\_li\\_liu&sid=HRCA&xid=947c4f1b](http://0-link.galegroup.com.liucat.lib.liu.edu/apps/doc/A511076560/HRCA?u=nysl_li_liu&sid=HRCA&xid=947c4f1b)
- Long Island University Post Campus. (2016). *Anatomy & Physiology I & II*. McGraw-Hill Education.
- McPhail, S. M., Dusten, J., Canning, J., & Haines, T. P. (2012). Life impact of ankle fractures: Qualitative analysis of patient and clinician experiences. *BMC Musculoskeletal Disorders*, 13(1), Retrieved from [http://0-link.galegroup.com.liucat.lib.liu.edu/apps/doc/A507948816/HRCA?u=nysl\\_li\\_liu&sid=HRCA&xid=e63b8c61](http://0-link.galegroup.com.liucat.lib.liu.edu/apps/doc/A507948816/HRCA?u=nysl_li_liu&sid=HRCA&xid=e63b8c61)
- Menta, R., & Howitt, S. (2014). Meniscal allograft transplant in a 16-year-old male soccer player: A case report. *Journal of the Canadian Chiropractic Association*, 58(4), 436-443.

## Common Sports Related Injuries with a Focus on the Ankle and Knee Joints

Retrieved from <https://0-search-ebshost-com.liucat.lib.liu.edu/login.aspx?direct=true&db=awh&AN=100644124&site=ehost-live>

Milner, C. E., et al. (2006). Biomechanical Factors Associated with Tibial Stress Fracture in Female Runners. *Medicine & Science in Sports & Exercise*, 38(2), 323-328. Retrieved from [https://journals.lww.com/acsm-msse/fulltext/2006/02000/Biomechanical\\_Factors\\_Associated\\_with\\_Tibial.19.aspx](https://journals.lww.com/acsm-msse/fulltext/2006/02000/Biomechanical_Factors_Associated_with_Tibial.19.aspx)

Mirkin, G., & Hoffman, M. (1978). *The Sportsmedicine Book*. Toronto, Canada: Little, Brown and Company.

Moffat, M. (1999). *Book of Body Maintenance and Repair*. New York, New York: Henry Holt and Company.

*Muscles Surrounding the Knee Joint*. Retrieved from <https://humananatomyly.com/leg-muscle-over-knee/>

Nicholson, C.W., Berlet, G. C., & Lee, T. H. (2007). Prediction of the success of nonoperative treatment of insertional Achilles tendinosis based on MRI. *American Orthopaedic Foot & Ankle Society*, 28(4), 472-477. Retrieved from <https://www.ncbi.nlm.nih.gov/pubmed/17475142?dopt=Abstract>

Ogilvie-Harris, D.J., & Gilbert, M. (1995). Treatment modalities for soft tissue injuries of the ankle: a critical review. *Clinical Journal of Sport Medicine*, 5(3), 175-186. Retrieved from <https://www.ncbi.nlm.nih.gov/pubmed/7670974>

Orchard, J., & Best, T. (2002). The Management of Muscle Strain Injuries: An Early Return Versus the Risk of Recurrence. *Clinical Journal of Sport Medicine*, 12(1), 3-5. Retrieved from

[https://journals.lww.com/cjsportsmed/fulltext/2002/01000/the\\_management\\_of\\_muscle\\_strain\\_injuries\\_an\\_early.4.aspx](https://journals.lww.com/cjsportsmed/fulltext/2002/01000/the_management_of_muscle_strain_injuries_an_early.4.aspx).

Orchard, J.W., et al. (2002). Exact moment of a gastrocnemius muscle strain captured on video.

*British Journal of Sports Medicine*, 36(3), 222+. Retrieved from [http://0-](http://0-link.galegroup.com.liucat.lib.liu.edu/apps/doc/A89021726/PPSM?u=nysl_li_liu&sid=PPSM&xid=bc2defcc)

[link.galegroup.com.liucat.lib.liu.edu/apps/doc/A89021726/PPSM?u=nysl\\_li\\_liu&sid=PPSM&xid=bc2defcc](http://0-link.galegroup.com.liucat.lib.liu.edu/apps/doc/A89021726/PPSM?u=nysl_li_liu&sid=PPSM&xid=bc2defcc)

Polzer, H., et al. (2012). Diagnosis and treatment of acute ankle injuries: development of an evidence-based algorithm. *Orthopedic Reviews*, 4(1), Retrieved from

<https://www.ncbi.nlm.nih.gov/pmc/articles/PMC3348693/>

Ramelli, F. D. (2003). Diagnosis, management and post-surgical rehabilitation of an Achilles

tendon rupture: a case report. *Journal of the Canadian Chiropractic Association*, 47(4),

261-268. Retrieved from [https://0-search-ebSCOhost-](https://0-search-ebSCOhost-com.liucat.lib.liu.edu/login.aspx?direct=true&db=awh&AN=12151828&site=ehost-live)

[com.liucat.lib.liu.edu/login.aspx?direct=true&db=awh&AN=12151828&site=ehost-live](https://0-search-ebSCOhost-com.liucat.lib.liu.edu/login.aspx?direct=true&db=awh&AN=12151828&site=ehost-live)

Resch, H., & Breitfuss, H. (1995). Spontaneous tendon ruptures. Etiology, pathogenesis and therapy. *Der Orthopade*, 24(3), 209-219. Retrieved from

<https://www.ncbi.nlm.nih.gov/pubmed/7617377#>

Rowan, T. L., & Drouin, J. L. (2013). A multidisciplinary approach including the use of platelet-

rich plasma to treat an elite athlete with patellar tendinopathy – a case report. *Journal of*

*the Canadian Chiropractic Association*, 57(4), 301-309. Retrieved from [https://0-search-](https://0-search-ebSCOhost-com.liucat.lib.liu.edu/login.aspx?direct=true&db=awh&AN=97583156&site=ehost-live)

[ebSCOhost-](https://0-search-ebSCOhost-com.liucat.lib.liu.edu/login.aspx?direct=true&db=awh&AN=97583156&site=ehost-live)

[com.liucat.lib.liu.edu/login.aspx?direct=true&db=awh&AN=97583156&site=ehost-live](https://0-search-ebSCOhost-com.liucat.lib.liu.edu/login.aspx?direct=true&db=awh&AN=97583156&site=ehost-live)

## Common Sports Related Injuries with a Focus on the Ankle and Knee Joints

- Sampson, S., Gerhardt, M., & Mandelbaum, B. (2008). Platelet rich plasma injection grafts for musculoskeletal injuries: a review. *Current Reviews in Musculoskeletal Medicine* 1(3), 165-174. Retrieved from <https://www.ncbi.nlm.nih.gov/pubmed/19468902>
- Scott, A., Grewal, N., & Guy, P. (2014). The seasonal variation of Achilles tendon ruptures in Vancouver Canada: a retrospective study. *The British Medical Journal*, 4(4), Retrieved from <https://www.ncbi.nlm.nih.gov/pmc/articles/PMC3927994/>
- Scuderi, G. (2010). *The Knee: A Comprehensive Review*. Hackensack, New Jersey: World Scientific Publishing Co.
- Swedler, D. I., et al. (2015). Incidence and Descriptive Epidemiology of Injuries to College Ultimate Players. *Journal of Athletic Training*, 50(4), 419-425. Retrieved from <http://natajournals.org/doi/10.4085/1062-6050-49.3.73?code=nata-site>
- Swenson, D. M., et al. (2010). Epidemiology of US High School Sports-Related Fractures, 2005-2009. *Clinical Journal of Sport Medicine*, 20(4), 293-299. Retrieved from [https://journals.lww.com/cjsportsmed/Abstract/2010/07000/Epidemiology\\_of\\_US\\_High\\_School\\_Sports\\_Related.8.aspx](https://journals.lww.com/cjsportsmed/Abstract/2010/07000/Epidemiology_of_US_High_School_Sports_Related.8.aspx)
- Tibiofemoral Joint*. Retrieved from <http://healthfixit.com/tibiofemoral-joint/>
- Vanlommel, L., et al. (2013). Incidence and risk factors of lower leg fractures in Belgian soccer players. *International Journal of the Care of the Injured*, 44(12), 1847-1850. Retrieved from [https://www.injuryjournal.com/article/S0020-1383\(13\)00309-4/pdf](https://www.injuryjournal.com/article/S0020-1383(13)00309-4/pdf)
- Waldén, M., et al. (2012). Prevention of acute knee injuries in adolescent female football players: cluster randomized controlled trial. *The British Medical Journal*, Retrieved from <https://www.bmj.com/content/344/bmj.e3042>



## Common Sports Related Injuries with a Focus on the Ankle and Knee Joints

Wong, J. J., & Muir, B. (2013). Insufficiency fracture of the tibial plateau after anterior cruciate ligament reconstructive surgery: a case report and review of the literature. *Journal of the Canadian Chiropractic Association*, 57(2), 123-131. Retrieved from <https://0-search-ebscost-com.liucat.lib.liu.edu/login.aspx?direct=true&db=awh&AN=88944307&site=ehost-live>

Zhang, H., et al. (2015). Analysis for clinical effect of virtual windowing and poking reduction treatment for Schatzker III tibial plateau fracture based on 3D CT data. *BioMed Research International*, Retrieved from [http://0-link.galegroup.com.liucat.lib.liu.edu/apps/doc/A458160595/HRCA?u=nysl\\_li\\_liu&sid=HRCA&xid=18b21825](http://0-link.galegroup.com.liucat.lib.liu.edu/apps/doc/A458160595/HRCA?u=nysl_li_liu&sid=HRCA&xid=18b21825)