

Pittsburg State University

Pittsburg State University Digital Commons

Electronic Thesis Collection

Fall 12-29-2016

THE CLINICAL UTILITY OF CONCOMITANT PTEN AND FAS DELETION AS AN EARLY INDICATOR FOR PROSTATE ADENOCARCINOMA SUBTYPES THAT LEAD TO EXTRACAPSULAR METASTASIS

Brendan J. Coulter

Pittsburg State University, brendan.j.t.coulter@gmail.com

Phillip Harries

Pittsburg State University

Follow this and additional works at: <https://digitalcommons.pittstate.edu/etd>



Part of the [Immune System Diseases Commons](#), and the [Pathological Conditions, Signs and Symptoms Commons](#)

Recommended Citation

Coulter, Brendan J. and Harries, Phillip, "THE CLINICAL UTILITY OF CONCOMITANT PTEN AND FAS DELETION AS AN EARLY INDICATOR FOR PROSTATE ADENOCARCINOMA SUBTYPES THAT LEAD TO EXTRACAPSULAR METASTASIS" (2016). *Electronic Thesis Collection*. 237.

<https://digitalcommons.pittstate.edu/etd/237>

This Thesis is brought to you for free and open access by Pittsburg State University Digital Commons. It has been accepted for inclusion in Electronic Thesis Collection by an authorized administrator of Pittsburg State University Digital Commons. For more information, please contact mmccune@pittstate.edu, jmauk@pittstate.edu.

THE CLINICAL UTILITY OF CONCOMITANT PTEN AND FAS DELETION AS AN
EARLY INDICATOR FOR PROSTATE ADENOCARCINOMA SUBTYPES THAT LEAD TO
EXTRACAPSULAR METASTASIS

A Thesis Submitted to the Graduate School
in Partial Fulfillment of the Requirements
for the Degree of
Master of Science

Brendan James-Truman Coulter

Pittsburg State University

Pittsburg, Kansas

December, 2016

THE CLINICAL UTILITY OF CONCOMITANT PTEN AND FAS DELETION AS AN
EARLY INDICATOR FOR PROSTATE ADENOCARCINOMA SUBTYPES THAT LEAD TO
EXTRACAPSULAR METASTASIS

Brendan James-Truman Coulter

APPROVED:

Thesis Advisor _____
Dr. Phillip Harries, Department of Biology

Committee Member _____
Dr. Anuradha Ghosh, Department of Biology

Committee Member _____
Dr. James McAfee, Department of Chemistry

Acknowledgements

I would like to thank Peter Hartmayer, VP Cymogen DX/Wave Sense for all the material support and product expertise, Doug Khalenbeck COO of Gopath Global for permission to obtain patient specimens and authorization to use laboratory equipment, including the state-of-the-art Bioview Duet (Bioview Inc., Tel Aviv, Israel) image analysis system. I would also like to acknowledge Dr. Jeremy Squire, PhD., FACMG, Queens University, Kingston, Ontario, Canada for his advice and cytogenetic expertise in PTEN deletions. Finally I would like express my deep appreciation for the patience and guidance afforded to me by the Biology Department, the Graduate School at Pittsburg State University, and especially Dr. Phillip Harries PhD.

THE CLINICAL UTILITY OF CONCOMITANT PTEN AND FAS DELETION AS AN
EARLY INDICATOR FOR PROSTATE ADENOCARCINOMA SUBTYPES THAT LEAD TO
EXTRACAPSULAR METASTASIS

An Abstract of the Thesis by
Brendan James-Truman Coulter

The utility of genes PTEN and FAS as prognostic markers for the identification of early and/or aggressive prostatic adenocarcinomas is seemingly validated in the study results we obtained using fluorescence in-situ hybridization (FISH) of archived paraffin embedded surgical prostate core biopsy samples obtained from two CLIA and CAP licensed anatomical pathology labs (Bostwick Laboratories, Uniondale, NV and GoPath Laboratories, Buffalo Grove, IL). From early benign subsets of sample cases to aggressive extracapsular invasive tumors, the presence of random deletions evolves into clonal populations of co-deletion of both genes at question. We identify independent research that demonstrates the ability of these two genes to work together in a pathway of rapid cell division and then (or sometimes concomitant) evasion of said neoplastic tumor cell lines from innate cell mediated immunity. Sample size limitations limits predictive values in our study, however this research adds credence to personal anecdotal observation I have made in the past in the capacity of FISH clinical operations and validation management and personal “bench work.” Further, since the onset of our research, using a completely different modality, scientists have studied the same markers together and reached the similar if not the same conclusions.

TABLE OF CONTENTS

CHAPTER	PAGE
I. INTRODUCTION.....	1
II. DIAGNOSTICS BACKGROUND.....	3
III. PROGNOSTICS BACKGROUND.....	6
IV. PTEN RESEARCH.....	10
V. FAS RESEARCH.....	11
VI. MATERIALS AND METHODS.....	13
VII. DATA ANALYSIS and THRESHOLD CUT-OFF.....	24
I. PRECISION.....	25-27
II. CLINICAL ACCURACY.....	28-30
VIII. DISCUSSION.....	32
IX. CONCLUSION.....	35
CITED REFERENCES.....	36
APPENDICES.....	37
APPENDIX A NEGATIVE CUT-OFF.....	38
APPENDIX B POSITIVE SUBSET.....	41
APPENDIX C METASTASIS SUBSET.....	73

LIST OF TABLES

TABLES	PAGE
PRECISION	
TABLE 1.....	23
TABLE 2.....	24
TABLE 3.....	25
TABLE 4.....	26
TABLE 5.....	27
TABLE 6.....	28
ACCURACY	
7 (Positive subset Gleason 6-7).....	29
TABLE 8 (Positive subset Gleason 8-9).....	30
TABLE 9 (Benign subset).....	31

LIST OF FIGURES

FIGURES	PAGE
1A.....	12
1B.....	18
2.....	20
3.....	20
4.....	20
5.....	21
6.....	22
7.....	34

CHAPTER I

INTRODUCTION

According to the American Cancer Society there will be 233,000 new cases of prostate cancer diagnosed in 2014. Of these, 29,480 will be terminal. ACS reports that for the same year, prostate cancer (PC) will be the second most common cause of death from cancer in the United States.

The World health organization's HDI (Human Development Index) categorizes more and less developed regions of the world based on economy, literacy rate, access to health care as well as other factors. In addition, they gather data as it relates to the incidences, mortality and the projected growth of the various forms of cancer throughout the world. In a recent published report by the WHO affiliated International Agency for Research on Cancer (Cancer Research UK, Jan. 2014), HDI and regional cancer statistics were combined. The results show the unmistakable trend of prostate cancer (incidences and deaths) increasing relative to increases in the HDI. Even more disturbing, this same article ranks PC (+3%) at the top of the projected growth percent for 2030 as well as five other common cancer types (Lung (+1%), Colorectal (+1%), Breast (+2%), Cervical (+2%) and Stomach (-2.5%). In the past several decades, clinical screening tests, especially Pap smears, have proven to be effective in preventing low grade squamous intraepithelial lesions (LGSIL) from developing into higher grades including cervical squamous or adenocarcinoma.

In a report published by the Journal of Clinical Oncology¹ found that expensive new treatments for prostate cancer such as IMRT (intensity modulated radiation therapy), laparoscopic

or robotic MIRT's (minimally invasive radiation therapy) and brachytherapy (seeding) with or without radiation therapy increased dramatically between 2002 and 2005. Clearly there is a need to try and push the strategy to beat prostate cancer away from exorbitantly priced treatments, to more affordable, more beneficial forms of preventive medicine (molecular diagnostics or prognostics and the development of pharmaceuticals with the insight molecular pathology and cytogenetics offer).

CHAPTER II

DIAGNOSTICS

Current prostate screening methods are either unreliable or invasive. In cervical cancer cytology based Pap Smears combined with Human Papilloma Virus (HPV) molecular based virus identification are both non-invasive, inexpensive and highly reliable (i.e., when Pap test is combined with HPV molecular testing). Prostate screening has historically relied on two screening modalities. One type uses quantitative analysis of a specific protein obtained from blood samples. This protein, the prostate specific antigen (PSA) is detected and quantified using traditional clinical chemistry methods. According to the Mayo Clinic website, limitations of the PSA assay are **PSA-raising factors** such as benign hyperplasia, inflamed and infected prostate **lowering factors** like BPH or urinary drugs or chemotherapy agents, **inaccurate results**, and **over-diagnosis** in that many of the tumors will not progress to detectable symptoms in their lifetime. The second method of screening is based on the surgical removal of a needle core biopsy from specific regions of the prostate gland. Following this surgery the specimen is processed for histopathological analysis. By its very nature, prostate surveillance is hampered by masculine psychological and societal attitudes with regards to the disease. Historical cultural and behavioral problems seem to be an intrinsic limitation of prostate screening partly due to the invasive nature of the standard diagnostic assays.

The evolution in diagnostics of prostate cancer beyond simple stains and counter-stains like H&E (Hematoxylin and Eosin respectively) follow a path that is the antithesis of Francis Crick's central dogma² IE DNA-RNA-Protein. Thus the recent history of cancer diagnostics

follows the detection of specific proteins associated with cancer, to the detection of RNA molecules that code for the protein products related to cancer. Now we are finally beginning the herculean task of identifying genes and chromosomal aberrations that relate to cancer. This effort begins with a search for larger microscopic features such as chromosome size/number and progresses to an examination of nuclear: cytoplasmic ratios and eventually the spatial relationship between nuclei, cells and adjoining tissues. Early stains relied on variations in staining dependent upon variations in cell structure and pH. These early differential or counter stains were the first step toward focusing on those cellular characteristics deemed most clinically significant.

The first step away from early types of stains occurred in 1941 by Gomori. In his paper³ uses the differential stain chromium hematoxylin-phloxin. He describes a specific staining capability that utilizes the basic environment produced by the insulin producing β cells (Islets of Langerhans) to differentially stain, both directly and indirectly, for the presence insulin. This ushered in the era of special stains.

In reality, any stain that is not an H&E stain is a special stain. The main body of special stains lies in immunohistochemical (IHC) staining or immunofluorescent staining. These stains can be visualized by traditional bright field microscopy or fluorescence microscopy. The origin of this method can be traced back to 1942⁴. According to a paper written to dedicate the contributions of Albert H. Coons the author (Karnovsky)⁵ describes the formulation of a rather straightforward approach at selecting antibodies that are specific for the antigenic epitope of choice (proteins involved in normal or carcinogenic processes), and then labeling by color or fluorescent tags for microscopic analysis.

IHC for prostate includes several stains. Key among them is P63, which is a homolog of the P53 tumor suppressor gene (P53 and P63 can used both diagnostically and prognostically). P63 is expressed in the basal cell layer of the epithelium and is involved in embryogenesis. CK903 and Cytokeratin 34 beta E12 are basal cell specific anti-keratin antibody stains that when positive rule out PC, but when negative do not automatically indicate PC. AMACR and P504S

are positive in PC lesions and positive in benign lesions. In other words, this is a positive dual stain that allows for the differential diagnosis of PC vs. benign tumors. Other positive stains include low molecular weight cytokeratin, EMA and CEA. Negative stains include CD10, Muc6 (normal in lipochrome laden seminal vesicle cells), CK7, CK20 and thrombomodulin. High grade PC (Gleason 8-10) do not express the proteins these negative stains pick up. In an attempt to supplement positive AMACR IHC researches have directed their attention to the Fatty Acid Synthetase⁶. Using microarray or advanced sequencing analysis, studies have shown increases in production of FASn RNA molecules as a backdrop, Wu and associates were able to demonstrate increased expression of FASn PC glands by IHC. Although FASn expression is used as a positive diagnostic marker when up-regulated, we will see that there is a dichotomy to this extraordinary gene, and in fact, it may play a key role in the ability of a tumor suppressor (PTEN) to evade the patients cell mediated anti-cancer immunological response. We now find ourselves at the transition point from diagnostic protein and RNA analysis, to gene and chromosomal prognostication.

CHAPTER III

PROGNOSTICS

“It appears to me a most excellent thing for the physician to cultivate Prognosis; for by foreseeing and foretelling, in the presence of the sick, the present, the past, and the future, and explaining the omissions which patients have been guilty of, he will be the more readily believed to be acquainted with the circumstances of the sick; so that men will have confidence to entrust themselves to such a physician” (Hippocrates, *The Book of Prognostics* 400 B.C.E.)⁷. The art of prognostication and its implementation as a viable medical objective or tool is not new. In CAP Foundation’s (*Conference Series Futurescape of Pathology 2008*)⁸ Jennifer Hunt MD of the Cleveland Clinic describes the time-line of diagnostics and prognostics as it relates to the technology of the day. Where 1500-1800 represented the period of gross examination as a way of achieving these goals. The period between 1800-1930 was dominated by microscopic analysis. Next electron microscopy gave us deeper insight from 1930-1980. IHC followed from 1980-2000 and has been the standard tool to differentiate (diagnostics) types of tumors, and give us deeper insight into the biology of the individual’s cancer (biomarker prognostics). At the turn of the millennia, DNA and the emerging disciplines (e.g., FISH, PCR and next-generation sequencing) are now growing into their place as the yardstick for detecting cancer, predicting outcomes, and hopefully providing opportunities for developing therapeutic strategies to defeat the cancer that is specific even for a single individual.

Arguably the modern age of prognostics started in 1932 with the classification scheme set forth by Cuthbert E. Dukes⁹, whereby he uses a staging system to determine the overall lethality

of the rectal cancer. If the cancer is confined to the rectal tissue there is a better prognosis. If growth is seen in the extra-rectal tissue, the prognosis is poorer, and even worse predictions of the poorest outcomes are seen in patients where the cancer has metastasized to regional and distant lymph nodes respectively. For the most part, traditional pathology, and even diagnostics, relies on the identification of a normal vs. atypical state or condition. In short, it is the phenotypic or genotypic comparison between abnormal and normal. This can be on an organismal, tissue, cellular and even molecular level. Prognostics and modern therapeutics however, rely on a much deeper understanding of interactions between all of the aforementioned levels. Today's prognostics mostly involve the identification of genetic alterations and the subsequent proteins, pathways and extracellular signaling that are directly affected by these alterations. At center stage are the genes and proteins classified as oncogenes and tumor suppressor genes.

The first oncogene or proto-oncogene was discovered in 1970. However, events dating back to 1909 lead to this discovery. In a paper describing the "road to discovering" the first proto-oncogene¹⁰ details the first breakthrough as the point when they identified a hen's tumor cells being transplantable to chickens of the same species¹¹. They determined that the transformative agent was a non-cellular filterable particle. Later studies showed that the virus often had replicative capacity but not transformative (cancer causing) capability and vice-versa. This in turn lead to studies that helped implicates the host genome in the transformation process. Finally, with the help of more modern molecular biology techniques, the first proto-oncogene c-SRC was discovered. Hence, the presence of this gene can be used in the prognostication of sarcoma.

Oncogenes convey carcinogenic properties by producing proteins that ramp-up cell cycle division, whereas tumor suppressor genes code for proteins that in essence keep the cell cycling in check. When deleted, tumor suppressor genes can cause cancer or make it significantly more aggressive. Arguably two of the most significant tumor suppressor genes discovered were p53 and PTEN. PTEN (phosphatase and tensin homolog) or MMAC1 (mutated in multiple advanced cancers) are the same protein and were discovered simultaneously by researchers Li and Steck

respectively in 1997¹². Subsequent studies have helped cobble together a picture of this amazing gene's role in tumor suppression, and embryogenesis and even apoptosis. In a review article published in 2004 by the Medical Science Monitor, Eric C. Chu and Andrzej S. Tarnawski¹³ outline the known basic involvement of the PTEN protein in tumor suppression. It starts with the molecular structure and its dual enzymatic capacity. In that they have both protein phosphatase and lipid phosphatase activity. Like so many other critical proteins, PTEN is involved in a multi-tiered pathway that affects cell cycling, growth and apoptosis. They describe the protein as having two domains and a tail section. The first motif is made up of the N-terminal region which consists of the Phosphatase domain. This is purportedly responsible for the tumor second motif is made up of the C-terminal region which consists of the C2 domain and the tail or PDZ domain. The C2 domain is responsible for PTEN's affinity for phospholipids. This allows for PTEN to be placed appropriately for a signal transduction cascade that involves many proteins. The tail domain contains protein kinase CK2 phosphorylation sites which allow for stability and activity of the protein. The general pathway starts with PTEN positioning itself on the membrane proximal to a tyrosine kinase receptor which as yet is not fully understood, The other major well documented area of clinicopathological and molecular diagnostics and prognosis are the and ETS (MAINLY TEMPRSS-ERG) fusion related family destruction.

Prostate cancer displays a "multifocal" pattern when observed in traditional morphologic histopathological analysis, whereby this cancer (PcA) has demonstrated upwards of 79% multifocal distribution in one large study by Yoshimoto¹⁴ which included 142 prostatectomy specimens all positive for PCA. Further, this multifocal characteristic is accompanied by varying genetic heterogeneity. As mentioned above, the two major genetic alterations are the ETS genomic rearrangements and PTEN loss. According to this study, albeit commonly seen together, PTEN loss has a stronger correlation with higher Gleason score than ETS by itself¹⁵. It has therefore been determined that PTEN loss demonstrates the ability to be a more useful early biomarker for the detection of aggressive cancers. In fact, 35-58% of advanced cancers have PTEN loss either

as hemizygous or homozygous. As they point out, however, the ETS rearrangements likely play an important role in prostate cancer progression due to the involvement of its promotor region driving the expression of the fused ETS gene.

This is the main crux of this study. Since there is a lack of correlation between ETS rearrangements and high Gleason score, could there not be some other “genetic factor” that drives the clonal populations towards aggressiveness independent or in combination with a completely different mode of clonal expansion and metastatic potential. As we will see, there might be something going on with the PTEN loss or more accurately its loss and the concomitant loss of its proximal gene FAS and its relationship to apoptosis and cell mediated immunological cancer destruction.

CHAPTER IV.

PTEN RESERCH

When trying to determine the clinical outcome of prostate cancers with Gleason scores remain the best prognostic markers. With a grant from the Canary Foundation, a multicenter retrospective study was performed using tissue microarrays (TMA) to study PTEN. The majority of positive core biopsies performed on patients result in a score of 6 or 7. However, upon radical prostatectomies performed on the same patients 14-51% and 9% were downgraded (Troyer, 2015). Another study has shown that clinical stage, which is the second most used indicator does not help predict the final stage¹⁶. According to the Canary study, of the 55 tumors with homozygous deletion 16 had interstitial deletions involving PTEN alone retaining both flanking genes in the 4 probe cocktail (fig 5) and 39 homozygous deletions having deletions of all three genes (WAPAL, PTEN & FAS). Interestingly, without explanation, they consider the deletion of all three genes as mere artifacts. They might be artifacts in as far as their research is concerned but their ubiquitous presence in certain clonal populations make it worthy of investigation in order to rule out their potential to the overall transformation from indolent to more aggressive forms. Further they report undeleted cases as correlating to Gleason 6 while having a Gleason score of 8 was more associated with homozygous deletions. As will be seen, these results are contrary to what was observed in my research.

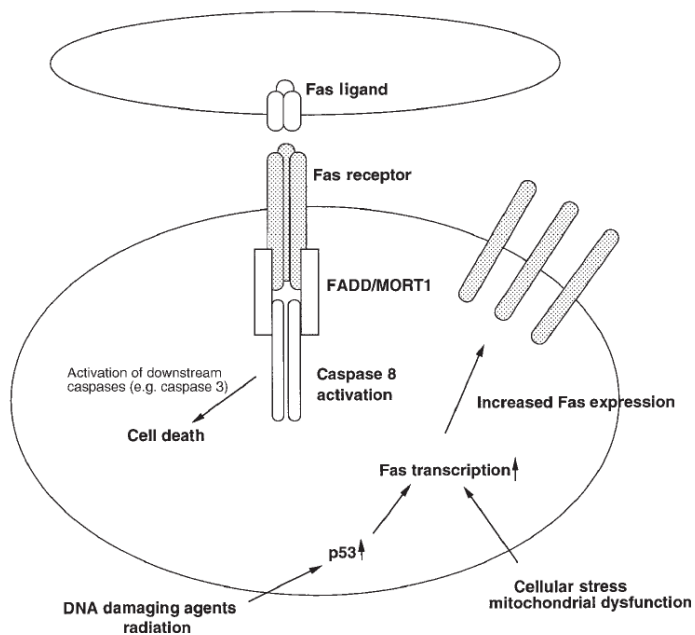
CHAPTER V.

FAS RESERCH

Fatty acid synthase or FAS (also known as APO-1 and CD95) is a gene that codes for the FAS ligand and the FAS cell surface receptor which are part of the super family TNF. The interaction of this receptor by the FAS ligand has been well documented to induce apoptosis. It was first identified by a study done in 1989 by BC Trauth¹⁷ in the American Journal of Medicine. They were able to induce apoptosis with the use of a monoclonal antibody directed at the FAS cell surface receptor. FAS is one of the destruction pathways used by cytotoxic T via MHC class I cells to induce apoptosis¹⁸. These researchers also note that experimental introduction of DNA damage causes a marked upregulation and overexpression of both the FAS ligand and cell surface receptor. It is therefore possible for cells undergoing significant genomic stress to upregulate these proteins, which in turn find their way to the cell membrane and engage to form a complex that ultimately interacts with several intermediate proteins and complexes. These intermediates are eventually able activate the protease caspase 8 and finally caspase 3 (fig 7) which cleave substrates like the nuclear lamins, actin filaments as well as enzymes responsible for DNA repair. DNA fragmentation is often associated with end stage apoptosis. Up regulation and presentation of the FAS ligand is known to be associated with cytotoxic T cells thereby making them “weaponized.” This affords lymphocytes the ability to interact with and turn on the self-destruct triggers in said stressed or compromised cells (e.g., cancer). Interestingly this article points to the use of anti-FAS antibody in the treatment of certain diseases such as glumerulonephritis, arthritis and other systemic autoimmune diseases.

Over expression of FAS in PCA has been demonstrated in several studies. On the surface, no pun intended, the over expression of FAS would seem to rule it out as an early biomarker for aggressive type prostate tumors. However, like the presence of FAS mutations in the precursor lesions known as PIN (prostatic intraepithelial neoplasia, Bostwick¹⁹), and the subsequent lack of mutation in the FAS gene in higher grade neoplasia,²⁰ later over expression does not rule out its role in the early pathogenesis of aggressive PCA. It is this conundrum, in my opinion, that elicits the premature conclusion by the above mentioned Troyer and colleagues use to describe the loss of FAS as a mere artifact.

Figure 1A.



CHAPTER VI.

MATERIALS AND METHODS

Quality Control

Probe were stored at -20° , protected from light. Excess freeze/thaws cycles were avoided. Probe were not used beyond their expiration date shown on vial. All reagents were molecular grade. Reagents were labeled, dated, and all prepared reagents were initialed. Parallel test were performed on all newly prepared reagents with reagents that have passed manufacturing QC requirements. Reagents were prepared and pre-warmed in advance when applicable. Equipment was routinely calibrated according to CLIA standards. Control slides were run concurrently with patient slides to monitor their assay performance and to assess their accuracy of signal enumeration. Control slides were used beginning with the de-paraffinization process onward. Reagents were required to reach their desired temperatures prior to initiating the procedure. DNA probe were validated with established cut off values. Each hybridized slide was evaluated against quality parameters determined by the laboratory. FISH assay results were considered not to be informative if the specimen quality and/or specimen slide preparation was inadequate. A rigorous quality check was performed before scoring.

Preparations required before starting procedure

2ul specimen sections were baked for 3 hours to overnight at 56° C. All reagents and stock solutions were prepared prior to the start of teach procedure. Care was taken to make sure slides were labeled correctly: probe ID, date, and study number. If an H & E slide corresponding to the FISH slide was available a pathologist demarcated the area of interest, corresponding slide

areas were marked on the test slide with a diamond tipped pencil on the backside of specimen slides(s) prior to processing. Focus on these areas was given when analysis was being performed.

Equipment

Fluorescent microscope equipped with recommended filters: DAPI, Aqua, Orange, Green, and Red Phase contrast light microscope, Fume hood, Micro-pipettor (1-20 μ l), 20-200 μ l), 100-1000 μ l), Timer, Magnetic stirrer, Vortex mixer, Microcentrifuge, Water baths, Thermobrite or hybrite, pH meter, Hot air oven (56°C), Leica Ariol scanning System

Materials

Calibrated thermometers, Micro test tube racks, Rubber cement, 2 microns section of positively charged or, silicized microscope slides, Glass coverslips-22x22mm or 24x50 mm, Polypropylene micro centrifuged tubes, (1.5ml), Graduated cylinders, Forceps, Coplin jars note: gradually heat glass Coplin jars up to 72-80°C otherwise they will crack, Anhydrous Ethyl Alcohol. Store at room temperature. Open in fume hood 20x SSC, NP40 or Igepal. Store in dark 2-8°C, DAPI II store at -20°C, Micropipettor tips 10, 200, 1000, Stir bars, HCl 1.0N soln, 12 N HCl, NaOH 1.0N soln, Pepsin Powder, Laboratory wipes, Pyrex bottles -250-500ml, 1L, 1L volumetric flasks, DAPI II counterstain (Vysis), Triton X, EDTA, NaBH₄, DiH₂O, 10% Neutral Buffered Formalin (NBF)

Reagents Preparation

1X PBS (pH7.2-7.4)

100mL 10X PBS + 900ml Deionized water

1% Formaldehyde:

125 ml of 10% NBF

370 ml of 1X PBS

5 ml of 100X MgCl₂.

Store at 2-8°C.

Denature solution: (pH 7.0-8.0) (70% Formamide/2X SSC):

350 ml Formamide, 50 ml 20X SSC, and 100 ml DI water.

Store at 2-8°C.

1mM EDTA

20X SSC (using 20X SSC powder)

264g 20XSSC + 900ml of DiH₂O. Mix thoroughly.

Adjust pH to 7.0 and adjust volume to 1L with additional water. Store at 2-8° for 6 months.

20X SSC

Dissolve the following in 800ml of DiH₂O:

175.3g NaCl and 88.2g NaCitate

Adjust the pH to 7.0 with a few drops of 1N HCl or 1N NaOH and adjust the volume to 1L with additional DiH₂O. Store at 2-8° for 6 months

2X SSC

100ml 20XSSC

900ml DiH₂O

pH to 7.0-7.5. Store at 4-8°C.

Wash Solution (0.2XSSC/0.3%NP-40) (1 Liter)

10mL 20X SSC

3mL NP40

Bring up to 1 liter with DiH₂O.

pH to 7.0-7.5. Store at RT.

0.01N HCl (pH 2-2.5)

833μL of 12N HCl into 1L DiH₂O

Pepsin

Stock Pepsin: 10g pepsin to 100ml of purified water

Aliquot into ~7mL tubes, freeze, expires in 3 months.

Working pepsin: Add 6.6ml of thawed and mixed Stock Pepsin solution to 500ml of 0.01N HCl

Triton**Stock Triton Solution:**

25ml of 2M MgCl₂

125ml of 10X PBs

850ml of DiH₂O

Working Triton Solution:

500mL stock triton solution

2.5mL Triton X

NaBH₄

Use 1mg of NaBH₄ per one milliliter of 1XPBS

Probe

3-5 μ L of Cymogen DX (Irvine, CA) ***PTEN Del-Tect*TM Four Color Probe**

Procedure

Specimens were cut to 2 μ m sections from blocks; slides were baked in oven at 56°C for 3 hours or overnight. Manual Deparaffinization. Slides were immersed in xylene for 2 minutes x 5 changes in a fume hood. Slides were immersed in 100% EtOH for 2 minutes x 5 changes in fume hood. Slides were rinsed in diH₂O x 3 changes. Antigen retrieval was performed in with 1 mM EDTA in pressure cooker for 25 min >125° C. They were then rinsed in deionized water 3-4 times. Slides were taken out and until they cooled down. Slides were placed in 1mg/ml NaBH₄/1XPBS solution for 10min, and then repeated in fresh solution for 10min, then rinsed in several changes of water. Slides were run on Vysis processor using the standard tissue protocol.

FISH probes were thawed at RT for 10 minutes, vortexed briefly and microcentrifuged for 5-10 seconds. The probe was then warmed so that the viscosity decreased sufficiently to allow accurate pipetting. 3-5 μ l was added, with the appropriate amount of anti-fade reagent, to the tissue area on the slide, and placed and appropriate sized coverslip was placed on probe area. Bubbles were removed by gently massaging them out using our finger nail. Coverslips were

sealed with rubber cement. Thermobrite was set to 83°C for 5 minutes (the co-denature step) and then 37°C for 16-24 hours for hybridization. Moisture strips soaked with dH₂O and place in the slots in the Thermobrite. Test slides were placed flat in the center position to outside. The lid was closed and the program ran. The Thermobrite was not reopened for 16 hours. Probes were refrozen @ -20°C. 0.2 XSSC/0.3% NP40 was warmed (~45min) in a water bath. The temperature was double checked for the hot wash solution by inserting a thermometer directly into the solution, before and after sample slide were added. The solution had to be at 50° +/- 1°. Rubber cement was removed from the slide. Slides were placed in RT 2XSSC for 5 min. and agitated to remove the coverslips. If coverslip did not come off, the coverslips were gently moved to the edge of the slide and flicked off with the fingernail or forceps. Slides were washed in the hot wash mixture for exactly 2 minutes at 50°C, while gently agitating the first 30 seconds. Slides were transferred to fresh 2XSSC at RT briefly. Air dry slide in dark drawer. Thaw DAPI II counterstain. Vortex and pulse microcentrifuge DAPI II. Add 10-15µl DAPI II to the tissue areas on the dry slide. Coverslip slide and refreeze DAPI II. Place slide in a slide tray in the freezer for ~ 30 min or until ready to analyze.

Controls

Control slides had to be run concurrently with patient slides in order to monitor the assay's performance and to assess the accuracy of signal review. One positive control slide had to be processed for each specimen processing run, and with each new kit lot. Included was a parallel patient slide (previously tested) every time newly prepared reagents were used.

Specimen Requirements

Specimen Type(s) including minimum volume/amount to perform assay: Specimen type PTEN/FAS FISH prostate biopsy FFPE slides. Minimum volume/amount: 2µm sections from tissue block. Specimen collection stability and handling: Specimens had to be fixed in formalin 24-48 hours of collection. PTEN/FAS FISH assay was performed within 4 weeks of the slide preparation for optimal results. Unacceptable samples/specimen rejection criteria. An analyzed

specimen was eliminated if the following conditions /criteria occurred: Section cut from tissue block and placed on slide was non-representative of original histological diagnosis. Specimen in which the representative tissue was exhausted during the histological diagnostic process. Poor hybridization (e.g. weak or no signals) resulted in equivocal interpretation. Samples that were not received in formalin in the histology lab. Samples that were not embedded in paraffin.

Principles of Fish Evaluation

When evaluating the results of FISH, several factors were kept in mind: the architecture of the tissue, including local variations in neoplastic cell content, fixation, and tumor cellularity within the section; the frequent presence of truncated nuclei; and the complex nature of genetic arrangements that were seen in some neoplasms.

Enumeration guidelines for deletion of locus-specific probe on formalin-fixed paraffin-embedded (FFPE) tissue was provided. Typically, areas selected for FISH evaluation were marked on a Hematoxylin and Eosin (H & E) stained slide that were directly adjacent to section being used for FISH. Areas of the FFPE section selected for enumeration had to pass rigorous quality criteria as being suitable for FISH analysis as detailed below.

Evaluation of Selected Areas (marked with diamond pen on back of slide)

Hybridized slides were evaluated for the specificity of the hybridization, the probe signal intensity and the signal to background noise was determined so the hybridization was optimal for the given analyses. Typically, at least 85% of all nuclei in the target area were easily enumerable. There was a minimum background or nuclear fluorescent "noise". The FISH signal intensity was consistently greater than background intensity in the regions of the slide chosen for analysis. Thus, background noise was recognized by their lower intensity of the probe signal and different shape.

The target area was scanned using a low power objective to examine cell distribution. FISH analysis was normally focused on areas richest in abnormal cells. Variability most often was observed within the section in terms of tissue preservation and morphological detail. It was

useful to keep a conventionally H&E stained section for reference. Select of several areas was chosen on the tissue where the cells were evenly distributed yet at a density that several nuclei could be evaluated at 40x objective.

Areas were avoided where the borders of individual nuclei were not clearly identified and/or high cell density caused excessive nuclear overlapping. At the same time the quality of the tissue section was reviewed, the FISH signals were assessed by selecting and looking for the areas with the brightest, most distinct signals while simultaneously having a low background “noise.” This made individual nuclei more distinct and easier to enumerate. In general nuclei were selected that had the same intensity and the DAPI staining was mostly uniform.

The shape and appearance of the DAPI was compared to the H&E or immunohistochemical stained nuclei with a focus on the morphological characteristics of the cells and the histological patterns of the tissue.

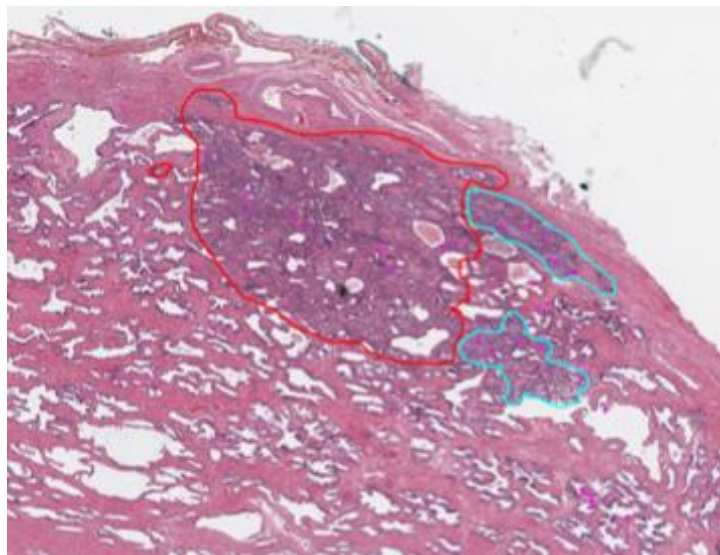


Figure 1B. Areas of interest marked on the H&E slide by the pathologist.

Selection of Nuclei to Score

The selection of nuclei to score was a distinct step from the actual enumeration of probe signals. In a given field of view, the nuclei were scored and first selected on the basis of the criteria listed below.

Enumeration of the nuclei meeting these criteria were scored in an unbiased fashion.

DAPI/Morphological Criteria:

Nuclei had bright and uniform DAPI staining. Within adequate specimens, interphase cells were required to be well defined and non-disrupted. (Figure 2A)

- A. Prostate cancer cells were selected on the basis of their large size, well-round nucleus that was located near the central focal plane (Figure 2B). Small nuclei or nuclei that were below average size were not selected as they may have had truncation affect due to the sectioning process. (Figure 2C)
- B. The slide preparation required that they not be under-treated to the point of preventing clear identification of the nuclear borders. Over-treated samples had a doughnut-like appearance, with the nuclear contents missing from the center and were not enumerated. (Figure 3)
- C. Tumor nuclei could not be covered by a cloudy yellowish layer or obscured by auto-fluorescent structures.
- D. Nuclei were examined that were well separated from each other (touching or overlapping nuclei were avoided). (Figure 2D)
- E. The nucleus had to have a consistent size at extreme focal planes along the z-axis. This would ensure that the maximum volume of nucleus was present, minimizing sectioning artefacts (Such nuclei would have been considered “intact” nuclei). (Figure 4)

Figure 4:

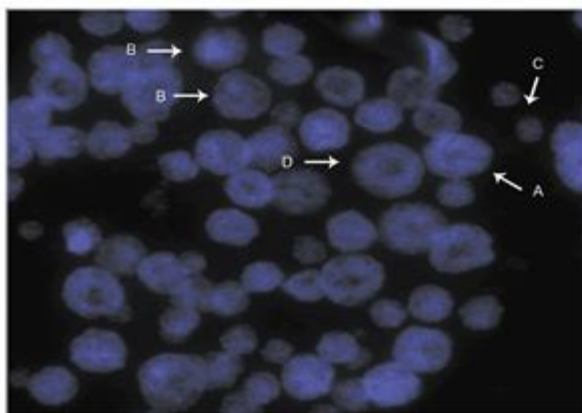


Figure 2 - Selection of nuclei to score. A) bright and uniform staining. B) large, well-rounded nucleus. C) small nucleus not suitable for scoring. D) well separated nuclei.

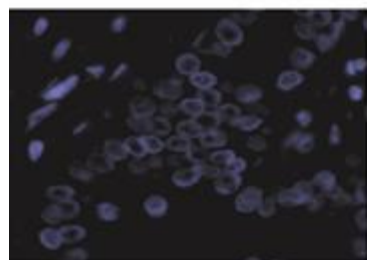


Figure 3 - Overdigestion of FFPE sample, as seen by the doughnut-like appearance of the nuclei.



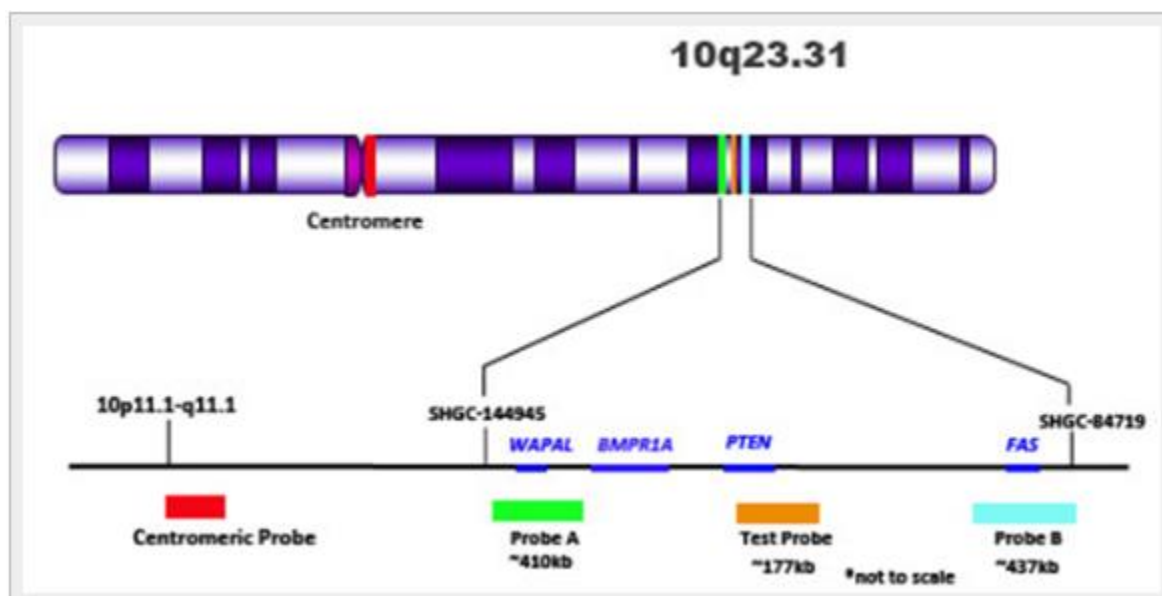
Figure 4. A representation of truncated nuclei due to the sectioning process. Intact 'nuclei' will have similar size as the extreme ends of the z-axis focal plane.

ENUMERATION OF SIGNALS

Having selected the optimal group of nuclei to score in the given field of view, I proceeded to enumerate the probe signals in the unbiased manner described above. I scored only those cells with red (centromeric) signals. This PTEN deletion probe set probe included four probes, each labelled with a different fluorophore. Each probe was enumerated on its own using a single narrow band pass filter. Beginning with the first probe color and its appropriate filter (FAS and aqua or PTEN and RED), I enumerated the signal in a given cell, and proceeded or toggled to the next color/filter. I repeated this until all the probes and colors were enumerated for a given cell. The number of signals in the nucleus selected for enumeration were recorded separately on the score sheet. Only cells with 2 red (centromeric) signals were enumerated. It was usually necessary to focus up and down in the z-axis of the focal plane to accommodate the different spatial configurations the probe signals occupied within the nucleus. In some cases, paired signals

would appear. I counted paired signals (two smaller signals in very close proximity, with distance between them less than the size of one signal) as one signal. Following DNA replication during mitosis, some nuclei may present paired signals, two smaller signals in very close proximity. These paired signals represent a single chromosome already replicated into sister chromatids. I evaluated split or questionable signals by observing at higher magnification. I counted only nuclei, in which a definite enumeration could be made, I did not analyze or enumerate inconclusive cells. I did not evaluate interphase nuclei with multiple signals located on the extreme periphery of the nucleus. I recorded accurately the signal count from each cell. When the boundary of visible or interpretable nuclei is reached I skipped to the next field of view and continued the scanning process. Moving from left to right (or top to bottom) I continued to scan the slide for fields with evaluable nuclei. I repeated this scanning process until the appropriate number of nuclei was enumerated (50 or more were enumerated depending upon the prevalence of the abnormal cells and the area of interest is analyzed).

Figure 5:



The PTEN probe consists of four colors: red, orange, green, and aqua. The red fluor localizes to the centromere of chromosome 10, while the orange fluor is specific for the gene of interest

(PTEN). The green fluor localizes to the WAPAL gene and is centromeric to PTEN, while the aqua fluor localizes to the FAS gene and is telomeric to PTEN

CHAPTER VII.

DATA ANALYSIS

FISH results for this study were performed using the same clinical accuracy results obtained in laboratory in which the results for this research project was completed using the ASR (analyte specific reagent) validation parameters required by CLIA (Clinical Laboratory Improvement Amendments). This included parallel results from Bostwick laboratories in New York and Orlando, reproducibility (precision) using 3 positive and 3 negative, two technicians over the course of 3 days each having a different “running” of samples, sensitivity and specificity using known (known conventional surgical pathology diagnoses) and positive threshold (see Figure 6 FAS/PTEN CUT-OFF below) cutoffs using cases obtained exclusively for this research project.

FAS/PTEN CUT-OFF

CASE	FAS HEMI DELETION	FAS HOMO DELETION	PTEN HEMI DELETION	PTEN HOMO DELETION	
GP14-1807-F		21	1	16	0
GP14-1061-G		22	0	20	0
GP14-1485-F		0	0	0	0
GP14-1485-C		29	3	28	2
GP14-1590-C		20	0	13	0
GP14-1732-D		14	0	9	0
GP14-1732-E		14	0	9	0
GP14-1807-E		18	1	15	1
GP14-1997-G		6	3	6	0
GP14-2018-I		8	0	6	0
MEAN =		15.2	0.8	8	8
STANDARD DIVIATION=		8.638415493	1.229272594	8.024961059	0.674948558
2XST DIV		17.27683099	2.458545189	16.04992212	1.349897115
3XST DIV		25.91524648	3.687817783	24.07488318	2.024845673
PERCENTAGE CUT-OFF		26/200= 13%	4/200= 2%	24/200= 12%	2/200= 1%

PRECISION**TABLE 1.** DAY 1, RUN 1, TECHNOLOGIST 1

	CASE #	Hemizygous deletion (% of cells)	Homozygous deletion (% of cells)	FISH INTERPRETATION
1	Val-0020908	26	8	Abnormal/ Hemizygous
2	Val-0022175	4	34	Abnormal/ Homozygous
3	Val-0026865	22	2	Abnormal/ Hemizygous
4	Val-0018480	8	4	Normal/ Diploid
5	Val-0018585	0	0	Normal/ Diploid
6	Val-0018540	8	6	Normal/ Diploid

TABLE 2. Day 1, Run 1, Technologist 2

	CASE #	Hemizygous deletion (% of cells)	Homozygous deletion (% of cells)	FISH INTERPRETATION
1	Val-0020908	30	6	Abnormal/ Hemizygous
2	Val-0022175	14	36	Abnormal/ Homozygous
3	Val-0026865	22	6	Abnormal/ Hemizygous
4	Val-0018480	12	4	Normal/ Diploid
5	Val-0018585	2	0	Normal/ Diploid

6	Val-0018540	8	10	Normal/ Diploid
---	-------------	---	----	-----------------

TABLE 3. Day 2, Run 2, Technologist 1

	CASE #	Hemizygous deletion (% of cells)	Homozygous deletion (% of cells)	FISH INTERPRETATION
1	Val-0020908	26	6	Abnormal / Hemizygous
2	Val-0022175	8	30	Abnormal/ Homozygous
3	Val-0026865	24	10	Abnormal / Hemizygous
4	Val-0018480	8	6	Normal / Diploid
5	Val-0018585	0	0	Normal / Diploid
6	Val-0018540	6	12	Normal / Diploid

TABLE 4. Day 2, Run 2, Technologist 2

	CASE #	Hemizygous deletion (% of cells)	Homozygous deletion (% of cells)	FISH INTERPRETATION
1	Val-0020908	30	4	Abnormal / Hemizygous
2	Val-0022175	14	34	Abnormal/ Homozygous
3	Val-0026865	22	6	Abnormal / Hemizygous
4	Val-0018480	14	6	Normal / Diploid
5	Val-0018585	4	0	Normal / Diploid
6	Val-0018540	2	6	Normal / Diploid

TABLE 5. Day 3, Run 3, Technologist 1

	CASE #	Hemizygous deletion (% of cells)	Homozygous deletion (% of cells)	FISH INTERPRETATION
1	Val-0020908	30	6	Abnormal / Hemizygous
2	Val-0022175	2	38	Abnormal/ Homozygous
3	Val-0026865	28	2	Abnormal / Hemizygous
4	Val-0018480	14	2	Normal / Diploid
5	Val-0018585	2	2	Normal / Diploid
6	Val-0018540	6	12	Normal / Diploid

TABLE 6. Day 3, Run 3, Technologist 2

	CASE #	Hemizygous deletion (% of cells)	Homozygous deletion (% of cells)	FISH INTERPRETATION
1	Val-0020908	32	6	Abnormal / Hemizygous
2	Val-0022175	10	30	Abnormal/ Homozygous
3	Val-0026865	24	0	Abnormal / Hemizygous
4	Val-0018480	12	4	Normal / Diploid
5	Val-0018585	0	0	Normal / Diploid
6	Val-0018540	10	6	Normal / Diploid

CLINICAL ACCURACY:

(Gleason 6-7)

Diagnostic Sensitivity =[20]

[20]+ [4] = 16.67%

Table 7.

VAL-0001132	Negative/Diploid
VAL-0001142	Negative/Diploid
VAL-0001152	Negative/Diploid
VAL-0001158	Negative/Diploid
VAL-0001204	Negative/Diploid
VAL-0002962	Negative/Diploid
VAL-0003074	Negative/Diploid
VAL-0004217	Negative/Diploid
VAL-0005732	Negative/Diploid
VAL-0006333	Hemizygous Positive
VAL-0006616	Negative/Diploid
VAL-0026059	Hemizygous Positive
VAL-0010531	Negative/Diploid
VAL-0026876	Hemizygous Positive
VAL-0027757	Negative/Diploid
VAL-0027669	Hemizygous Positive
VAL-0027758	Negative/Diploid
VAL-0028436	Negative/Diploid
VAL-0025618	Negative/Diploid
VAL-0025477	Negative/Diploid

CLINICAL ACCURACY:

(Gleason 8-9)

Diagnostic Sensitivity =

[20]

[20]+ [8] = 71.42%

Table 8.

VAL-0029477	Hemizygous Positive
VAL-0003074	Negative/Diploid
VAL-0006567	Negative/Diploid
VAL-0018499	Hemizygous Positive
VAL-0019274	Negative/Diploid
VAL-0019573	Hemizygous Positive
VAL-0026462	Homozygous Positive
VAL-0026865	Homozygous Positive
VAL-0026910	Negative/Diploid
VAL-0028404	Hemizygous Positive
VAL-0028491	Negative/Diploid
VAL-0028845	Hemizygous Positive
VAL-0008210	Negative/Diploid
VAL-0026340	Hemizygous Positive
VAL-0027758	Negative/Diploid
VAL-0027943	Hemizygous Positive
VAL-0028970	Homozygous Positive
VAL-0029662	Negative/Diploid
VAL-0007794	Hemizygous Positive
VAL-0028425	Homozygous Positive

CLINICAL ACCURACY:

(Benign Subset)

Diagnostic Specificity =

[20]

[20]+ [0] = 100.0%

Table 9.

VAL-0000080	Hemizygous Positive
VAL-0015564	Negative/Diploid
VAL-0015574	Negative/Diploid
VAL-0015577	Hemizygous Positive
VAL-0015578	Negative/Diploid
VAL-0015588	Hemizygous Positive
VAL-0015595	Homozygous Positive
VAL-0015615	Homozygous Positive
VAL-0015617	Negative/Diploid
VAL-0015662	Hemizygous Positive
VAL-0015636	Negative/Diploid
VAL-0015656	Hemizygous Positive
VAL-0015658	Negative/Diploid
VAL-0015663	Hemizygous Positive
VAL-0015682	Negative/Diploid
VAL-0015685	Hemizygous Positive
VAL-0015687	Homozygous Positive
VAL-0015825	Negative/Diploid
VAL-0015568	Hemizygous Positive
VAL-0022914	Homozygous Positive

CHAPTER VIII.

DISCUSSION

If we take the premise that FAS plays a role in at least one of the pathways to tumorigenesis, what might that look like? Whether it is the byproduct of some inherited genetic pattern that predisposes certain cells to transition into the progenitors of FAS deletions, PTEN deletions or the combination, or some environmental or epigenetic threshold, we ultimately end up with these mutated cells. One could image a stepwise progression where first a FAS gene is mutated absent of a concomitant PTEN deletion. This FAS deleted cell would be able to, by way of processes referenced above, escape apoptotic self-destruction and thrive, divide with ever more degrees of genetic instability until it reaches a critical mass whereby the proximal gene PTEN is lost as well. At this point not only has the cell attained the ability to escape cytotoxic T cell destruction, it has lost a major built in tumor suppressor stop gap system in the PTEN pathogenesis model. These cells now no longer have the cell cycle control mechanisms and proliferate aggressively, all the while going undetected by our cell mediated immunity. Conversely a larger deletion encompassing FAS and PTEN would presumably follow a similar evolution with the likelihood of a more rapid progression to the type of aggressive clonal populations seen in invasive PCA or reach a stage sandwiched between isolated inter-epithelial neoplasia and outright malignancy. This hypothetical transition point would be characterized by the rapid division of PTEN⁻/FAS⁻ cells which give way to significant genetic instability and thus harbor the classic signs of out-of-control chromosomal aneuploidy and/or polysomy.

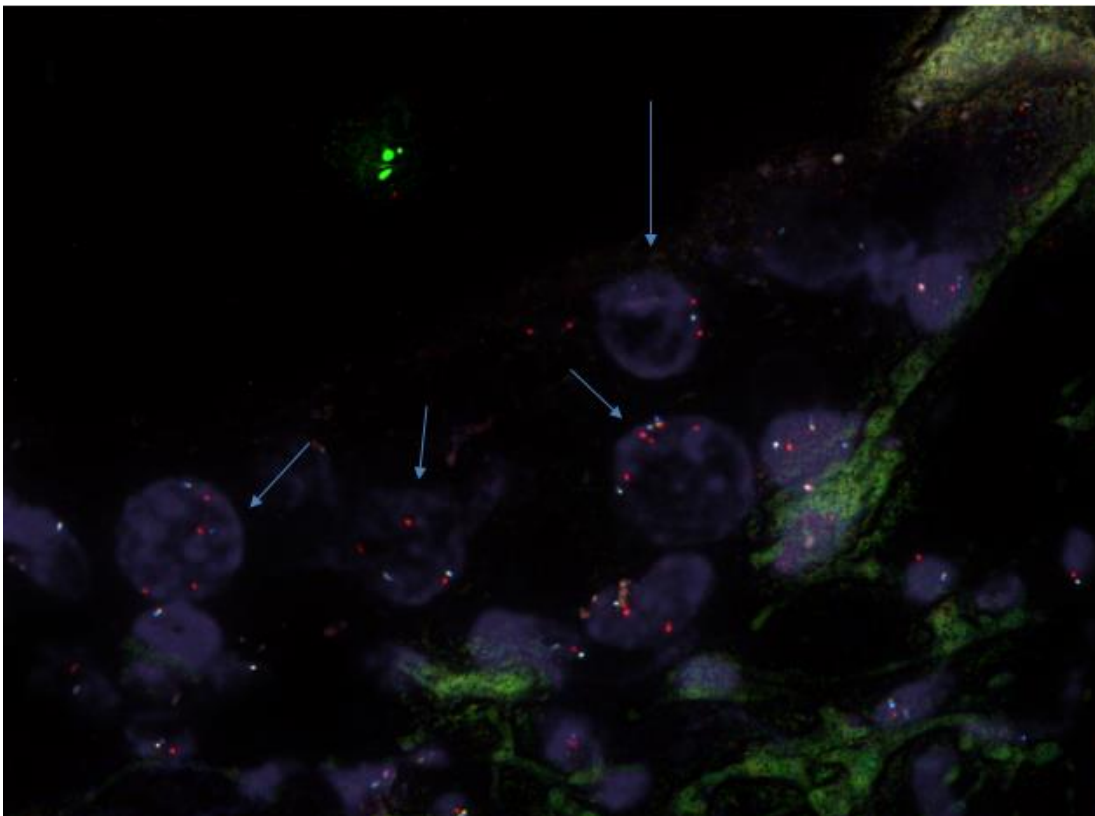
Although my sample size is limited and obviously affects the overall certainty of the study, there seems to be some evidence that this is a feasible explanation in that there is a simultaneous presence of clearly malignant prostate tumor cells having either heterozygous or hemizygous deletions of FAS and PTEN genes and the presence of massive prostate tumor cells with marked increases in chromosomes (polysomic genomes) and amplified genes (see fig.). Perhaps the best evidence for the progression of PTEN⁻/FAS⁻ or 10q23.2–10q23.3 is seen in figure 7, whereby both a population of single hemizygous PTEN⁻/FAS⁻ and the marked nuclear diameter sized nuclei with severe genetic instability or tumorigenicity having increases in genomes/genes across the whole genome.

In a recent study²¹ using SNP (Single Nucleotide Polymorphism) “Nex-Gen” sequencing, Ibeawuchi and colleagues elaborate on a direct connection between simultaneous deletion of both the PTEN and FAS gene and their role in aggressive Pca clonal subtypes. Their study included a long clinical follow-up period that ranged from 2.0–9.7 (mean 5.4) years. The sample size and the longitudinal nature of this research elicits confidence in my original belief that the two deletions are more than genomic coincidences. I believe it is worth noting that this published paper was released subsequently to my thesis statement and data collection. Moreover, limitations of quantitative experiments, in my opinion, are exposed here. In that, the end product of aggressive tumors relating to concomitant deletion of these two genes are clear in both my investigation and this published study, however the semi-quantitative nature of FISH microscopy allows for the morphological and the associated genomic marker changes which inform a more clear evolution of simple single deletion to the devastating simultaneous deletion of both genes—creating the dynamic tumor suppressor (PTEN) with inflammatory evading biochemistry (FAS).

This study strengthens my belief in the utility of real-time nucleic acid or polypeptide fluorescence reporter microscopy (e.g., confocal microscopy) or alternatively the step-wise “snap-shot” morphological/genomic changes seen in paraffin embedded FISH analysis. Knowing what happens visually allows for more efficient recognition of neoplastic anomalies such as the

one I anecdotally discovered and described in this project. PTEN, like other well researched tumor suppressor and oncogenes, plays a role in multiple neoplastic pathways in multiple tumor sites with presumably multiple cancer progression rates and clonal subtypes. The question, if validated, is there a recurrent or reproducible progression that can be detected to aid in treating this pathogenesis or even manipulated in order to prevent this disease out-right.

TABLE 7



CHAPTER IX.

CONCLUSION

This project was born from the observation that the four probe flanking construct that in theory would identify truncation (cutting off) artifact of portions of the chromosome of interest was not working as intended. That is, instead of there being red (Chromosome 10), green (WALPAL) and aqua (FAS) present with the gold or orange (PTEN) deleted in indicative cases, we consistently observed the red chromosomal copy control signal alone by itself. From this arose many questions. A key question from a clinical accuracy point-of-view was were these the result of wide spread massive truncation artifact (i.e. the cutting of the entire complement of PTEN, FAS and WALPAL) or something actually occurring in-situ. I think it is abundantly clear through the data sets that we have collected, that the pattern of clonal populations that have both morphological changes associated with prostatic adenocarcinoma and concurrent single copy control signals with the loss of all signals are not a coincidence. If you compare benign subsets to the aggressive metastatic subsets, you evolve from sporadic rare events of cells demonstrating this single copy control red signal to this condition being the norm and actually demarcating a given clonal population. I decided to make this my research after hearing that FAS was a key immunological gene. The connection between inflammation and cancer is becoming more apparent and my anecdotal work observations seem to fit into this newly found etiological player in neogenesis. The potential connection between these patterns genomically, morphologically or the type of cancer progression and the immune escape is exciting because further research and conformation of these connecting processes could offer deeper understanding of cancer's ability

to evolve and kill, and ultimately allow us to design better methods of diagnostics, prognostics and eventual treatment if not cures.

CITED REFERENCES

1. Nguyen P.L, Gu X., Lipsitz S. 2011, Cost Implications of the Rapid Adoption of Newer Technologies for Treating Prostate Cancer, *Clinical Oncology*, V29,#12, 1517-1524.
2. Watson JD, Crick FH, 1951 Molecular Structure of Nucleic Acids: A Structure for Deoxyribose Nucleic Acid, *Nature*. 171.
3. Gomori, G., 1941 Observations with differential stains on human islets of Langerhans. *Am J. Pathol* May, 395-406.
4. Coons AH, Creech HJ, Jones RN 1942. The demonstration of pneumococcal antigen in tissues by the use of fluorescent antibody. *J Immun.* 45:159-170.
5. Karnovsky MJ: Obituary—Dedication to Albert to Coons, 1912-1978. *J Histochem Cytochem* 22: 1117-1118.
6. Wu M, Singh SB, Chung CC, 2011, Antidiabetic and antisteatotic effects of the selective fatty acid synthase (FAS) inhibitor platensimycin in mouse models of diabetes. *Proc Natl Acad Sci USA* Mar 29; 108(13): 5378-83.
7. Hippocrates, The book of Prognostics 400 BCE.
8. Hunt JL, 2009, Biomarkers in Anatomical Pathology: Adding value to Diagnosis. *Archives of Pathology and Laboratory Medicine*, Apr. Vol. 133, No 4 532-536.
9. Dukes CE, The classification of cancer of the rectum. 1932, *J. Pathol. Bacteriol* 35:323-32.
10. Martin GS., 2004, The road to Src. *Oncogene* 23:7910-7917.
11. Rous P, 1910, A Transmissible Avian Neoplasm (Sarcoma of the Common Fowl), *J. Exp. Med.* 12 (5): 696-705.
12. Steck PA, Pershous MA, Jasser SA, 1997, Identification of a candidate tumour suppressor gene, MMAC1, at chromosomes 10q23.3 that is mutated in multiple advanced cancers. *Nature Genetics* 15:356-362.
13. Chu EC, Tarnawski AS, 2004, PTEN regulatory functions in tumor suppression and cell biology. *Med Sci Monit*, Oct; 10(10):RA235-41.
14. Yoshimoto M, Ding K, Sweet J, Squire J, 2012, PTEN losses exhibit heterogeneity in multifocal prostatic adenocarcinoma and are associated with higher Gleason grade. *Mod Pathol* 26: 435-447 10.1038.
15. Troyer DA, Squire JA, 2015, A multicenter study shows PTEN deletion is strongly associated with seminal vesicle involvement and extracapsular extension in localized prostate cancer. *Prostate*, Aug. 1:75(11):1206-15.
16. Cooke EW, Shrieve DC, Tward JD. 2012 Clinical versus pathologic staging for prostate adenocarcinoma: how do they correlate? *Am J Clin Oncol.* Aug;35(4):364-8.
17. Trauth BC, Klas C, Peters AMJ, Matzuka S, 1989. Monoclonal Antibody-Mediated Tumor Regression by Induction of Apoptosis. *Science, New Series*, Vol. 245 No 4915 (Jul) 301-305.
18. Waring P, Mullbacher A, 1999. Cell death induced by the Fas/Fas ligand pathway and its role in pathology. *Immunol Cell Biol.* Aug; 77(4):312-7.
19. Bostwick DG. 1995, High grade prostatic intraepithelial neoplasia. The most likely precursor of prostate cancer. *Cancer Apr.* Vol 75(S7):1823-1836.
20. Takayama, TK, McMullen BA, Nelson PS, Matsumura M, Fujikkawa K. 2001, Characterization of hK4 (prostase), a prostate-specific serine protease: specific antigen (pro-PSA) and single-chain urokinase-type plasminogen activator and degradation of prostatic acid phosphatase. *Biochemistry*, Dec 18; 40(50): 15341-8.
21. Ibeawuchi C, Schmidt H, Voss R, Titze U, Abbas M, Neumann J, Eltze E, Hoogland AM, Brandt B and Semjonow Axel. Exploring Prostate Cancer Genome Reveals Simultaneous Losses of PTEN, FAS and PAPSS2 in Patients with PSA Recurrence after Radical Prostatectomy. *International Journal of Molecular Sciences*, 16, 3856-3869.

APPENDIX

NEAGATIVE SUBSET ENUMERATION DATA

FAS Hemizygous %	0.105
FAS Homozygous %	0.005
Total FAS Deletion %	0.11

PTEN Hemizygous %	0.08
PTEN Homozygous%	0
Total PTEN Deletion %	0.08

FAS Hemizygous %	0.11
FAS Homozygous %	0
Total FAS Deletion %	0.11

PTEN Hemizygous %	0.1
PTEN Homozygous%	0
Total PTEN Deletion %	0.1

FAS Hemizygous %	0
FAS Homozygous %	0
Total FAS Deletion %	0

PTEN Hemizygous %	0
PTEN Homozygous%	0
Total PTEN Deletion %	0

FAS Hemizygous %	0.145
FAS Homozygous %	0.015
Total FAS Deletion %	0.16

PTEN Hemizygous %	0.14
PTEN Homozygous%	0.01
Total PTEN Deletion %	0.15

FAS Hemizygous %	0.1
FAS Homozygous %	0
Total FAS Deletion %	0.1

PTEN Hemizygous %	0.065
PTEN Homozygous%	0
Total PTEN Deletion %	0.065

FAS Hemizygous %	0.07
FAS Homozygous %	0
Total FAS Deletion %	0.07

PTEN Hemizygous %	0.045
PTEN Homozygous%	0
Total PTEN Deletion %	0.045

FAS Hemizygous %	0.07
FAS Homozygous %	0
Total FAS Deletion %	0.07

PTEN Hemizygous %	0.045
PTEN Homozygous%	0
Total PTEN Deletion %	0.045

FAS Hemizygous %	0.09
FAS Homozygous %	0.005
Total FAS Deletion %	0.095

PTEN Hemizygous %	0.075
PTEN Homozygous%	0.005
Total PTEN Deletion %	0.08

FAS Hemizygous %	0.03
FAS Homozygous %	0.015
Total FAS Deletion %	0.045

PTEN Hemizygous %	0.03
PTEN Homozygous%	0
Total PTEN Deletion %	0.03

FAS Hemizygous %	0.04
FAS Homozygous %	0
Total FAS Deletion %	0.04

PTEN Hemizygous %	0.03
PTEN Homozygous%	0
Total PTEN Deletion %	0.03

GP14-1807F

GP14-1732D

GP14-1061G

GP14-1732E

GP14-1485F

GP14-1807E

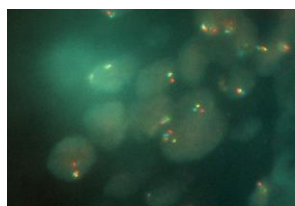
GP14-1485C

GP14-1997G

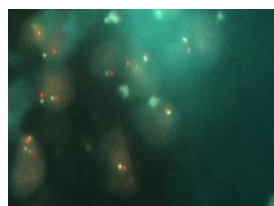GP14-1590C

GP14-2018I

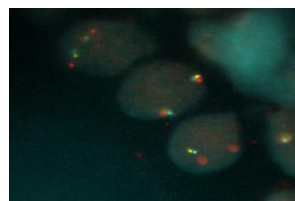
NEAGATIVE SUBSET ENUMERATION IMAGES



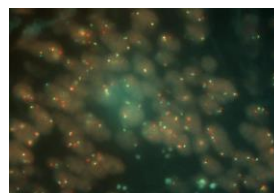
GP14-1807F



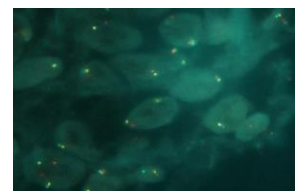GP14-1732D



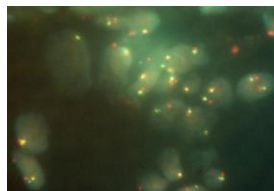
GP14-1061G



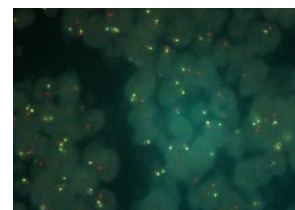
GP14-1732E



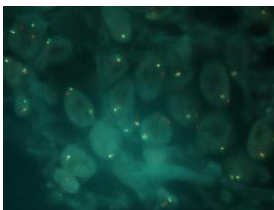
GP14-1485F



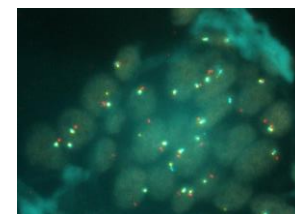
GP14-1807E



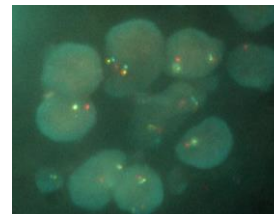GP14-1485C



GP14-1997G



GP14-1590C



GP14-2018I

Negative Subset and Threshold Cut-Off

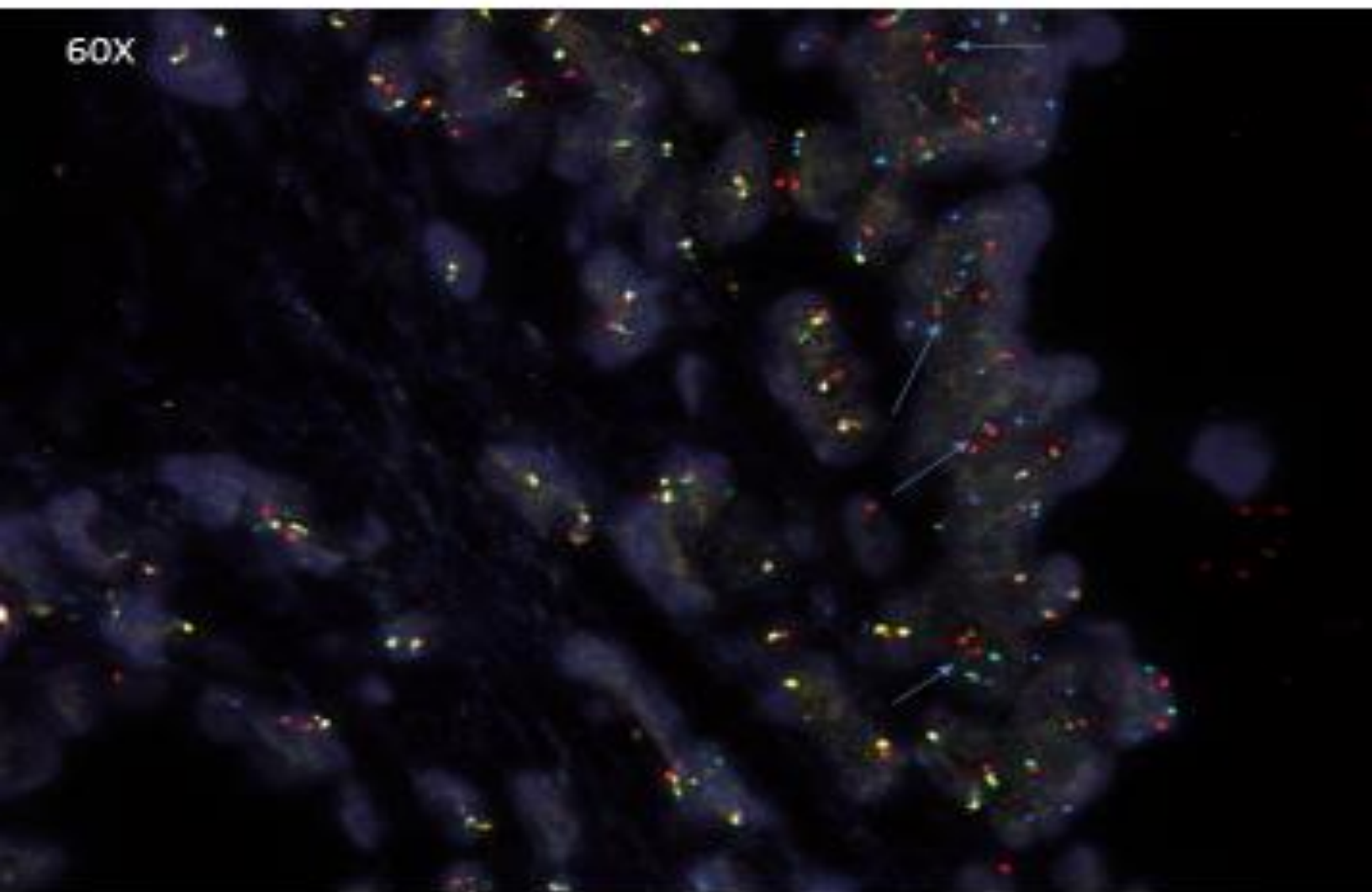
FAS/PTEN CUT-OFF

CASE	FAS HEMI DELETION	FAS HOMO DELETION	PTEN HEMI DELETION	PTEN HOMO DELETION
GP14-1807-F	21	1	16	0
GP14-1861-G	22	0	20	0
GP14-1485-F	0	0	0	0
GP14-1485-C	29	3	28	2
GP14-1590-C	20	0	13	0
GP14-1732-D	14	0	9	0
GP14-1732-E	14	0	9	0
GP14-1807-E	18	1	15	1
GP14-1997-G	6	3	6	0
GP14-2018-I	8	0	6	0
MEAN =	15.2	0.8	8	8
STANDARD DIVIATION=	8.638415483	1.229272584	8.024961059	0.674948558
2X ST DIV	17.27683099	2.458545189	16.04992212	1.349897115
3X ST DIV	25.91524648	3.687617788	24.07488318	2.024845673
PERCENTAGE CUT-OFF	26/200= 13%	4/200= 2%	24/200= 12%	2/200= 1%

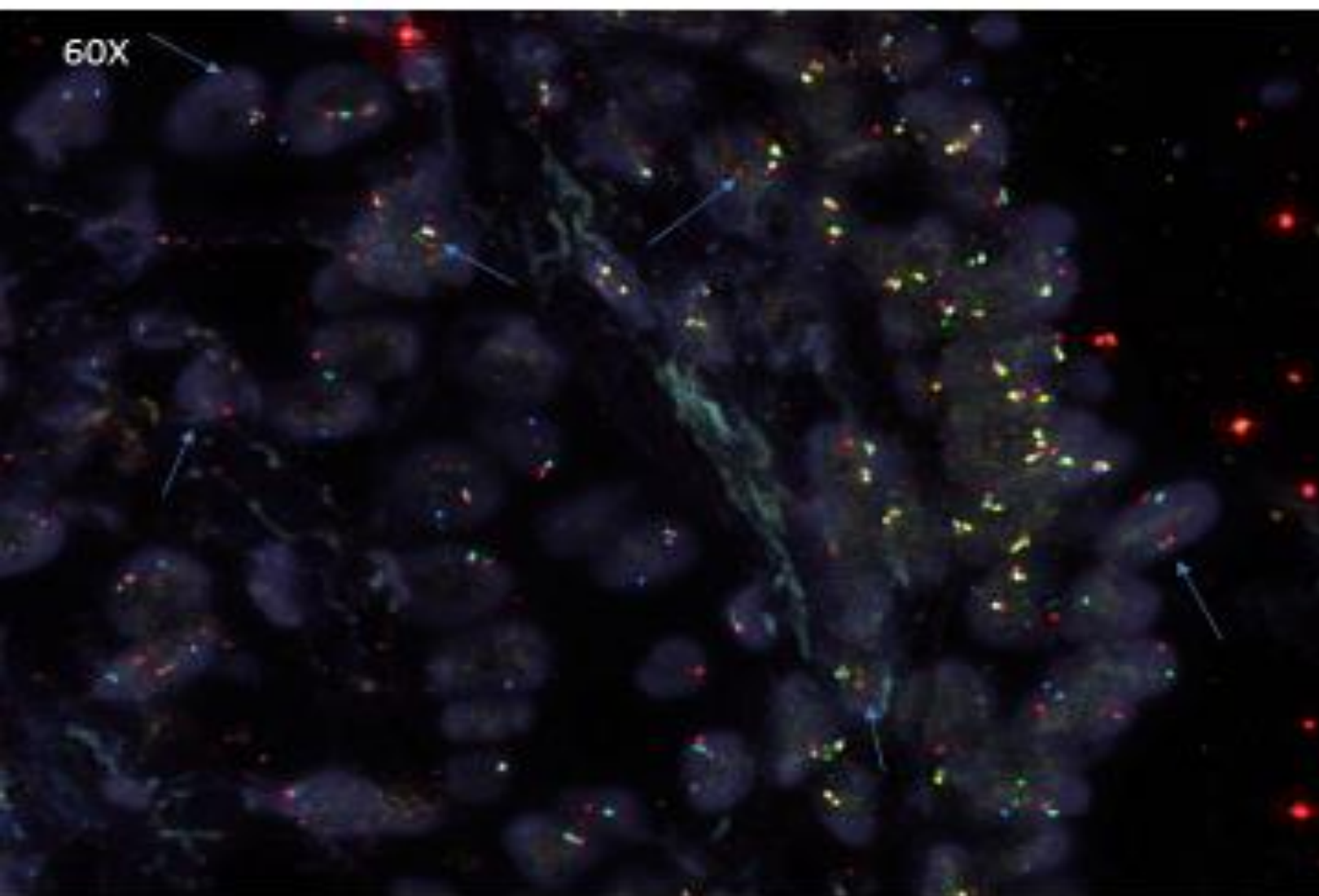
POSITIVE SUBSET

[REDACTED]		[REDACTED]-004224
DOB: 05-27-1935 Age: 79 Gender: Male Collected: 08-06-2014 Received: 08-07-2014		[REDACTED] [REDACTED] [REDACTED] [REDACTED] Fax: [REDACTED]
Clinical Info Summary Elevated PSA, Nodular Prostate w/o Urinary Obstruction	Diagnosis Summary Adenocarcinoma Involving 2 out of 6 cores. Highest Gleason 3+3=6. Chronic inflammation and Atrophy present Confirmed by PIN4 stain	<p> ● Malignant ■ Benign ▲ High grade PIN ◆ Atypical </p>
<p>Prostatic ca, H&E</p>	<p>Prostatic ca, PIN4 IHC.</p>	
Final Diagnosis (Left) A. Prostatic adenocarcinoma, Gleason 3 + 3 (score = 6), involving 30% of needle core, measuring 4.2 mm. B. Prostatic adenocarcinoma, Gleason 3 + 3 (score = 6), involving 30% of needle core, measuring 4.5 mm (Confirmed by PIN4 immunostain). C. Benign prostatic tissue with atrophy and chronic inflammation.		Final Diagnosis (Right) D. Benign prostatic tissue. E. Benign prostatic tissue with atrophy. F. Benign prostatic tissue with chronic inflammation.
Notes: Per protocol PTEN FISH pending with separate report to follow.		
Gross Description Specimens are received in formalin, labeled with patient's name, anatomic pathology number and location, and consist of pale tan portion(s) of cylindrical tissue 1 mm. in diameter and with lengths stated as below:		
<u>Left</u>		<u>Right</u>
A. 14mm	C. 12mm	D. 10mm
B. 15mm		E. 10mm
		F. 13mm

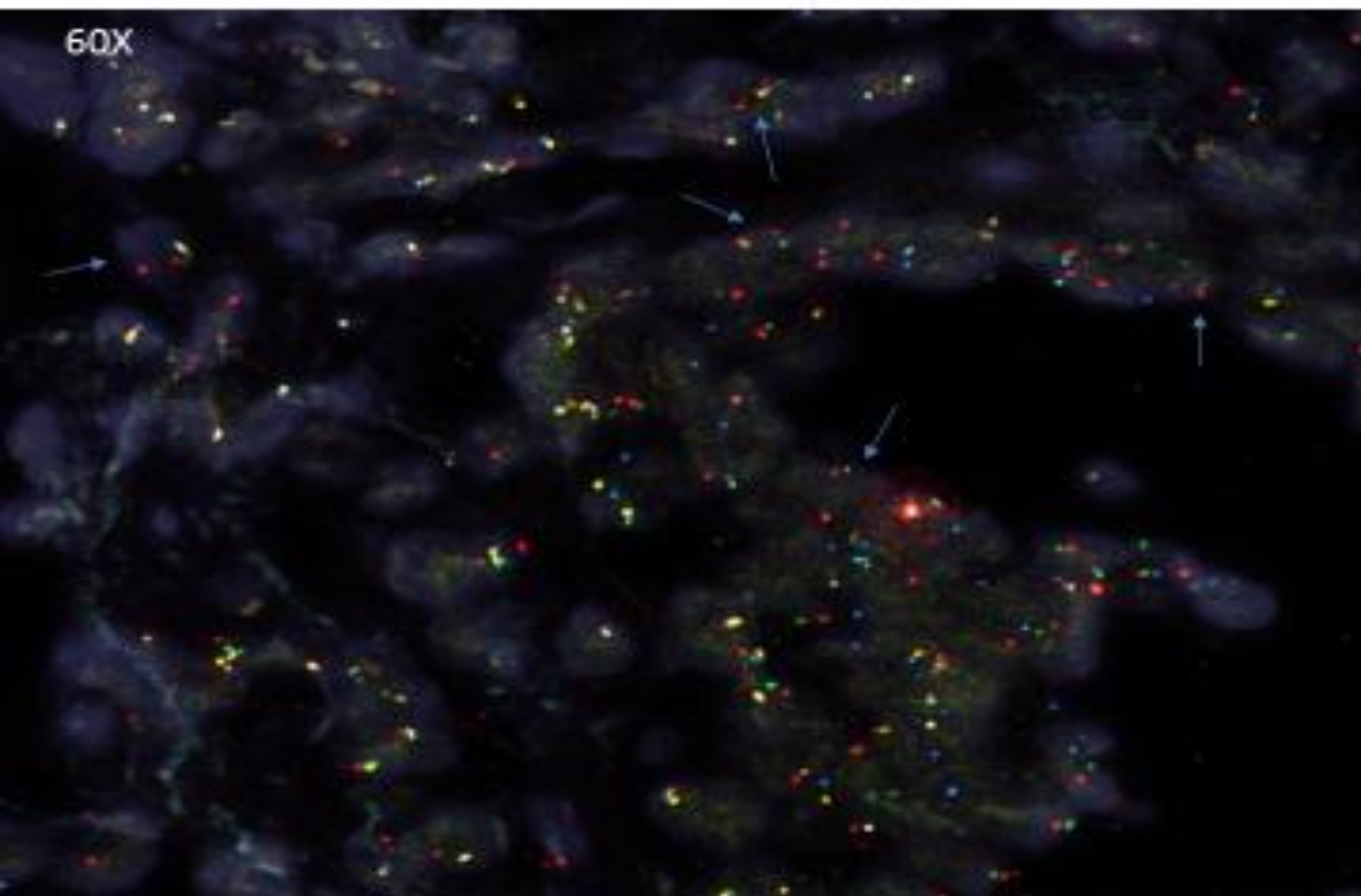
FOV 1 COMBINED 4224B



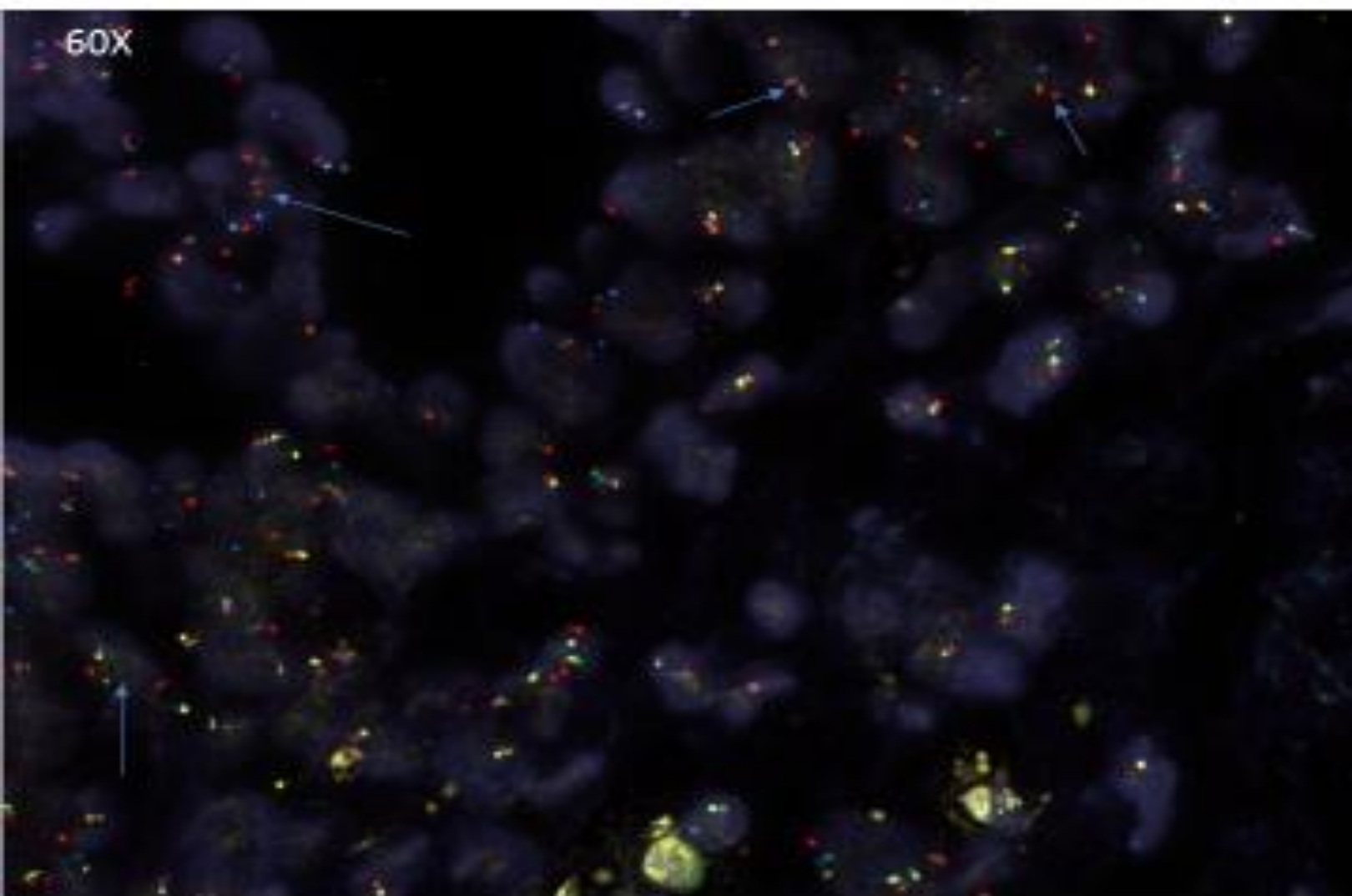
FOV 2 COMBINATION 4224B



FOV 3 COMBINED 4224B



FOV 4 COMBINED 4224B



FAS Enumeration Chart

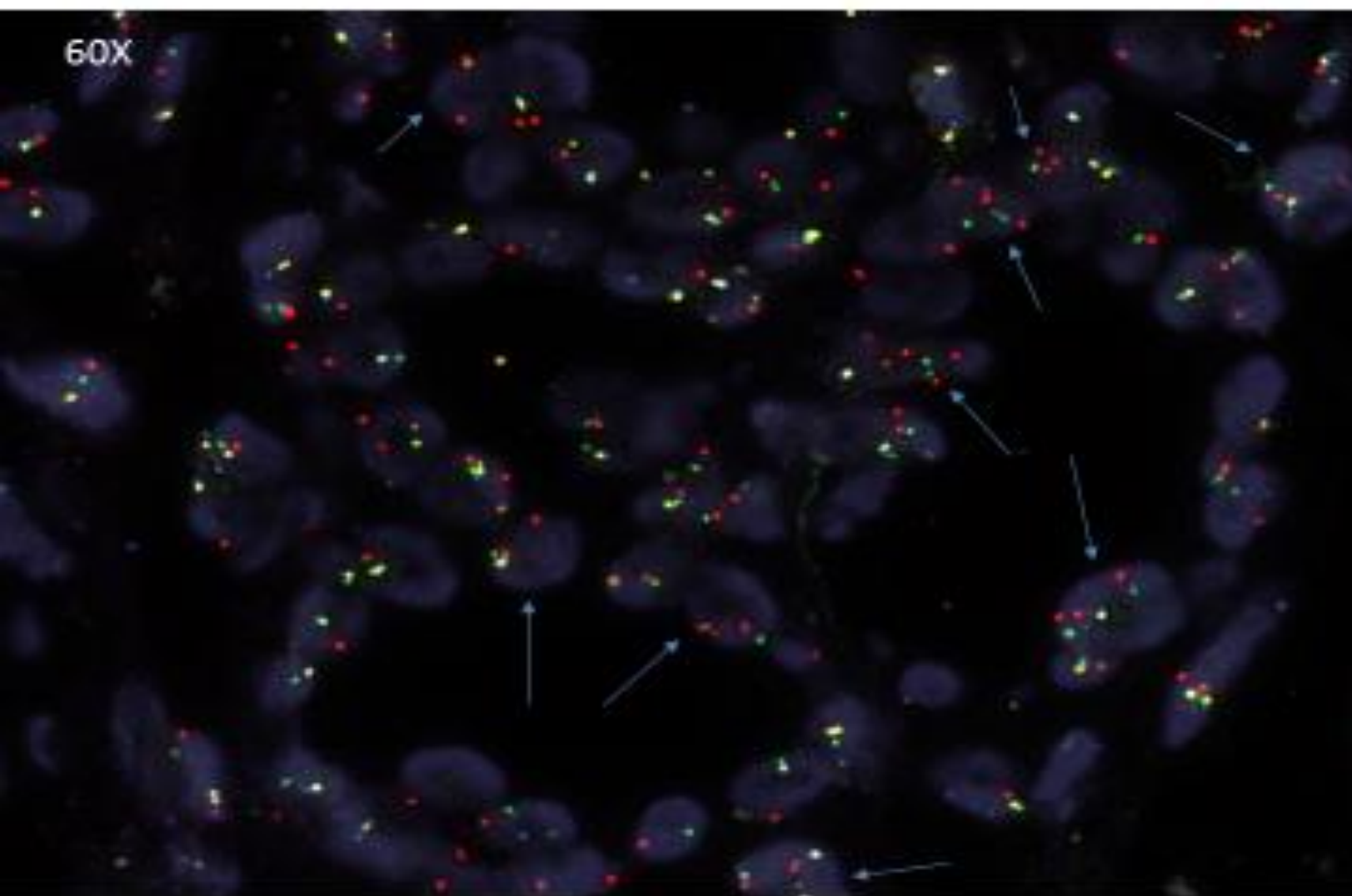
SLIDE ID		4224B			FAS	FAS	FAS	PTEN	PTEN	PTEN
CH1	CEP10	FAS	PTEN	FAS	FAS	FAS	PTEN	PTEN	PTEN	
	(HELO)	(ALQA)	(GQD)	Hemi	Homo	Normal	Hemi	Homo	Normal	
1	2	2	2			X			X	
2	2	2	2			X			X	
3	2	1	1	X			X			
4	2	1	1	X			X			
5	2	2	2			X			X	
6	2	2	2			X			X	
7	2	1	1	X			X			
8	2	2	2			X			X	
9	2	1	0	X				X		
10	2	2	2			X			X	
11	2	2	2			X			X	
12	2	1	1	X			X			
13	2	1	0	X				X		
14	2	2	2			X			X	
15	2	2	2			X			X	
16	2	2	2			X			X	
17	2	1	1	X			X			
18	2	2	2			X			X	
19	2	1	1	X			X			
20	2	1	1	X			X			
21	2	2	2			X			X	
22	2	2	2			X			X	
23	2	2	2			X			X	
24	2	1	0	X					X	
25	2	2	2			X			X	
26	2	2	2			X			X	
27	2	1	0	X				X		
28	2	1	1	X			X			
29	2	2	2			X			X	
30	2	1	1	X			X			
31	2	2	2			X			X	
32	2	2	2			X			X	
33	2	2	2			X			X	
34	2	2	2			X			X	
35	2	2	2			X			X	
36	2	2	2			X			X	
37	2	1	1	X			X			
38	2	2	2			X			X	
39	2	1	0	X				X		
40	2	1	1	X			X			
41	2	2	2			X			X	
42	2	2	2			X			X	
43	2	1	1	X			X			
44	2	2	2			X			X	
45	2	2	2			X			X	
46	2	1	1	X			X			
47	2	2	2			X			X	
48	2	2	2			X			X	
49	2	1	1	X			X			
50	2	2	2			X			X	
				19	0	31	14	4	32	

FAS Hemi zygous %	0.38
FAS Homo zygous %	0
Total FAS Deletion %	0.38

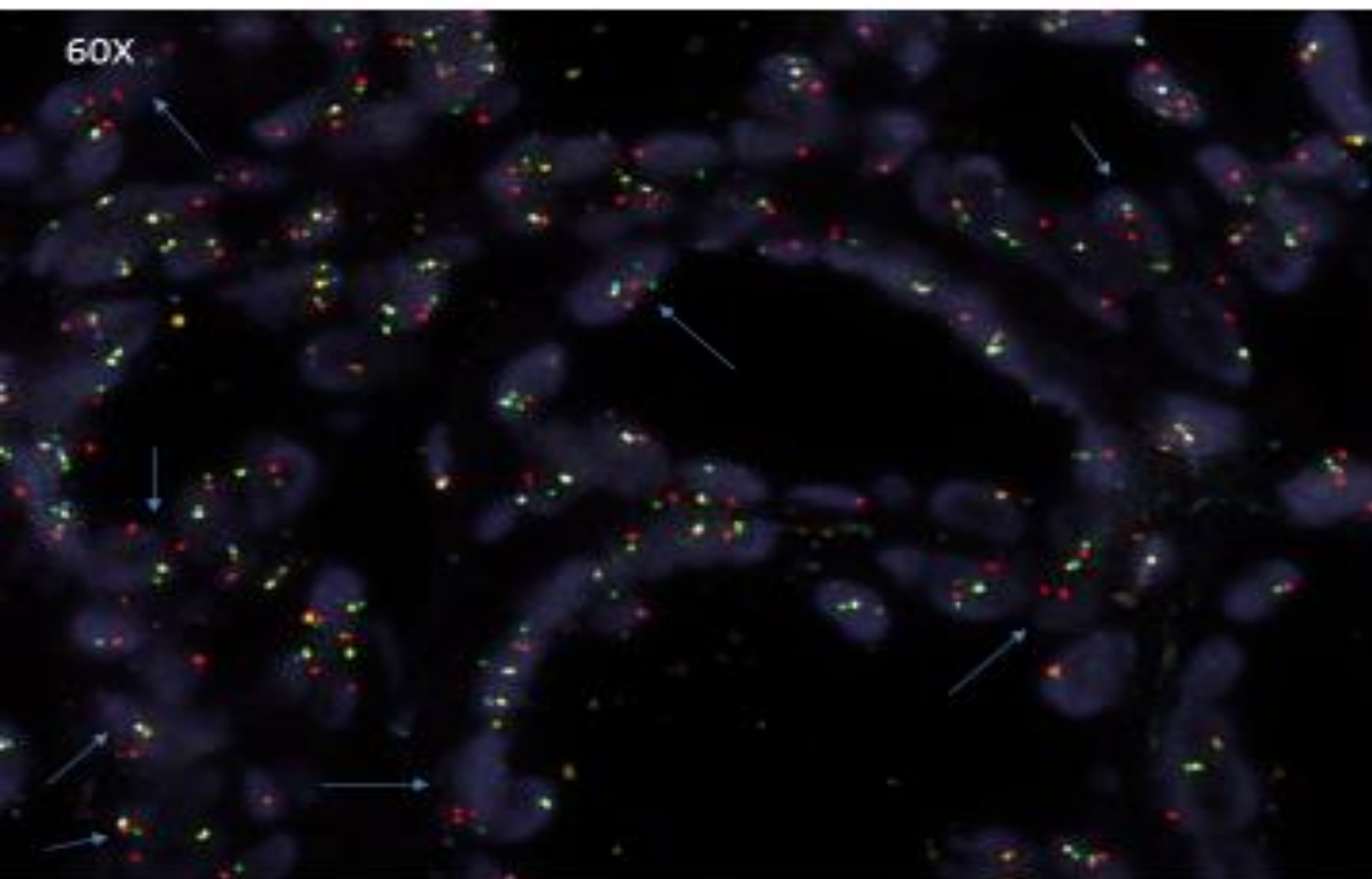
PTEN Hemi zygous %	0.28
PTEN Homo zygous %	0.08
Total PTEN Deletion %	0.36

[REDACTED]		[REDACTED]-006291	
DOB: 03-27-1942 Age: 72 Gender: Male Collected: 12-30-2014 Received: 12-31-2014		[REDACTED] MD [REDACTED] Urology Group - [REDACTED] [REDACTED] [REDACTED] Phone: [REDACTED] Fax: [REDACTED]	
Clinical Info Summary Elevated PSA of 10.6	Diagnosis Summary Small focus of Adenocarcinoma Gleason score 3+3 (6) involving 1 out of 12 specimen No perineural invasion is seen.		
Specimen J	Specimen J		
Final Diagnosis (Left) A. Focal high-grade prostatic intraepithelial neoplasia (PIN). B. Benign prostatic tissue. C. Benign prostatic tissue. G. Benign prostatic tissue. H. Benign prostatic tissue. I. Benign prostatic tissue.		Final Diagnosis (Right) D. Benign prostatic tissue. E. Benign prostatic tissue. F. Benign prostatic tissue. J. Small focus of prostatic adenocarcinoma, Gleason score 3 + 3 (6), involving less than 5% of total tissue volume, measuring 0.6 mm (Confirmed by a cocktail of immunohistochemical stains for high molecular weight cytokeratin, P63 and racemase). K. Benign prostatic tissue. L. Benign prostatic tissue.	
Notes: Technical component performed at GoPath Laboratories, LLC, 1351 Barclay Boulevard, Buffalo Grove, IL 60089 (855)GOPATH9. Professional component performed by Masoud Ganji, MD, North Shore Pathologists, SC, 13111 North Port Washington Road, Mequon, WI 53097 (262) 243-7423. Microscopic examination performed. Case reviewed at the departmental QA conference.			
Gross Description Specimens are received in formalin, labeled with patient's name, anatomic pathology number and location, and consist of			

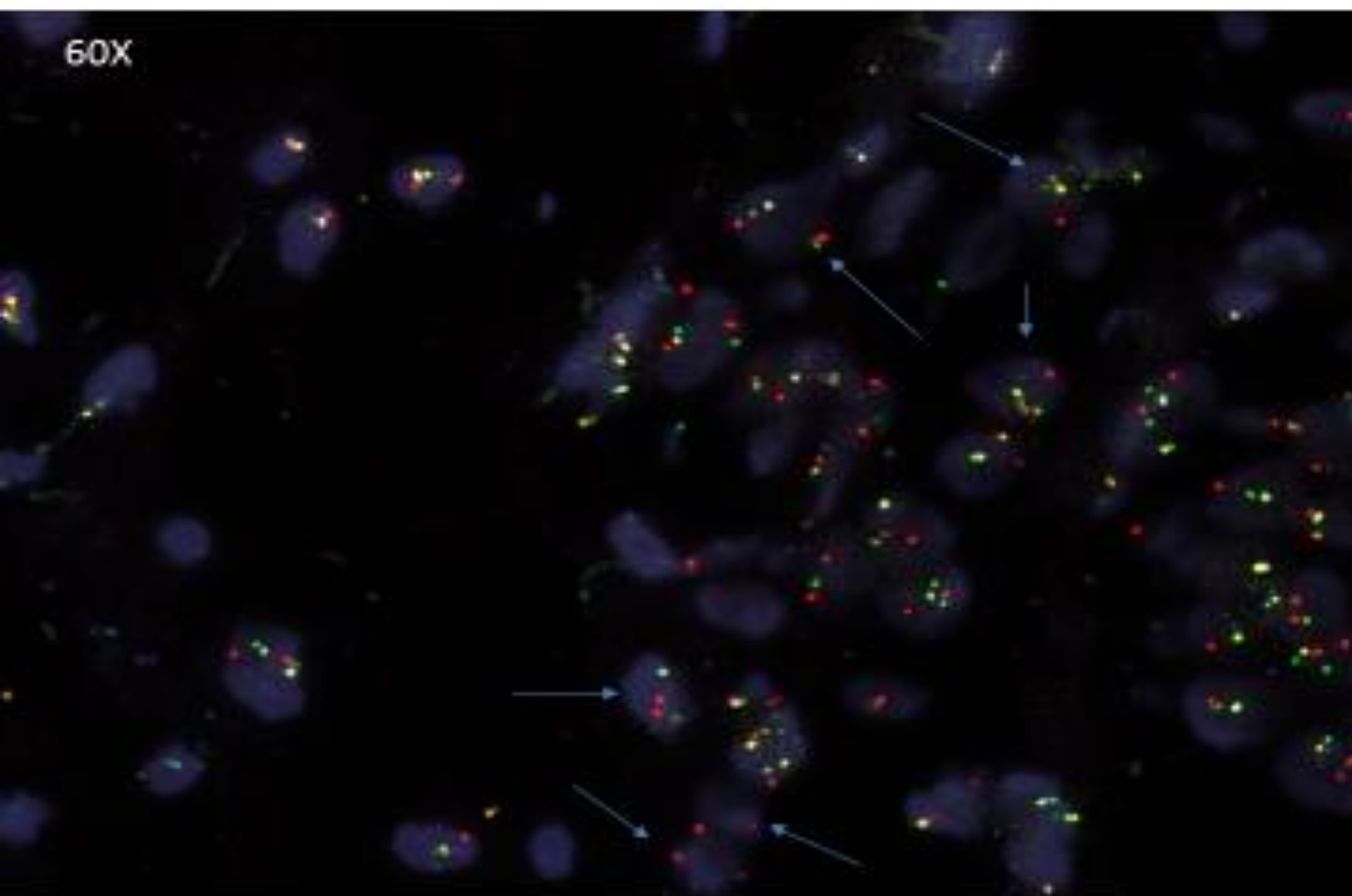
FOV 1 COMBINED 6291-J



FOV 2 COMBINED 6291J



FOV 3 COMBINED 6291J



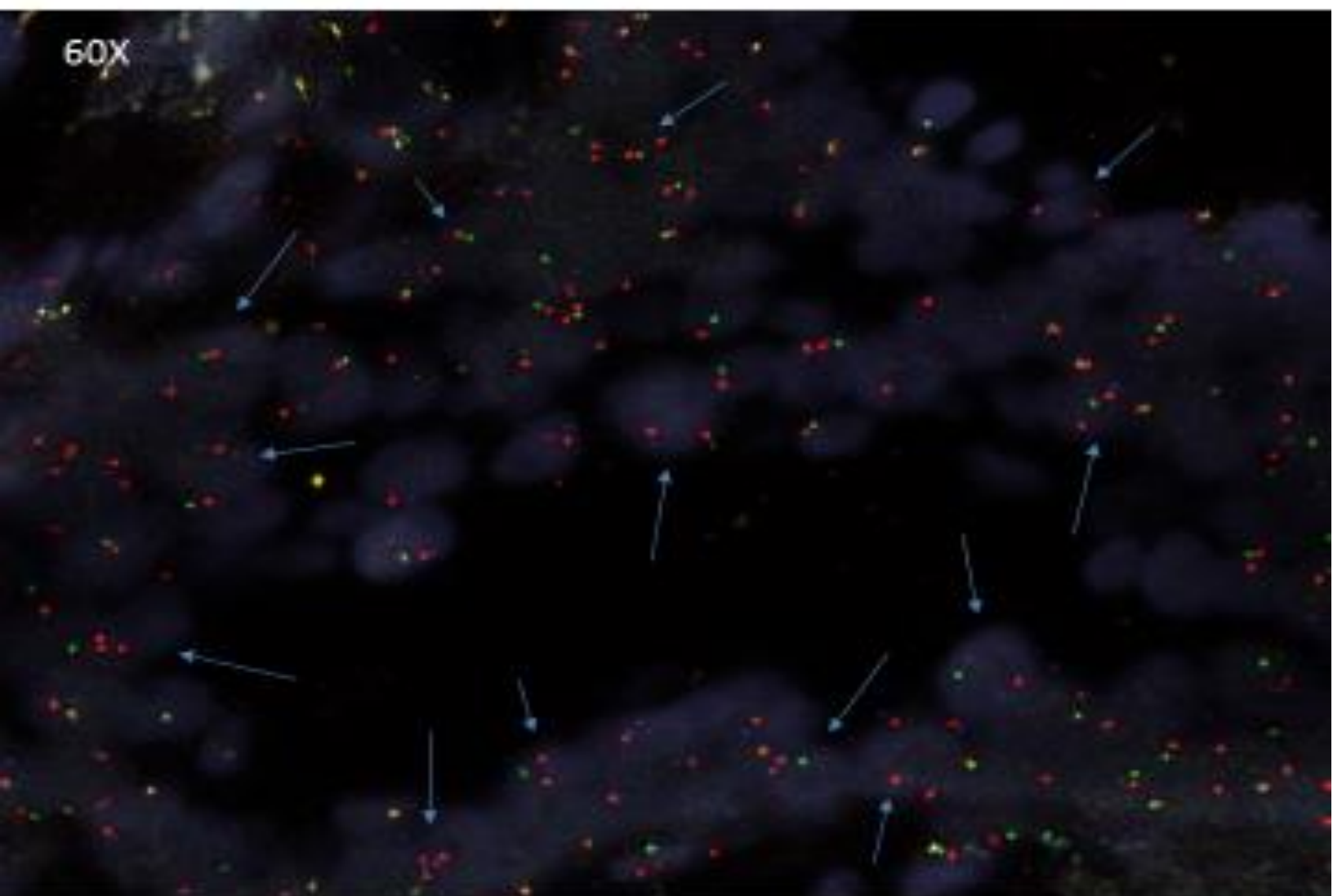
FAS Enumeration Chart

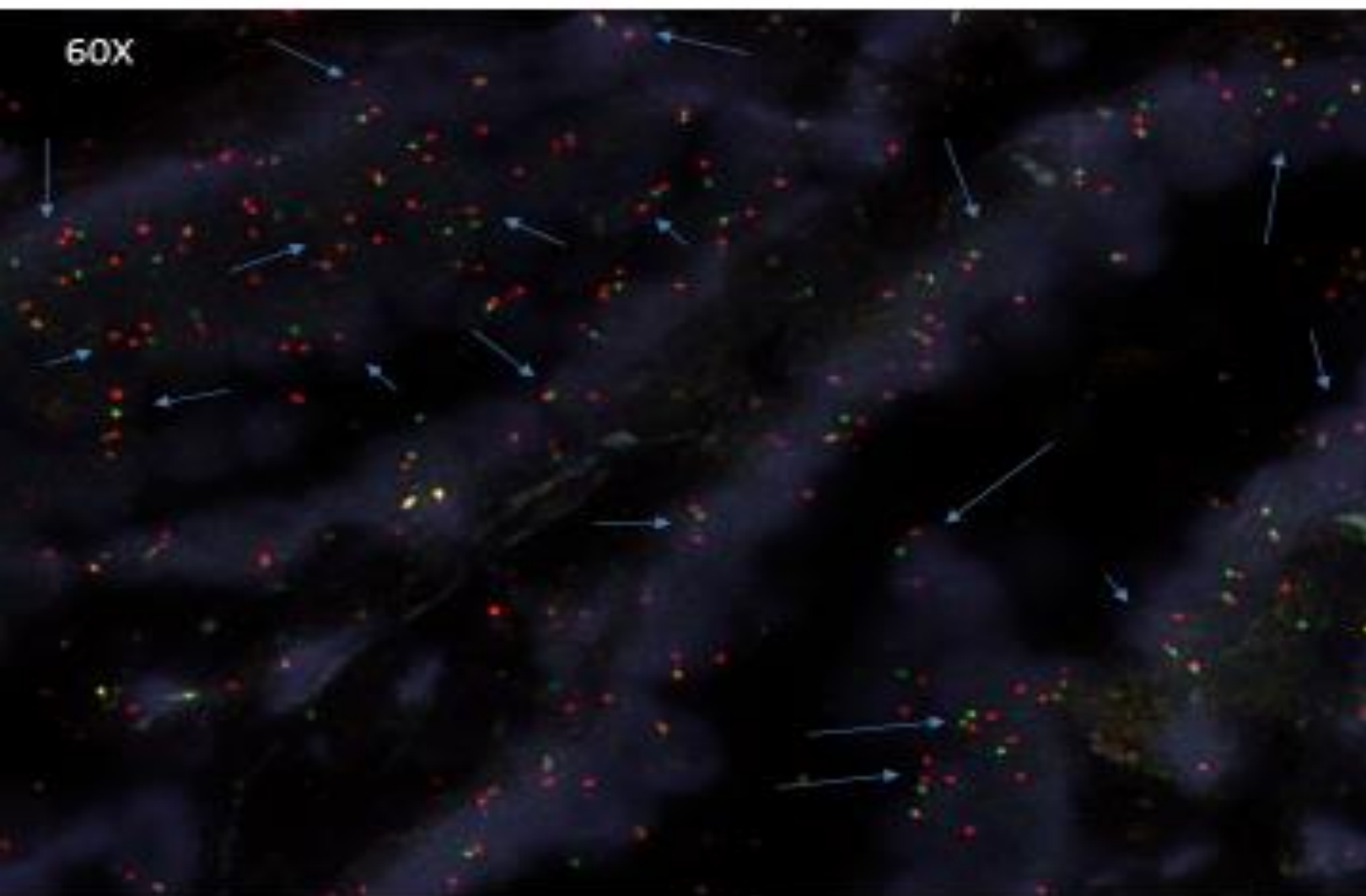
SLIDE ID		6291-I							
Cell	Cell ID	FAS	PTEN	FAS	FAS	FAS	PTEN	PTEN	PTEN
	(RED)	(BLUE)	(GREEN)	NORM	NORM	NORM	HEMI	HOMO	NORMAL
1	2	0	1		X		X		
2	2	2	2			X			X
3	2	2	2			X			X
4	2	0	0		X			X	
5	2	2	2			X			X
6	2	2	2			X			X
7	2	2	2			X			X
8	2	1	1	X			X		
9	2	2	2			X			X
10	2	2	2			X			X
11	2	2	2			X			X
12	2	0	0		X			X	
13	2	2	2			X			X
14	2	2	2			X			X
15	2	2	2			X			X
16	2	2	2			X			X
17	2	1	1	X			X		
18	2	2	2			X			X
19	2	2	2			X			X
20	2	2	2			X			X
21	2	0	0		X			X	
22	2	0	0		X			X	
23	2	2	2			X			X
24	2	2	2			X			X
25	2	2	2			X			X
26	2	2	2			X			X
27	2	2	2			X			X
28	2	1	1	X			X		
29	2	2	2			X			X
30	2	2	2			X			X
31	2	0	0		X			X	
32	2	2	2			X			X
33	2	2	2			X			X
34	2	1	1	X			X		
35	2	2	2			X			X
36	2	0	0		X			X	
37	2	2	2			X			X
38	2	1	1	X			X		
39	2	0	0		X			X	
40	2	2	2			X			X
41	2	0	0		X			X	
42	2	2	2			X			X
43	2	1	1	X			X		
44	2	1	1	X			X		
45	2	1	1	X			X		
46	2	1	1	X			X		
47	2	1	1	X			X		
48	2	1	1	X			X		
49	2	0	0		X			X	
50	2	2	2			X			X
				11	20	29	14	9	29

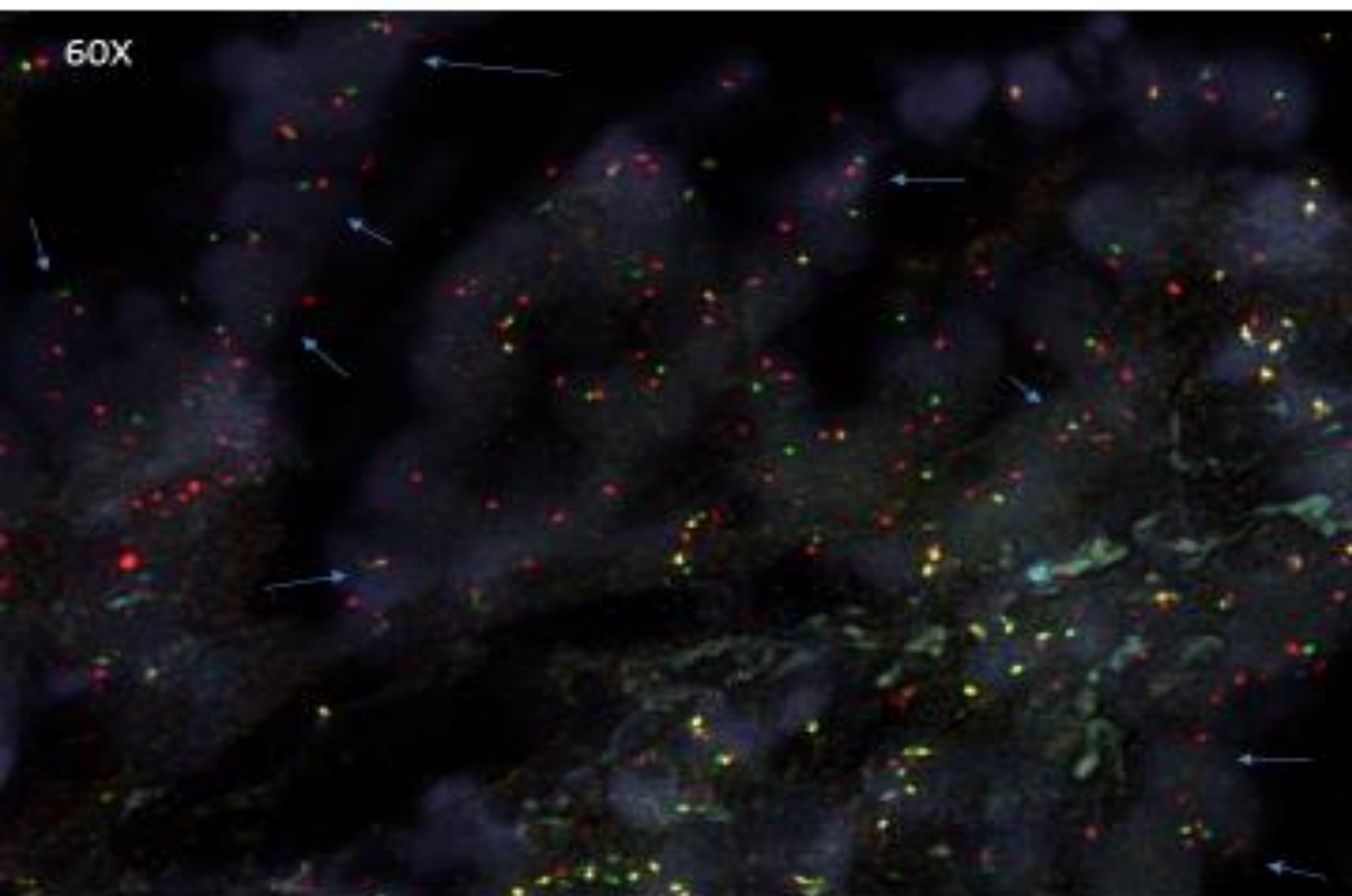
FAS Hemi-zygous %	0.22
FAS homo-zygous %	0.2
Total FAS Deletion %	0.42

PTEN Hemi-zygous %	0.24
PTEN homo-zygous %	0.28
Total PTEN Deletion %	0.52

[REDACTED]		[REDACTED] 006113			
Age: 67 Gender: Male Collected: 12-17-2014 Received: 12-18-2014		John Matteucci, MD John C. Matteucci, Jr., MD S/C 6127 Green Bay Road Suite 600 Kenosha, WI 53142 Phone: 262-653-9221 Fax: 262-653-9229			
Clinical Info Summary Last total PSA 6.3	Diagnosis Summary Adenocarcinoma Involving 8 out of 12 specimens. Highest Gleason 3+3=6. Perineural invasion is seen.				
 Specimen A	 Specimen B	Final Diagnosis (Left) A. Prostatic adenocarcinoma, Gleason 3 + 3 (score = 6), involving 70% of needle core, measuring 5 mm. Perineural invasion seen. B. Prostatic adenocarcinoma, Gleason 3 + 3 (score = 6), involving 95% of needle core, measuring 5 mm. Perineural invasion seen. C. Prostatic adenocarcinoma, Gleason 3 + 3 (score = 6), involving 60% of needle core, measuring 4 mm. G. Prostatic adenocarcinoma, Gleason 3 + 3 (score = 6), involving 60% of needle core, measuring 4 mm. Perineural invasion seen. H. Prostatic adenocarcinoma, Gleason 3 + 3 (score = 6), involving 95% of needle core, measuring 5 mm. Perineural invasion seen. I. Prostatic adenocarcinoma, Gleason 3 + 3 (score = 6), involving 70% of needle core, measuring 3 mm.		Final Diagnosis (Right) D. Benign prostatic tissue. E. Focus of atypical glands, suspicious for adenocarcinoma. F. Prostatic adenocarcinoma, Gleason 3 + 3 (score = 6), involving less than 5% of needle core, measuring 0.2 mm. J. Benign prostatic tissue. K. Prostatic adenocarcinoma, Gleason 3 + 3 (score = 6), involving 5% of needle core, measuring 0.3 mm. L. Focus of atypical glands, suspicious for adenocarcinoma.	
Notes: Technical component performed at GoPath Laboratories, LLC, 1351 Barclay Boulevard, Buffalo Grove, IL 60089 (855)00PATH9. Professional component performed by Masoud Ganj, MD, North Shore Pathologists, SC, 13111 North Port Washington Road, Mequon, WI 53097 (262) 243-7423. Microscopic examination performed. Case reviewed at the departmental QA conference.					
Gross Description Specimens are received in formalin, labeled with patient's name, anatomic pathology number and location, and consist of pale tan portion(s) of cylindrical tissue 1 mm. in diameter and with lengths stated as below.					

FOV 1 (#1) COMBINATION 6113B

FOV 1 (#2) COMBINATION 6113B

FOV 2 (#2) COMBINATION 6113B

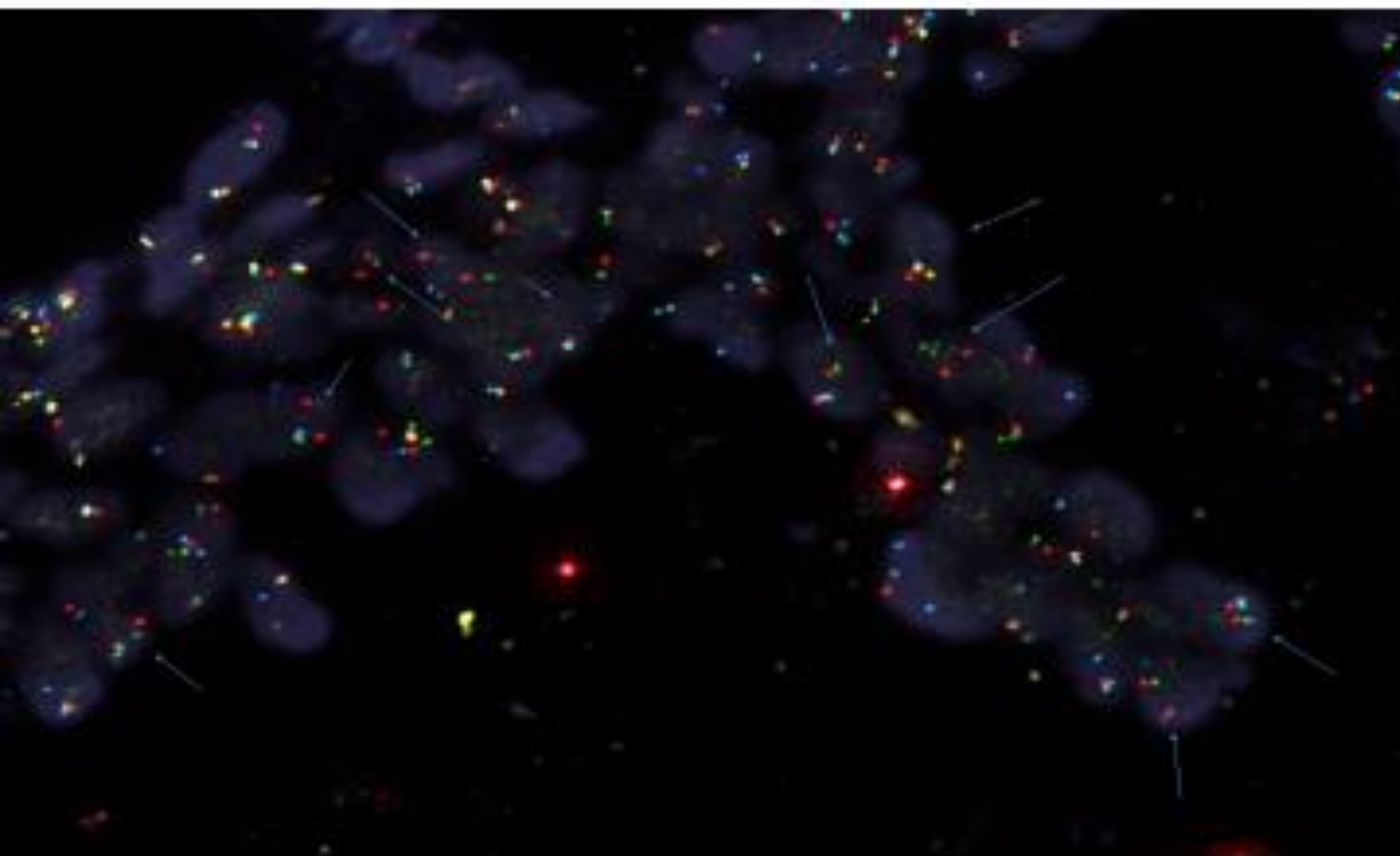
FAS Enumeration Chart

SLIDE ID		6113-B			FAS	FAS	PTEN	PTEN	PTEN
Cell	CEP ID	FAS	PTEN	FAS	FAS	FAS	PTEN	PTEN	PTEN
	Color	Normal	Loss	Hemiz	Normal	Normal	Hemiz	Normal	Normal
1	2	2	2			X			X
2	2	1	0	X				X	
3	2	2	2			X			X
4	2	2	2			X			X
5	2	2	2			X			X
6	2	1	0	X				X	
7	2	1	0	X				X	
8	2	1	0	X				X	
9	2	0	0		X			X	
10	2	2	2			X			X
11	2	1	0	X				X	
12	2	1	0	X				X	
13	2	2	2			X			X
14	2	0	0		X			X	
15	2	1	0	X				X	
16	2	1	0	X				X	
17	2	1	0	X				X	
18	2	1	0	X				X	
19	2	1	0	X				X	
20	2	2	2			X			X
21	2	0	0		X			X	
22	2	1	1	X			X		
23	2	1	0	X				X	
24	2	2	2			X			X
25	2	1	0	X				X	
26	2	1	1	X			X		
27	2	0	0		X			X	
28	2	1	0	X				X	
29	2	1	0	X				X	
30	2	1	1	X			X		
31	2	1	0	X				X	
32	2	1	0	X				X	
33	2	2	2			X			X
34	2	1	1	X			X		
35	2	2	0			X		X	
36	2	1	0	X				X	
37	2	2	0			X		X	
38	2	2	0			X		X	
39	2	1	1	X			X		
40	2	1	0	X				X	
41	2	1	0	X				X	
42	2	2	0			X		X	
43	2	1	2	X				X	
44	2	1	0	X				X	
45	2	1	1	X			X		
46	2	1	0	X				X	
47	2	1	0	X				X	
48	2	2	2			X			X
49	2	2	0			X		X	
50	2	2	2			X			X
				30	4	15	5	32	27

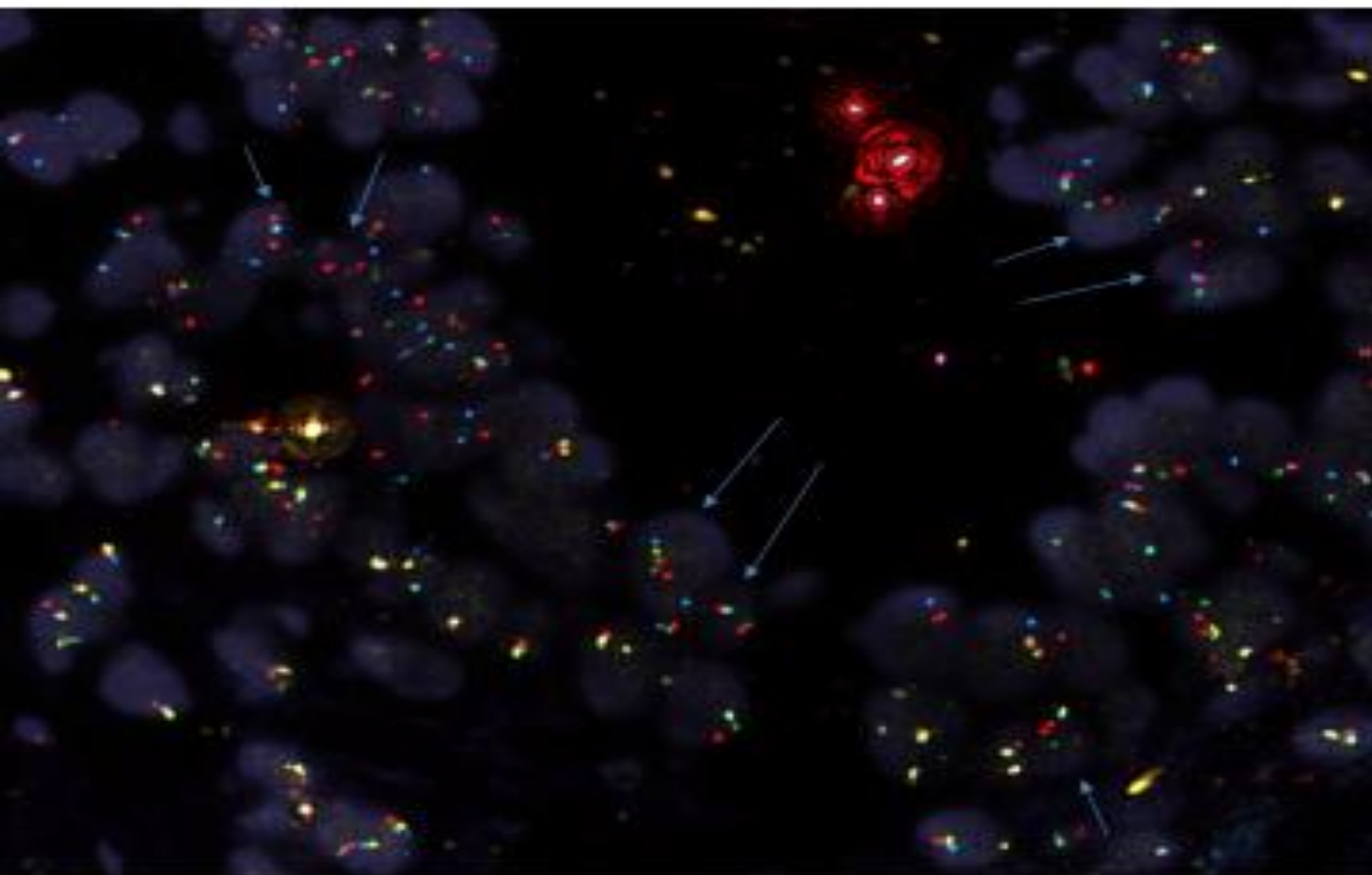
FAS Hemizygous %	0.33
FAS homozygous %	0.00
Total FAS Deletion %	0.33

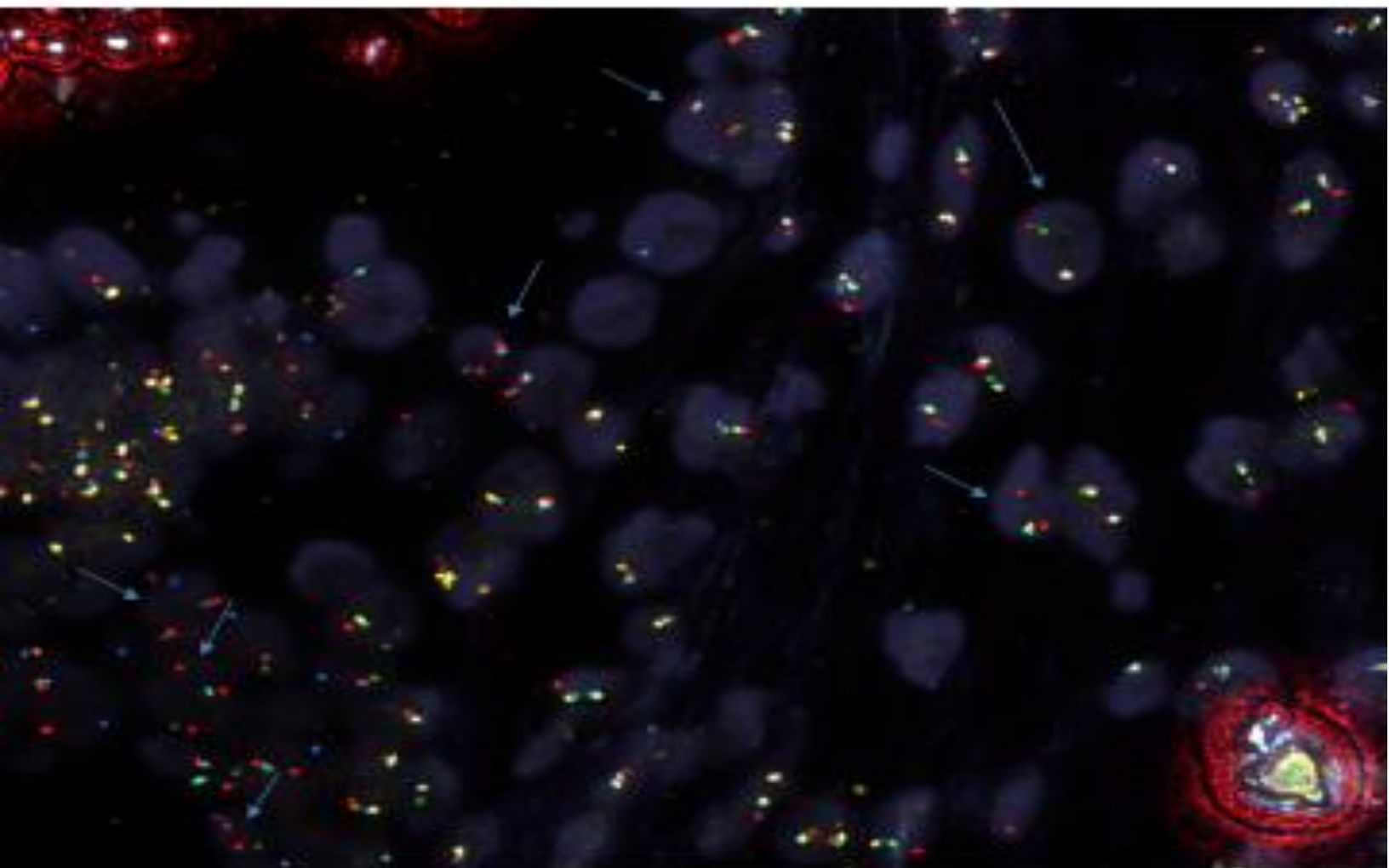
PTEN Hemizygous %	0.12
PTEN homozygous %	0.00
Total PTEN Deletion %	0.12

[REDACTED]		[REDACTED]-002740 H	
DOB: 01-23-1942 Age: 72 Gender: Male Collected: 05-05-2014 Received: 05-05-2014		[REDACTED] [REDACTED] [REDACTED] Kankakee, IL 60901-3679 Phone: 815-937-2128 Fax: 815-937-2102	
Clinical Info Summary Elevated PSA 6.36	Diagnosis Summary Adenocarcinoma Involving 1 out of 12 cores. Highest Gleason 3+3=6. -Chronic inflammation present -Confirmed by PIN4 stain	<p> ● Malignant ■ Benign ■ High grade PIN ◆ Atypical </p>	
<p>Prostatic Ca, H&E</p>	<p>Prostatic Ca, PIN4 IHC.</p>		
Final Diagnosis (Left) A. Benign prostatic tissue. B. Benign prostatic tissue. C. Benign prostatic tissue with acute inflammation. G. Benign prostatic tissue with chronic inflammation (Confirmed by PIN4 immunostain). H. Prostatic adenocarcinoma, Gleason 3 + 3 (score = 6), multifocal, involving 5% of needle core, measuring 0.5 mm (Confirmed by PIN4 immunostain). I. Benign prostatic tissue.		Final Diagnosis (Right) D. Benign prostatic tissue. E. Benign prostatic tissue with chronic inflammation. F. Benign prostatic tissue. J. Benign prostatic tissue. K. Benign prostatic tissue. L. Benign prostatic tissue with chronic inflammation.	
Notes: The adenocarcinoma found is small but multifocal. PIN4 IHC shows strong cytoplasmic staining for raseinase and loss of basal layer. These findings support the diagnosis. Clinical correlation would be helpful. Per protocol, PTEN FISH will be performed with a report to follow.			
Gross Description Specimens are received in formalin, labeled with patient's name, anatomic pathology number and location, and consist of pale tan portion(s) of cylindrical tissue 1 mm. in diameter and with lengths stated as below:			
<u>Left</u>		<u>Right</u>	
A. 15 mm	G. 18 mm	D. 13 mm	J. 16 mm
B. 17 mm	H. 19 mm	E. 14 mm	K. 17 mm
C. 10 mm	I. 15 mm	F. 18 mm	L. 14 mm

FOV 1 COMBINATION 2740H

FOV 2 COMBINATION 2740H



FOV 3 COMBINATION 2740H

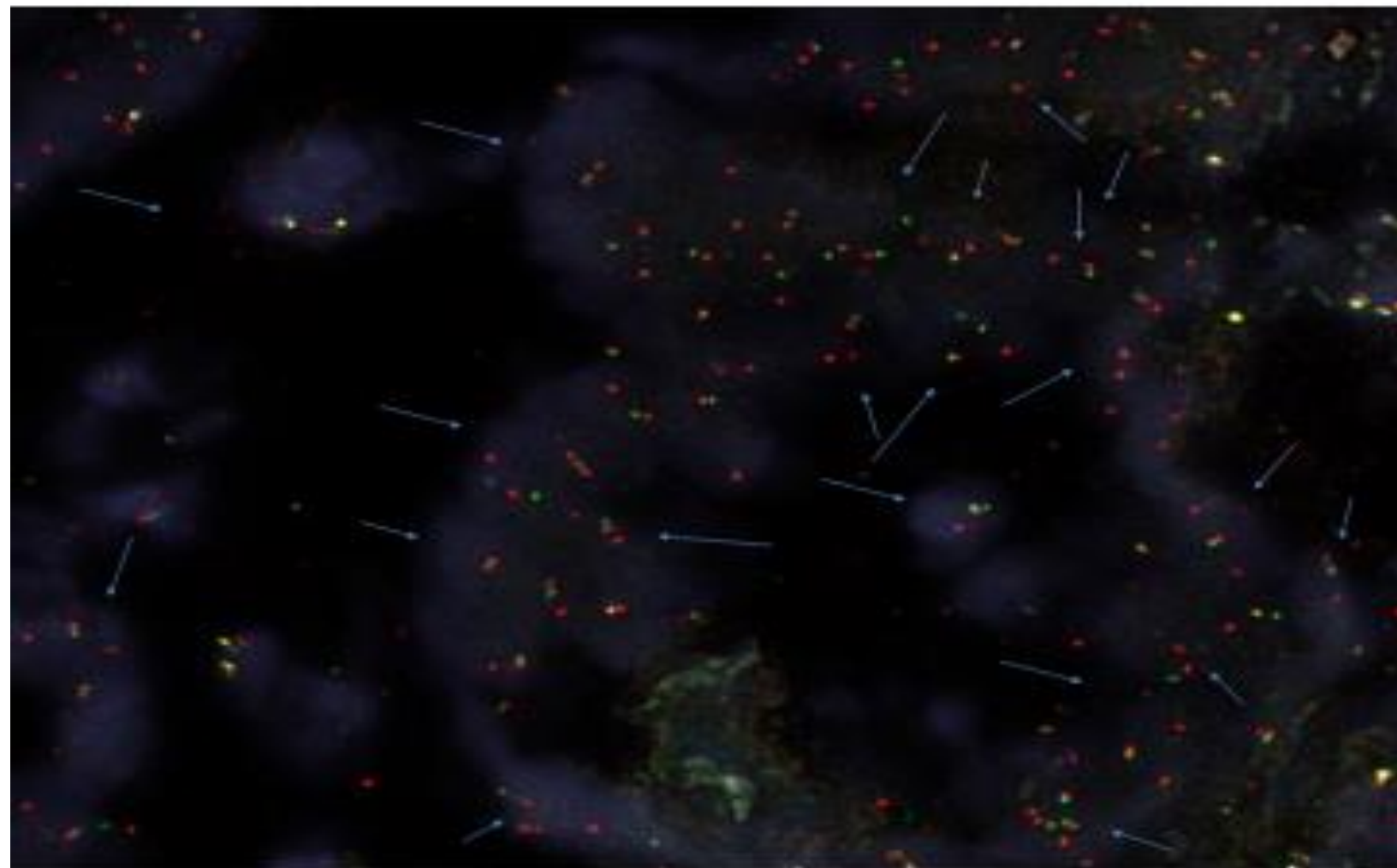
FAS Enumeration Chart

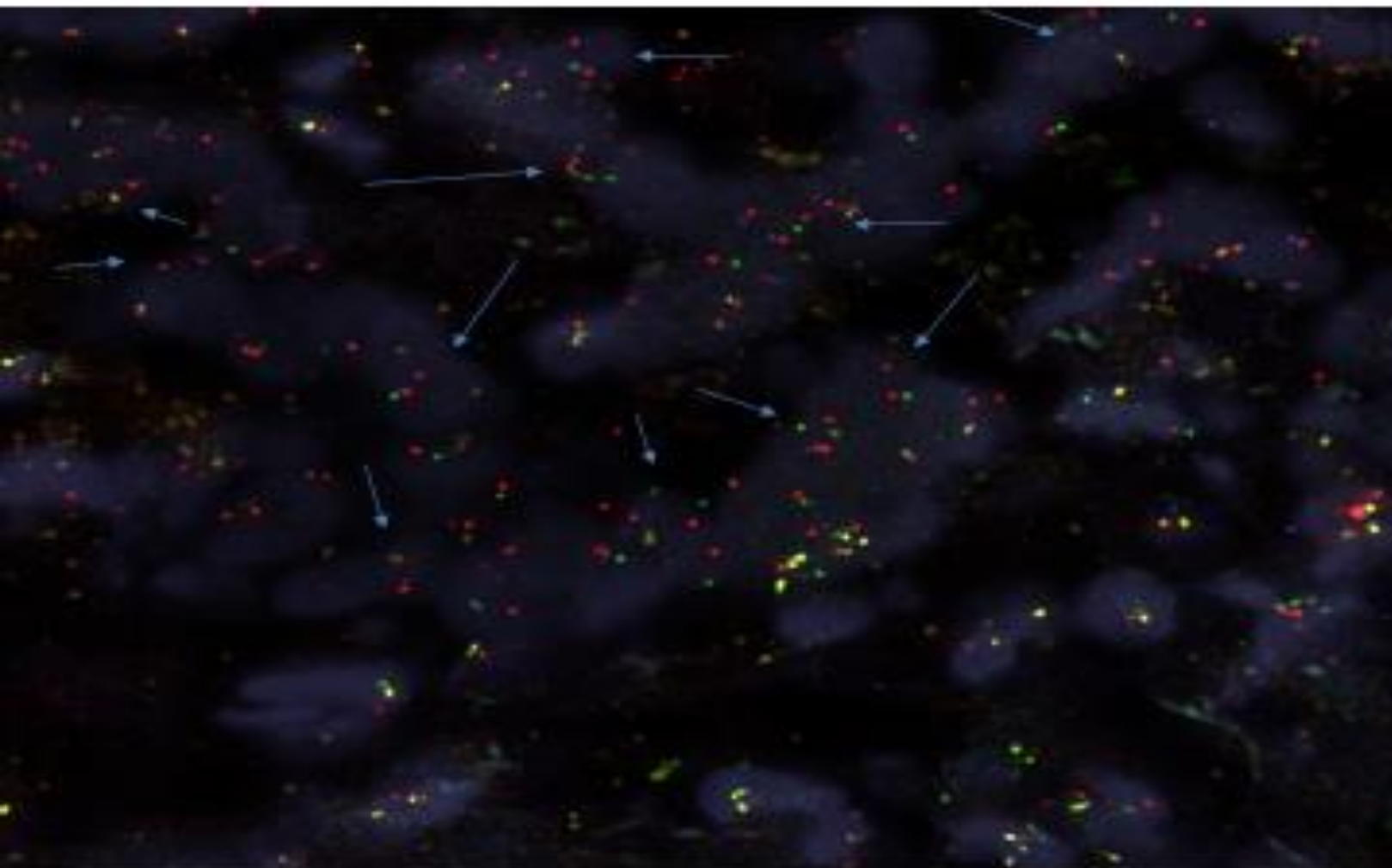
SLIDE ID		2740-H								
DBI	CEP ID	FAS AQUA	PTEN GOLD	FAS Hemi	FAS HOMO	FAS Normal	PTEN Hemi	PTEN HOMO	PTEN Normal	
1	2	2	2			X			X	
2	2	1	1	X			X			
3	2	2	2			X			X	
4	2	2	2			X			X	
5	2	1	0	X				X		
6	2	2	2			X			X	
7	2	2	2			X			X	
8	2	2	2			X			X	
9	2	2	2			X			X	
10	2	0	0		X			X		
11	2	2	2			X			X	
12	2	1	1	X					X	
13	2	2	2			X			X	
14	2	2	2			X			X	
15	2	1	1	X			X			
16	2	2	2			X			X	
17	2	2	2			X			X	
18	2	0	0		X			X		
19	2	2	2			X			X	
20	2	1	1	X			X			
21	2	1	1	X			X			
22	2	1	1	X			X			
23	2	2	2			X			X	
24	2	1	1	X			X			
25	2	2	2			X			X	
26	2	1	0	X				X		
27	2	1	1	X			X			
28	2	1	1	X			X			
29	2	1	1	X			X			
30	2	2	2			X			X	
31	2	2	2			X			X	
32	2	1	0	X				X		
33	2	0	1		X		X			
34	2	2	2			X			X	
35	2	2	2			X			X	
36	2	1	1	X			X			
37	2	2	2			X			X	
38	2	2	2			X			X	
39	2	1	1	X			X			
40	2	1	1	X			X			
41	2	2	2			X			X	
42	2	1	0	X				X		
43	2	1	1	X			X			
44	2	2	2			X			X	
45	2	0	0		X			X		
46	2	2	2			X			X	
47	2	2	2			X			X	
48	2	1	1	X			X			
49	2	2	2			X			X	
50	2	1	0	X				X		
				20	4	26	15	8	27	

FAS Hemi by grade %	0.2
FAS HOMO by grade %	0.09
Total FAS Detection %	0.29

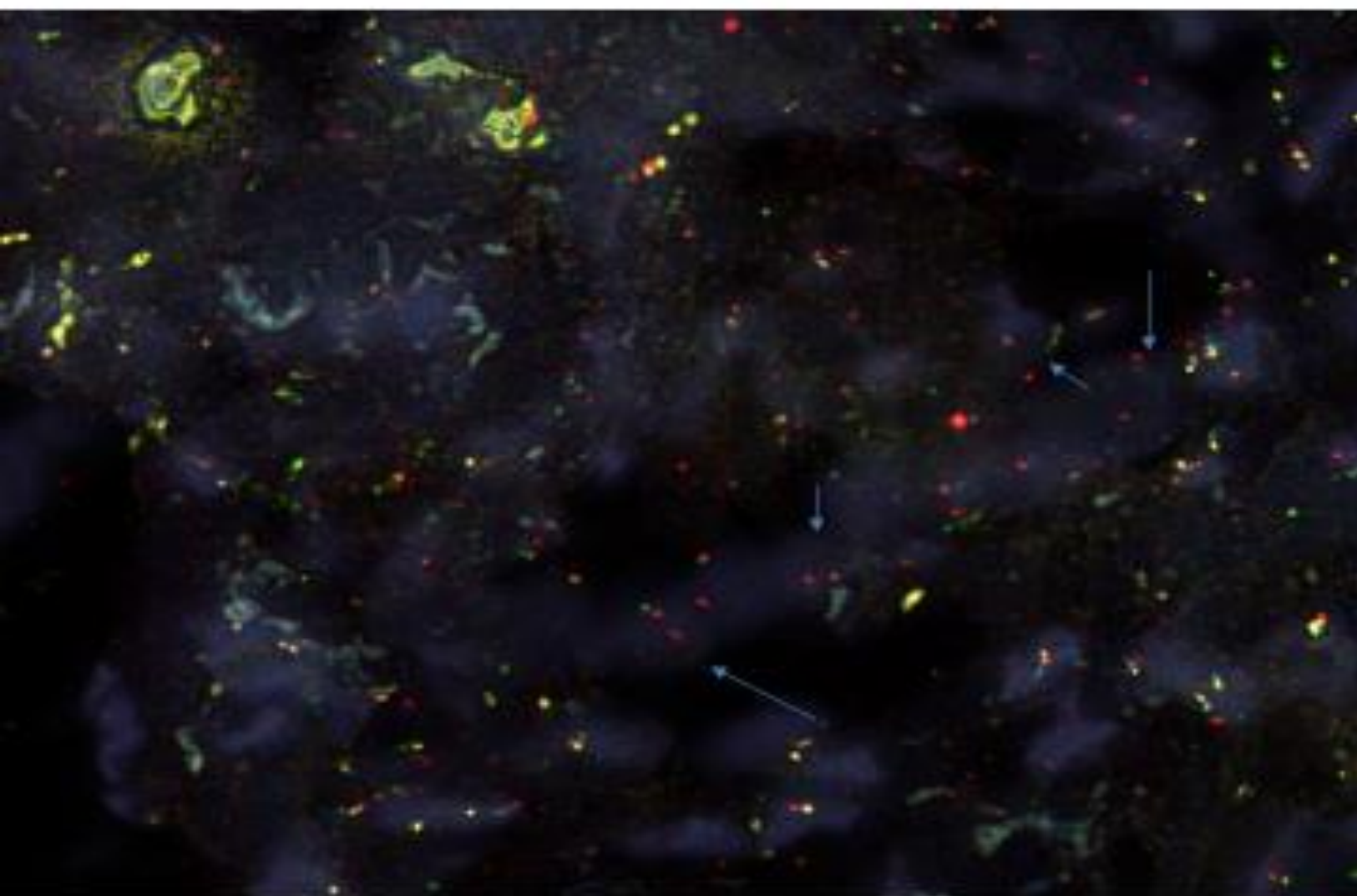
PTEN Hemi by grade %	0.3
PTEN HOMO by grade %	0.19
Total PTEN Detection %	0.49

[REDACTED]		[REDACTED]-002740 I			
DOB: 01-23-1942 Age: 72 Gender: Male Collected: 05-05-2014 Received: 05-06-2014		[REDACTED] [REDACTED] [REDACTED] Kankakee, IL 60901-3679 Phone: 815-937-2128 Fax: 815-937-2102			
Clinical Info Summary Elevated PSA 6.36	Diagnosis Summary Adenocarcinoma Involving 1 out of 12 cores. Highest Gleason 3+3=6. -Chronic inflammation present -Confirmed by PIN4 stain	<p> ● Malignant ■ Benign ▲ High grade PIN ◆ Atypical </p>			
<p>Prostatic Ca, H&E</p>	<p>Prostatic Ca, PIN4 IHC.</p>	Final Diagnosis (Left) A. Benign prostatic tissue. B. Benign prostatic tissue. C. Benign prostatic tissue with acute inflammation. G. Benign prostatic tissue with chronic inflammation (Confirmed by PIN4 immunostain). H. Prostatic adenocarcinoma, Gleason 3 + 3 (score = 6), multifocal, involving 5% of needle core, measuring 0.5 mm (Confirmed by PIN4 immunostain). I. Benign prostatic tissue.		Final Diagnosis (Right) D. Benign prostatic tissue. E. Benign prostatic tissue with chronic inflammation. F. Benign prostatic tissue. J. Benign prostatic tissue. K. Benign prostatic tissue. L. Benign prostatic tissue with chronic inflammation.	
Notes: The adenocarcinoma found is small but multifocal. PIN4 IHC shows strong cytoplasmic staining for raseamase and loss of basal layer. These findings support the diagnosis. Clinical correlation would be helpful. Per protocol, PTEN FISH will be performed with a report to follow.					
Gross Description Specimens are received in formalin, labeled with patient's name, anatomic pathology number and location, and consist of pale tan portion(s) of cylindrical tissue 1 mm. in diameter and with lengths stated as below:					
<u>Left</u>		<u>Right</u>			
A. 15 mm	G. 18 mm	D. 13 mm	J. 16 mm		
B. 17 mm	H. 19 mm	E. 14 mm	K. 17 mm		
C. 10 mm	I. 15 mm	F. 16 mm	L. 14 mm		

FOV 1 COMBINATION 2740I

FOV 2 COMBINATION 2740I

FOV 2 COMBINATION 2740I



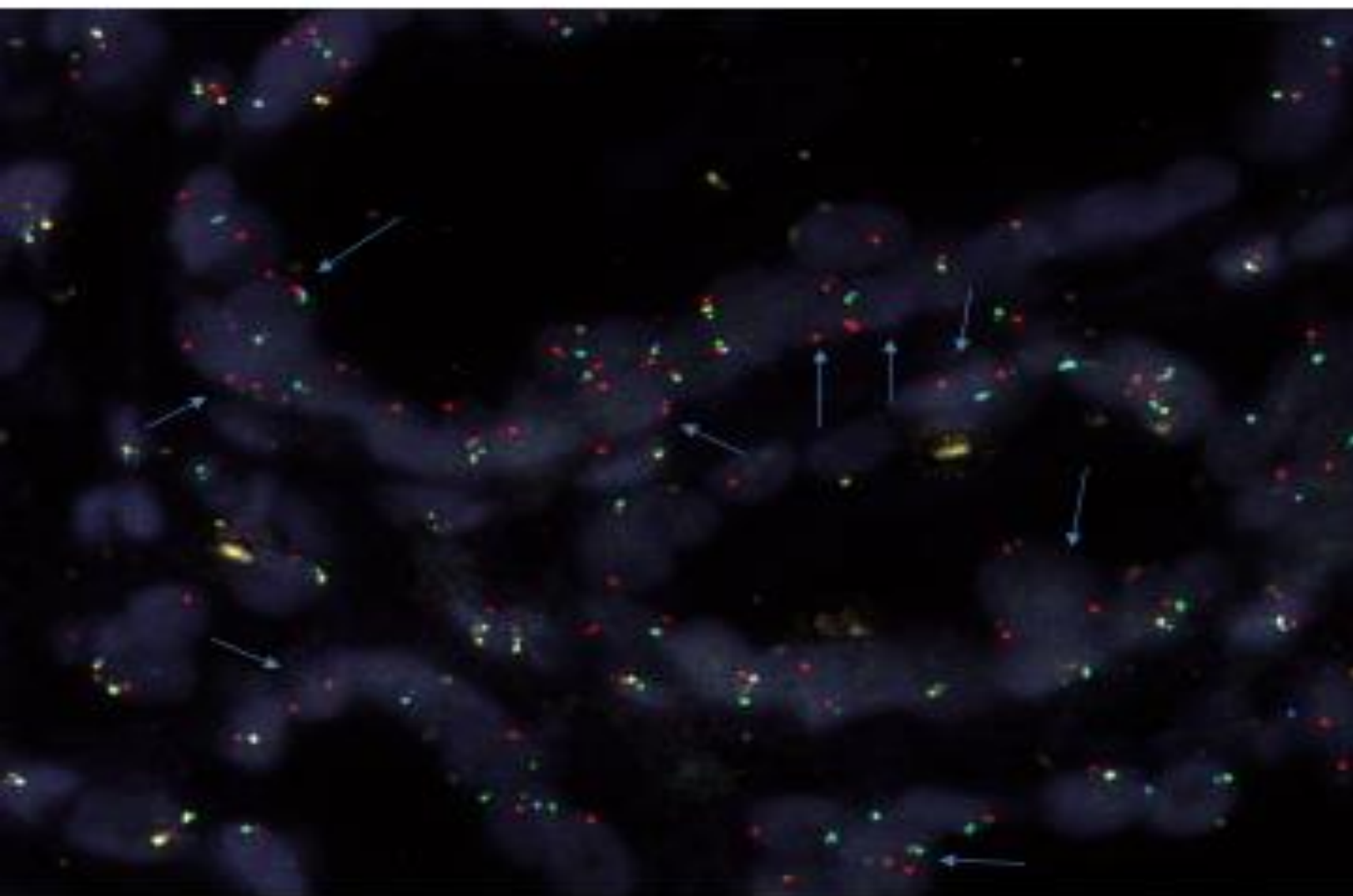
FAS Enumeration Chart

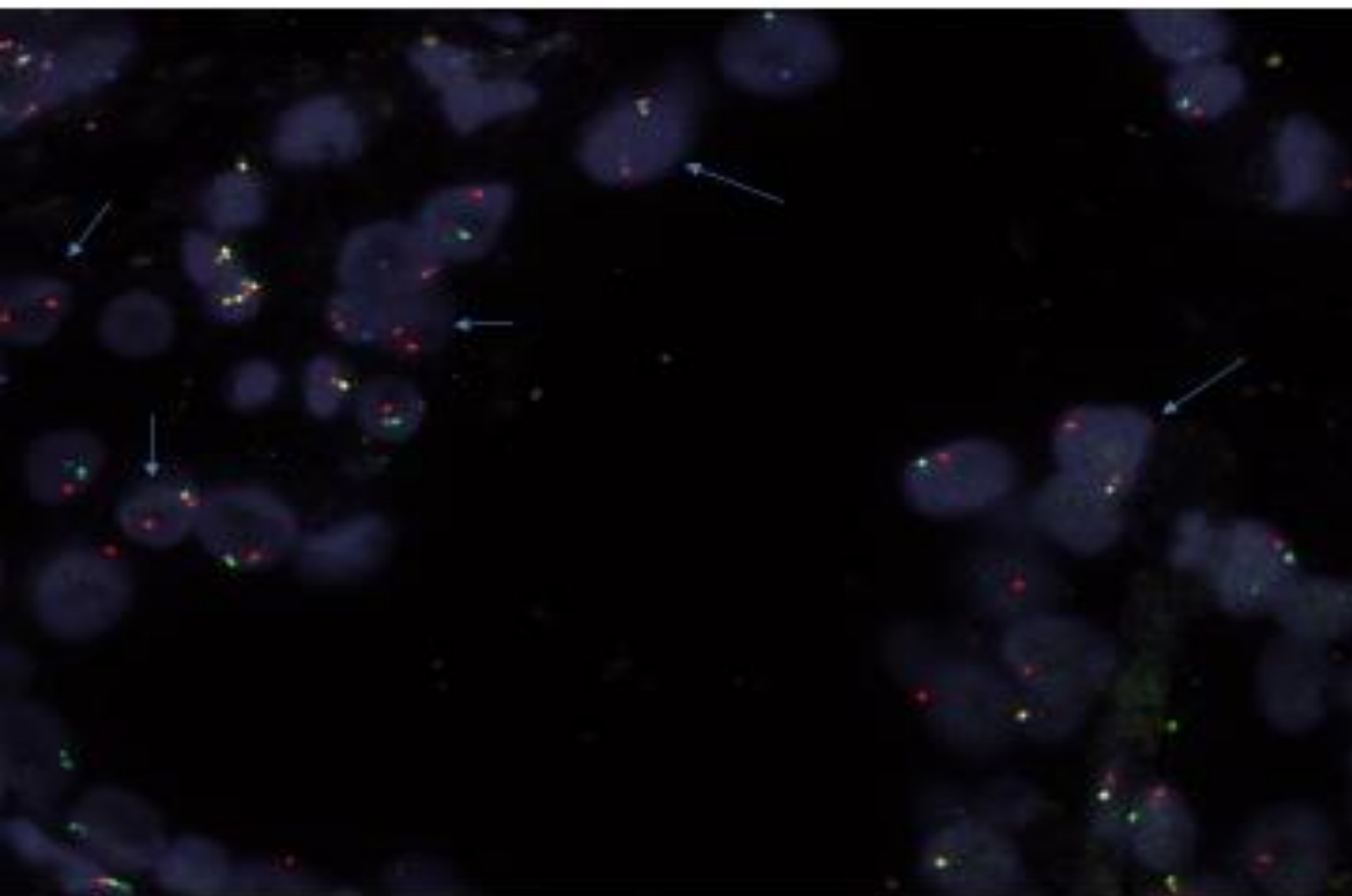
FAS Enumeration Chart									
SLIDE ID	2740-I								
CH1	CEP10	FAS	Pten	FAS	FAS	FAS	PTEN	PTEN	PTEN
	(HOM)	(HOM)	(HOM)	HOM	HOM	NORM	HOM	HOM	NORM
1	X	X	0			X		X	
2	X	X	X			X			X
3	X	X	0			X		X	
4	X	X	0			X		X	
5	X	X	X			X			X
6	X	X	X			X			X
7	X	X	0			X		X	
8	X	X	X			X			X
9	X	X	X			X			X
10	X	X	0			X		X	
11	X	X	0			X		X	
12	X	X	X			X			X
13	X	X	0			X		X	
14	X	X	X			X			X
15	X	X	0			X		X	
16	X	X	0			X		X	
17	X	X	X			X			X
18	X	X	0			X		X	
19	X	X	0			X		X	
20	X	X	0			X		X	
21	X	X	0			X		X	
22	X	X	X			X			X
23	X	X	0			X		X	
24	X	X	0			X		X	
25	X	X	X			X			X
26	X	X	0			X		X	
27	X	X	0			X		X	
28	X	X	0			X		X	
29	X	X	0			X		X	
30	X	X	0			X		X	
31	X	X	0			X		X	
32	X	X	0			X		X	
33	X	X	0			X		X	
34	X	X	X			X			X
35	X	X	X			X			X
36	X	X	0			X		X	
37	X	X	0			X		X	
38	X	X	X			X			X
39	X	X	0			X		X	
40	X	X	0			X		X	
41	X	X	0			X		X	
42	X	X	0			X		X	
43	X	X	X			X			X
44	X	X	0			X		X	
45	X	X	X			X			X
46	X	X	0			X		X	
47	X	0	0		X			X	
48	X	X	0			X		X	
49	X	X	0			X		X	
50	X	X	0			X		X	
				0	1	49	0	35	15

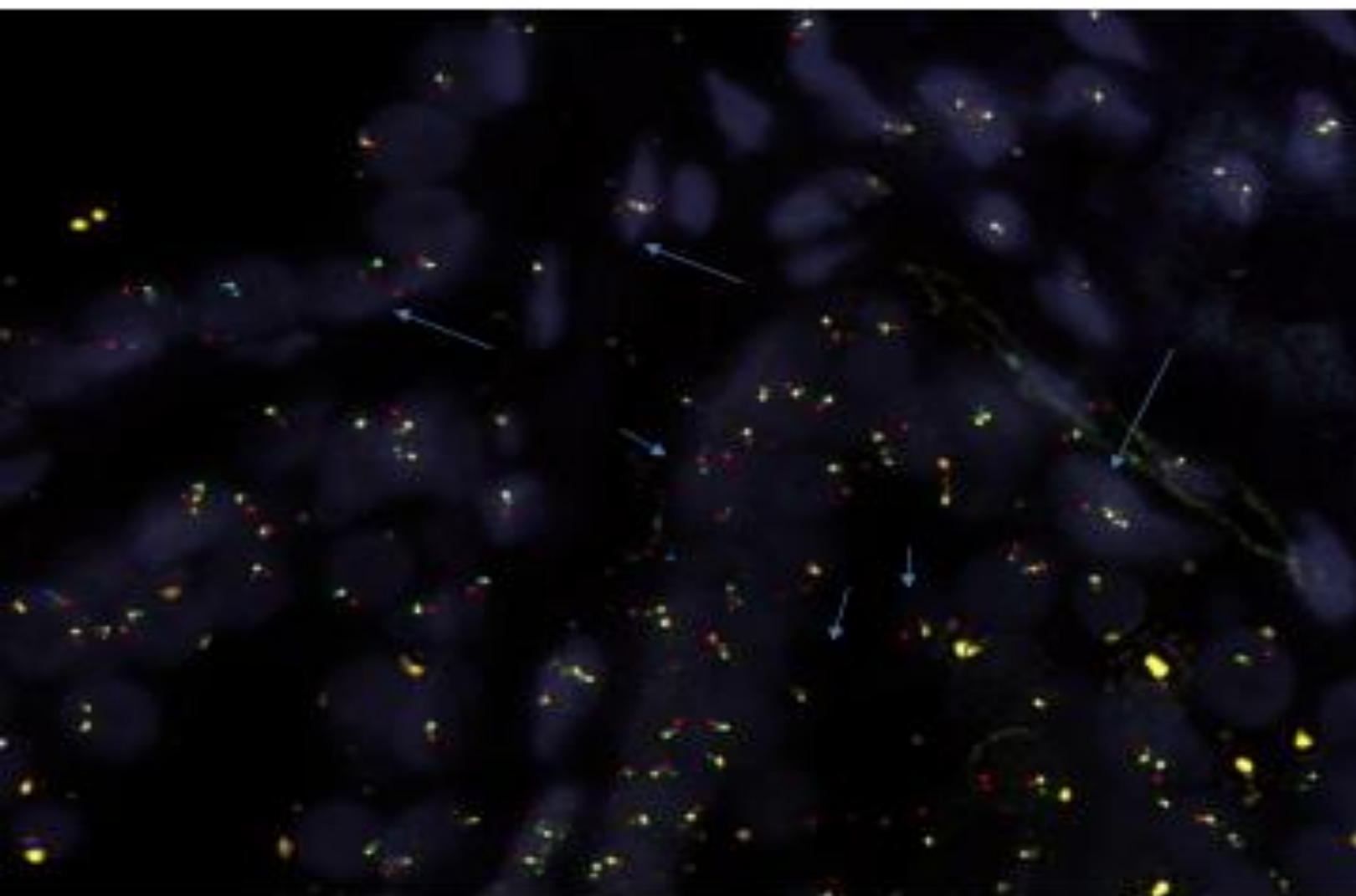
FAS Hemizygous %	0
FAS Homozygous %	0.02
Total FAS Deletion %	0.02

PTEN Hemizygous %	0
PTEN Homozygous %	0.07
Total PTEN Deletion %	0.07

[REDACTED]		[REDACTED]-003304
Date of Birth: 03-08-1946 Age: 67 Gender: Male		[REDACTED] [REDACTED] Phone: [REDACTED] Fax: [REDACTED]
Received: 10-30-2013	Collected: 10-29-2013	
Clinical Info Summary Nodular prostate without urinary obstruction	Diagnosis Summary Prostatic adenocarcinoma, Gleason score 3 + 3 (6).	
Specimen B	Specimen H	
Final Diagnosis (Left) A. Benign prostatic tissue. B. Prostatic adenocarcinoma, Gleason 3 + 3 (score 6), involving 12% of total submitted tissue, measuring 5 mm. C. Benign prostatic tissue. G. Benign prostatic tissue. H. Prostatic adenocarcinoma, Gleason 3 + 3 (score 6), involving 17% of total submitted tissue, measuring 4.5 mm. I. Benign prostatic tissue.	Final Diagnosis (Right) D. Prostatic adenocarcinoma, Gleason 3 + 3 (score 6), involving 5% of total submitted tissue, measuring 2 mm. E. Benign prostatic tissue. F. Benign prostatic tissue. J. Prostatic adenocarcinoma, Gleason 3 + 3 (score 6), involving 7% of total submitted tissue, measuring 2.5 mm. K. Benign prostatic tissue. L. Benign prostatic tissue.	
Notes: Dr. A. Thakur has seen specimens B, D, H and J and agrees with the diagnosis.		
Gross Description Specimens are received in formalin, labeled with patient's name, anatomic pathology number and location, and consist of pale tan portion(s) of cylindrical tissue 1 mm. in diameter and with lengths stated as below:		
<u>Left</u>		<u>Right</u>
A. 20 mm	G. 25 mm, 20 mm	D. 17 mm, 15 mm, 15 mm
B. 21 mm, 23 mm	H. 20 mm	J. 23 mm, 20 mm, 16 mm
C. 25 mm	I. 20 mm	E. 18 mm
		K. 20 mm, 15 mm
		F. 15 mm
		L. 15 mm
11-01-2013 16:38:15 <i>M. GANJI</i>		Masoud Ganji, MD

FOV 1 (#1) COMBINATION 3304B

FOV 1 (#2) COMBINATION 3304B

FOV 1 (#3) COMBINATION 3304B

FAS Enumeration Chart

SLIDE ID		3004-B			FAS	FAS	PTEN	PTEN	PTEN
Cell	CEP ID	FAS [good]	PTEN [good]	FAS Hemiz	FAS homo	FAS Normal	PTEN Hemiz	PTEN Homo	PTEN Normal
1	2	2	2			X			X
2	2	1	1	X			X		
3	2	1	1	X			X		
4	2	2	2			X			X
5	2	2	2			X			X
6	2	2	2			X			X
7	2	2	2			X			X
8	2	1	1	X			X		
9	2	2	2			X			X
10	2	1	1	X			X		
11	2	2	2			X			X
12	2	1	1	X			X		
13	2	2	2			X			X
14	2	2	2			X			X
15	2	2	2			X			X
16	2	1	1	X			X		
17	2	2	2			X			X
18	2	1	1	X			X		
19	2	2	2			X			X
20	2	2	2			X			X
21	2	1	1	X			X		
22	2	1	1	X			X		
23	2	2	2			X			X
24	2	1	1	X			X		
25	2	2	2			X			X
26	2	2	2			X			X
27	2	1	1	X			X		
28	2	1	1	X			X		
29	2	2	2			X			X
30	2	1	1	X			X		
31	2	2	2			X			X
32	2	2	2			X			X
33	2	2	2			X			X
34	2	2	2			X			X
35	2	2	2			X			X
36	2	2	2			X			X
37	2	1	1	X			X		
38	2	2	2			X			X
39	2	2	2			X			X
40	2	1	1	X			X		
41	2	2	2			X			X
42	2	2	2			X			X
43	2	1	1	X			X		
44	2	2	2			X			X
45	2	2	2			X			X
46	2	1	1	X			X		
47	2	2	2			X			X
48	2	1	1	X			X		
49	2	1	1	X			X		
50	2	1	1	X			X		
				20	0	30	20	0	50

FAS Hemizygous %	0.4
FAS homozygous %	0
Total FAS Deletion %	0.4

PTEN Hemizygous %	0.4
PTEN homozygous %	0
Total PTEN Deletion %	0.4

METASTIC SUBSET

SURGICAL PATHOLOGY REPORT
* Amended *

Patient Name: [REDACTED]
 Patient ID #: 000652138
 DOB/Age: 6/21/1942 (Age: 70) Gender: M
 Address: [REDACTED]
 Location: CAROL STREAM, IL 60188
 Physician(s): [REDACTED]

Specimen #: 6958
 Procedure Code: 3/15/2013
 Accession #: 3/15/2013
 Reported: 3/11/2013
 Encounter: 14243672
 Inpatient

3

Amendments:

Amended: 3/11/2013 by TIFFANY Y CHANG MD

Reason: CORRECTION OF PREVIOUSLY REPORTED INFORMATION

Correction in the staging summary

Previous Signout Date: 3/22/2013

Diagnosis:

1. RIGHT DISTAL URETER, EXCISION:
 - URETER WITHOUT DIAGNOSTIC ABNORMALITY.
 - NO EVIDENCE OF MALIGNANT TUMOR.
2. LEFT DISTAL URETER, EXCISION:
 - URETER WITHOUT DIAGNOSTIC ABNORMALITY.
 - NO EVIDENCE OF MALIGNANT TUMOR.
3. PROSTATE AND BLADDER WITH LYMPH NODES, ROBOTIC-ASSISTED CYSTOPROSTATECTOMY:
 - PROSTATIC ADENOCARCINOMA, GLEASON SCORE 5+4=9, INVOLVING BOTH THE RIGHT AND LEFT SIDES AND INVADING THROUGH THE WALL OF THE BLADDER AND INTO THE BLADDER MUCOSA, SEE PATHOLOGIC SUMMARY BELOW.
 - REMAINING UROTHELIAL MUCOSA WITH CHRONIC AND FOCAL GRANULOMATOUS INFLAMMATION, NO UROTHELIAL CARCINOMA IDENTIFIED.
 - URETERAL MARGINS ARE FREE OF TUMOR.
 - PROSTATIC MARGINS ARE FREE OF TUMOR (INVASIVE TUMOR IS FOCALLY WITHIN 1.0 MM OF THE MARGIN AT THE SEMINAL VESICLES).
 - SEMINAL VESICLES INVOLVED BY PROSTATIC ADENOCARCINOMA.
 - LYMPHOVASCULAR INVASION PRESENT.
4. LYMPH NODES, BILATERAL PELVIC DISSECTION:
 - SIX LYMPH NODES NEGATIVE FOR METASTATIC TUMOR (0/6).
5. DISTAL URETER, RIGHT, EXCISION:
 - PORTION OF URETER WITHOUT DIAGNOSTIC ABNORMALITY.
 - NO EVIDENCE OF MALIGNANT TUMOR.

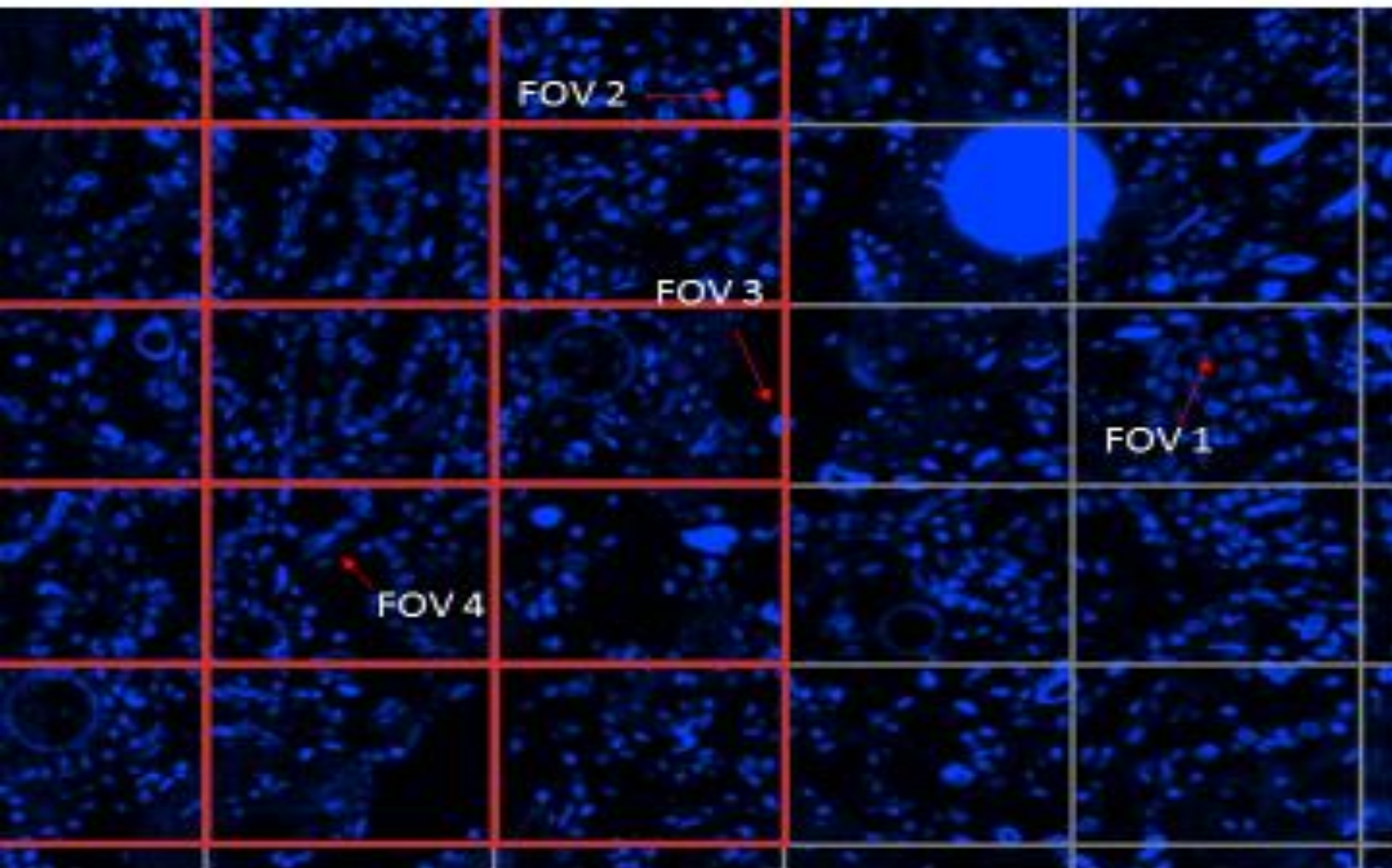
PROSTATE RADICAL PROSTATECTOMY PATHOLOGY SUMMARY

Procedure: Radical cystoprostatectomy.

DAVIS, JAMES A.

Page 1 of 3

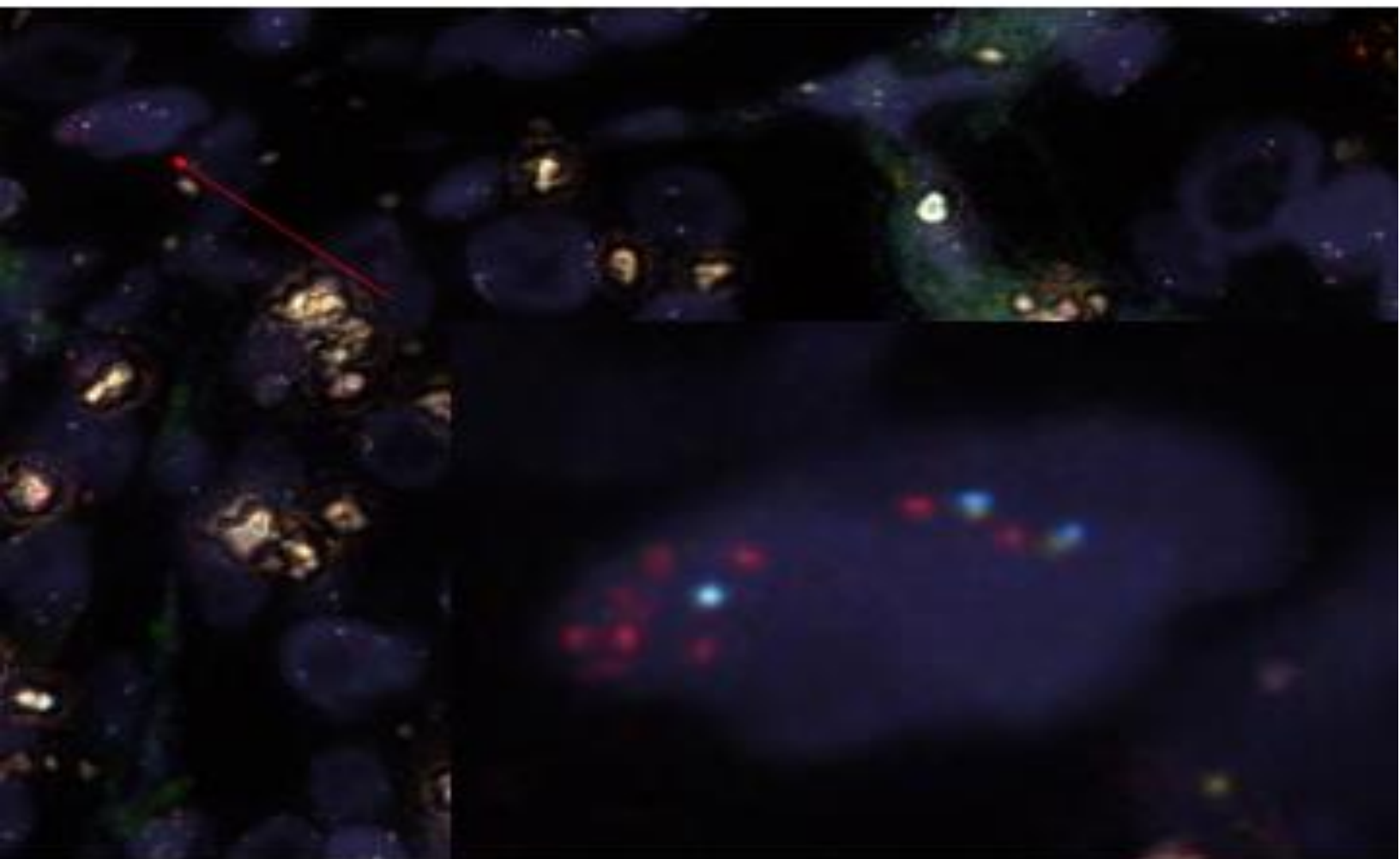
**METASTATIC PROSTATE
ADENOCARCINOMA TO SEMINAL VESICLE
6958-3
GENETIC (POLYSOMY) INSTABILITY and
CONCOMITANT DELETION of FAS AND
PTEN #1**



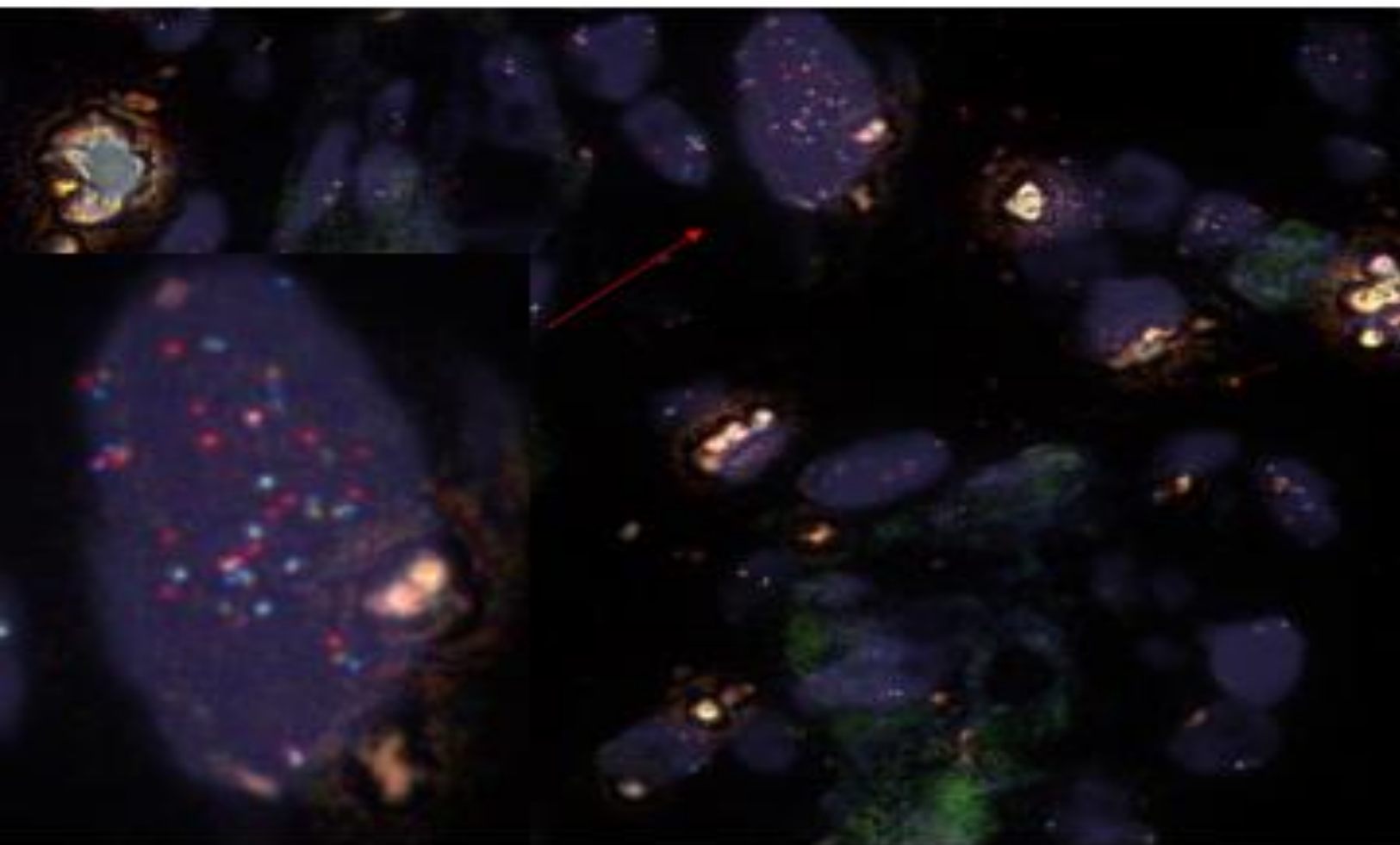
*Red Arrows denote cells with genetic instability

*Blue Arrows denote cells with concomitant deletion of FAS and PTEN

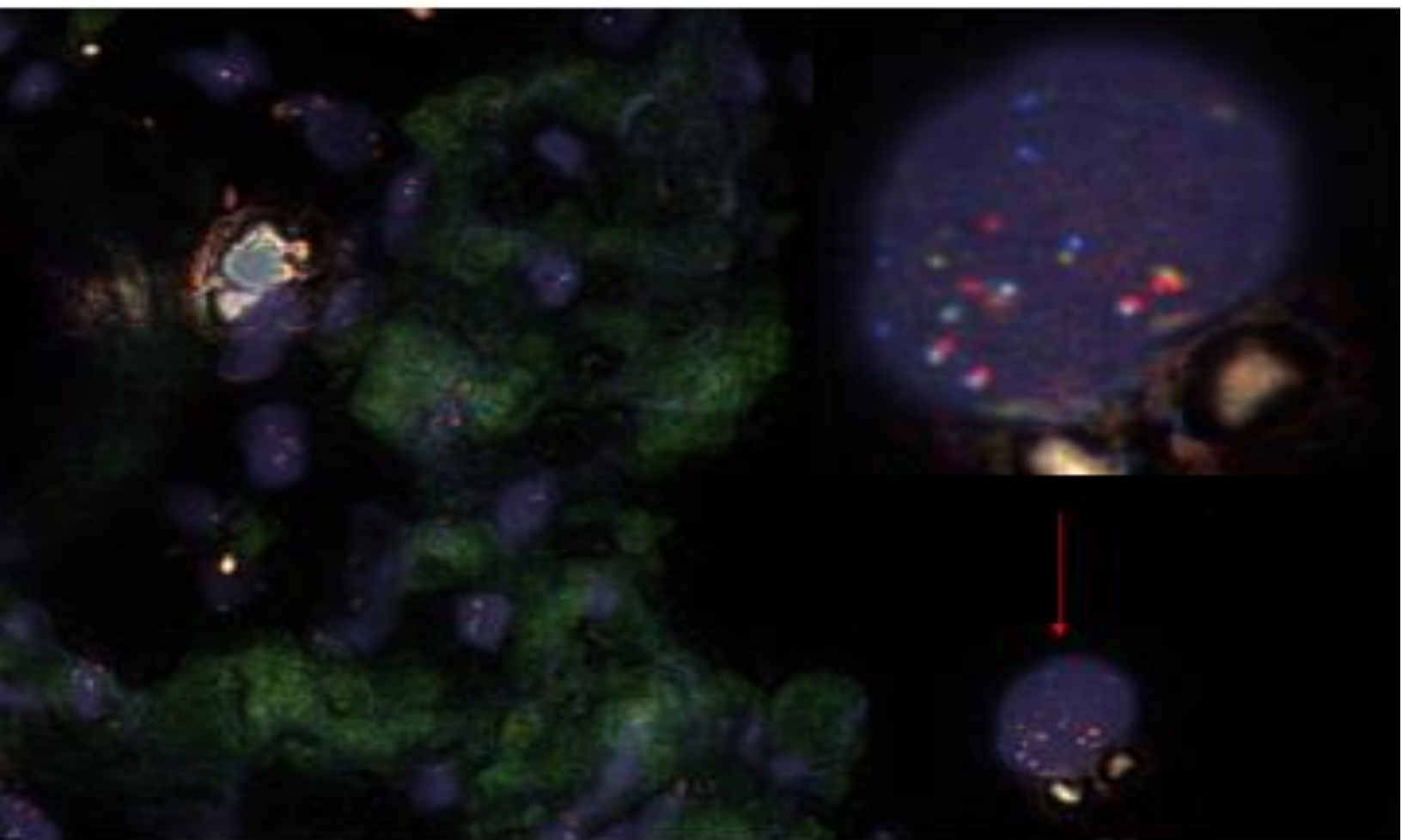
**FOV 1 COMBINATION 6958-3 GENETIC
INSTABILITY #1**



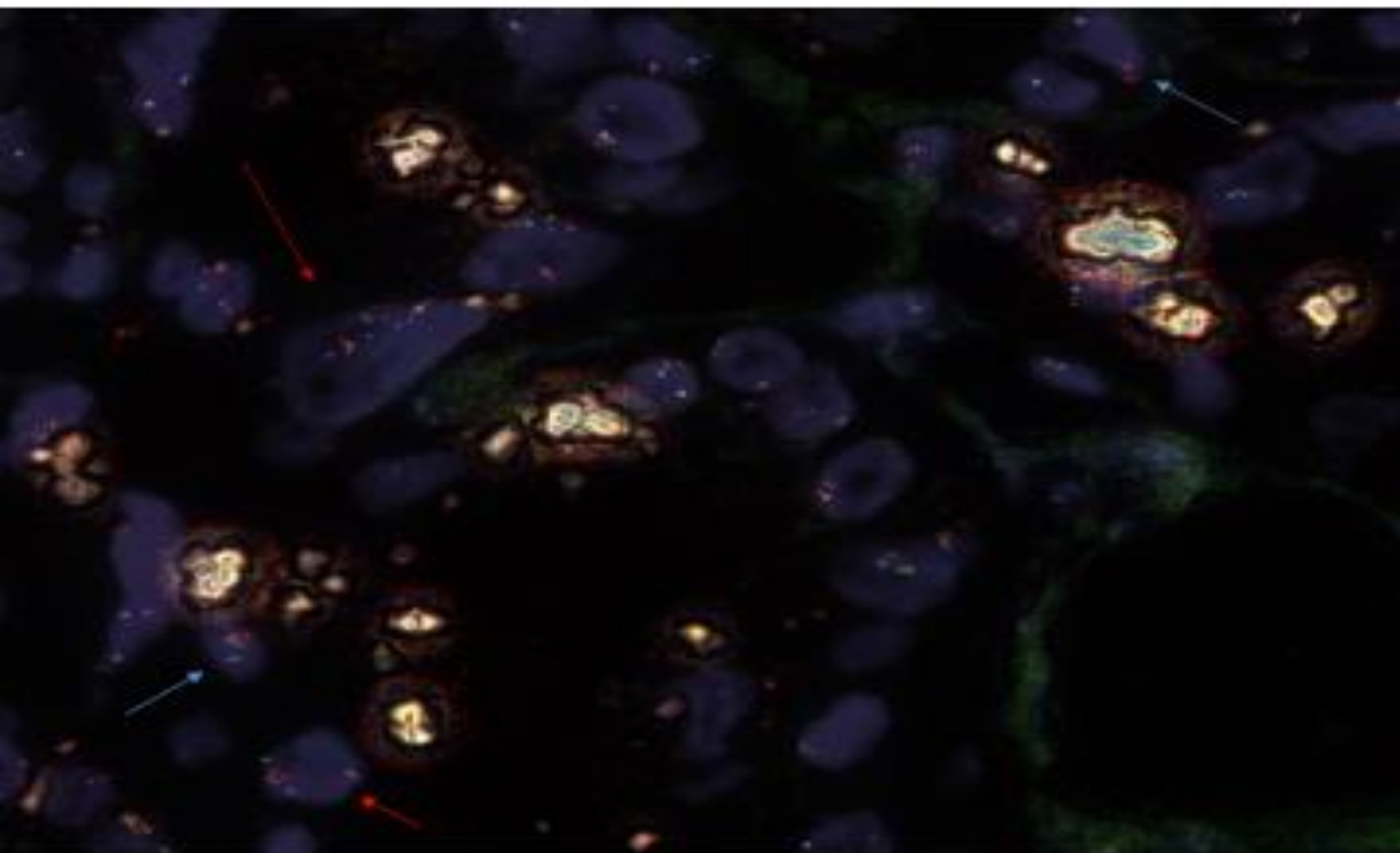
**FOV 2 COMBINATION 6958-3 GENETIC
INSTABILITY #1**



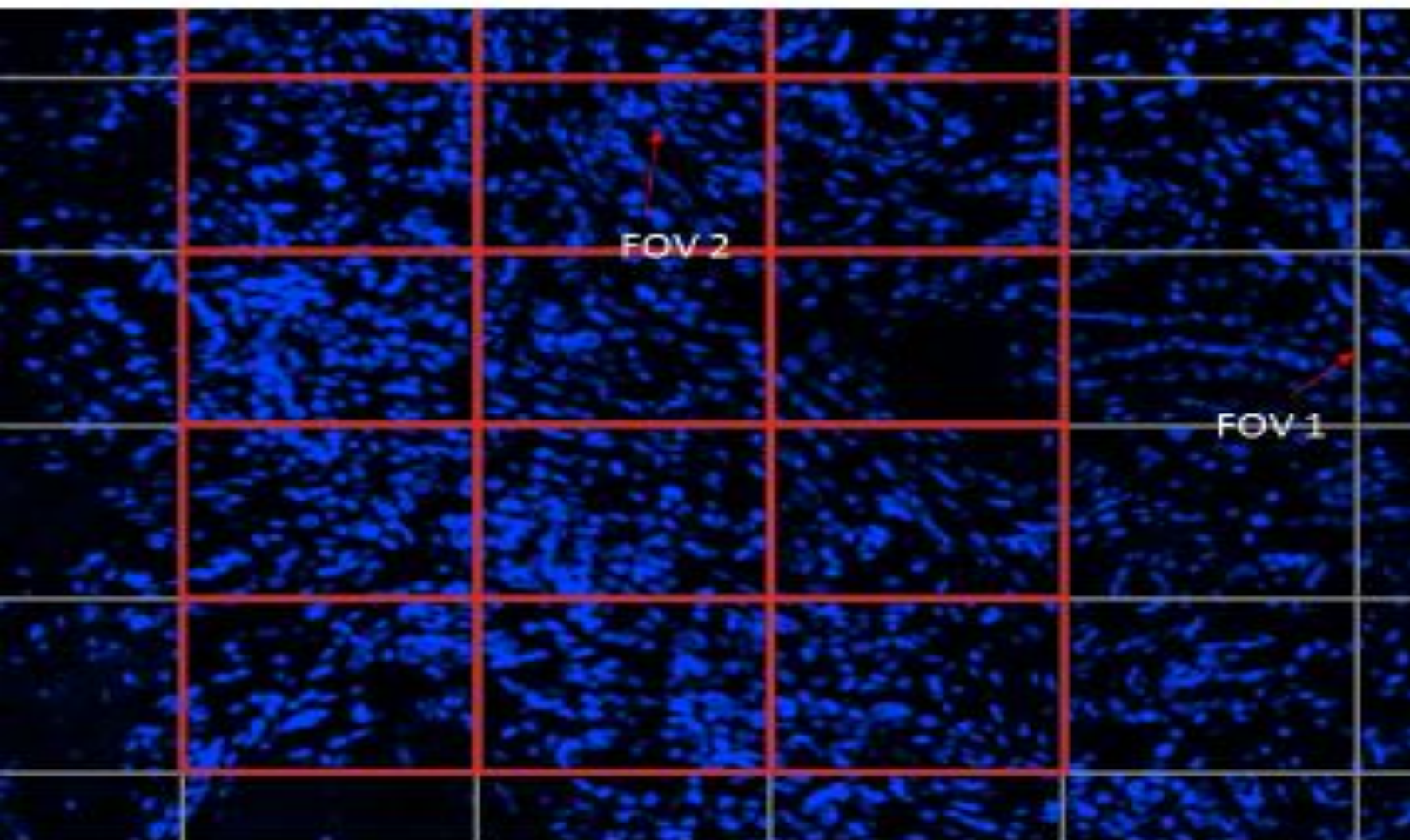
**FOV 3 COMBINATION 6958-3 GENETIC
INSTABILITY #1**



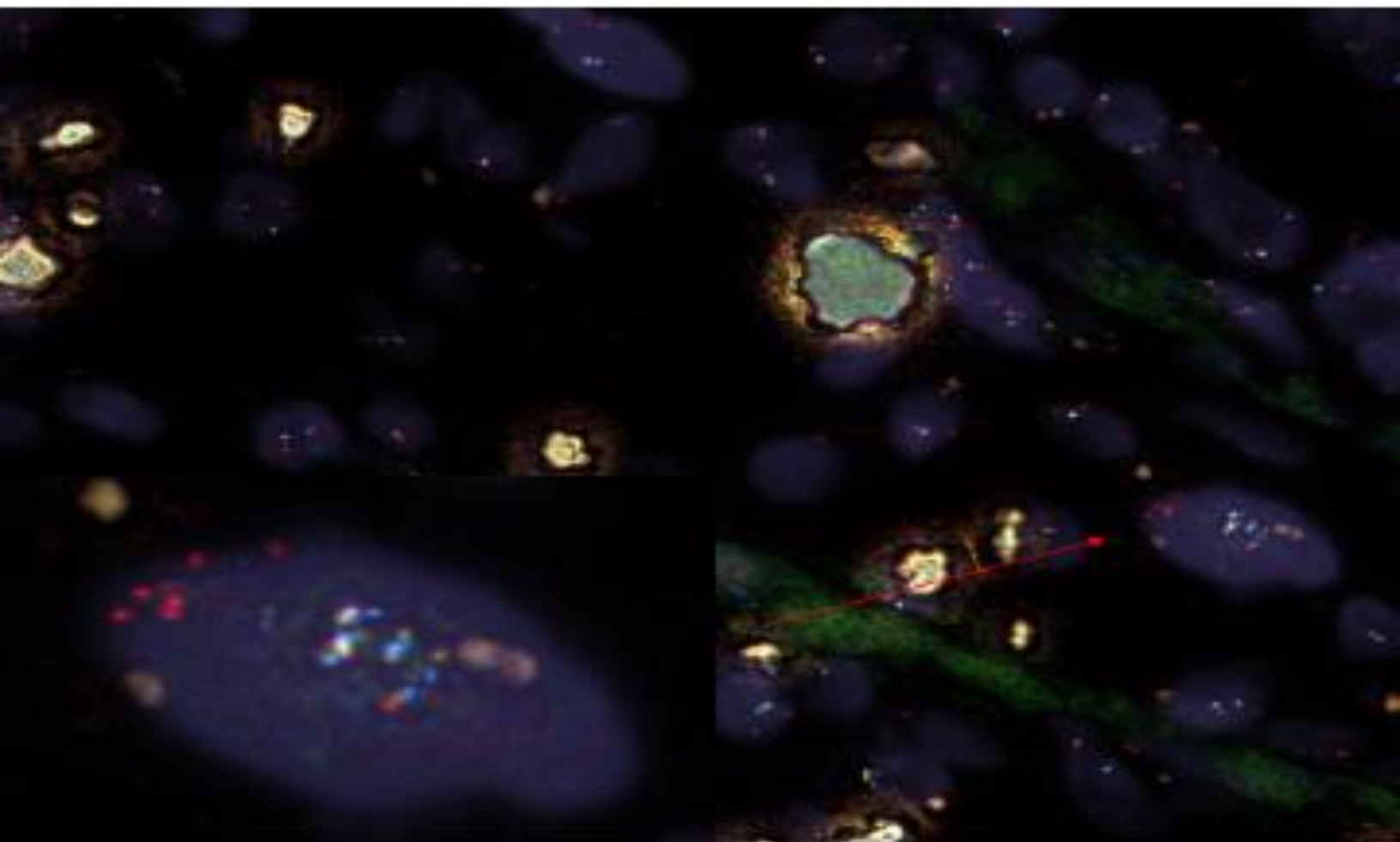
**FOV 4 COMBINATION 6958-3 GENETIC
INSTABILITY #1**



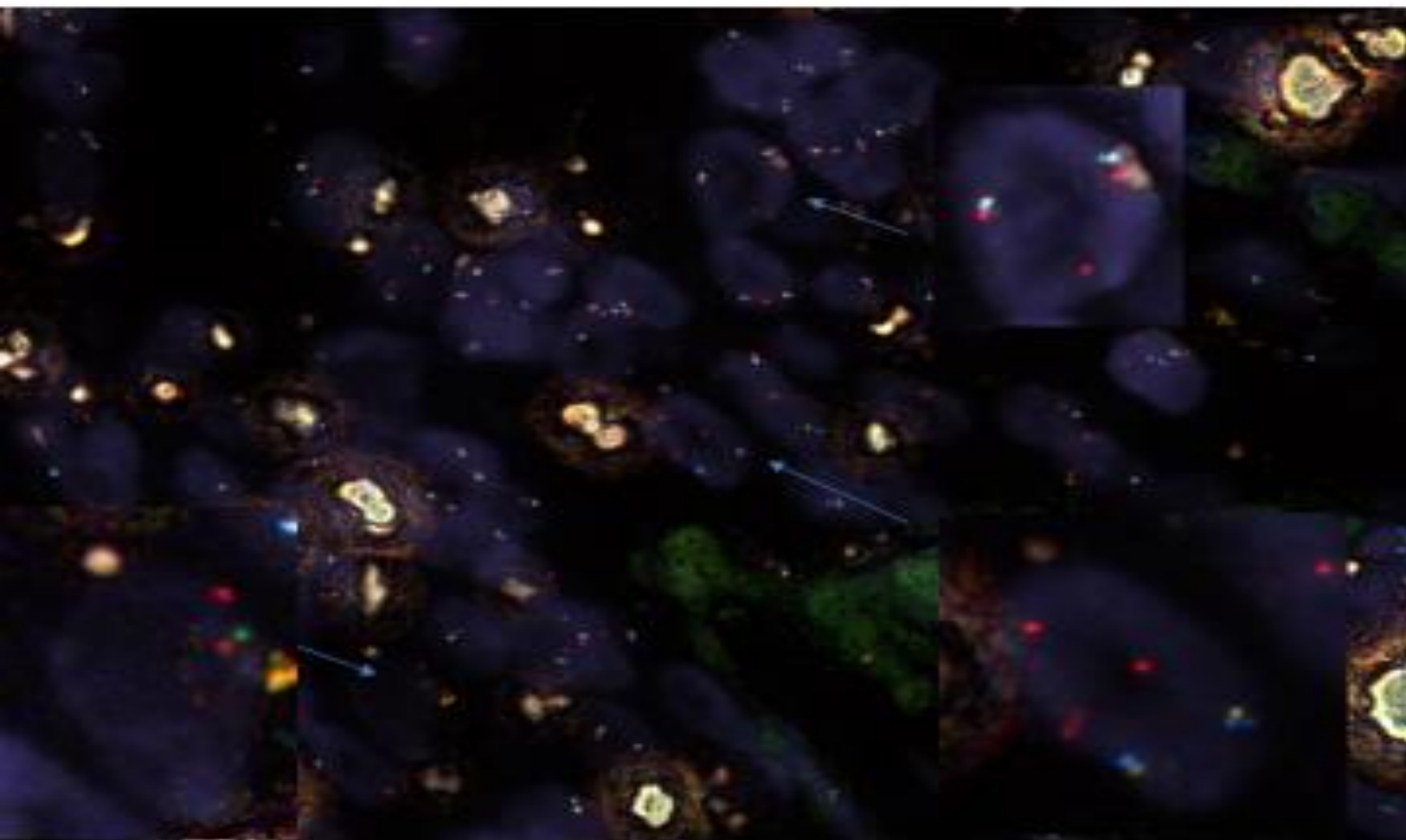
**METASTATIC PROSTATE ADENOCARCINOMA TO
SEMINAL VESICLE 6958-3
GENETIC (POLYSOMY) INSTABILITY and
CONCOMITANT DELETION of FAS AND PTEN #2**



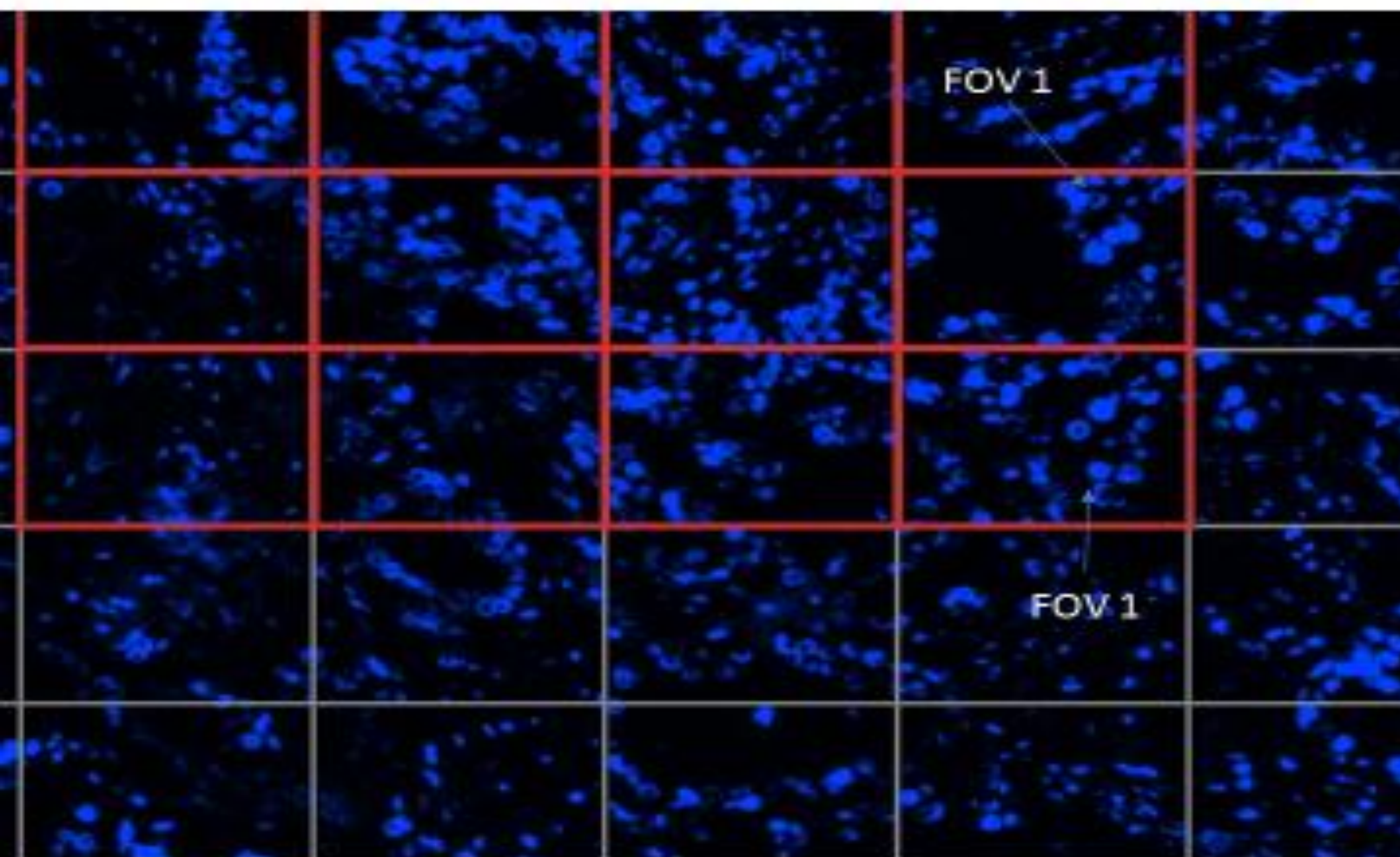
**FOV 1 COMBINATION 6958-3 GENETIC
INSTABILITY #2**



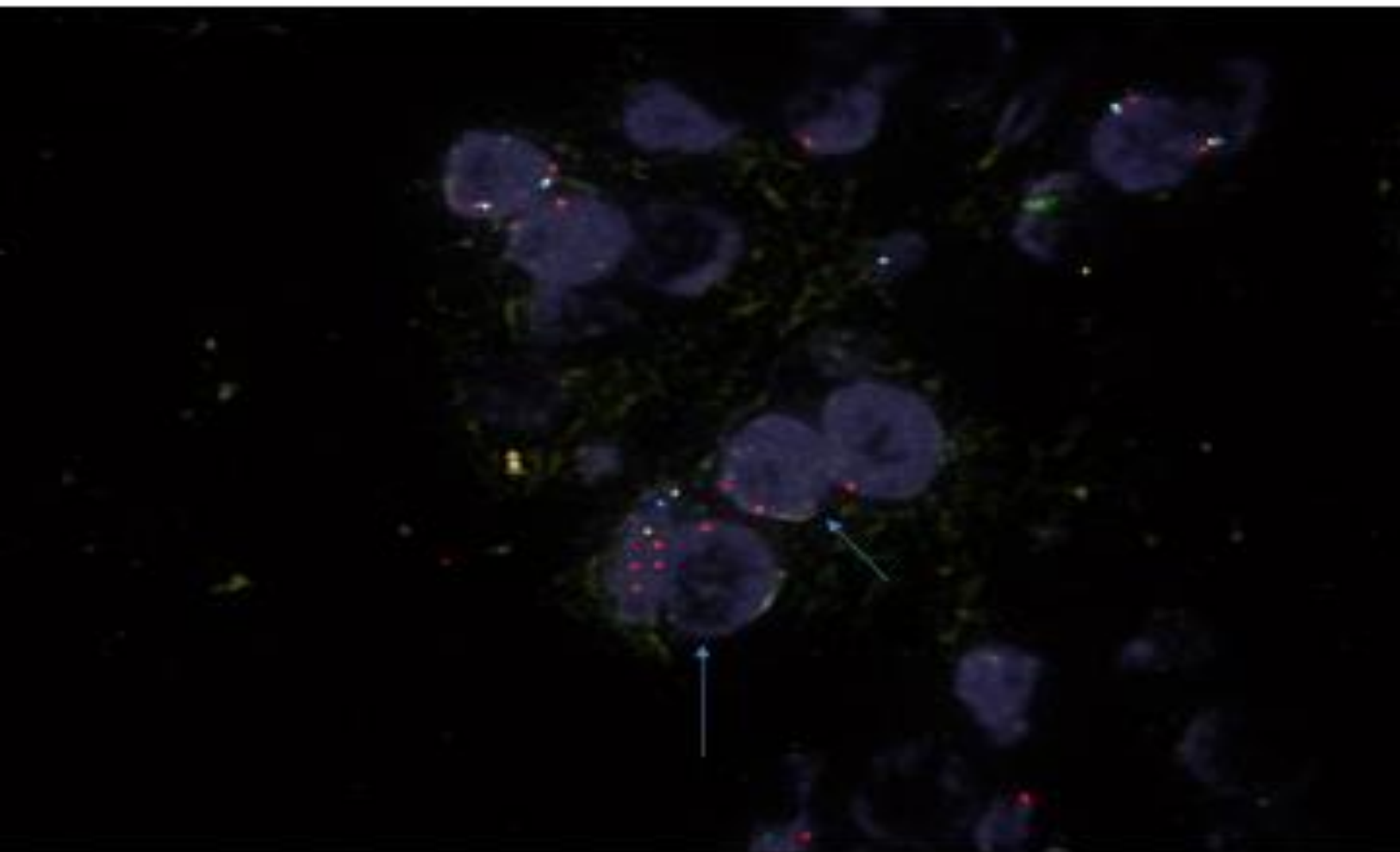
**FOV 2 COMBINATION 6958-3 FAS/PTEN
DELETION #2**



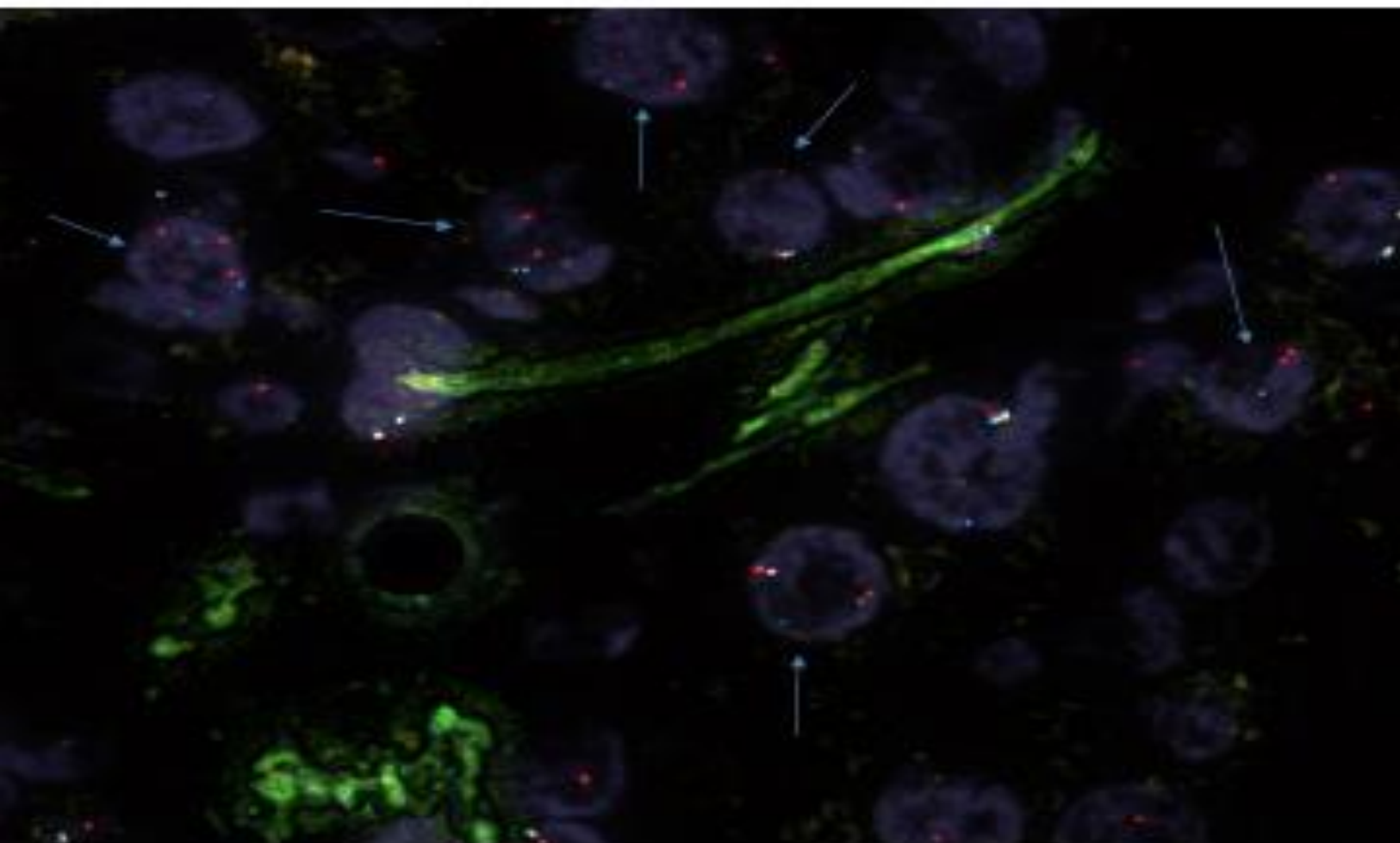
**METASTATIC PROSTATE
ADENOCARCINOMA TO SEMINAL VESICLE
6958-3
CONCOMITANT DELETION of FAS AND
PTEN #3**



**FOV 1 COMBINATION 6958-3 FAS/PTEN
DELETION #3**



**FOV 2 COMBINATION 6958-3 FAS/PTEN
DELETION #3**










FAS Enumeration Chart

SLIDE ID		6958-3			FAS	FAS	PTEN	PTEN	PTEN
CR1	CRP ID	FAS	PTEN	FAS	FAS	Normal	PTEN	PTEN	PTEN
	(REQ)	(ACQ/A)	(G/C/C)	Hemiz	Homo		Hemiz	Hemiz	Normal
1	2	2	2			X			X
2	2	2	2			X			X
3	2	2	2			X			X
4	2	2	2			X			X
5	2	0	0		X			X	
6	2	2	2			X			X
7	2	2	2			X			X
8	2	2	2			X			X
9	2	2	2			X			X
10	3	1	1	X			X		
11	2	2	2			X			X
12	2	2	2			X			X
13	3	2	2			X			X
14	2	2	2			X			X
15	2	1	1	X			X		
16	3	2	2			X			X
17	2	2	2			X			X
18	2	2	2			X			X
19	2	1	0	X				X	
20	2	2	2			X			X
21	2	2	2			X			X
22	2	2	2			X			X
23	2	2	2			X			X
24	4	1	1	X			X		
25	2	2	2			X			X
26	2	1	1	X			X		
27	2	2	2			X			X
28	2	1	1	X			X		
29	2	2	2			X			X
30	2	2	2			X			X
31	2	1	1	X			X		
32	2	2	2			X			X
33	4	1	1	X			X		
34	2	2	2			X			X
35	2	2	2			X			X
36	2	1	1	X			X		
37	2	2	2			X			X
38	2	1	1	X			X		
39	2	2	2			X			X
40	2	2	2			X			X
41	2	0	0		X			X	
42	2	2	2			X			X
43	2	2	2			X			X
44	2	2	2			X			X
45	3	1	1	X			X		
46	2	2	2			X			X
47	2	2	2			X			X
48	2	2	2			X			X
49	2	2	2			X			X
50	2	2	2			X			X
				11	2	57	10	3	57

FAS Hemizygous %	0.22
FAS Homozygous %	0.04
Total FAS Deletion %	0.26

PTEN Hemizygous %	0.2
PTEN Homozygous %	0.04
Total PTEN Deletion %	0.24

SURGICAL PATHOLOGY REPORT

Patient Name:			Specimen #	-26388
Patient ID #			Procedure Date	11/2/2010
DOB/Age:		Gender	Accessioned:	11/2/2010
Address		M	Reported	11/3/2010
			Encounter	7215454
Location:			Inpatient	
Physician(s):				

Diagnosis:

1. LYMPH NODES, BILATERAL PELVIC, DISSECTION:
 - THREE LYMPH NODES NEGATIVE FOR METASTATIC TUMOR, 0/3.
2. PROSTATE, ROBOTIC SALVAGE ROBOTIC PROSTATECTOMY:
 - PROSTATIC ADENOCARCINOMA, GLEASON'S SCORE 4+5 = 9, WITH EXTRAPROSTATIC EXTENSION AND FOCALLY POSITIVE MARGIN, SEE PATHOLOGIC SUMMARY BELOW.
 - BILATERAL SEMINAL VESICLES POSITIVE FOR ADENOCARCINOMA.

PROSTATE RADICAL PROSTATECTOMY PATHOLOGY SUMMARY

Procedure: Radical prostatectomy.

Prostate Size:

Weight: 52 grams.

Size: 5.4 x 4.7 x 4.1 cm.

Lymph Node Sampling: Pelvic lymph node dissection.

Histologic Type: Adenocarcinoma (acinar, not otherwise specified).

Histologic Grade:

Gleason Pattern:

Primary Pattern: Grade 4.

Secondary Pattern: Grade 5.

Total Gleason Score: 9.

Tumor Quantitation: Proportion (percentage) of prostate involved by tumor: 30%.

Extraprostatic Extension: Present: Focal. Specify site(s): Right side.

Seminal Vesicle Invasion: Present, bilateral.

Margins: Margins focally involved by invasive carcinoma on the right side and left seminal vesicle.

Treatment Effect on Carcinoma: Radiation therapy effect present.

Lymph-Vascular Invasion: Present, focal.

Perineural Invasion: Present.

Pathologic Staging (pTNM):

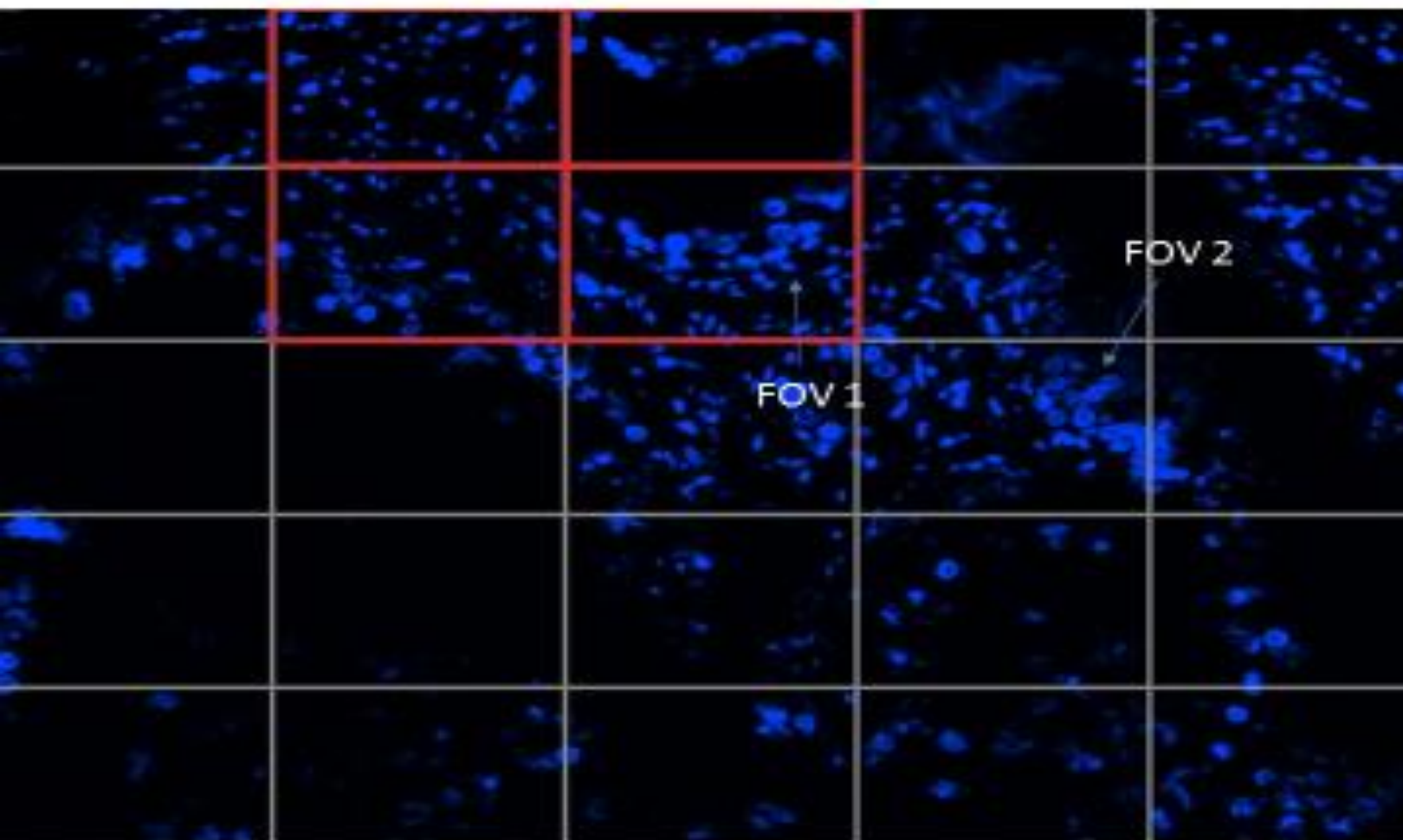
TNM Descriptors: y (post-treatment).

Primary Tumor (pT): pT3b: Seminal vesicle invasion.

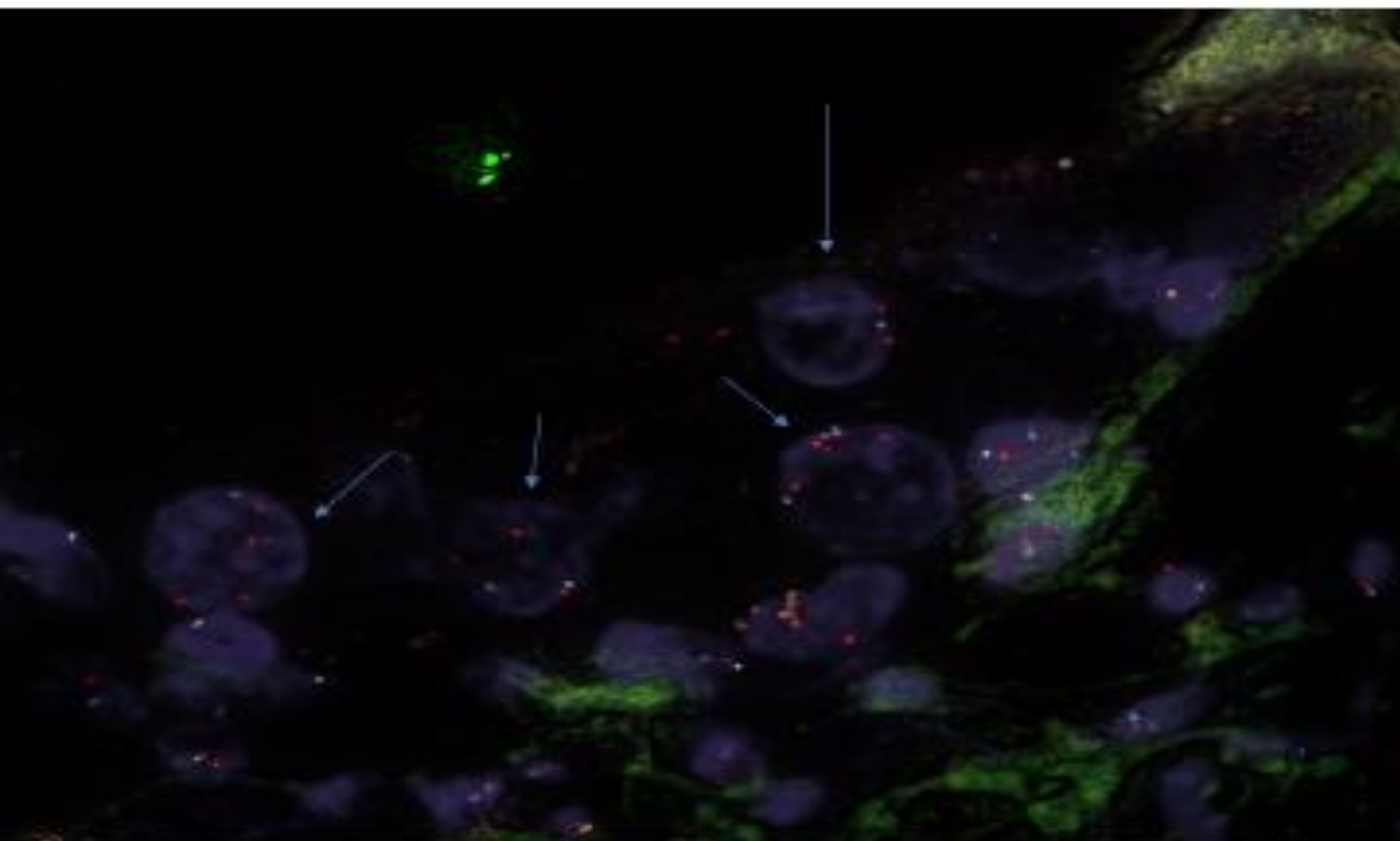
Regional Lymph Nodes (pN): pN0: No regional lymph node metastasis.

Distant Metastasis (pM): Not applicable.

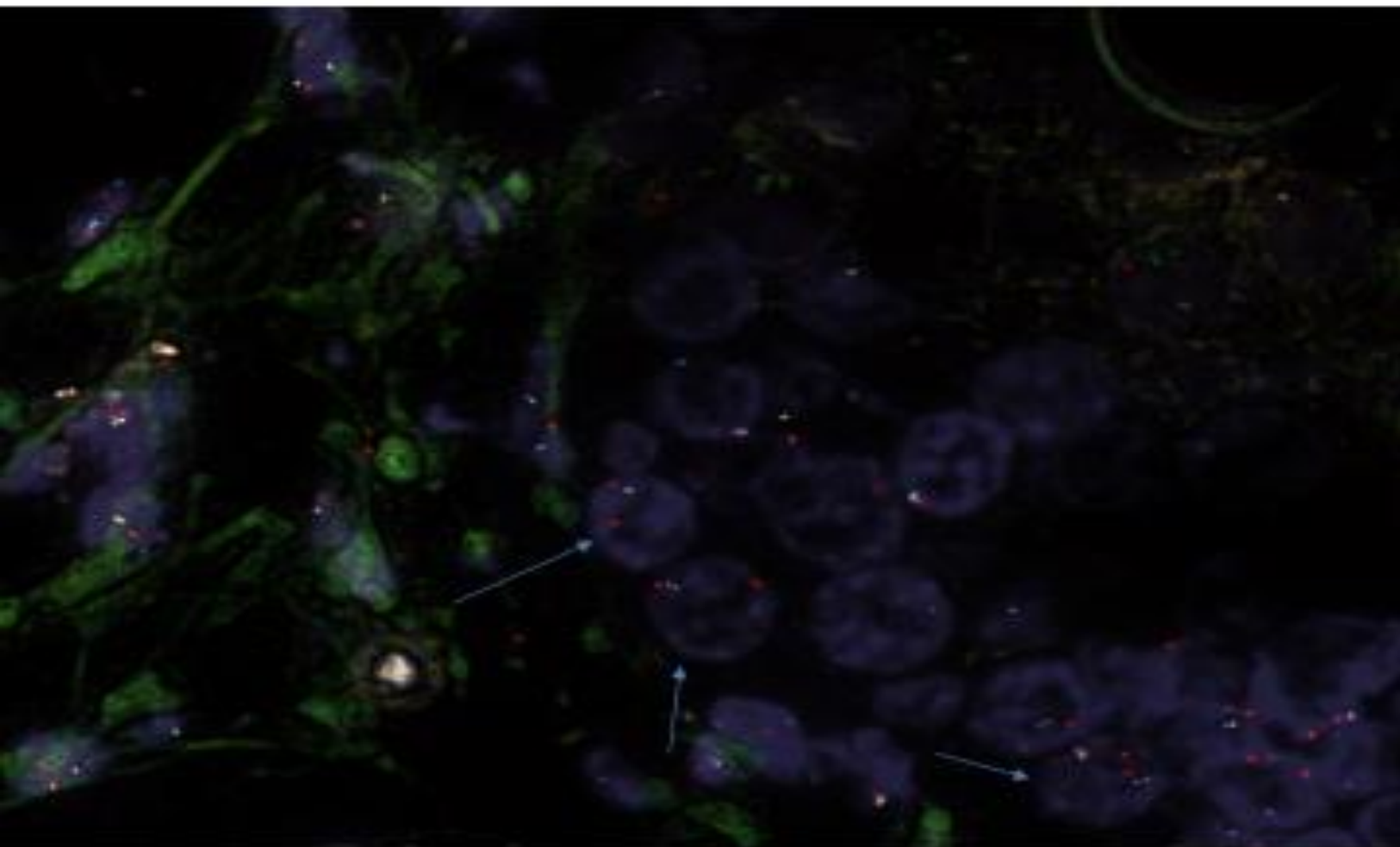
**METASTATIC PROSTATE
ADENOCARCINOMA TO SEMINAL VESICLE
26389 2Q
CONCOMITANT DELETION of FAS AND
PTEN #1**



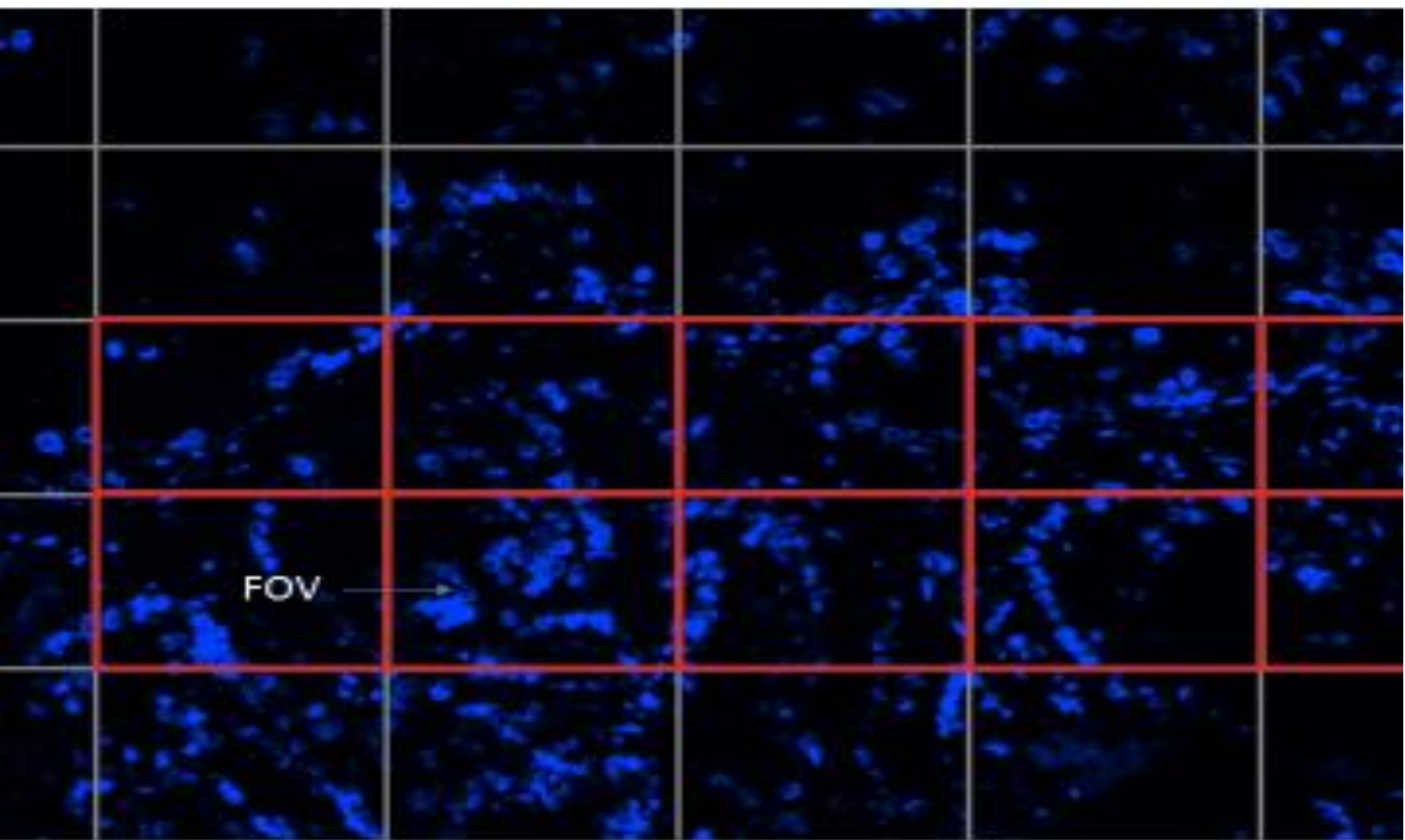
**FOV 1 COMBINATION 26389 2Q FAS/PTEN
DELETION**



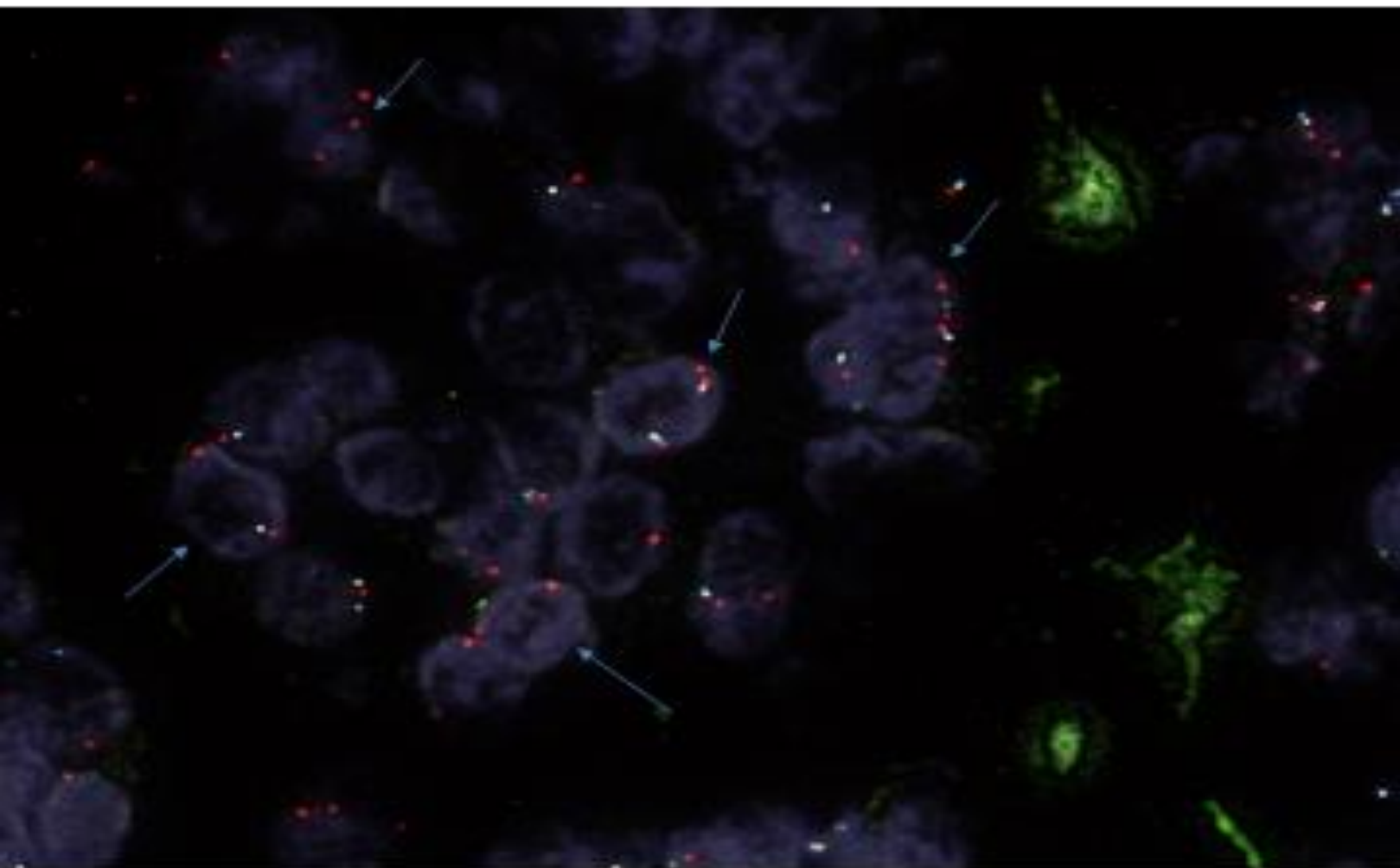
**FOV 2 COMBINATION 26389 2Q FAS/PTEN
DELETION**



**METASTATIC PROSTATE
ADENOCARCINOMA TO SEMINAL VESICLE
26389 2Q
CONCOMITANT DELETION of FAS AND
PTEN #2**



**FOV COMBINATION 26389 2Q FAS/PTEN
DELETION #2**



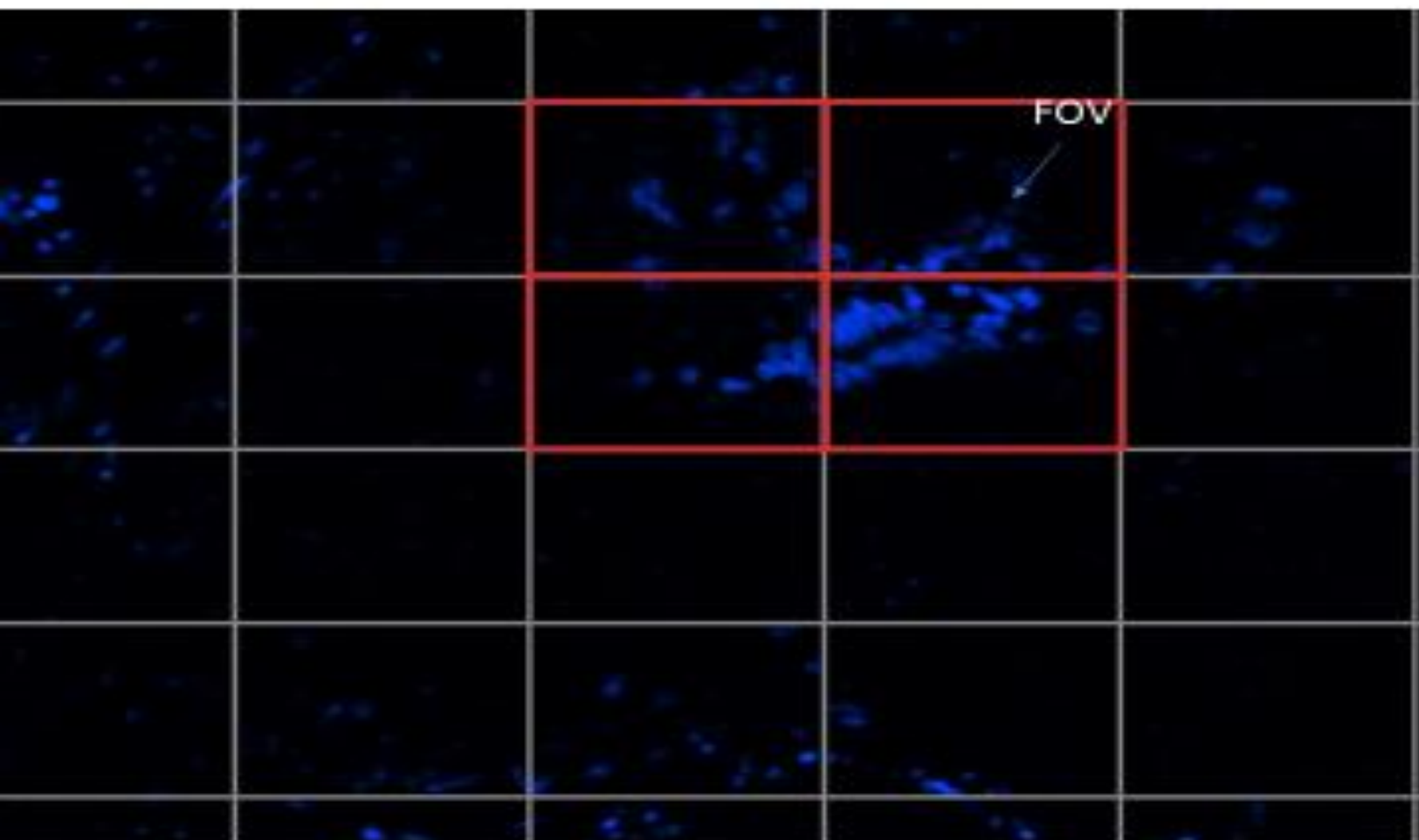
FAS Enumeration Chart

SLIDE ID		26389 2Q								
Cell	CEP 10	FAS	PTEN	FAS	FAS	FAS	PTEN	PTEN	PTEN	
	Loss	Loss	Loss	Normal	Normal	Normal	Normal	Normal	Normal	
1	2	2	2			X			X	
2	2	2	2			X			X	
3	2	2	2			X			X	
4	2	2	2			X			X	
5	2	2	2			X			X	
6	2	2	2			X			X	
7	2	1	0	X				X		
8	2	2	2			X			X	
9	2	2	2			X			X	
10	2	2	2			X			X	
11	2	2	2			X			X	
12	2	2	2			X			X	
13	2	1	1	X			X			
14	2	2	2			X			X	
15	2	1	1	X			X			
16	2	2	2			X			X	
17	2	2	2			X			X	
18	2	1	1	X			X			
19	2	2	2			X			X	
20	2	2	2			X			X	
21	2	2	2			X			X	
22	2	2	2			X			X	
23	2	1	0	X				X		
24	4	1	1	X			X			
25	2	2	2			X			X	
26	2	2	2			X			X	
27	2	2	2			X			X	
28	2	2	2			X			X	
29	2	2	2			X			X	
30	2	2	2			X			X	
31	2	2	2			X			X	
32	2	2	2			X			X	
33	2	0	0		X			X		
34	2	2	2			X			X	
35	2	2	2			X			X	
36	2	2	2			X			X	
37	2	1	1	X			X			
38	2	2	2			X			X	
39	2	1	1	X			X			
40	2	2	2			X			X	
41	2	2	2			X			X	
42	2	2	2			X			X	
43	2	2	2			X			X	
44	2	2	2			X			X	
45	2	0	0		X			X		
46	2	2	2			X			X	
47	2	2	2			X			X	
48	2	1	1	X			X			
49	2	2	2			X			X	
50	2	1	1	X			X			
				10	2	18	8	4	18	

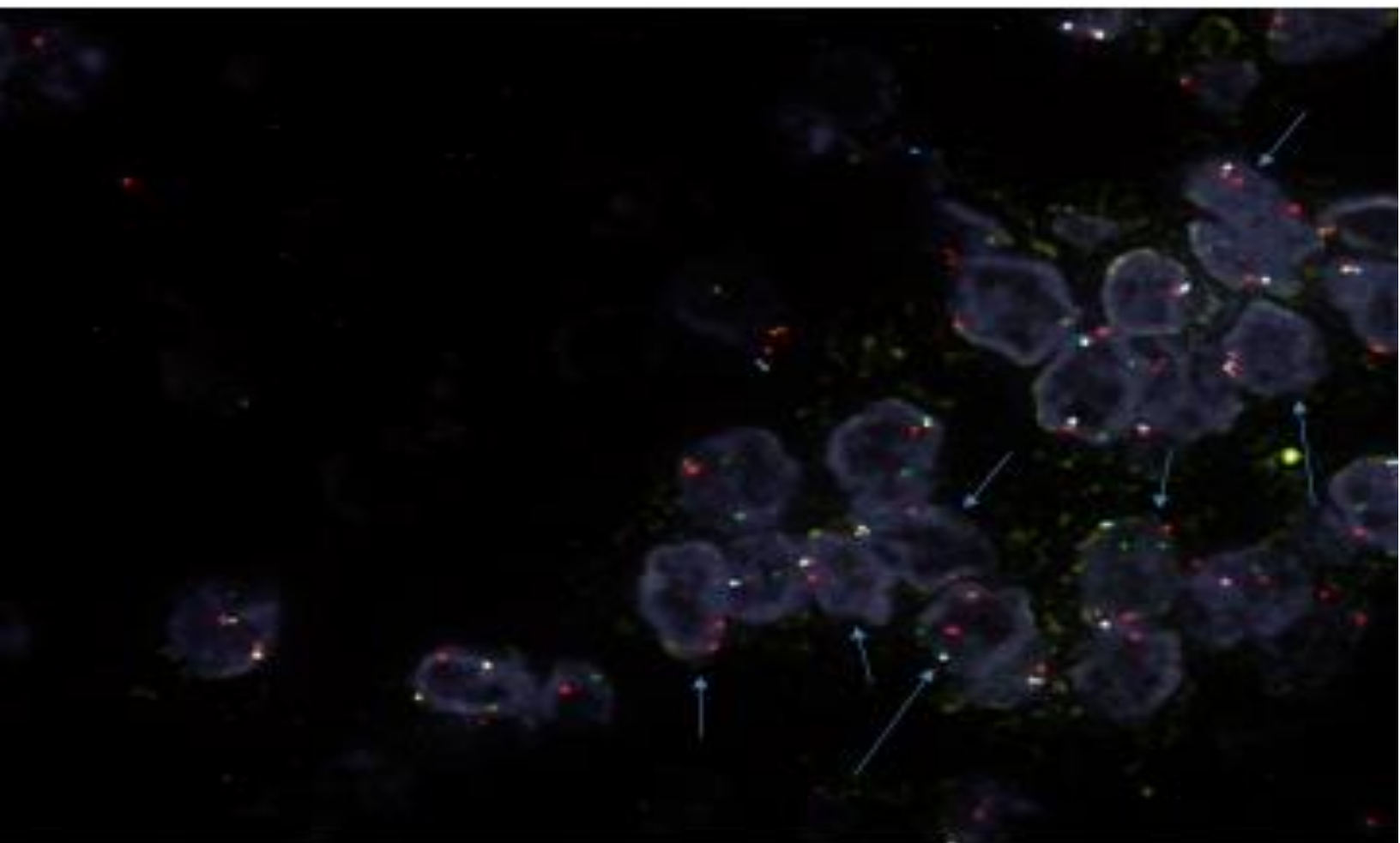
FAS Hemizygous %	0.2
FAS Homozygous %	0.04
Total FAS Deletion %	0.24

PTEN Hemizygous %	0.15
PTEN Homozygous %	0.08
Total PTEN Deletion %	0.24

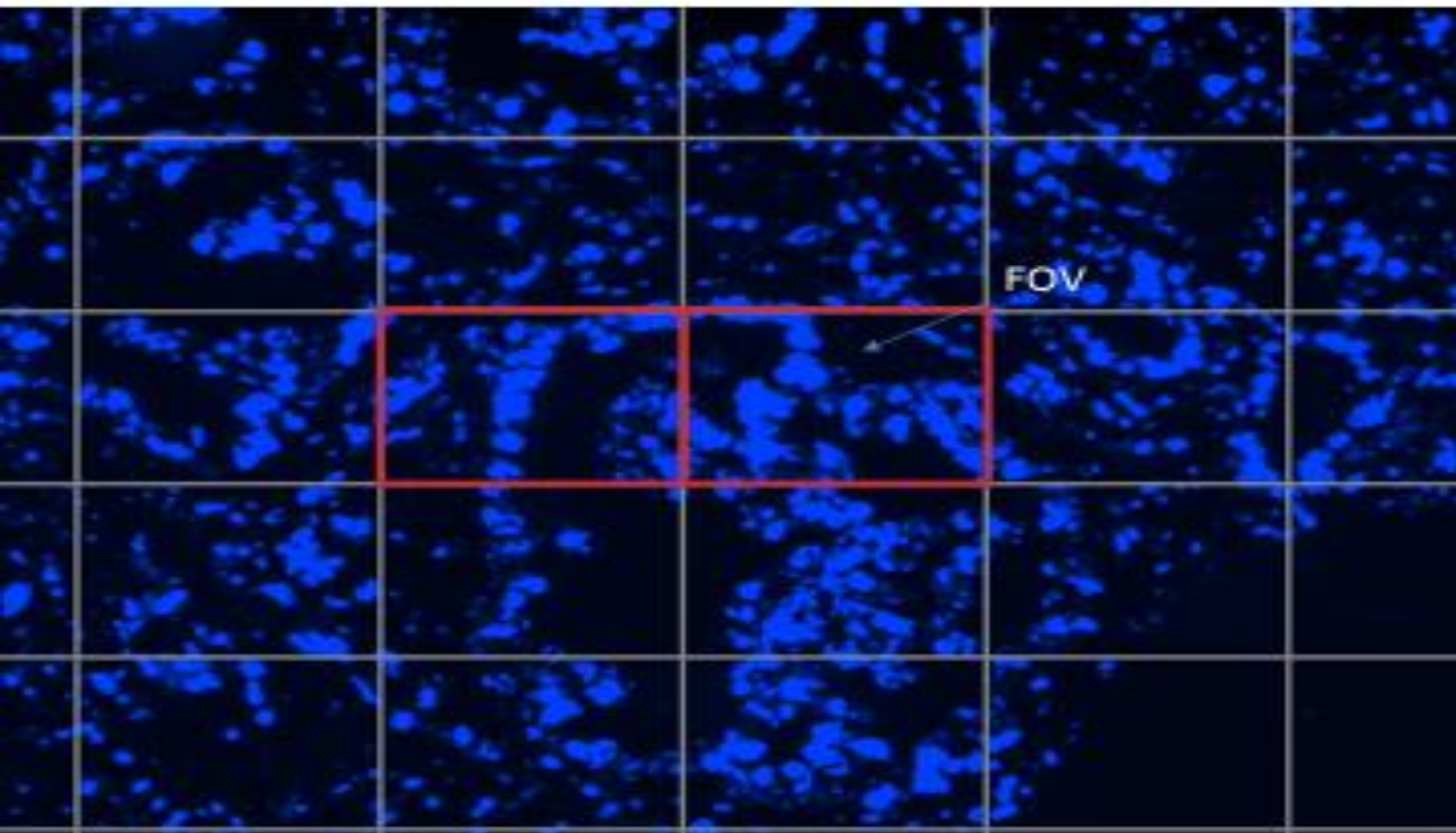
**METASTATIC PROSTATE
ADENOCARCINOMA TO SEMINAL VESICLE
26389 2R
COMCOMITANT DELETION of FAS AND
PTEN #1**



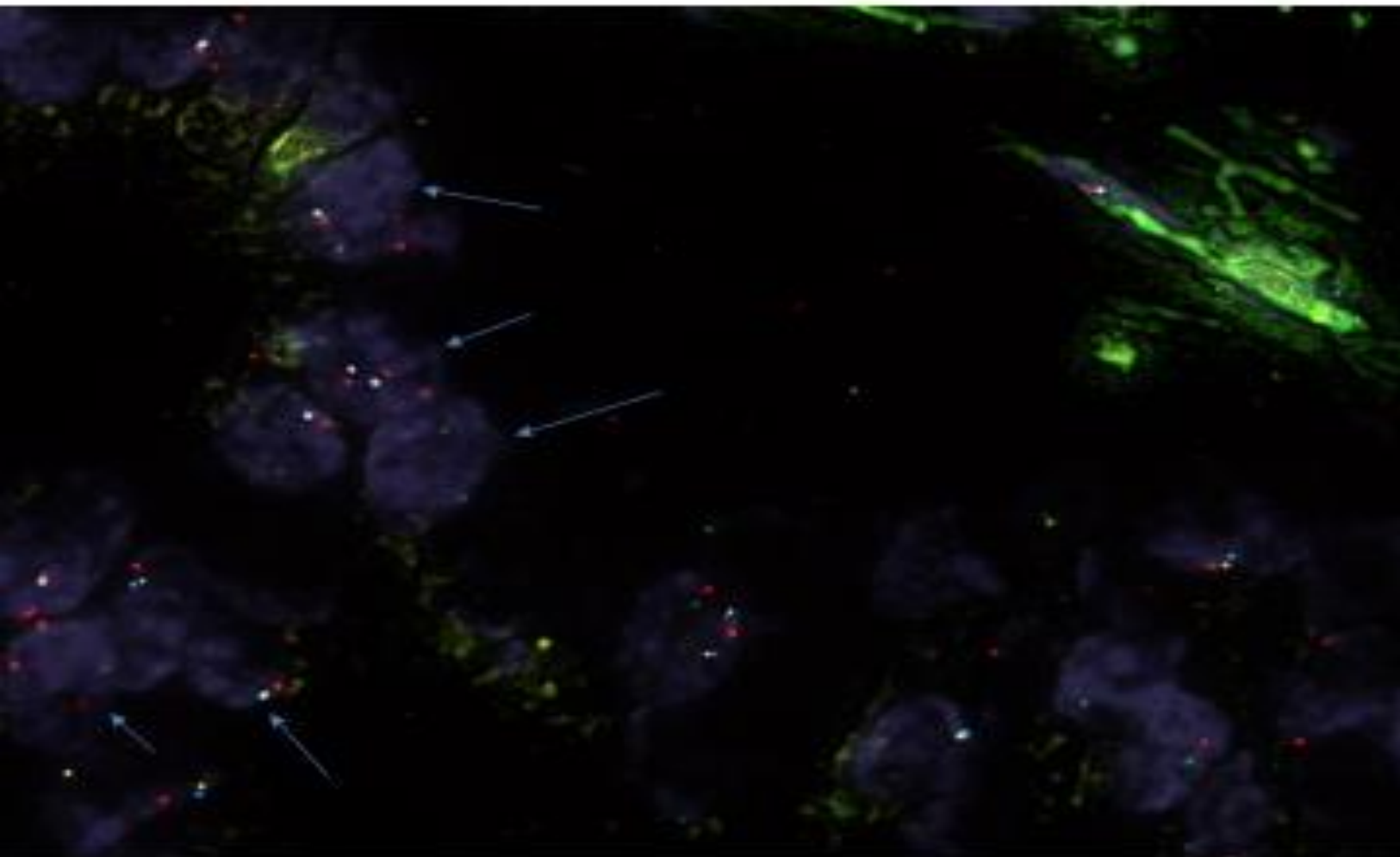
**FOV COMBINATION 26389 2R FAS/PTEN
DELETION #1**



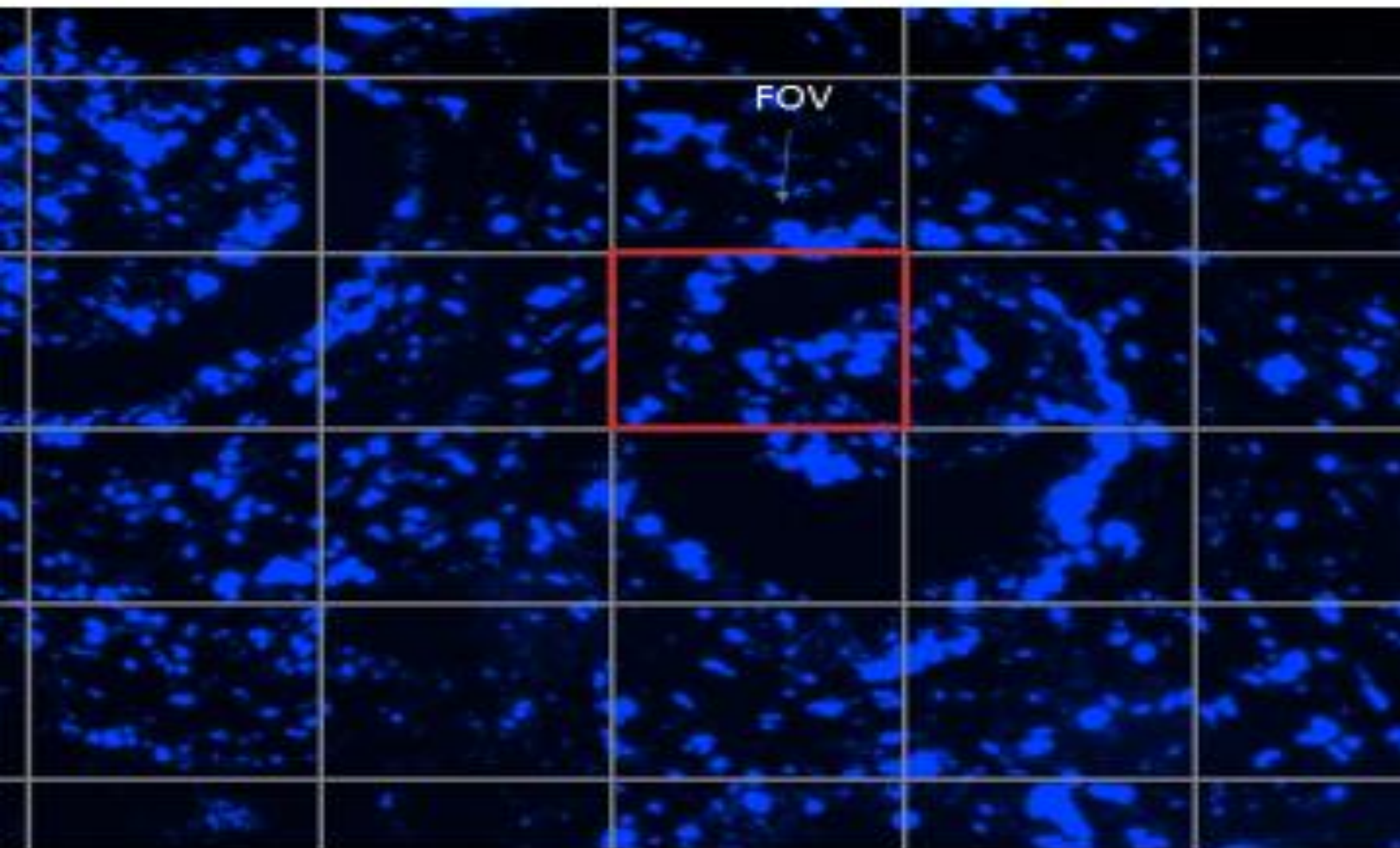
**METASTATIC PROSTATE
ADENOCARCINOMA TO SEMINAL VESICLE
26389 2R
CONCOMITANT DELETION of FAS AND
PTEN #2**



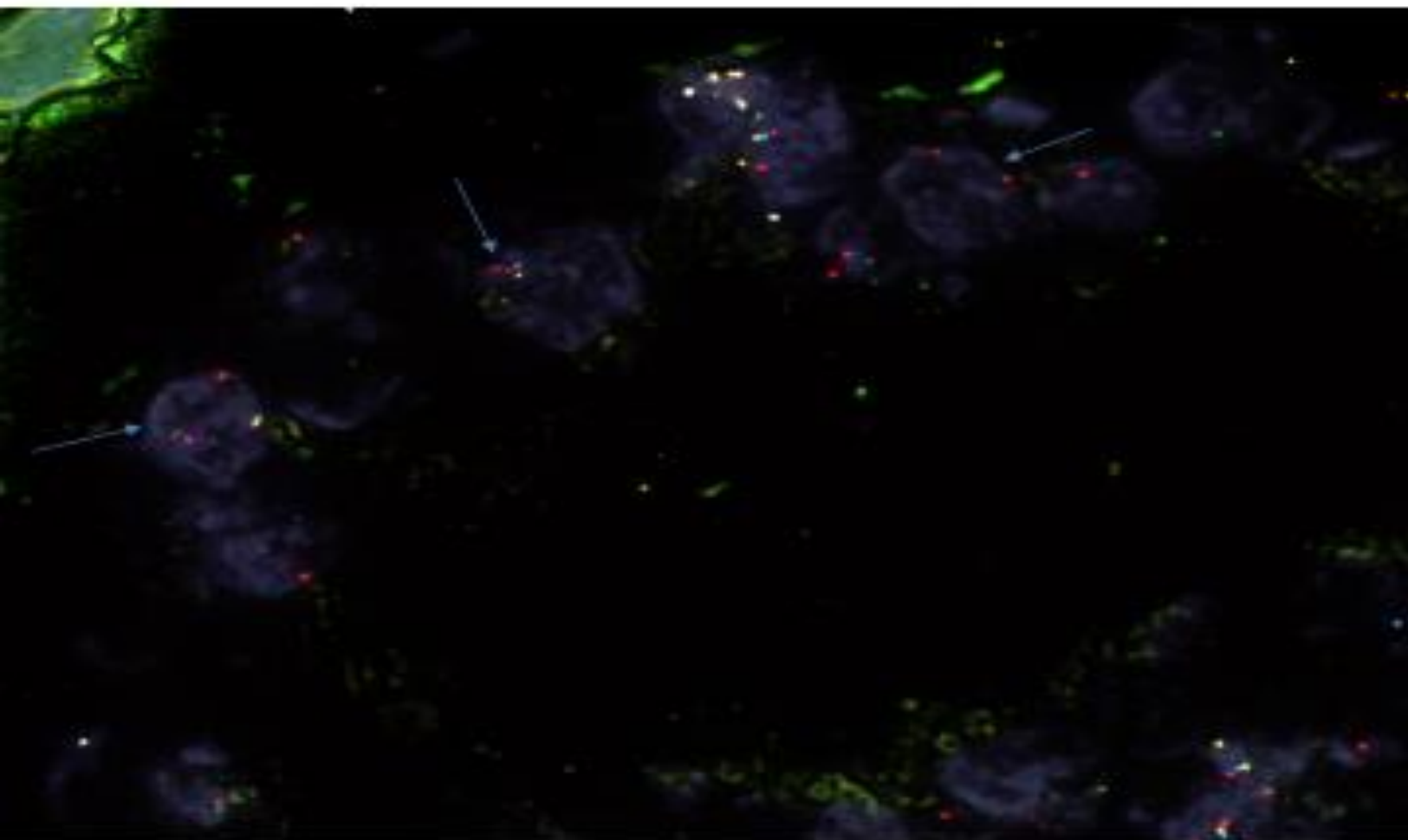
**FOV COMBINATION 26389 2R FAS/PTEN
DELETION #2**



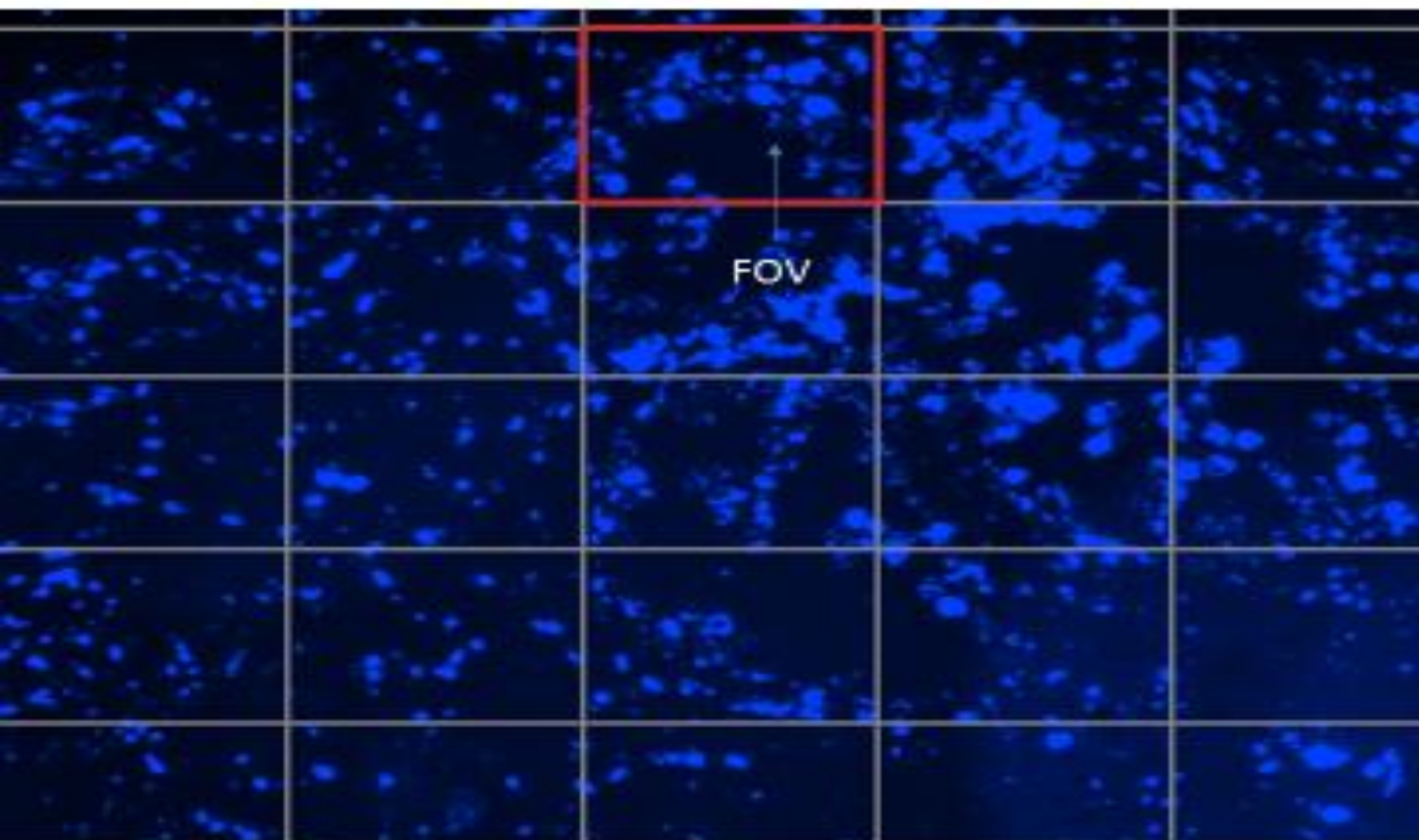
**METASTATIC PROSTATE
ADENOCARCINOMA TO SEMINAL VESICLE
26389 2R
CONCOMITANT DELETION of FAS AND
PTEN #3**



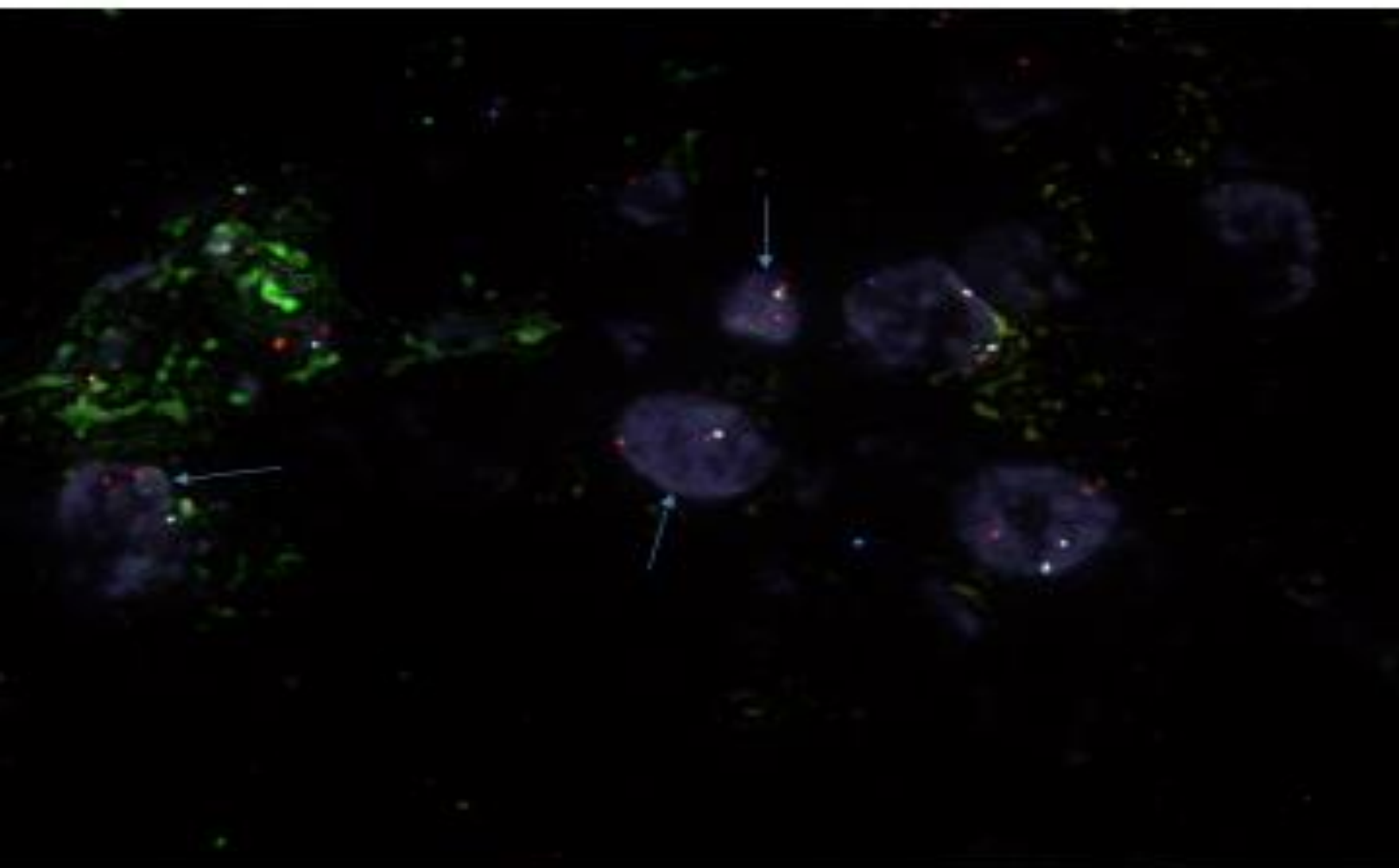
**FOV COMBINATION 26389 2R FAS/PTEN
DELETION #3**



**METASTATIC PROSTATE
ADENOCARCINOMA TO SEMINAL VESICLE
26389 2R
CONCOMITANT DELETION of FAS AND
PTEN #4**



**FOV COMBINATION 26389 2R FAS/PTEN
DELETION #4**



FAS Enumeration Chart

SLIDE ID		26389-2R								
Cell	CEP ID	FAS (RED)	PTEN (GOLD)	FAS Hemi	FAS Homo	FAS Normal	PTEN Hemi	PTEN Homo	PTEN Normal	
1	2	1	1	X			X			
2	2	2	2			X			X	
3	2	2	2			X			X	
4	2	0	0		X			X		
5	2	2	2			X			X	
6	2	2	2			X			X	
7	2	2	2			X			X	
8	2	1	1	X			X			
9	2	2	2			X			X	
10	2	2	2			X			X	
11	2	1	1	X			X			
12	2	1	1	X			X			
13	2	2	2			X			X	
14	2	1	1	X			X			
15	2	2	2			X			X	
16	2	2	2			X			X	
17	2	2	2			X			X	
18	2	2	2			X			X	
19	2	1	1	X			X			
20	2	2	2			X			X	
21	2	1	1	X			X			
22	2	1	1	X			X			
23	2	2	2			X			X	
24	3	1	1	X			X			
25	2	2	2			X			X	
26	2	2	2			X			X	
27	2	1	1	X			X			
28	2	2	2			X			X	
29	2	0	0		X			X		
30	2	2	2			X			X	
31	2	2	2			X			X	
32	2	1	1	X			X			
33	2	2	2			X			X	
34	2	1	1	X			X			
35	2	2	2			X			X	
36	2	1	1	X			X			
37	2	2	2			X			X	
38	3	1	1	X			X			
39	2	2	2			X			X	
40	2	2	2			X			X	
41	2	2	2			X			X	
42	2	2	2			X			X	
43	2	2	2			X			X	
44	2	2	2			X			X	
45	2	2	2			X			X	
46	2	2	2			X			X	
47	2	2	2			X			X	
48	2	2	2			X			X	
49	2	0	0		X			X		
50	2	1	1	X			X			
				15	3	32	15	3	32	

FAS Hemi zygous %	0.3
FAS homozygous %	0.09
Total FAS Deletion %	0.39

PTEN Hemi zygous %	0.3
PTEN homozygous %	0.09
Total PTEN Deletion %	0.39