



PATIENT MANAGEMENT

A Man with Acute Severe Pneumonia: Case Discussion from the University of Louisville Hospital

Viswanathan Nagarajan¹, Srinivas Dontineni¹, Veronica Corcino¹, Forest W. Arnold^{1*}

DOI: 10.18297/jri/vol3/iss1/8

Received Date: January 11, 2019

Accepted Date: February 2, 2019

<https://ir.library.louisville.edu/jri/vol3/iss1/>

Affiliations: ¹Division of Infectious Diseases, Department of Medicine, School of Medicine, University of Louisville

This original article is brought to you for free and open access by ThinkIR: The University of Louisville's Institutional Repository. It has been accepted for inclusion in The University of Louisville Journal of Respiratory Infections by an authorized editor of ThinkIR. For more information, please contact thinkir@louisville.edu.

Recommended Citation: Nagarajan, Viswanathan; Dontineni, Srinivas R.; Corcino, Veronica; and Arnold, Forest W. (2019) "A Man with Acute Severe Pneumonia: Case Discussion from the University of Louisville Hospital," *The University of Louisville Journal of Respiratory Infections*: Vol. 3 : Iss. 1 , Article 8.

Presentation of Case

Dr. Viswanathan Nagarajan (Infectious Diseases fellow): A 39-year-old previously healthy male presented to the emergency room for sudden onset left sided chest pain, cough with blood tinged sputum and shortness of breath, which started abruptly six hours prior to the presentation. He had been to another emergency room three days prior with myalgia, fever, headache, nausea, vomiting and diarrhea. Rapid influenza screen had been negative at that hospital. Nevertheless, he was discharged on oseltamivir. Now, shortness of breath was at rest and the chest pain was associated with cough and deep breathing. He also continued to have diarrhea and vomiting. Apart from having a 27 pack-year history of smoking, marijuana use and consuming a pint of alcohol every day, he had no history of intravenous drug use. He lived with his girlfriend, and denied promiscuous sexual activity or sex with males. He denied any travel outside of the US, or having pets at home. He had no known drug allergies.

His temperature was 38.8° Celsius, heart rate 130 beats/min, respiratory rate 33 breaths/min, blood pressure 151/83 mm Hg, and oxygen saturation 93% on room air (FiO₂ 21%). The patient was in moderate respiratory distress and was seen using accessory muscles of respiration. He was alert, but unable to speak up as his voice was feeble. He had no signs of clubbing or generalized lymphadenopathy. No needle tracks were observed. Lung auscultation revealed equal air entry on both sides with no changes in his inspiration to expiration ratio. Bilateral crackles and wheezing were noted on the entire left side. On percussion, no dullness or resonance was noted.

Diagnostic Approach

Dr. Julio Ramirez (Chief, ID): At this point, let's say you are working in the emergency room and are presented with this patient and do not have imaging or laboratory values yet. What do you think?


Dr. Srini Dontineni (ID fellow): It looks like a gentleman of 39 years without a history of medical problems who presents with fever, hemoptysis, myalgias and everything that appears to be an acute infectious process of the respiratory system and

community-acquired pneumonia (CAP). It looks bacterial and his recent influenza test was negative, so this is unlikely viral, but rather bacterial. The differential for bacterial CAP in this patient includes typical pathogens, such as, *Streptococcus pneumoniae*, *Haemophilus influenzae* and *Moraxella catarrhalis* as well as atypical pathogens, such as, *Chlamydia pneumoniae*, *Legionella pneumophila* and *Mycoplasma pneumoniae*.

Dr. Veronica Corcino (ID fellow): With an acute presentation of fever, nausea, and vomiting and developing respiratory symptoms that were more remarkable three days after being discharged from the emergency room, what is important for me is that he is a smoker (two or three packs per day). He could be colonized with many organisms. He also takes a half pint of alcohol and uses marijuana, so I agree with Dr. Dontineni's presentation that because of the respiratory symptoms, it could be pneumonia. What type of pneumonia? Maybe he started with some viral symptoms. He mentioned that he started with myalgias and fever the first time he went to the emergency room. I don't know if he was really negative for influenza, but he was discharged on oseltamivir. They may have been thinking about a false negative because of a known exposure to someone else. But the point is he may have had some viral infection and then developed a bacterial pneumonia. He also may have had so much alcohol that he lost consciousness and aspirated anaerobic bacteria, such as *Peptostreptococcus*, *Fusobacterium*, *Bacteroides*, or *Prevotella*. I would also consider *Klebsiella pneumoniae*. I also don't know if days before he had had a dental procedure? His symptoms now may be his immune system responding to *Pneumocystis jiroveci* pneumonia (PCP) or a bacterial infection, and specifically his pleuritic pain due a pneumothorax or to an abscess. As you know, community-acquired methicillin-resistant *Staphylococcus aureus*, and *Streptococcus* species including *S. pyogenes*, and *S. anginosus* may cause a severe pneumonia. Atypical organisms were mentioned and I agree.

I was thinking how to tie his vomiting and diarrhea with his respiratory symptoms. *Legionella* would explain both. If he had HIV, I would inquire about his GI symptoms. He is not a known intravenous drug user, but he does smoke marijuana,

*Correspondence To: Forest Arnold, DO, MSc
Work Address: 501 E. Broadway, suite 140 B Louisville, KY 40202
Work Email: f.arnold@louisville.edu

Copyright: © 2019 The author(s). This is an open access article distributed under the terms of the Creative Commons Attribution 4.0 International License (CC BY 4.0), which permits unrestricted use, distribution, and reproduction in any medium, provided the original author and source are credited. 

so there is a suspicion. Of course, if blood cultures are positive then he might have infective endocarditis, which is always in our differential. I think a fungal etiology is less likely.

Dr. Ramirez: You ran through the chapter of community-acquired pneumonia (CAP). You told us almost all the organisms that can cause CAP. Then, to both of you, if you can tell me one consideration, what do you think happened with this patient. What would be most likely?

Dr. Dontineni: Pneumonia acquired in the community.

Dr. Corcino: With these respiratory symptoms, we need to see the chest X-ray.

Dr. Ramirez: I know, but what would be the story? Don't tell me the differential.

Dr. Corcino: Acute viral syndrome that caused pneumonia.

Dr. Ramirez: I agree. The patient has a flu like syndrome for which he went to the ER and they did a rapid influenza test that was negative, but they are so convinced that it was a false-negative test that they sent the patient home with oseltamivir. So, it seems to me that the patient was having the influenza-like syndrome that is the classic post-influenza CAP. That's the story. Because the patient is a 39 year old with a respiratory rate of 33, 92% saturation on 2L/min of oxygen with a cough, you don't need a chest X-ray to diagnose pneumonia. Unless the patient had a pulmonary embolism at 3 o'clock in the morning, how do you explain a drop in saturation to 93% on 2L/min in a 39 year old? You have to have a massive VQ mismatch and most likely it is pneumonia. The history is interesting when he was in the ER of the other hospital. He doesn't complain of cough and all of a sudden at 3 o'clock in the morning he developed chest pain; he woke up with chest pain. You know this is classical for pneumococcal pneumonia. It is sudden pain like a knife [stabbing sound]. So this seems to me to be a case of post-influenza CAP due to *S. pneumoniae*, or possibly *S. aureus*. The patient had blood in his sputum, so he may have had necrotizing pneumonia from community-acquired MRSA. Then the way that this is forming in my mind is that it is community-acquired-MRSA due to USA 300 gene with Panton-Valentine leukocidin (PVL) toxin causing damage [1]. Then my primary consideration is probably post-influenza CA-MRSA or pneumococcal pneumonia.

On the CXR, we can expect to see cavities consistent with necrotizing pneumonia. We have discussed that *S. aureus* is now the second most common bacterial cause of CAP. So, when you list the most common pathogens causing CAP, remember to list *S. aureus*, and when you say *H. influenzae* and *M. catarrhalis*, also put *S. aureus*. This patient is too sick for a 39 year old to have *Mycoplasma pneumoniae* or *Chlamydia pneumoniae*. *Legionella pneumophila*, yes. It is not likely aspiration pneumonia, which is more subacute. You can aspirate all you want, but you will never be this hypoxic six hours later. You need time to develop the abscess and progress. Overall, I would consider these things, but from the long differential you listed, there are a lot of things that this is not. It has to be some acute organisms that can make a 39 year old severely sick.

Dr. Raghuram: One point I want to clarify—one of you mentioned that the rapid flu test was negative, so it was unlikely influenza, but the sensitivity of that test is between 50-70%, so just because it is negative doesn't mean that it is

unlikely. Another of you mentioned that since the patient is immunocompromised we should consider PCP, but this presentation is too acute to say that PCP should be in the differential, unless he has a pneumothorax. I agree with the comments that this could be post-influenza *S. pneumoniae* or *S. aureus*. And I think the third most common pathogen in this scenario is influenza. Even with influenza there are associated cardiac complications with myocarditis, pericarditis, or myocardial infarction, so any of that could be making this presentation worse.

Dr. Raff: Pneumococcal pneumonia classically has hyperbilirubinemia associated with it and often patients appear icteric at the onset. On the other hand, he has bilateral rales [crackles] and with pneumococcal pneumonia you expect single lobe involvement rather than bilateral. The rapid progression of hypoxia with intercostal retractions and the bloody sputum tends to be *S. aureus* as a necrotizing process. I agree that *H. influenzae* should also be considered [2]. Subsequently, it has been shown that paralysis of the mucociliary border and inactivity of pulmonary macrophages makes them susceptible to organisms in the nasopharynx - and the organisms are pneumococcus, *S. aureus*, *H. influenzae*, group A β -strep, *M. catarrhalis* (more in children than adults), and *Klebsiella pneumoniae* (which would explain the hemoptysis, especially in an alcoholic).

Dr. Ramirez: Yes, there are a number of bacteria that can cause pneumonia after having influenza. And that's why *H. influenzae* has its name - because it was isolated during outbreaks of influenza and it was thought to be the cause at a time before viruses were discovered. With the emergence of community-associated MRSA, there is a new concern.

Clinical Diagnosis

Post-influenza bacterial pneumonia

Hospital Course

Dr. Viswanathan: Initial labs were as follows. (Table 1) In addition, his lactic acid was 2.7 mmol/L, and increased to 5.4 mmol/L after six hours. His arterial blood gas on 21% FiO₂ had a pH of 7.43, pCO₂ of 26 mmHg, pO₂ of 63 mmHg and HCO₃ of 18 mmol/L. His total bilirubin was 14.1 mg/dL with direct being 8.7 mg/dL. Negative tests included an acute hepatitis panel, a human immunodeficiency virus test, and Streptococcal and Legionella urinary antigens. A rapid nasopharyngeal screen for respiratory syncytial virus was also negative, but for influenza A virus was positive.

Table 1 Initial labs for the patient in the emergency room.

WBC	3000 cells/mL
Hematocrit	45%
Platelets	121,000 cells/mL
Sodium	128 mmol/L
Potassium	3.8 mmol/L
Chloride	99 mmol/L
Creatinine	0.9 mg/dL
Glucose	183 mg/dL
Phosphate	1.0 mg/dL
AST	159 U/L
ALT	109 U/L
Total bilirubin	14.1 mg/dL
LDH	1888 U/L
ESR	4 mm/hr

ALT, alanine aminotransferase; AST aspartate aminotransferase; ESR, erythrocyte sedimentation rate; LDH, lactate dehydrogenase; WBC, white blood cell

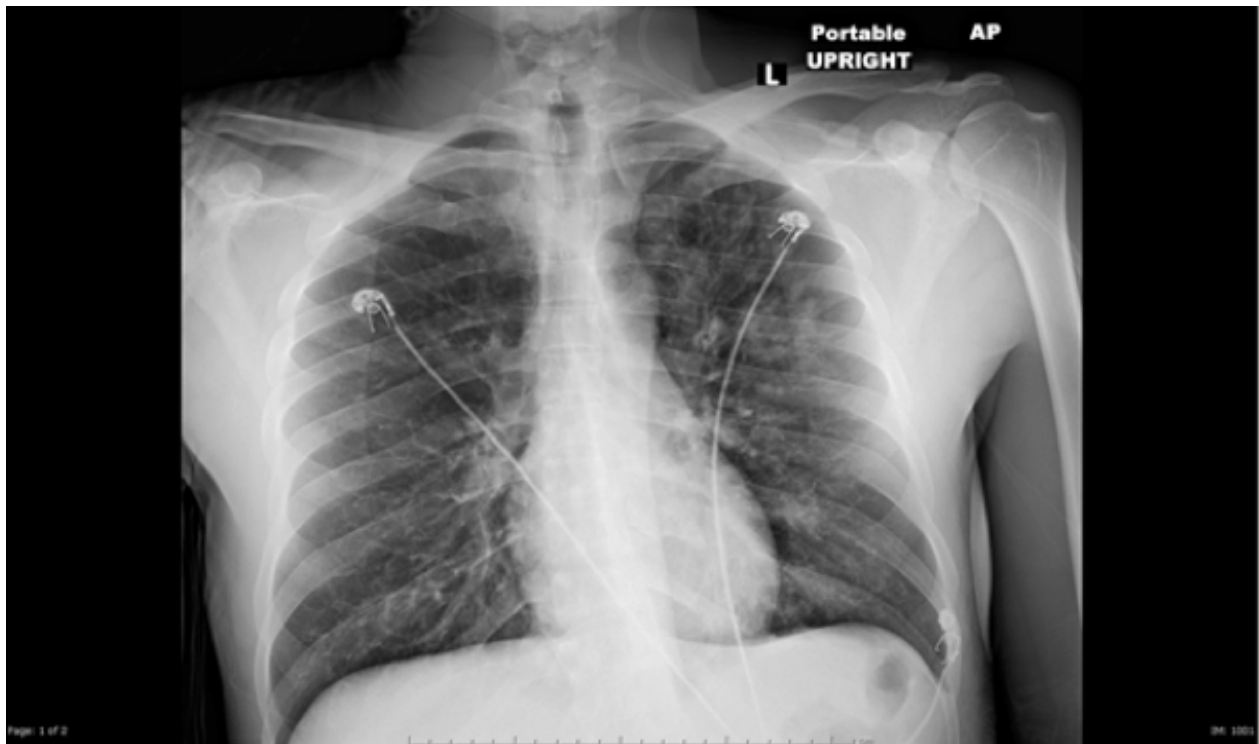


Figure 1 Chest radiograph of patient at presentation with respiratory distress.

Dr. Corcino: The only thing I would expect different in a healthy young male being this sick would be a higher white blood cell count.

Dr. Dontineni: The most notable abnormalities are his low platelets and his low pO_2 .

Dr. Ramirez: This emphasizes what we just discussed; that this patient is extremely sick with manifestations of CAP including sepsis, organ failure, a lactic acid of 5.4, platelets close to 100,000 cells/mL and a white blood cell count of only 3000 cells/mL. Again, any patient with severe CAP and neutropenia is community-acquired MRSA until proven otherwise.

Dr. Viswanathan: His chest radiograph was reviewed. **(Figure 1)**

Discussion

Dr. Dontineni: I don't see any infiltrate, consolidation, or pneumothorax. The costophrenic angles are clear and the trachea is in the midline.

Dr. Corcino: The right side may have the beginning of an infiltrate.

Dr. Ramirez: I am biased because after this presentation I am expecting something to be on the chest x-ray. The patient has left-sided chest pain and hemoptysis and he is telling me, in essence, to look at his left side. The outer one third of the lung is supposed to be very clear, and as you see, it is not clear on the left side. To me he has an infiltrate. I don't want to start imagining cavities because it is easy to do when you look at the edges of ribs.

Dr. Viswanathan: The report of the chest radiograph was "patchy bilateral airspace opacities (left greater than right); cardiomedial contours are within normal limits." A CT scan was obtained. **(Figure 2)**

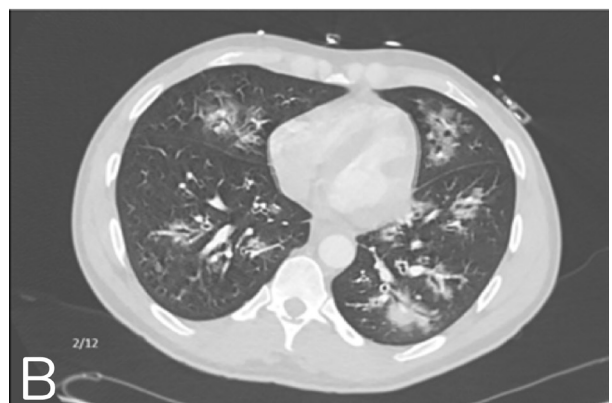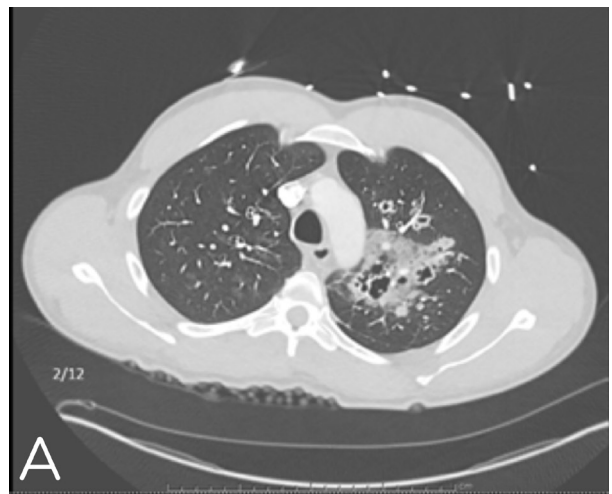


Figure 2
(A) CT scan of the chest showing extensive bronchial dilatation and wall thickening without pleural or pericardial effusions,
(B) Extensive bilateral cavitating pneumonia most likely representing septic emboli as well as mediastinal and hilar lymphadenopathy

Dr. Ramirez: These findings on the CT scan are impressive but you have to be able to find these changes on the portable film. There is data to show that you can miss up to 4% of infiltrates on a portable chest x-ray. There was a recent study of 300 pneumonia patients who received a portable chest radiograph and a CT scan [3].

There are some areas of necrosis inside of this infiltrate; perhaps an abscess or infiltrate around an airway with bronchopneumonia. There is lateral bronchopneumonia with upper lobe cavities highly suggestive of *S. aureus* USA 300 PVL toxin positive. This patient had several criteria for pneumonia due to this pathogen, so anti-MRSA treatment should be started in the emergency room in this circumstance, in addition to the other standard therapy for CAP.

Dr. Nagarajan: Blood cultures at 48 hours did not show any growth. The patient was transferred to ICU for hypoxic respiratory failure, and continued to be short of breath. Sputum for culture and AFB were obtained. He was placed in respiratory isolation and started on ceftriaxone and azithromycin.

Management

Dr. Ramirez: This patient was not placed on any anti-MRSA therapy on day one, except for clindamycin. The discussion in the emergency room for this patient should have been, "Does this patient get vancomycin, linezolid or ceftaroline? What is going to be the MRSA therapy?" Now we recognize that for community-acquired MRSA, there is not a single antibiotic that has been FDA approved. We use vancomycin or ceftaroline with clindamycin for the antitoxin effect, or linezolid, which already has this effect.

Another point is that the Gram's stain should be obtained and evaluated in the emergency room. We have an arrangement with microbiology that if the Division of Infectious Diseases orders a Gram's stain, microbiology will do it stat. If the patient has *S. aureus* pneumonia, the Gram's stain should have gram-positive cocci in clusters. This allows us to focus therapy for MRSA. It is interesting that they ordered clindamycin because they were considering an anaerobic infection due to aspiration, but they were actually helping in a different way because of the partial coverage for MRSA and its toxins.

Dr. Nagarajan: The CT of the chest was read as necrotizing cavitary pneumonia with septic emboli. His lactic acid improved to 1.4 mmol/L with intravenous fluids. He continued to be febrile (102.3°F), tachycardic (128 beats/min), and tachypneic (28 breaths/min) with a room air saturation of 94%. His antibiotics were changed to vancomycin, clindamycin, piperacillin/tazobactam and levofloxacin. After 72 hours on the ward, he was transferred back to ICU, for worsening respiratory status with a heart rate of 132 beats/min and a temperature of 103.2°F. The sputum culture grew MRSA after 27 hours.

Dr. Ramirez: For the fellows, we get so accustomed to the patient who is in the age range of 60-97 years. When we have a patient who is less than 40, we have a totally different type of patient. This patient who has multi-organ system failure and evidence of sepsis needs to be monitored closely. Furthermore, every patient who has sepsis is dehydrated and will improve slightly with rehydration, but this is not the point. MRSA is an aggressive form of pneumonia. When does the MRSA stop necrotizing the lungs? You need three or four days of antibiotics.

For the first one or two days of antibiotics, no clinically relevant pathophysiological progress occurs. And if vancomycin is started, it takes a while to become therapeutic; sometimes days. What was the Gram's stain?

Dr. Nagarajan: I didn't look at it. The blood cultures grew MRSA three times in four days. His transesophageal echo was negative for any vegetations.

Dr. Ramirez: We should always look at the Gram's stains. So, he had persistent MRSA bacteremia.

Dr. Raff: What percentage of patients with staphylococcal pneumonia are demonstratively bacteremic?

Dr. Ramirez: You know it's interesting and I don't know the percentage, but we just put an opinion piece in ULJRI (The University of Louisville Journal of Respiratory Infections) of how to treat *S. aureus* pneumonia with bacteremia [4]. We suspect that it is high because *S. aureus* is an aggressive pathogen. For pneumococcal pneumonia, bacteremia is 20-30% [5], but for *S. aureus*, we don't have a value.

I am reminded of when community-acquired MRSA first came about. This patient reminds me of a 35-year-old female who was admitted and died. She developed bronchopneumonia, was admitted to the ward and then transferred to the ICU where she was intubated and mechanically ventilated. She had an empyema complicated by a fistula and then she died of multi-organ failure. It took years to establish empiric therapy for MRSA in CAP patients with risk factors. We actually don't know if community-acquired MRSA is more virulent or if community-acquired MRSA becomes worse because coverage for MRSA is delayed for the first 48 hours.

Who is responsible here? Many pathogens causing pneumonia are aggressive, and a patient may die if treatment is delayed for 48 hours. There is discussion that receiving antibiotics within 4 hours of presenting to the hospital may be associated with better outcomes than 8 hours. Imagine not receiving antibiotics for 48 hours! This patient was started on vancomycin on the second day over 24 hours after presenting to the hospital with a level that probably wasn't therapeutic for another day or two.

This patient has bronchopneumonia and now we start seeing what was a tiny area on the initial X-ray. We can now clearly see necrotizing pneumonia. At this point, some expert opinions suggest administering immunoglobulins for this patient, although there is not data to support its use. The idea is that since PVL is just one toxin among many that we are exposed to throughout our lifetime from *S. aureus*, and to which we develop antibodies, immunoglobulin therapy may be another way to treat severe Staphylococcal infection. So this would be going back in history to give antibodies for pneumonia the same way they did in the pre-penicillin era.

Dr. Raff: Except they were using horse serum!

Dr. Ramirez: Yes; horse serum. So, here we would be giving antibiotics, antitoxins and immunoglobulins (meaning antibodies).

Dr. Nagarajan: The ICU started levofloxacin then de-escalated antibiotics to only vancomycin.

Table 2 Vancomycin levels, dosing and creatinine values for specific days of the patient's hospitalization.

Day	Vancomycin Level (µg/mL)	Vancomycin Dosing	Serum Creatinine (mg/dL)
1		2250 mg once	1.23
2	12.1	1500 mg q12 hrs	0.98
4	8.4	1250 mg q8 hrs	0.79
6	12.8	1500 mg q8 hrs	0.62
8	9.8	1750 mg q12 hrs	0.59
10	9.3	2500 mg q8 hrs	0.50
11	19.6	2250 mg q8 hrs	0.59

Dr. Ramirez: The point here is that in our study of community-acquired MRSA pneumonia, there is no study that is perfect. Linezolid was associated with better outcomes than vancomycin. But in all the studies comparing vancomycin and linezolid the question was whether linezolid is actually better or is vancomycin worse since a level was not therapeutic for the initial days. If we use vancomycin, we need to give a loading dose to be sure we get a therapeutic level on day one. And this is what you had here, except even with the loading dose you didn't have a therapeutic level until day four or five. For severely ill patients with community-acquired MRSA, we cannot be dependent on an antibiotic if we don't know that it is therapeutic on day one. Another point is that we do not typically even get a level on day one, because we know that the level is going to be low. Is six hours or eight hours going to make a difference? In this population, probably so. For these patients we should not use vancomycin.

Dr. Nagarajan: Pharmacy recommended the dosing. (Table 2) There was a difficulty bringing vancomycin to therapeutic levels.

Dr. Ramirez: This reminds me of the patients in the trauma unit years ago who had persistently low levels of aminoglycoside in the surgical ICU. It didn't matter how much antibiotic we gave them, the levels never reached a therapeutic range because they metabolized it so quickly. Some young people were very difficult to attain a therapeutic level for an antibiotic. To me, the drug of choice for MRSA pneumonia is linezolid.

Dr. Nagarajan: He did reach a therapeutic level of 19 µg/mL on 2.5 g of vancomycin every eight hours on hospital day # 11. Linezolid was added on day four. And vancomycin was continued.

Dr. Ramirez: Eleven days?! I don't need to emphasize my point any further. What was the MIC to vancomycin?

Dr. Nagarajan: One. The organism was found to be sensitive to vancomycin, clindamycin, tetracycline, trimethoprim/sulfamethoxazole and linezolid. On hospital day 12, he developed right-sided weakness and an MRI showed nonspecific changes. Another TEE found a small PFO with no vegetation. Ultimately, he defervesced and his oxygen saturation improved to 96% on room air with linezolid the following day.

Dr. Ramirez: When the community-associated MRSA epidemic started here, we had a few patients die with pneumonia. I remember that it was a big debate because linezolid was still very expensive, and its use was restricted to the Division of Infectious Diseases. The problem was that Infectious Diseases was being called on day three, which was preventing patients from linezolid's early antitoxin benefit. So, with the antimicrobial stewardship team, we approached the emergency department and told them that we wanted them to use linezolid in a young person with a multilobar infiltrate, hemoptysis, and neutropenia who was going to be admitted to the ICU for CAP- and that they did not need Infectious Diseases' approval. This was because we preferred to stop inappropriate linezolid after 24 hours rather than have appropriate patients go without it for 48 hours. We need to reemphasize our use of anti-MRSA therapy in the emergency department.

Dr. Nagarajan: The strategy that this division has used in the past for patients with this diagnosis is summarized in an article by Dr. Peyrani and Dr. Ramirez. [6].

Anatomical Diagnosis

Post-influenza MRSA pneumonia complicated with bacteremia and hypoxic respiratory failure.

This case was presented at the University of Louisville Division of Infectious Diseases Patient Management Conference.

References

- Gillet Y, Issartel B, Vanhems P, Fournet JC, Lina G, Bes M, et al. Association between *Staphylococcus aureus* strains carrying gene for Panton-Valentine leukocidin and highly lethal necrotising pneumonia in young immunocompetent patients. *Lancet*. 2002 Mar 2;359(9308):753-9
- Boonsarngsuk V, Thungtitigul P, Suwatanapongched T. Chronic *Klebsiella pneumoniae*: a rare manifestation of *Klebsiella pneumoniae*. *J Thorac Dis*. 2015 Sep;7(9):1661-4. PMID:26543615
- Self WH, Courtney DM, McNaughton CD, Wunderink RG, Kline JA. High discordance of chest x-ray and computed tomography for detection of pulmonary opacities in ED patients: implications for diagnosing pneumonia. *Am J Emerg Med*. 2013 Feb;31(2):401-5.
- Ramirez J, File T, Musher D. Duration of antibiotic therapy for patients with bacteremic *Staphylococcus aureus* community-acquired pneumonia. *The University of Louisville Journal of Respiratory Infections*. 2018;2(1):1. <https://doi.org/10.18297/jri/vol2/iss1/1/>.
- Said MA, Johnson HL, Nonyane BA, Deloria-Knoll M, O'Brien KL, Andreo F, et al.; AGEDD Adult Pneumococcal Burden Study Team. Estimating the burden of pneumococcal pneumonia among adults: a systematic review and meta-analysis of diagnostic techniques. *PLoS One*. 2013;8(4):e60273. <https://doi.org/10.1371/journal.pone.0060273> PMID:23565216
- Peyrani P, Ramirez J. What is the best therapeutic approach to methicillin-resistant *Staphylococcus aureus* pneumonia? *Curr Opin Infect Dis*. 2015 Apr;28(2):164-70. <https://doi.org/10.1097/QCO.000000000000149> PMID:25692268.