



12-1-1999

Analysis of Exhumed Skull of Marilyn Sheppard

Thomas Holland

How does access to this work benefit you? Let us know!

Follow this and additional works at: https://engagedscholarship.csuohio.edu/sheppard_forensic

Recommended Citation

Holland, Thomas, "Analysis of Exhumed Skull of Marilyn Sheppard" (1999). *Forensic Medicine*. 5.
https://engagedscholarship.csuohio.edu/sheppard_forensic/5

This Dr. Thomas Holland, defendant's expert is brought to you for free and open access by the 2000 Trial Expert Reports and Tests at EngagedScholarship@CSU. It has been accepted for inclusion in Forensic Medicine by an authorized administrator of EngagedScholarship@CSU. For more information, please contact library.es@csuohio.edu.

THOMAS D. HOLLAND, PhD

94-090 Kaweloali'i Place
Mililani, Hawai'i 96789
(808) 448-8032

1 December 1999

William D. Mason
Cuyahoga County Prosecutor
Justice Center, Courts Tower
1200 Ontario Street
Cleveland, Ohio 44113

Re: Analysis of skull associated with Cuyahoga County Medical Examiner Case 76629

BACKGROUND: On 5 October 1999 remains were disinterred from a mausoleum crypt in Mayfield Heights [Cleveland], Ohio, by direction of the Cuyahoga County [Ohio], Prosecutor. The remains were identified by cemetery records as those of Marilyn Reese Sheppard. Upon disinterment the casketed remains were taken to the Cuyahoga County Medical Examiner's office for analysis. Anthropological analysis was confined to the mandible and cranium and was conducted in the presence of Dr. C. Owen Lovejoy, a physical anthropologist representing the Medical Examiner. The remains were examined on 5 October 1999 and reinterred the following day.

DESCRIPTION OF REMAINS: The skull and mandible are those of a young, gracile, caucasoid female. There was a thin layer of desiccated soft tissue (skin) adhering to the bone upon first examination. Some of this adherent tissue was flaked off using a dental explorer to facilitate analysis. The skull had been previously reconstructed using a white substance that appeared upon examination to be plaster of Paris (hereafter termed plaster). The entire cavity of the skull was filled with plaster to the extent that it extruded through the foramen magnum. The frontal bone was largely missing, having been replaced by plaster. There is an apparent autopsy cut that intersects fractured bone on the left side of the skull at the coronal suture near the temporal line and on the right side at the juncture of the right parietal and the right temporal bones immediately superior of the mastoid process.

DESCRIPTION OF FRACTURES: There are no readily apparent fractures of the mandible upon gross examination, although several teeth (including a prosthetic cap) are damaged (these are addressed in a report by Dr. Lowell J. Levine, Forensic Odontologist). The fractures of the cranium are typical of blunt force trauma and are localized in four areas: upper face, middle face, right lateral vault, and left lateral vault (References 1, 2, 3, and 4).

Upper Face: There is an impact focal point located on the frontal bone approximately 1.5 cm above the medial margin of the left orbit. Fractures radiate from this point to involve both orbits. This focal point corresponds to the location of a soft tissue wound noted during the 1954 autopsy of Marilyn Reese Sheppard (Injury number 3, page 2, Report of Autopsy, Case 76629 [Reference 5]). Color photographs from the 1954 autopsy of Marilyn Reese Sheppard supplied by the Cuyahoga County Prosecutor's office suggest a second impact focal area nearer the midline of the frontal bone (References

6 and 7). The location of this focal point corresponds to the location of another soft tissue wound noted during the 1954 autopsy (Injury number 4, page 2, Report of Autopsy, Case 76629 [Reference 5]). A color autopsy photograph (Reference 8) showing soft tissue injuries supports the autopsy report in placing two wounds over these impact foci. Unfortunately the absence of many of the frontal bone fragments precludes determining the precise location of additional impact foci.

Mid Face: Fractures to the mid face can be classified as *LeFort I* with complete separation of the maxillae. In addition, there are fractures running from the inferior margin of both orbits through the maxillary sinuses. These fractures intersect the fracture lines of the *LeFort I* near the zygomatic processes. The combination of frontal and maxillary fractures results in the separation of the nasal region of the face. This separation of the nasal region is reflected in the autopsy report, which indicated fracturing of the "nasal bone with crepitus on manipulation" (Injury number 21, page 3, Report of Autopsy, Case 76629 [Reference 5]). In fact, it was not the nasal bone, per se, that was fractured but rather the entire nasal region was segmentally fractured. Additionally, there are fractures through the frontosphenoid process of the right zygomatic near the fronto-zygomatic suture and through the left zygomatic process of the frontal bone.

Right Lateral Vault: There is a depressed fracture of the right temporal bone with involvement of the right greater wing of the sphenoid. A review of an autopsy photograph showing the soft tissue injuries to the right side of the head suggests a contused area between the right ear and the right eye (Reference 9). The 1954 autopsy report (Injury number 16, page 3, Report of Autopsy, Case 76629 [Reference 5]) and the autopsy photograph reveal a small laceration in the same area. The location of these injuries corresponds closely to the area of depressed bone.

Left Lateral Vault: A fracture line radiating from the frontal bone crosses the coronal suture involving the left parietal bone superior to the squamosal suture. The inferior margin of the autopsy cut intersects this fracture.

OBSERVATIONS: The presence of a large mass of plaster in the cranial vault precluded visual examination of the endocranial surfaces of the cranium for evidence of trauma. Similarly, the plaster mass precluded the use of radiographs. The presence of desiccated soft tissue on both the cranium and mandible may also have obscured small and micro fractures. The absence of several frontal bone fragments seen in autopsy photographs from 1954 also precluded the accurate determination of the minimum number of impact foci.

CONCLUSIONS: The cranium and mandible disintegrated from the crypt of Marilyn Reese Sheppard are those of a young adult caucasoid female who experienced blunt-force trauma to the face, forehead, and right side of the head.



Thomas D. Holland, PhD, DABFA
Forensic Anthropologist

REFERENCES

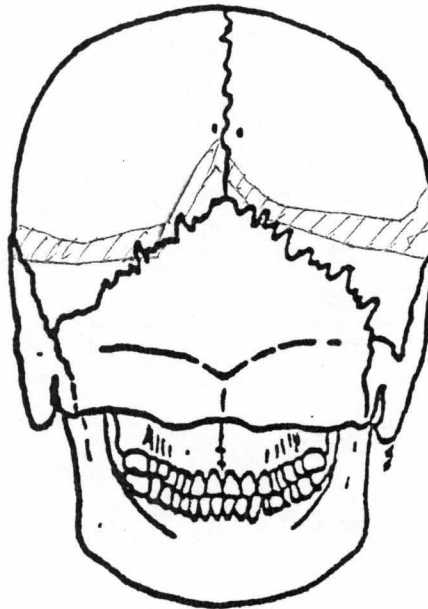
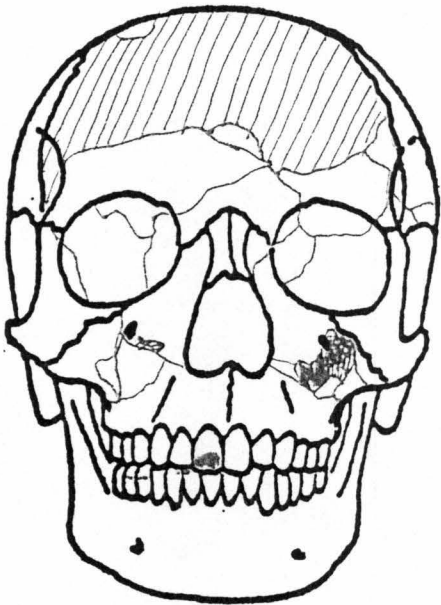1. Color Photograph on CD-ROM 76629-03, MSEXNEG 011.tif
2. Color Photograph on CD-ROM 76629-03, MSEXNEG 024.tif
3. Color Photograph on CD-ROM 76629-03, MSEXNEG 029.tif
4. Skull Diagram Showing Primary Fracture Lines. Hand labeled at top "Case 76629 TDH 5/OCT/99"
5. Xerographic Copy: Report of Autopsy Held on the Body of Marilyn Sheppard, Case No. 76629, Autopsy No. M-7280, Date: 7-4-54; S.R. Gerber, M.D., Coroner, Cuyahoga County, State of Ohio [Copy marked Cuyahoga County Coroner's Office March 1996 Case #76629 A-1];
6. Color Photograph; 5x7 inches; Labeled on Back: "SET NUMBER 3, 19, Cuyahoga County Coroner's Office Photography Dept Cleveland Ohio 44106 Name: Marilyn Reese Sheppard Case: 76629 Autopsy: M-7280 Date Of Death: 07/04/54; Not To Be Copied Without Permission"
7. Color Photograph; 5x7 inches; Labeled on Back: "SET NUMBER 3, 22, Cuyahoga County Coroner's Office Photography Dept Cleveland Ohio 44106 Name: Marilyn Reese Sheppard Case: 76629 Autopsy: M-7280 Date Of Death: 07/04/54; Not To Be Copied Without Permission"
8. Color Photograph; 5x7 inches; Labeled on Back: "SET NUMBER 3, 3, Cuyahoga County Coroner's Office Photography Dept Cleveland Ohio 44106 Name: Marilyn Reese Sheppard Case: 76629 Autopsy: M-7280 Date Of Death: 07/04/54; Not To Be Copied Without Permission"
9. Color Photograph; 5x7 inches; Labeled on Back: "SET NUMBER 3, 7, Cuyahoga County Coroner's Office Photography Dept Cleveland Ohio 44106 Name: Marilyn Reese Sheppard Case: 76629 Autopsy: M-7280 Date Of Death: 07/04/54; Not To Be Copied Without Permission"

DOCUMENTS REVIEWED

1. Xerographic Copy: Report of Autopsy Held on the Body of Marilyn Sheppard, Case No. 76629, Autopsy No. M-7280, Date: 7-4-54; S.R. Gerber, M.D., Coroner, Cuyahoga County, State of Ohio [Copy marked Cuyahoga County Coroner's Office March 1996 Case #76629 A-1]; Reviewed in Cleveland, Ohio, on 3-6 October 1999 and in Mililani, Hawai'i, on 28-30 November 1999.
2. Xerographic Copy: Vital Statistic Report; Coroner's Office, Cuyahoga County, Ohio Coroner's Office, Case No. 76629 [Copy marked Cuyahoga County Coroner's Office March 1996 Case #76629 A-12]; Reviewed in Cleveland, Ohio, on 3-6 October 1999 and in Mililani, Hawai'i, on 28-30 November 1999.
3. Xerographic Copy: Coroner's Verdict; Case No 76629 [Copy marked Cuyahoga County Coroner's Office March 1996 Case #76629 A-18]; Reviewed in Cleveland, Ohio, on 3-6 October 1999 and in Mililani, Hawai'i, on 28-30 November 1999.
4. Xerographic Copy: Affidavit of Paul Leland Kirk; State of Ohio vs Samuel H. Sheppard; Court of Common Pleas, Criminal Branch, No. 64571 [Marked Exhibit 44]; Reviewed in Cleveland, Ohio, on 3-6 October 1999 and in Mililani, Hawai'i, on 10, 28-30 November 1999.
5. Color Photographs; 5x7 inches; Labeled on Back: "Cuyahoga County Coroner's Office Photography Dept Cleveland Ohio 44106 Name: Marilyn Reese Sheppard Case: 76629 Autopsy: M-7280 Date Of Death: 07/04/54; Not To Be Copied Without Permission" Reviewed in Cleveland, Ohio, on 3-6 October 1999 and in Mililani, Hawai'i, on 1 December 1999.

CASE 76629

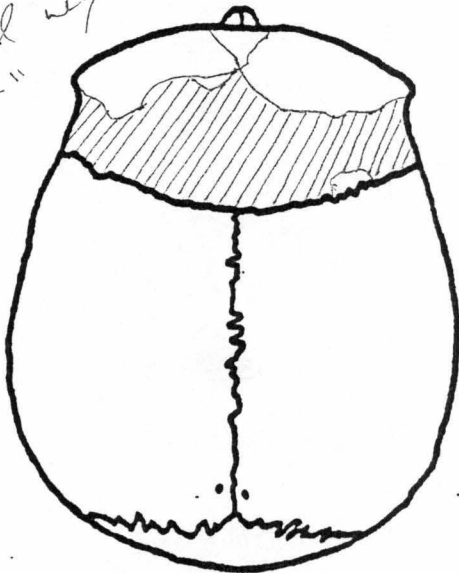
TD 4
5/OCT/9



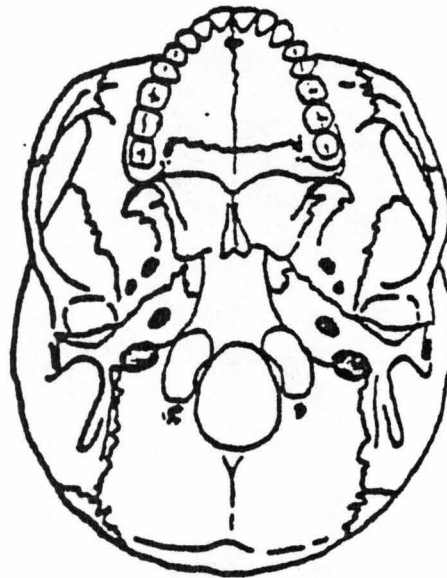
AUT
CUT



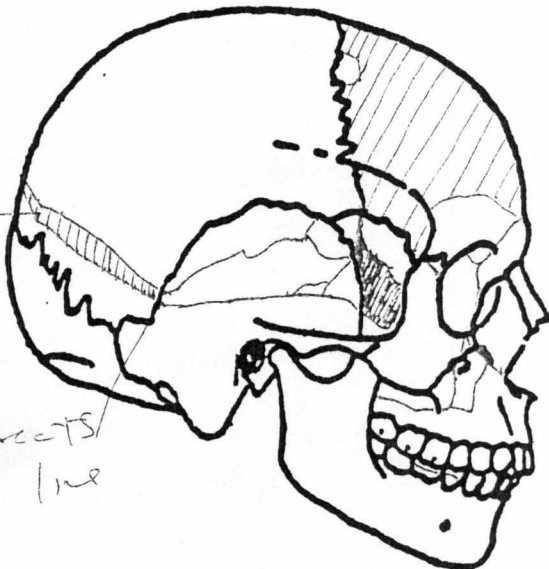
MISSING -
REPLACED
"PLASTER"



MISSING

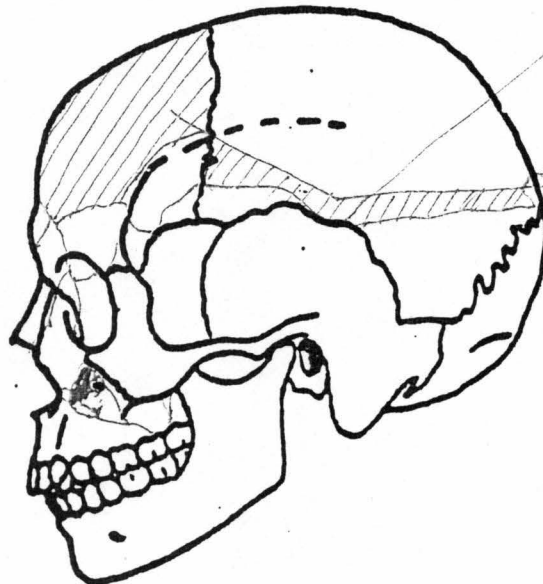


AUT
CUT



intersects
Fx line

intersects
Fx line



Antopsy
cut