

Cleveland State University
EngagedScholarship@CSU



Cleveland-Marshall
College of Law Library

Cleveland State Law Review

Law Journals

1958

Diagnosis and Treatment of the Modern Backache

A. W. Humphries

C. E. Wasmuth

Follow this and additional works at: <https://engagedscholarship.csuohio.edu/clevstlrev>

 Part of the [Health Law and Policy Commons](#), and the [Medical Jurisprudence Commons](#)

How does access to this work benefit you? Let us know!

Recommended Citation

A. W. Humphries & C. E. Wasmuth, Diagnosis and Treatment of the Modern Backache, 7 Clev.-Marshall L. Rev. 274 (1958)

This Article is brought to you for free and open access by the Law Journals at EngagedScholarship@CSU. It has been accepted for inclusion in Cleveland State Law Review by an authorized editor of EngagedScholarship@CSU. For more information, please contact library.es@csuohio.edu.

Diagnosis and Treatment of the "Modern" Backache

A. W. Humphries, M.D. and C. E. Wasmuth, M.D.***

THE PATIENT WITH THE INJURED BACK usually is seen by the general practitioner, by the specialist (usually an orthopedist and/or a neurosurgeon) and, in this day and age, also by the lawyer. It is entirely possible that more injured backs are seen by the actively practicing lawyer than by the actively practicing orthopedist or the neurosurgeon. Moreover, the lawyer may be as perplexed by a high percentage of these injured backs as is the orthopedist or the neurosurgeon, for the clinical features may be complex and the history of the origin of the back injury may be obscure, making difficult an accurate diagnosis and selection of the most logical and intelligent form of treatment. In addition, the frequency with which backs are injured in our present industrial world may result in a particular patient's history being somewhat confused by the similarity of the histories of many of his friends who have had back injuries of equal or of greater degree.

To complicate the situation, a person with a bona fide back injury accompanied by a developed muscle strain, an intermittently protruding intervertebral disc or a degenerated intervertebral disc, may, at the time of any particular medical examination, have no positive findings whatsoever if he happens to be "between attacks." Similarly, the patient who has little organic disability may have, at least on superficial physical examination, a large number of positive findings that are the result either of voluntary or of exaggerated response to medical examination in an effort to build a case. Although we have seen only a small number of people whom we have believed to be true malingerers, we have seen a fair number who either deliberately, or because they have little insight, seem to be excessively disabled by what appears on medical examination to be a relatively minor defect.

* Head of the Department of Vascular Surgery of the Cleveland Clinic Foundation; A.B., Dartmouth College; M.D., New York University; Diplomate of the American Board of Orthopedic Surgery; Fellow of the American College of Surgeons.

** Member of the Staff in the Department of Anesthesiology of the Cleveland Clinic Foundation; B.S. and M.D. from the University of Pittsburgh; Fellow of the American College of Anesthesiology; Diplomate of the American Board of Anesthesiology; and a third year student at Cleveland-Marshall Law School.

This is perhaps a not too surprising finding in these days of the labor unions and State Workman's Compensation Commission. Finally, in evaluating a patient's problem, many times we are forced to rely upon his description of pain—a purely subjective symptom that we cannot analyze quantitatively.

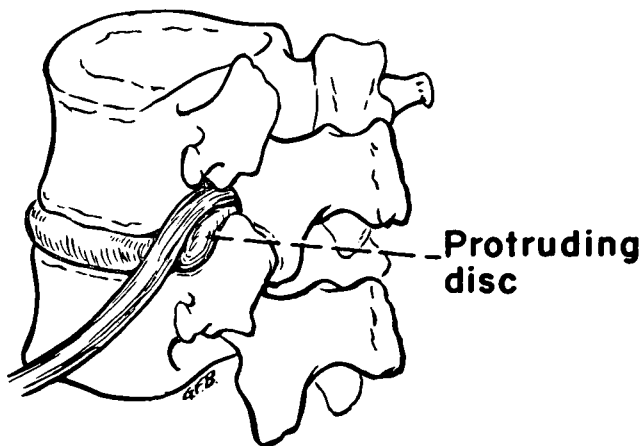


Fig. 1

From a mass of people with confusing backaches, two reasonably distinct clinical entities frequently stand out. The first is the ruptured or protruding lumbar intervertebral disc (Fig. 1). In its most typical form this appears initially as a sudden backache, which may or may not be associated with radiation of pain down the posterior aspect of the leg in the sciatic distribution. This usually occurs after some unusual motion or stress in a person who either has been entirely well prior to this incident, or who has had similar episodes of greater or lesser degree. If an episode begins initially with back pain, posterior radiation of pain down the leg becomes apparent within a short period of time and rapidly assumes predominance over the backache. The pain down the leg is aggravated by those actions that cause further protrusion of the intervertebral disc and greater pressure upon the nerves that are being compressed in the back. Such aggravating factors are apt to be bending over and lifting, straight leg raising, coughing, sneezing, or other less common motions which vary according to the individual. If pressure on the nerve root is present for a sufficient length of time, characteristic and obvious physical findings become apparent which establish the diagnosis.

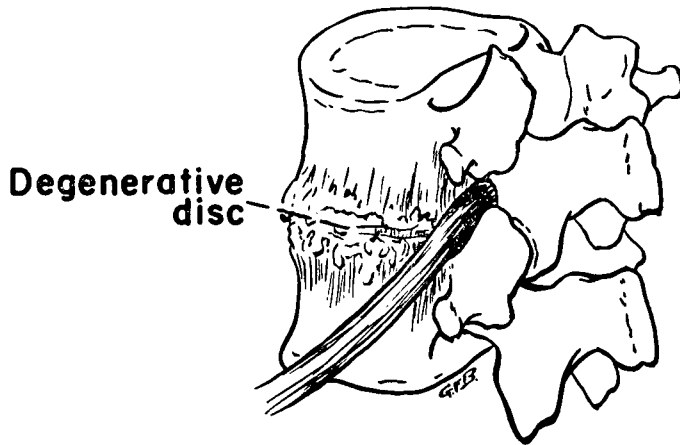


Fig. 2

The second clinical picture frequently seen is that of the degenerated intervertebral disc (Fig. 2). This occurs in a patient who has recurrent episodes of what primarily is back pain, although some radiation of pain along the sciatic distribution of the leg may be present. Characteristically, in this condition the patient states that the pain is primarily in the back and minimally in the leg; whereas, in the ruptured intervertebral disc the leg pain is predominant and the back pain is secondary. These patients rarely show positive neurologic signs even after the condition has persisted for a long period of time. They do, however, tend to have stiff backs with decreased amounts of motion, and they characteristically become "afraid of their backs" to such a degree that frequently they will refuse to work. On roentgenograms (in contrast to the patient with the acute ruptured intervertebral disc wherein the intervertebral spaces either are normal or slightly diminished), backs in this group of patients frequently show a markedly narrowed intervertebral space. Whereas in the ruptured intervertebral disc, the disc has burst out of its containing ligaments, and in the degenerated disc there is some metabolic change that occurs, resulting in a loss of the semigelatinous contents of the disc and the development of fibrosis. In fibrosis the disc has lost its dynamic elastic function and remains little more than a scar between two adjacent intervertebral bodies. This type of hypodynamic joint has been compared to a rusty hinge on a door. Whenever the door is moved the hinge may squeak. If the door is nailed shut so that it cannot

be opened, the hinge cannot squeak. As time goes on, motion in such a degenerated joint may result in secondary osteoarthritic changes and the development of a true "wear-and-tear" arthritis in this area.

In the treatment of these conditions one must bear in mind that there is, as in all diseases, a distinct tendency and effort on the part of the body to repair the damage spontaneously. Conservative care in the case of a ruptured intervertebral disc, consisting of rest, traction, local injections of procaine hydrochloride and hydrocortisone, epidural injections of saline solution, the use of a supportive device such as a corset or a brace, and graded exercises with slowly increasing activity, may well result in amelioration of symptoms in a fair percentage of patients. However, in a certain proportion of those whose symptoms are relieved, the resultant healing is insecure, and disc protrusion may recur after physical exertion at some time in the future. If relief of pain is not obtainable through conservative measures, or if there are multiple recurrences of the disability, and if the clinical picture is clear-cut enough to make the diagnosis unquestioned, surgical excision of the protruded intervertebral disc at the offending interspace may well be considered the treatment of choice (Fig. 3).

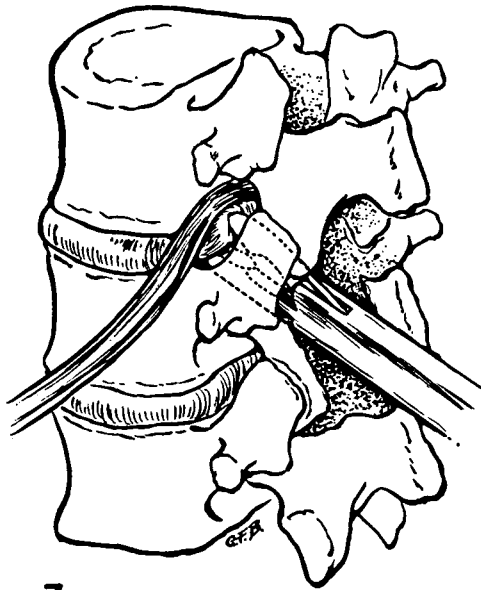
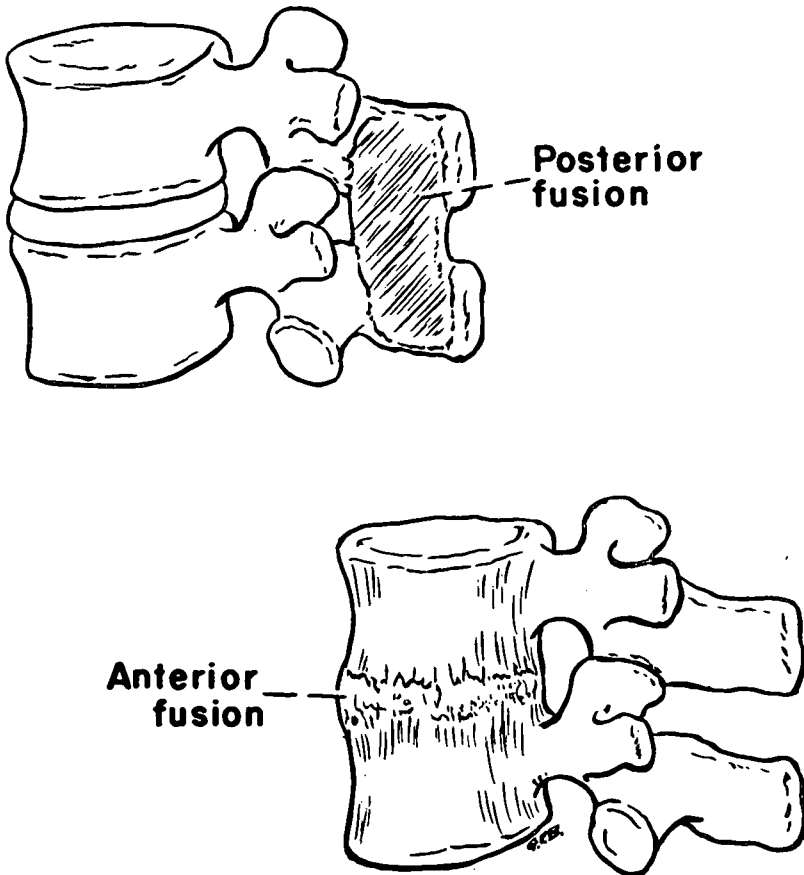


Fig. 3

In the case of the degenerated intervertebral disc, initially conservative therapy again is indicated. Since the single most aggravating factor is motion of the joint, immobilization of the lower portion of the back is indicated. This may be accomplished by a corset for a woman or a brace for a man. These devices may be supplemented by the use of physical modalities such as heat and massage to release muscle spasm, and the use of exercises to strengthen the back muscles so that they too may aid in support and immobilization of the low part of the back. This conservative treatment proves to be satisfactory in a large number of these people. A certain proportion, however, find that the supportive device must be worn constantly, or their symptoms recur. In others the relief obtainable by such devices is only partial, since an external device which takes its "grip" through intervening fat, muscle and soft tissue cannot firmly fix and prevent motion between the deeply buried involved vertebral bodies.

Finally, in some patients conservative care affords no relief of symptoms. In such patients the surgical formation of an internal supportive device, namely the fusion of one vertebra to the next, provides absolute immobilization and thereby relief of symptoms. The attainment of a solidly fused spinal segment is at best a difficult proposition. This involves the healing of bone to bone and, as is well known, bone healing is slow. To make two vertebrae fuse, one to the other, it is first required that the conditions for a fusion be set up. This is done at the time of operation when adjacent bone surfaces are roughened to provide a raw surface against which new bone can form and the insertion of new bone in the form of a graft to bridge the space between one vertebra and the other. Following the operation itself, this portion of the spine must be kept immobilized for a long enough time for bone to heal. This can be seen in Figure 4. A fusion may be done either from a posterior direction in which case the bone bridge is created between the two "handles" of the vertebrae or the operation may be done from the front through the abdominal cavity in which case the two vertebral bodies are made to grow together. It makes more sense to obtain an interbody fusion than an "inter-handle" fusion since it is mechanically more stable. Both involve technical difficulties stemming from the problem of postoperative immobilization, but either results in the satisfactory solution to the problem if a solid fusion is finally obtained.

**Fig. 4**

In summary, there are two reasonably clear-cut forms of backache that lend themselves to a reasonably straight-forward form of treatment. These are (1) the ruptured intervertebral disc and (2) the degenerated intervertebral disc. In both instances, once a diagnosis can be reasonably made, treatment is at first conservative, and this form of treatment frequently is successful. In the absence of success, an operative procedure is available which offers reasonable hope of correction of the difficulty.