

Cleveland State University
EngagedScholarship@CSU



Cleveland-Marshall
College of Law Library

Cleveland State Law Review

Law Journals

1964

Outpatient Injuries of the Hand

Frank W. Masters

David W. Robinson

Follow this and additional works at: <https://engagedscholarship.csuohio.edu/clevstrev>

 Part of the [Medical Jurisprudence Commons](#)

How does access to this work benefit you? Let us know!

Recommended Citation

Frank W. Masters & David W. Robinson, Outpatient Injuries of the Hand, 13 Clev.-Marshall L. Rev. 473 (1964)

This Article is brought to you for free and open access by the Law Journals at EngagedScholarship@CSU. It has been accepted for inclusion in Cleveland State Law Review by an authorized editor of EngagedScholarship@CSU. For more information, please contact library.es@csuohio.edu.

Outpatient Injuries of the Hand

Frank W. Masters and David W. Robinson**

INJURY OF THE HAND is the most frequent of all compensable accidents. Varying from simple abrasion to extensive avulsion, and combined with loss of function and earning power, the specialized problems of hand injury have created an entirely new field of surgical reconstruction and rehabilitation.

For every major injury that requires extensive and often staged reconstruction, there are multiple lesser accidents which are suitable for outpatient management. Such trauma does not require elaborate surgical facilities for definitive care, and a maximum of function can be obtained with a minimum of complication and loss of time. These "minor" injuries include various soft tissue defects which are primarily limited to the digits. When structural elements such as tendon or bone are involved, the injury cannot be considered as minor or as an outpatient type of trauma, since permanent loss of function may follow ideal therapy.

Here the term "minor" injury is a misnomer. All hand injuries, regardless of superficiality, may result in crippling loss of function if treatment is inadequate or mishandled. The essential elements of diagnosis, examination, approach to therapy and after-care are constant. The major difference between an injury requiring hospitalization and one amenable to outpatient management is the extent of the trauma. This article reviews the major outpatient injuries with respect to method of management, choice of definitive procedure, and preservation of function.

Injury to the Fingernail and Matrix

Subungual hematoma¹ is an extremely common injury usually resulting from a "pinch" or "smash." The distal phalanx² is swollen and tender, with discoloration beneath the nail. This

* M.D.; of the Department of Surgery, Section of Plastic Surgery, University of Kansas Medical Center, Kansas City, Kansas.

[Note: This is a digest by the Editors of this Law Review, of a medical article by the authors, in the July 1962 issue of *G.P.*, as approved by the authors and the latter, and with permission. It has been simplified, for use by attorneys.]

¹ A collection of blood under the nail.

² Last joint of finger.

is accompanied by a deep, throbbing pain, made worse by dependency. Therapy consists of evacuation of the hematoma and provision of a pathway for drainage to prevent re-formation of the clot.

Various methods of management have been described. A small hole can be drilled through the nail with a scalpel blade or with a small dental drill, but the simplest procedure is to use the heated point of a paper clip. This method is quick, virtually painless, and requires no pressure to penetrate the thickness of the nail.

The major complication of this therapy is infection. This can be prevented by careful pre-operative cleansing and simple coverage of the drainage site after evacuation.

Partial avulsions of the nail are easily treated as outpatient injuries. Therapy depends upon the direction of the avulsion. If the distal part of the nail is torn free, it should be replaced in its bed and splinted in place with a simple adhesive dressing. If, however, the partial avulsion occurs at the base of the nail and does not involve the nail matrix,³ the loose segment should be trimmed away to the adherent area, under local anesthesia, and the nail base dressed with a non-adherent dressing to promote epithelization.⁴ If the detached nail is replaced without debridement,⁵ the devitalized fragment acts as a foreign body and

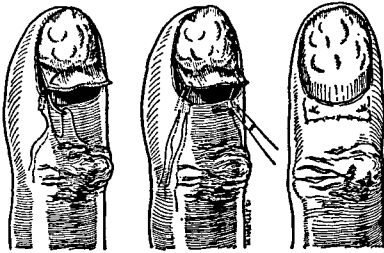


Figure 1. Injury to nail matrix—The repair of the avulsed nail matrix is facilitated by mattress sutures at the base. The matrix must be replaced to prevent osteomyelitis of the underlying distal phalanx.

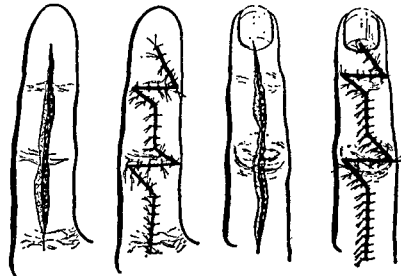


Figure 2. Laceration without deep damage—Z-plasty at the flexion creases will prevent future contraction of a linear laceration across the creases.

³ Nail bed.

⁴ Healing with skin.

⁵ The surgical removal of lacerated, devitalized, or contaminated tissue.

the subsequent tissue reaction may produce a paronychia-type infection.⁶

When the nail matrix is avulsed, it should be replaced and sutured beneath the eponychial⁷ covering (Figure 1). Since the matrix is fused with the dorsal periosteum⁸ of the distal phalanx, its avulsion is a possible source of osteomyelitis⁹ and destruction of the bone. The avulsed matrix can be easily restored to its anatomic location by using two mattress sutures of fine silk or nylon and a non-adherent pressure dressing applied to aid in immobilization.

Lacerations

The repair of simple lacerations presents no difficulty unless the flexion creases are crossed. Even extensive lacerations that do not involve tendons still fall into the category of "outpatient" injury. The immediate repair should consist first of a thorough cleansing with bland soap and water. No chemical antiseptic should be used. This is followed by a careful debridement, particularly of nonviable muscles. A meticulous repair is then done, designed to eliminate dead space. Immobilization to put the hand at rest is essential to promote rapid healing and facilitate return to active function. If there is any concern about identification of deeper structures, a bloodless field is necessary and a pneumatic tourniquet is mandatory.

When the dorsal or volar¹⁰ flexion creases are crossed by a wound and the laceration is repaired by side-to-side approximation at the flexion crease, contracture and loss of function are inevitable unless the direction of the laceration is altered at the level of the flexion crease. The most satisfactory method of altering the line of contracture is by simple Z-plasty wherever the line of laceration crosses the flexion crease (Figure 2). This maneuver breaks up the line of contracture by staggering the line of closure. However, if the contracture has not had enough

⁶ Inflammation of the tissues adjacent to the nail of a finger, usually accompanied by infection and pus formation.

⁷ The thin skin adherent to the nail at its proximal portion.

⁸ Membrane of connective tissue that closely invests all bones except at the articular surfaces.

⁹ An infectious, inflammatory disease of bone marked by local death and separation of tissue.

¹⁰ Relating to the palm of the hand.

time to produce fibrotic¹¹ joint changes, it, too, can be corrected by Z-plasty as shown in Figures 3A and 3B. The majority of such reconstructive procedures can be prevented by careful repair of the original wound including preservation of the integrity of the flexion crease.

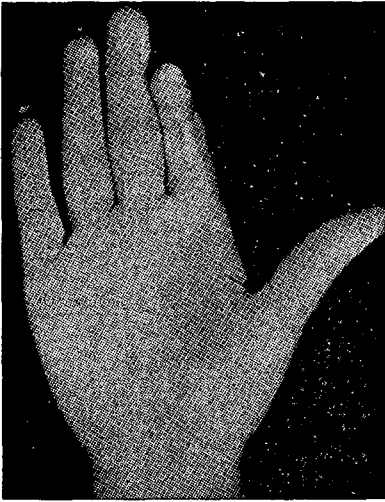


Figure 3A. A linear laceration of the index finger of an 18-year-old girl resulted in contracture when repaired in a straight line.

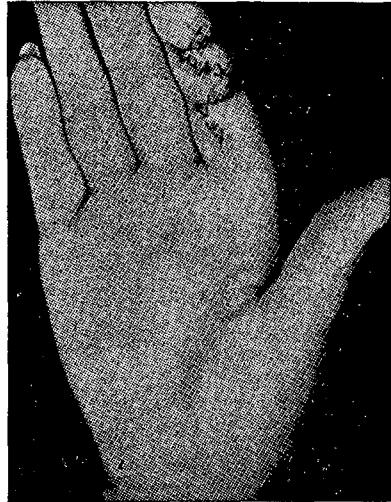

Figure 3B. The flexion contracture can be released by Z-plasty but could have been prevented.

Digital Nerve Repair

Digital nerve injury frequently complicates simple lacerations of the fingers. This diagnosis may be missed unless a careful sensory examination is an integral part of the evaluation of any wound. The resulting loss of function can be disabling if a painful neuroma¹² develops at the site of nerve injury.

Digital nerve repair as a primary procedure does not require elaborate surgical facilities. A 6-0 eye silk is the only specialized equipment needed. Under local anesthesia, with hemostasis¹³ secured by a rubber band tourniquet at the base of the finger, end-to-end repair of the digital nerve can be readily performed to the level of the distal flexion crease. The nerve ends must not be grasped with instruments but handled very

¹¹ Formation of fibrous tissue.

¹² A tumor or mass growing from a nerve and usually consisting of nerve fibers.

¹³ Arrest of bleeding.

gently, using only fingers and the suture needle. The ends should be brought accurately together without torsion or tension and, if length permits, trimmed with a sharp blade. Perineural¹⁴ sutures holding the two ends of the nerve in accurate approximation will produce uniformly good results. The return of sensation may be prolonged, since the process of nerve regeneration may take several weeks or months depending upon the location of the injury. When the nerve is divided proximal to the digit, outpatient management should not be considered.

Amputation

Partial or complete amputations of the digits may lend themselves well to outpatient management, particularly when soft tissue alone is involved. The partial amputation produces the more complex problem of definitive management because the vascular supply of the flap is the sine qua non of survival.

Because the normal hand has an abundant supply of blood, arterial insufficiency is unusual and loss of arterial function is well tolerated. Venous congestion, however, almost always produces necrosis¹⁵ in varying amounts. The common situations which predispose to venous congestion are crush injuries and retrograde flaps¹⁶ when the pedicle¹⁷ is situated distal to the normal pathways of venous return.

When cyanosis¹⁸ and delayed capillary return are apparent at the time of primary repair, the "take a chance" attitude of "sew it back and hope it survives" usually ends in disaster. These congested flaps should be totally removed. If they are not crushed, they can be defatted¹⁹ and the skin can be replaced as a primary full-thickness skin graft. If congestion is evident after a crush injury, the flap should be discarded and the defect either closed primarily or resurfaced with a split-thickness skin graft. Such injuries, when limited to a single digit, do not require elaborate surgical facilities. In such cases, outpatient management is the rule rather than the exception.

The management of a complete amputation varies with the

¹⁴ The connective-tissue sheath that surrounds a bundle of nerve fibers.

¹⁵ Localized death of living tissue.

¹⁶ Mass of soft tissue having a single attachment to the body.

¹⁷ The point of attachment of flap to body.

¹⁸ Bluish or purplish discoloration due to deficient oxygenation of the blood.

¹⁹ Removal of subcutaneous fat.

level of injury and the structures involved. Length should be preserved where possible, particularly if the thumb is injured. The very young person has an amazing tolerance for this kind of trauma and adapts readily to a defect which would produce a functional deficit in the adult.

When digital amputation involves the distal phalanx, the level of injury determines the management. If the tendon insertions are not involved, length should be preserved. Even though resection of bone will facilitate closure, it is preferable to preserve the functional length of the distal phalanx by saving the bone for length and applying a skin graft to the avulsed area. This technique is shown in Figures 4A-4D.




Figure 4A. A fingertip amputation following a crushing injury in an automobile door.

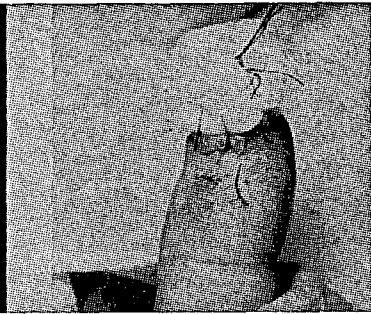


Figure 4C. A tie-over bolus dressing is applied to maintain pressure on the graft.

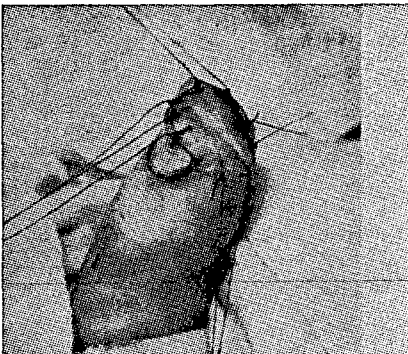


Figure 4B. After careful cleansing and debridement, the amputation site is resurfaced with a split-thickness skin graft to preserve length of the digit.

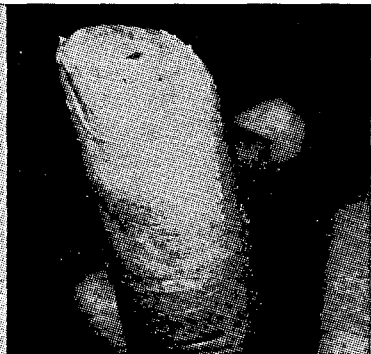

Figure 4D. Postoperative appearance 10 days after repair.

If a small amount of bone is exposed, but the insertions of the flexor²⁰ and extensor²¹ tendons are still intact, the bone should be rongeuired²² to smooth the bony phalanx. Here, again, length is maintained by using a split-thickness skin graft for immediate closure of the wound (Figure 5).

If amputation involves the extensor tendon insertion, the remainder of the distal phalanx should be sacrificed because a mallet finger is inevitable if the unopposed flexor profundus²³ is allowed to act. When the entire distal phalanx requires resection, the cartilage and condyles²⁴ should be removed and the distal end shaped in a tapering fashion to allow for greatest function. Under no circumstances, however, should the closure be reinforced by suture of the two tendon ends across the resected end of the bone. Such a technique will produce an extremely painful stump and markedly limit the function of the finger.

The soft tissue closure of an amputation stump should be tailored to give adequate coverage over the end of the bone for a good pad without "dog ears" or tightness. This technique is shown in Figure 6.

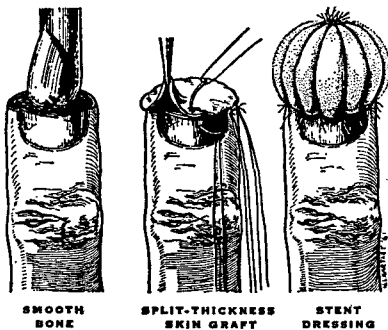


Figure 5. Fingertip amputation—The split-thickness skin graft technique is the best method of maintaining the length of an amputated fingertip even though bone is exposed. If the bone is rongeuired smooth, the graft will "take" directly over the bone narrow cavity.

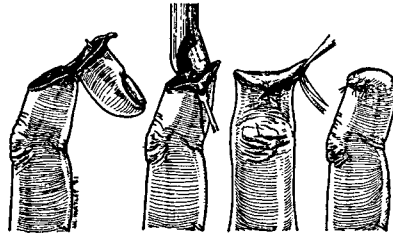


Figure 6. Closure of amputation—When the level of amputation involves the extensor tendon insertion, the soft tissue closure of the amputation stump should be tailored to give adequate coverage without "dog ears."

²⁰ A muscle that serves to bend a limb.

²¹ A muscle serving to extend a limb.

²² An instrument for removing small pieces of bone.

²³ The deep tendon to a finger.

²⁴ An articular prominence of a bone; especially one of a pair like knuckles.

Burns

Among the most frequently burned areas of the body are the hands. Children frequently grasp hot objects. Small, deep burns of the hand are more serious than similar injuries of other parts of the body. Careful diagnosis of the burned hand is most important. The differentiation between partial²⁵ and full-thickness²⁶ skin loss is essential for proper therapy, early healing, and ultimate function.

Partial thickness burns will heal spontaneously if the physician will protect the remaining viable skin. Many methods of management and a great variety of materials have been advocated. Under controlled conditions, considerable latitude is allowed. Partial thickness burns of the hand should be managed by the closed technique. This includes immobilization in an occlusive dressing with the individual fingers separated and the hand in the position of function. Loose epithelium and the tops of vesicles should be debrided and the hand cleansed with dilute bland soap and water followed with saline. A dressing should be applied carefully, utilizing fine mesh, nearly dry, grease gauze to prevent adherence and destruction of young epithelium. This is followed by a bulky pressure dressing separating the fingers.

Barring complications, second-degree burns of the hand will heal spontaneously in 10 to 14 days. A carefully applied initial dressing need not be changed for five to seven days after injury. At the time of the first dressing change, extreme care should be taken not to injure the newly formed epithelial covering. When epithelization is complete, mobilization is begun to prevent fibrosis²⁷ and contracture.²⁸ However, the epithelial surface must be protected from excessive wear and tear until the covering is mature; this may require two to three weeks.

When *full-thickness burn* occurs, the area involved must be small if the injury is to be treated on an outpatient basis. Small, deep burns of the hand are managed conservatively until the area of loss is sharply demarcated and necrotic skin has

²⁵ Second degree burn.

²⁶ Third degree burn.

²⁷ A condition marked by increase of interstitial fibrous tissue.

²⁸ A permanent shortening (as of muscle, tendon, or scar tissue) producing deformity or distortion.

sloughed (Figure 7A). When granulation²⁹ has occurred, the area must be resurfaced with split-thickness skin grafts as soon as possible, not only to restore skin coverage, but also to prevent fibrosis and loss of function (Figure 7B).

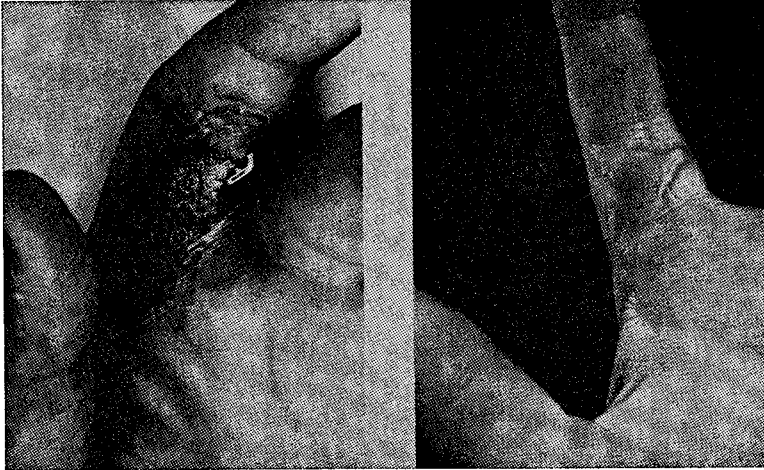


Figure 7A. A third-degree burn of the index finger in a 30-year-old worker.

Figure 7B. Eight weeks after early split-thickness skin grafting to resurface the granulating wound and prevent fibrosis.

²⁹ One of the minute red granules of new capillaries formed on the surface of a wound in healing.