

Journal of Mind and Medical Sciences

Volume 5 | Issue 2

Article 20

2018

Functional radical cervical dissection for differentiated thyroid cancer: the experience of a single center

Tulin Adrian

Prof. Dr. Agrippa Ionescu Emergency Hospital, Department of General Surgery, Bucharest, Romania

Lucian Alecu

Prof. Dr. Agrippa Ionescu Emergency Hospital, Department of General Surgery, Bucharest, Romania, alecu.l@yahoo.com

Catalina Poiana

Carol Davila University of Medicine and Pharmacy, C.I. Parhon Institute of Endocrinology, Bucharest, Romania

Luminita Tomescu

Professor Dr. Agrippa Ionescu Emergency Hospital, Department of Radiology and Imaging, Bucharest, Romania

Iulian Slavu

Prof. Dr. Agrippa Ionescu Emergency Hospital, Department of General Surgery, Bucharest, Romania, iulian.slavu@yahoo.com

See next page for additional authors

Follow this and additional works at: <https://scholar.valpo.edu/jmms>

 Part of the [Endocrinology, Diabetes, and Metabolism Commons](#), [Oncology Commons](#), and the [Surgery Commons](#)

Recommended Citation

Adrian, Tulin; Alecu, Lucian; Poiana, Catalina; Tomescu, Luminita; Slavu, Iulian; Tulin, Raluca; Pituru, Silviu; Orlov, Cristina; Jecan, Radu; Cristian, Balalau; Pantea Stoian, Anca; Hainarosie, Razvan; and Nitipir, Cornelia (2018) "Functional radical cervical dissection for differentiated thyroid cancer: the experience of a single center," *Journal of Mind and Medical Sciences*: Vol. 5 : Iss. 2 , Article 20.

DOI: 10.22543/7674.52.P278283

Available at: <https://scholar.valpo.edu/jmms/vol5/iss2/20>

This Research Article is brought to you for free and open access by ValpoScholar. It has been accepted for inclusion in Journal of Mind and Medical Sciences by an authorized administrator of ValpoScholar. For more information, please contact a ValpoScholar staff member at scholar@valpo.edu.

Functional radical cervical dissection for differentiated thyroid cancer: the experience of a single center

Authors

Tulin Adrian, Lucian Alecu, Catalina Poiana, Luminita Tomescu, Iulian Slavu, Raluca Tulin, Silviu Pituru, Cristina Orlov, Radu Jecan, Balalau Cristian, Anca Pantea Stoian, Razvan Hainarosie, and Cornelia Nitipir



Research article

Functional radical cervical dissection for differentiated thyroid cancer: the experience of a single center

Adrian Tulin¹, Lucian Alecu¹, Catalina Poiana², Luminita Tomescu³, Iulian Slavu¹, Raluca Tulin⁴, Silviu Pituru², Cristina Orlov⁵, Radu Jecan⁶, Cristian Balalau⁷, Anca Pantea Stoian⁸, Razvan Hainarosie², Cornelia Nitipir^{2,5}

¹Prof. Dr. Agrippa Ionescu Emergency Hospital, Department of General Surgery, Bucharest, Romania

²Carol Davila University of Medicine and Pharmacy, Bucharest, Romania

³Professor Dr. Agrippa Ionescu Emergency Hospital, Department of Radiology and Imaging, Bucharest

⁴Professor Dr. Agrippa Ionescu Emergency Hospital, Department of Endocrinology, Bucharest

⁵Elias University Emergency Hospital, Department of Medical Oncology, Bucharest, Romania

⁶Professor Dr. Agrippa Ionescu Emergency Hospital, Department of Plastic Surgery, Bucharest

⁷St. Pantelimon Emergency Hospital, Department of General Surgery, Bucharest, Romania

⁸Carol Davila University of Medicine and Pharmacy, Department of Diabetes, Nutrition and Metabolic Diseases, Bucharest, Romania

Abstract

There is ongoing debate regarding the role of neck dissection in differentiated thyroid cancer, about its usefulness in elective settings, and the increased costs regarding morbidity and operative time. This retrospective study aimed to determine the rate of metastases in cervical lymph nodes, to examine the morbidity of this surgery, and to assess whether a pattern of distribution of tumor cells concerning neck lymphatic compartments exists. The most frequent type of cancer to metastasize was papillary cancer, the majority of patients were young with a median of 30 years, predominantly females. Differentiated thyroid cancer frequently metastasizes to the central and lateral compartments of the neck. The morbidity is minimal in a high-volume center. Radical neck dissection is safe and feasible in selected patients with confirmed invaded or enlarged lymph nodes due to differentiated thyroid cancer, and postoperative complications are minimal if the anatomy is correctly identified and the cases strictly selected.

Keywords

: thyroid, differentiated cancer, surgery, cervical dissection

Highlights

- ✓ Central and lateral neck dissections/ CLND is a feasible option for differentiated thyroid cancers, with a low complication rate.
- ✓ Berry picking of the enlarged lymph nodes should be avoided, due to the fact that the complication rate is similar to CLND and the recurrence rate of malignancy is higher.

To cite this article: Tulin A, Alecu L, Poiana C, Tomescu L, Slavu I, Tulin R, Pituru S, Orlov C, Jecan R, Balalau C, Stoian AP, Hainarosie R, Nitipir C. Functional radical cervical dissection for differentiated thyroid cancer: the experience of a single center. *J Mind Med Sci.* 2018; 5(2): 278-283. DOI: 10.22543/7674.52.P278283

Introduction

Thyroid cancer has seen a constant increase in incidence over the years. It is distributed according to cell differentiation into two distinct classes. The first is represented by well-differentiated cancers, the most frequently encountered being the papillary and follicular forms. The second class corresponds to poorly differentiated tumors, like medullary and anaplastic forms, the latter being associated with fast and aggressive evolution (1).

Differentiated thyroid cancers generally have a mild evolution and good prognosis, the survival of these patients 10 years after diagnosis reaching 90%. Papillary thyroid cancer, which is one of the most encountered types of thyroid cancer, has seen an increase in incidence (almost doubled over the last 30 years), largely due to an early diagnosis of subclinical cases (through the emergence of new techniques of diagnosis and early access to specialized medical care) (2, 3).

Lymphatic metastasizing is frequent and is diagnosed in up to 50% of the cases; there are controversies about the prognostic value of these metastases, which do not seem to influence survival. Subclinical metastases are encountered in a large number of patients, and do not affect postoperative survival. A frequent site of metastasis is the central compartment of the neck, which contains the VI-th and VII-th lymphatic stations of the neck (4-6).

The European Treatment Guidelines (ETA) recommend systematically performing dissection of the neck compartments which contain enlarged lymph nodes, identified either preoperatively (with the help of ultrasound) or intraoperatively (during extemporaneous examination). This recommendation rests on the fact that young patients who are often diagnosed with aggressive forms of thyroid cancer have a benefit regarding overall survival, while for the other patients recurrence seems to be reduced when lymphatic dissection is performed (7, 8).

According to the European Guidelines, such surgical options are recommended only when enlarged or invasive nodules are present. In the USA, this procedure (routine lymph dissection of the central neck compartment) is not yet included in treatment guidelines (being currently under discussion), due to the high rate of invasion at this level at the time of diagnosis (9, 10). There is legitimate hesitation to adopt this technique in elective conditions, due to the high postoperative morbidity. Possible complications include recurrent laryngeal nerve injury (which is constantly located in the tracheoesophageal groove, where the lymphatic tissue needs to be dissected and removed) and postoperative

hypoparathyroidism. Between 3% and 6% of patients undergoing central compartment lymph node dissection remain with postoperative hypoparathyroidism and/ or temporal dysphonia (11).

The scope of this study was to evaluate (based on our clinic database) the rate of postoperative complications (hypocalcemia, recurrent laryngeal nerve injury) resulting after central and lateral neck dissections (CLND), and the rate/ path of metastasis encountered in the case of local lymph nodes.

Materials and Methods

The study was designed as an observational and retrospective analysis, being performed on 88 patients with thyroid disease who were operated (irrespective of the operative indication) between January 2014 and July 2018 in the Clinic of General Surgery of Emergency Hospital `Prof. Dr. Agrippa Ionescu` Bucharest. We enrolled in this trial 44 patients who underwent total thyroidectomy and 44 who underwent total thyroidectomy with CNLD. All patients were referred to the surgical department after evaluation by a multidisciplinary team, coordinated by the endocrinologist. Informed consent was signed by patients so as to be able to collect and use the data. The hospital ethical committee approved the study, data included in analysis being related especially to the patients' age, gender, and histopathological report. Statistical analysis was done using SPSS V20. Patients were selected for CLND if enlarged lymph nodes were identified at clinical examination, through ultrasonography, or during extemporaneous examination. The lymph dissection was performed only on the side of the neck where the enlarged lymph nodes were identified (Picture 1).

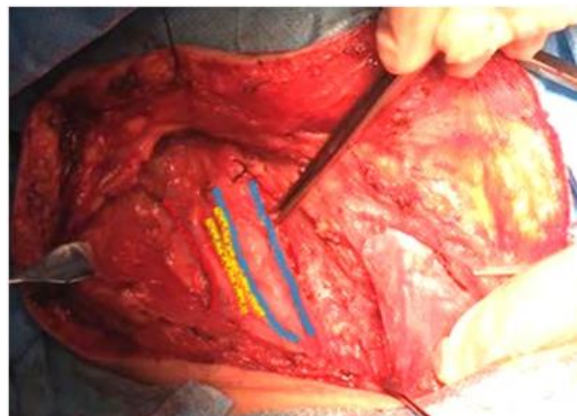


Figure 1. Shows the main vessels of the neck after lymphatic dissection, starting from the outside: the internal jugular vein, common carotid artery, and the vagus nerve between them. We did not use a neuro-locator device to identify the recurrent laryngeal nerves; rather they were identified by careful dissection in the esophagotracheal groove (Figure 2).

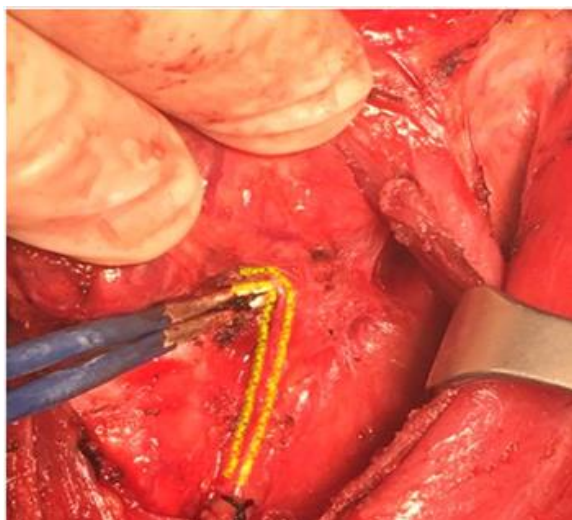


Figure 2. The recurrent laryngeal nerve identified and protected at the inferior pole of the left thyroid lobe.

Results

The majority of patients were females, with a 4:1 (female to male) gender ratio. Mean age of the study group was 50 years, ranging from 19 to 73, the standard deviation being 13,4. Mean age of the patients with CLND was 39 years.

The histopathological report showed that the median tumour size which was associated with lymphatic dissemination was 18,2 mm. Regarding cellular type, the majority of tumors were papillary (63.63%: n=56), followed by follicular (15.9%: n=14), medullary (9.9%: n=8), and anaplastic (11.36% n=10). Multifocality in the thyroid gland was identified in 35.22% (n=31) of the cases with invaded locoregional nodes. The average excision of each intervention was 15 lymph nodes, of which about 6 presented a tumoral infiltration. A local invasion through the thyroid capsule into adjacent structures (which corresponds to T4 tumours) was observed only in cases of anaplastic tumours.

10.22% (n=9) of the patients without CLND and 12.5% (n=11) of the patients who underwent CLND had postoperative complications. The Pearson chi-square for this association had a value of 0.20, p=0.61.

In the two groups (thyroidectomy alone vs. thyroidectomy plus CLND), transient hypocalcemia was present in 5.68% (n=5) vs. 7.95% (n=7), transient recurrent nerve paresis in 2.27% (n=2) vs. 2.27% (n=2), postoperative neck hematoma in 3.4% (n=3) vs. 1.13% (n=1). No correlation was found between any type of complication and the two types of surgical procedures. Pearson Chi-Square value was 0.681, p= 0.8.

Metastasis to the lymph nodes was identified more frequently in patients with extracapsular invasion than in patients without invasion. The central compartment with the levels VI (peri-thyroidal paralaryngeal, paratracheal, pretracheal and prelaryngeal nodes) and VII (upper anterior mediastinal lymph nodes) was noted as the most frequently involved in the lymphatic dissemination of the tumour cells (n=8), followed by the lateral neck compartment (n=4), and superior mediastinum (n=2). Levels I and V presented the lowest rate of metastasis. Contralateral lymph nodes could not be evaluated due to the fact that the authors generally did not undertake contralateral neck dissection in elective settings.

Table 1. Tumor spread

Location	Frequency	Percent
Lateral neck compartment	4	9,1
Central neck compartment	8	18,2
Superior mediastinum	2	4,5

Table 2. Complication rates

Complication	Frequency	Percent
No. complications	34	77,3
Transient hypocalcemia	7	15,9
Transient recurrent nerve paresis	2	4,5
Posoperative neck hematoma	1	2,3
Total	44	100,0

Discussions

Neck dissection plays an essential role in surgical management of head and neck cancer patients. In the studied sample, the CLND was performed as elective procedure, that is only in cases of clinically enlarged lymph nodes (that were identified preoperatively), or in cases of lymph nodes identified during the intraoperative extemporaneous evaluation (and confirmed as being invaded by tumoral cells). This decision was undertaken due to the risk of complications related to the recurrent laryngeal nerve or hypoparathyroidism. Such complications can occur in up to 6% of the patients, as demonstrated by multiple clinical trials, which recommend that radical dissection of the neck should be limited in thyroid cancer only to compartments that present enlarged lymph-nodes (12, 13). Diagnostic procedures used for detection of the lymph nodes were represented by clinical and ultrasound examinations, the latter playing a crucial but not definitive role, as they can give false negative results due to its sensitivity and specificity (14).

Other authors recommend prophylactic CLND in patients with cN0 not only for T3 or T4 tumours, but also for tumours larger than 1 cm. This tactical decision is argued regarding small tumors by the fact that the presence of lymph node metastases can change postoperative treatment regardless of the location of the primary tumor. As an example of tactical decision-making, small (pT1) tumours limited to the thyroid gland/capsule but with lymphatic metastasis receive radioiodine therapy, while larger (pT2) tumours without lymph node metastasis do not (15, 16). Due to the extensive dissection and anatomical implications of CLND, some surgeons in the past have advocated for “berry picking” resections aimed at removing only macroscopically enlarged nodes (17, 18). We do not fully agree with this technique, since these “berry picking” surgeries are associated with high recurrence rates (which in turn require reoperation that is in often associated with a higher complication rate due to local fibrosis). As noted by Munacchio *et al.*, the complication rate in functional neck dissections is no higher than those identified in berry picking surgeries (19).

CLND is associated with an increased rate of transient hypocalcemia when compared to simple total thyroidectomy; this view point is consistent with our data, where the incidence of transient hypocalcemia in thyroidectomy group was 8% while in the CLND group it approached 10%. This oscillation is probably due to thyroid gland anatomy, especially the inferior region that can easily be extracted with the lymph nodes from

the central compartment. Vascular compromise as a source of blood comes from the same inferior region/thyroid arteries, located in an extensive dissected area. When the parathyroid gland was recognized, after resection, it was transplanted by injection of a suspension solution of parathyroid in the sternocleidomastoid muscle. The utility of the procedure could not be evaluated, due to the fact that in no cases were all of the four glands were resected. This aspect is related to the observation that parathyroid function correlates with the number of parathyroid glands that remain.

Postoperative dosage of calcium and parathyroid hormone/ PTH levels should be done in elective settings when an extended lateral neck dissection is performed, to be able to rapidly initiate treatment for hypocalcemia and shield the patient from the associated morbidities. When available, intraoperative dosages of PTH levels offer the best image over the functionality of the parathyroid glands (20, 21).

Regarding the rate of the recurrent laryngeal nerve injury, we had an incidence of 6% in CLND, significantly higher than that related to total thyroidectomy, which was about 4%. As noted before, this rate increases due to the extensive dissection of the lymph nodes, especially those of the central compartment, which frequently wrap around the recurrent laryngeal nerve. In addition, some tumours increase the overall size of the thyroid gland and invade the surrounding structures with subsequent local retraction.

In such cases, familiarity of the local anatomy, with slow and careful dissection, should be the basic option, with the possibility of using the neurolocator when there are doubts, as the use of a neurolocator can reduce the incidence of nerve damage when tissue deformity is present (22). All of our procedures involved central and lateral neck dissection, including the posterior triangle which can be associated with spinal accessory nerve damage. Therefore, great care must be taken to avoid nerve damage. A helpful tip is to set the markers along the nerve course (which projects superficially by connecting the mandible angle and the mastoid process), addressing this line in middle. The lower course of this line should be avoided, as it generally represents the assumed path of the spinal accessory nerve (23).

Patients with large tumours and extracapsular invasion are often associated with lymph node metastasis, this observation being also confirmed by Ortiz S *et al.* (24). The histopathology reports revealed, especially for papillary cancer type, that dissemination

of the tumoral cells to the lymph nodes from the central and lateral compartments was frequently found. Non-invaded nodes or those with limited invasion to only one lymph node was rarely observed, similar to literature data (25). Elective dissection of the contralateral lymph nodes was avoided, because it is rarely involved in metastasis of differentiated thyroid cancer (26).

Study limits. The study has the limits of a retrospective investigation: the researchers could not control the exposure or outcome assessment or the accuracy of recordkeeping, thus making it subject to biases. Also, the temporal relationship regarding the evolution of the subjects was difficult to evaluate. Even if the question of making a radical neck dissection in thyroid cancer is still under debate/ development, the utility of this procedure has been demonstrated for some patients. In contrast, postoperative complication rates, such as hypocalcemia and intermittent/ permanent recurrent laryngeal nerve paralysis, are more often encountered in thyroidectomy with CLND dissection that occurs only in thyroidectomy. For these reasons, the authors recommend special attention to the dissection procedure and a thorough knowledge of the local anatomy. Large prospective randomized trials are needed to demonstrate the utility of elective neck dissection of the central compartments (taking into account the risk-benefit ratio), due to the significant morbidity associated with this procedure (27, 28).

Conclusions

CLND is a feasible option with a low complication rate for differentiated thyroid cancers when the local anatomy is clearly understood. Still debatable is whether to use it in elective settings, such that large prospective randomised trials are required in the future to demonstrate its benefits. Compared to thyroidectomy alone, there is an increased rate of hypoparathyroidism and recurrent laryngeal nerve damage in thyroidectomy associating central and lateral neck dissections. Berry picking of the enlarged lymph nodes should be avoided, due to the fact that the complication rate is similar to CLND and the recurrence rate of malignancy is higher.

Conflict of interest disclosure

The authors declare that there are no conflicts of interest to be disclosed.

Acknowledgments

All authors have equal contribution to this article.

References

1. Kumar V, Abbas AK, Astar JC. Robbins and Cotran Pathologic Basis of Disease. 9th ed. Philadelphia: Elsevier Saunders; 2014.
2. Hundahl SA, Fleming ID, Fremgen AM, et al. A national cancer data base report on 53,856 cases of thyroid carcinoma treated in the US, 1985-1995. *Cancer*. 1998; 83(12): 2638-48. PMID: 9874472
3. Chen AY, Jemal A, Ward EM. Increasing incidence of differentiated thyroid cancer in the United States, 1988–2005. *Cancer*. 2009; 115(16): 3801–7. DOI: 10.1002/cncr.24416
4. Mirallie E, Visset J, Sagan C, Hamy A, Le Bodic MF, Paineau J. Localization of cervical node metastasis of papillary thyroid carcinoma. *World J Surg*. 1999; 23(9): 970–973. PMID: 10449830
5. McConahey WM, Hay ID, Woolner LB, et al. Papillary thyroid cancer treated at the Mayo Clinic, 1946 through 1970: initial manifestations, pathologic findings, therapy, and outcome. *Mayo Clin Proc*. 1986; 61(12): 978–96.
6. Qubain SW, Nakano S, Baba M, Takao S, Aikou T. Distribution of lymph node micrometastasis in pN0 well-differentiated thyroid carcinoma. *Surgery*. 2002; 131(3): 249-56. PMID: 11894028
7. Ito Y, Tomoda C, Uruno T, et al. Preoperative ultrasonographic examination for lymph node metastases: usefulness when designing lymph node dissection for papillary micro carcinoma of the thyroid. *World J Surg*. 2004; 28(5): 498-501. DOI: 10.1007/s00268-004-7192-z
8. Tisell LE, Nilsson B, Molne J, et al. Improved survival of patients with papillary thyroid cancer after surgical microdissection. *World J Surg*. 1996; 20(7): 854-9.
9. Cooper DS, Doherty GM, Haugen BR, Kloos RT, Lee SL, Mandel SJ, Mazzaferri EL, McIver B, Sherman SI, Tuttle RM; American Thyroid Association Guidelines Taskforce. American Thyroid Association Guidelines Taskforce. Management guidelines for patients with thyroid nodules and differentiated thyroid cancer. *Thyroid*. 2006; 16(2): 109-42. PMID: 16420177, DOI: 10.1089/thy.2006.16.109
10. Carty SE, Cooper DS, Doherty GM, et al. American Thyroid Association Surgery Working Group; American Association of Endocrine Surgeons; American Academy of Otolaryngology-Head and Neck Surgery; American Head and Neck Society, Consensus statement on the terminology and classification of central neck dissection for thyroid

- cancer. *Thyroid*. 2009; 19(11): 1153-8. DOI: 10.1089/thy.2009.0159
11. Cheah WK, Arici C, Ituarte PH, Siperstein AE, Duh QY, Clark OH. Complications of neck dissection for thyroid cancer. *World J Surg*. 2002; 26(8): 1013–16. DOI: 10.1007/s00268-002-6670-4
 12. Robbins KT, Clayman G, Levine PA, Medina J, Sessions R, Shaha A, Som P, Wolf GT; American Head and Neck Society; American Academy of Otolaryngology-Head and Neck Surgery. Neck dissection classification update: revisions proposed by the American Head and Neck Society and the American Academy of Otolaryngology. *Arch Otolaryngol Head Neck Surg*. 2002; 128(7): 751-8. PMID: 12117328
 13. Raffaelli M, De Crea C, Sessa L, Giustacchini P, Revelli L, Bellantone C, Lombardi CP. Prospective evaluation of total thyroidectomy versus ipsilateral versus bilateral central neck dissection in patients with clinically node-negative papillary thyroid carcinoma. *Surgery*. 2012; 152(6): 957-64. PMID: 23158170; DOI: 10.1016/j.surg.2012.08.053
 14. Hughes DT, Doherty GM. Central neck dissection for papillary thyroid cancer. *Cancer Control*. 2011; 18(2): 83-8. DOI: 10.1177/107327481101800202
 15. Giugliano G, Proh M, Gibelli B, Grosso E, Tagliabue M, De Fiori E, Maffini F, Chiesa F, Ansarin M. Central neck dissection in differentiated thyroid cancer: technical notes. *Acta Otorhinolaryngol Ital*. 2014; 34(1): 9-14. PMID: 24711677
 16. Raffaelli M, De Crea C, Sessa L, Giustacchini P, Bellantone R, Lombardi CP. Can intraoperative frozen section influence the extension of central neck dissection in cN0 papillary thyroid carcinoma? *Langenbecks Arch Surg*. 2013; 398(3): 383-8. DOI: 10.1007/s00423-012-1036-3
 17. Raina S, Rocko JM, Swaminathan AP, Brief DK, Lazaro EJ. Current attitudes in the management of thyroid cancer. *Am Surg*. 1983; 49(2): 110–2.
 18. Nicolosi A, Mallocci A, Esu S, Addis E, Tarquini A. The role of node-picking lymphadenectomy in the treatment of differentiated carcinoma of the thyroid. *Minerva Chir*. 1993; 48(9): 459–63.
 19. Munacchio MJ, Kim AW, Vijungco JD, Prinz RA. Greater local recurrence occurs with “berry picking” than neck dissection in thyroid cancer. *Am Surg*. 2003; 69(3): 191–7. PMID: 12678473
 20. Zarnegar R, Brunaud L, Clark OH. Prevention, evaluation, and management of complications following thyroidectomy for thyroid carcinoma. *Endocrinol Metab Clin North Am*. 2003; 32(2): 483-502. PMID: 12800542
 21. Wei T, Li Z, Jin J, Chen R, Gong Y, Du Z, Gong R, Zhu J. Autotransplantation of inferior parathyroid glands during central neck dissection for papillary thyroid carcinoma: a retrospective cohort study. *Int J Surg*. 2014; 12(12): 1286-90. DOI: 10.1016/j.ijssu.2014.11.001
 22. Hermann M, Hellebart C, Freissmuth M. Neuromonitoring in Thyroid Surgery. Prospective Evaluation of Intraoperative Electrophysiological Responses for the Prediction of Recurrent Laryngeal Nerve Injury. *Ann Surg*. 2004; 240(1): 9–17. PMID: 15213612
 23. Paunica M, Manole A, Motofei C, Tanase GL. The Globalization in the actual Context of the European Union Economy. *Proceedings of the international conference on business excellence*. 2018; 12(1): 739-750. DOI: 10.2478/picbe-2018-0066
 24. van Wilgen CP, Dijkstra PU, van der Laan BF, et al. Shoulder and neck morbidity in quality of life after surgery for head and neck cancer. *Head Neck*. 2004; 26(10): 839–44. PMID: 15390203
 25. Ortiz S, Rodriguez JM, Soria T, et al. Extrathyroid spread in papillary carcinoma of the thyroid: clinicopathological and prognostic study. *Otolaryngol Head Neck Surg*. 2001; 124(3): 261–5. PMID: 11240987
 26. Gimm O, Rath FW, Dralle H. Pattern of lymph node metastases in papillary thyroid carcinoma. *Br J Surg*. 1998; 85(2): 252–4.
 27. Ciuhu AN, Rahnea Niță RA, Popescu M, Dumitru Badiu CD, Pantea Stoian AM, Lupuliasa D, Gherghiceanu F, Diaconu CC, Rahnea Niță G. Evidence of strong opioid therapy for palliation of breathlessness in cancer patients. *Farmacia*. 2017; 65(2):173-178.
 28. Roh JL, Park JY, Park CI. Total thyroidectomy plus neck dissection in differentiated papillary thyroid carcinoma patients: pattern of nodal metastasis, morbidity, recurrence, and postoperative levels of serum parathyroid hormone. *Ann Surg*. 2007; 245(4): 604–10. PMID: 17414610; DOI: 10.1097/01.sla.0000250451.59685.67