

REVIEW ARTICLE

Facial Erythema of Rosacea – Aetiology, Different Pathophysiologies and Treatment Options

Martin STEINHOFF^{1,3}, Martin SCHMELZ⁴ and Jürgen SCHAUBER⁵¹Department of Dermatology and UCD Charles Institute for Translational Dermatology, University College Dublin, Belfield, Dublin-4, Ireland, ²Department of Dermatology, University of San Diego, San Diego, ³Department of Neurosciences, University of California, Davis, CA, USA, ⁴Department of Anaesthesiology, University of Heidelberg, Mannheim, and ⁵Department of Dermatology and Allergy, Ludwig-Maximilian University Munich, Munich, Germany

Rosacea is a common chronic skin condition that displays a broad diversity of clinical manifestations. Although the pathophysiological mechanisms of the 4 subtypes are not completely elucidated, the key elements often present are augmented immune responses of the innate and adaptive immune system, and neurovascular dysregulation. The most common primary feature of all cutaneous subtypes of rosacea is transient or persistent facial erythema. Perilesional erythema of papules or pustules is based on the sustained vasodilation and plasma extravasation induced by the inflammatory infiltrates. In contrast, transient erythema has rapid kinetics induced by trigger factors independent of papules or pustules. Amongst the current treatments for facial erythema of rosacea, only the selective α_2 -adrenergic receptor agonist brimonidine 0.33% topical gel (Mirvaso®) is approved. This review aims to discuss the potential causes, different pathophysiologies and current treatment options to address the unmet medical needs of patients with facial erythema of rosacea. *Key words: rosacea; erythema; brimonidine; pathophysiology; vasculature; treatment.*

Accepted Dec 21, 2015; Epub ahead of print Dec 30, 2015

Acta Derm Venereol 2016; 96: 579–586.

Prof Martin Steinhoff, Department of Dermatology and Charles Institute for Translational Dermatology, School of Medicine and Medical Sciences, University College Dublin, Dublin, Ireland. E-mail: martin.steinhoff@ucd.ie

Rosacea is a common chronic facial skin disease with female predominance that affects millions of patients worldwide, mostly individuals with fair skin (Fitzpatrick phenotypes I–II) and the northwest European population (1–3). Rosacea is diagnosed when one or more of the following primary features are present: flushing (transient erythema); persistent (non-transient) erythema in certain facial areas; papules and pustules; and telangiectasia (2, 4). Secondary features are often present alongside the primary symptoms, but can also appear independently and include burning or stinging, plaques, dry appearance, oedema, ocular involvement (e.g. blepharitis, “dry eyes”, photosensitivity, recurrent hordeolum), peripheral location (e.g. scalp and ears) and phymatous changes (4, 5).

To aid the different dominant features and for improved diagnosis, the most common patterns of signs and symptoms of rosacea have been designated as 4 different subtypes, erythematotelangiectatic (ETR), papulopustular (PPR), phymatous (PhR) and ocular (OR) (3), with ETR and PPR being the two most common subtypes (6).

CORRELATIONS BETWEEN CLINICAL FEATURES AND VASCULAR CHANGES

As a broad diversity of clinical manifestations are associated with rosacea, a variety of pathophysiological mechanisms have been linked with the different clinical presentations; none of these mechanisms have been completely elucidated. One of the reasons for this is that all 4 subtypes have never been studied in parallel. Moreover, in PPR, biopsies have mostly been taken from papules or pustules, and have not been compared with erythematous areas in PPR (1, 7). It is thought that although no single mechanism is dominant in all cases of rosacea, each individual mechanism has a varying presence in individual cases and may correlate with the different clinical features (8). Again, an experimental basis for this hypothesis by comparison of the different subtypes does not exist. In addition to these pathophysiological aspects, rosacea also remains an under-diagnosed and under-treated skin condition (2). In particular, the treatment of facial erythema of rosacea is a common clinical challenge.

It is not yet clear if rosacea subtypes develop in a progressive serial fashion, or if the subtypes occur as discrete variants (1, 9). However, patients often report that rosacea symptoms start with transient flushing that later gives way to a persistent erythema. Facial erythema, the most common primary feature of all subtypes of rosacea, has been described as a mandatory diagnostic feature and is thus the predominant mark of patients with rosacea, especially in the ETR and PPR subtypes, but it can also be present in PhR and OR (2, 4, 6, 10). Precise data for this observation, however, are still lacking. Facial erythema is usually diffuse in nature, generally persists despite resolution of inflammatory lesions and predominantly occurs in a central position on the face (8).

Vascular changes in susceptible individuals are thought to be triggered by certain environmental or

lifestyle factors (including ultraviolet [UV] exposure, temperature changes, exercise, spicy food and alcohol consumption [of note, certain alcoholic beverages more than others]) (7, 11). Whether transient and persistent types of erythema possess a different pathophysiology is still unknown. Moreover, the quantity and quality of the various trigger factors that induce erythema in a single patient vary. Flushing shares many clinical and histological characteristics as well as kinetic development of capsaicin-induced neurogenic inflammation (12–14), comprising of sustained vasodilation, oedema of the superficial dermis and leukocyte infiltration (15). In addition to erythema, extensive telangiectasias throughout the superficial and middle dermis are a main histological feature of ETR, but may also occur in other subtypes. However, the presence of enlarged, dilated capillaries, arterioles and venules in the superficial dermis, often of unusual shapes, is particularly important in ETR (7). Signs of blood vessel angiogenesis only occur in the PhR subtype (16). In contrast to flushing, a different pathomechanism appears to underlie blushing. This review aims to discuss the complexities of facial erythema, covering the potential causes, pathophysiology, current treatments and unmet needs in patients with this condition.

AETIOLOGY

The aetiology and pathophysiology of rosacea are not completely understood, and the clinical course likely varies from patient to patient (17). Due to the increased prevalence of rosacea in northern Europeans, a genetic predisposition is suspected; however, the genes involved are yet to be confirmed. Patients with rosacea have a greater than 4-fold increased chance of having a family member with rosacea compared with the general population, and two single-nucleotide polymorphisms (SNPs) have recently been identified as being associated with rosacea in a genome-wide association study, supporting a genetic predisposition (1, 18). One of these SNPs is intergenic but located in proximity to a gene involved in histocompatibility and immune response (human leukocyte antigen [HLA] class II histocompatibility antigen, DR alpha chain [HLA-DRA]), which is consistent with the inflammatory nature of the disease. However, the rosacea subtype of these patients was not confirmed and it is therefore unknown whether these SNPs are associated with the erythema of rosacea. Genetic analyses have also identified polymorphisms in the glutathione S-transferase genes, responsible for cellular defence against reactive oxygen species (ROS) damage (19). These polymorphisms; leading to excessive ROS formation induced by UV light, may be a genetic risk factor in the development of rosacea (19).

Gene array and real-time polymerase chain reaction (PCR) analyses indicate a defined gene profile for each of the different rosacea subtypes (with some overlap

between ETR, PPR and PhR), which also differs from healthy skin (1, 8, 14). Proposed contributory factors to the development of rosacea include: abnormal vascular reactivity; dysregulation of the innate immune system; increased susceptibility of sensory nerves to temperature changes or other trigger factors such as spicy food, ethanol, exercising or climatic exposures (including UV radiation); high ROS levels; increased serine protease or matrix metalloproteinase (MMP) activity; *Demodex* overgrowth; or small intestinal bacterial overgrowth (SIBO) and pilosebaceous unit abnormalities; with variable proof by evidence-based data (2, 9, 20–23).

Triggers for flushing events and aggravation of rosacea include a wide variety of physical, chemical, psychological and emotional factors including temperature changes (heat, noxious cold), UV irradiation, ingredients of spicy food (e.g. mustard oil or capsaicin), certain alcoholic beverages, increased body temperature (exercising), certain cosmetic formulations or emotional stress (24, 25). In this context, the transient receptor potential (TRP) family of receptors should be mentioned. They are a diverse group of non-selective cation channels activated by these various rosacea trigger factors that can subsequently mediate and maintain some of the symptoms of rosacea (flushing as part of acute neurogenic inflammation) (Fig. 1) (13, 14). In addition, lipid metabolites (e.g. sphingosine-1-phosphate [S1P]), organic alcohols (ethanol) and their metabolites (acetaldehyde) or hormones (e.g. neurohormones) can modulate vascular changes during inflammatory processes and may thus play a role in rosacea (1, 26–28). The short half-life of S1P favours a role of this mediator for rapid modulation of vascular tone. In general, however, neurogenic inflammation optimally mimics the rapid onset and kinetics of a flushing incident, and is induced by sensory nerve activation (15, 16, 29). The aetiology of other, rarer, variants such as rosacea conglobata or fulminans (also known as pyoderma faciale) are also poorly understood. The latter only affects young women, often during or after pregnancy, indicating a role of hormonal dysregulation in this rosacea variant (30). The fact that ETR is not primarily associated with adolescence or menopause argues against a significant contribution of hormonal factors in the 4 rosacea subtypes.

PATHOPHYSIOLOGY

Although rosacea has been recognised for thousands of years, its pathophysiology is not well defined and the role of the so-called “trigger factors” in the causation or exacerbation of rosacea is yet to be fully elucidated (24). Rosacea shows huge variations in clinical manifestations and as such probably encompasses a wide range of pathophysiological mechanisms that are not fully elucidated (Fig. S1¹) (7). The key pathophysiological elements that are often present are augmented immune

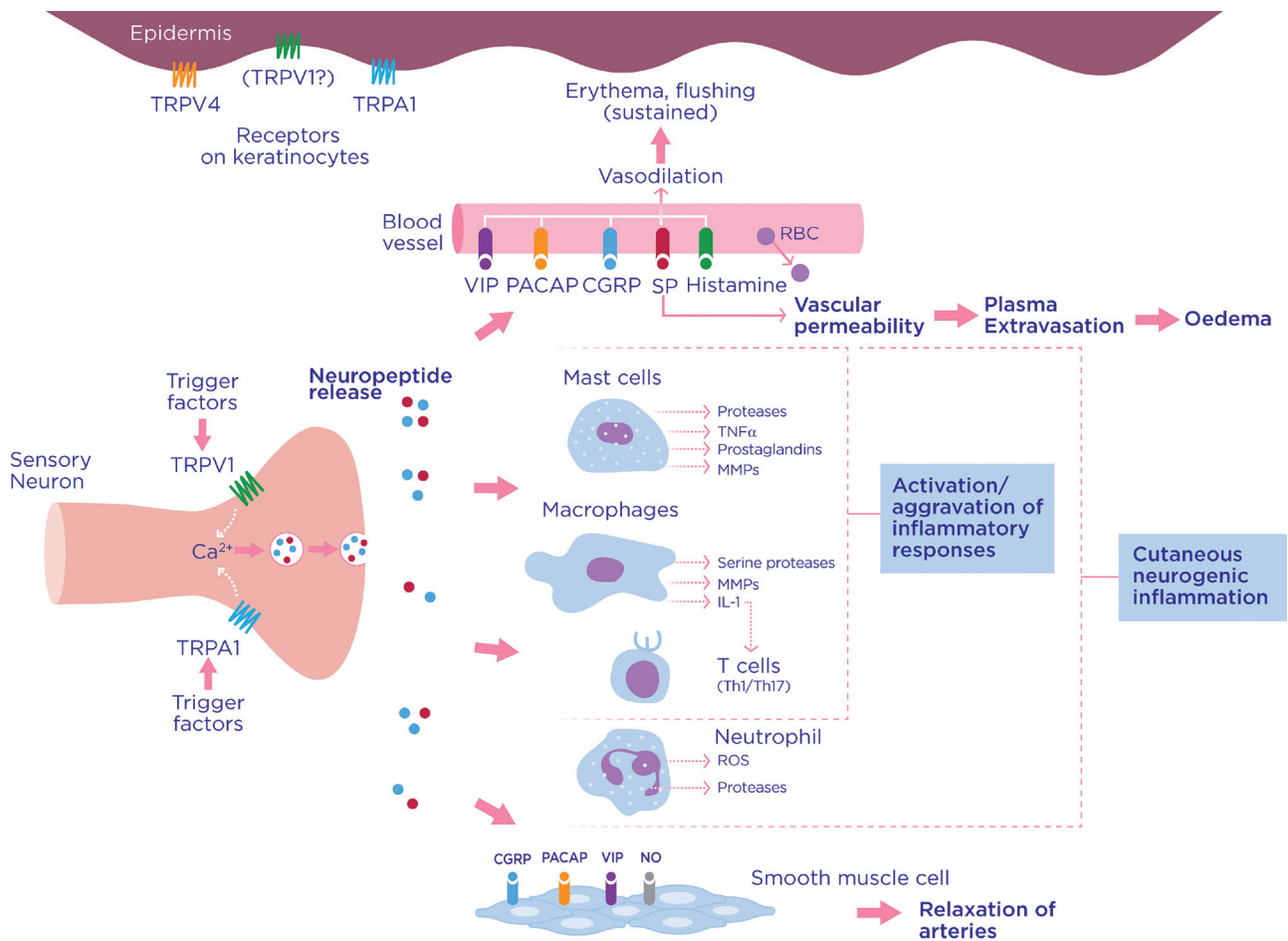


Fig. 1. Potential mechanisms of transient receptor potential vanilloid 1 (TRPV1)- and ankyrin 1 (TRPA1)-mediated inflammatory responses in rosacea. TRPV1 and TRPA1 are non-selective cation (calcium) channels that are activated by rosacea trigger factors and are significantly upregulated in rosacea human tissue. TRPV1 and/or TRPA1 are activated by spices, temperature changes or alcohol. Both can be expressed by neuronal or non-neuronal tissues. Subsequent depolarisation after calcium influx induces release of neuropeptides, including for example substance P (SP), pituitary adenylate cyclase-activating polypeptide (PACAP) and calcitonin gene-related peptide (CGRP). Neuropeptide action on blood vessels causes vasodilation (responsible for erythema and flushing) and plasma extravasation (oedema). Flushing is usually transient in healthy individuals but may be sustained in patients with rosacea. Neuropeptide response on T cells, mast cells and macrophages results in activation or aggravation of the inflammatory response by release of cytokines, lipids, proteases or prostanoids. Macrophages release proteases upon stimulation by cytokines. Smooth muscle cells relax in response to neuropeptides and/or nitric oxide (NO). RBC: red blood cell; ROS: reactive oxygen species. (Modified from Steinhoff et al. (9), Aubdool et al. (13), Sulk et al. (14), Sulk et al. (16), Schaubert et al. (99)).

activation and response, and neurovascular dysregulation (6, 7). However, a critical problem is that early ETR (commonly-termed ‘pre-rosacea’ or ‘early-onset rosacea’), which manifests as transient flushing without any other rosacea signs or symptoms and is dependent on rosacea trigger factors, has not been thoroughly investigated. So far, researchers have found a marked upregulation of genes involved in vasoregulation and neurogenic inflammation in all subtypes of rosacea (16). However, the correlation with dysregulated protein levels in the pathophysiology of rosacea remains to be studied; thus, the cause or causes leading to transient flushing and subsequent persistent erythema are still poorly understood in humans. The most promising preli-

minary evidence for a pathophysiological impact for the induction of erythema and vasodilation demonstrates an involvement of antimicrobial peptides and proteases (31), neuropeptides (9) or TRP ion channels (14).

Various microbes including bacteria or mites have been implicated in the pathophysiology of rosacea. A role of *Helicobacter pylori* could not be verified in various studies (32, 33), but a role of a dysregulated microbiome in patients with SIBO might be responsible for rosacea in a certain subset of patients (22).

Demodex folliculorum or bacteria digested within *Demodex* mites have been implicated in the pathophysiology of rosacea and are thought to trigger the innate immune responses rather than be a mandatory component (23, 26). However, gene array studies and histological data do not support an important role for known microbial agents in the early phase of rosacea (ETR) (1, 17, 34). As

¹<http://www.medicaljournals.se/acta/content/?doi=10.2340/00015555-2335>

with SIBO and chemical trigger factors, it is possible that different trigger factors in different subgroups lead to the same clinical manifestations of rosacea, similar to what is observed for IgE⁺ and IgE⁻ atopic dermatitis. In future, thorough studies must include all subtypes of rosacea. Of note, no evidence-based studies exist regarding the incidence of trigger factors including *Demodex* or bacteria such as *Bacillus oleronius* in early ETR.

Augmented immune response

In patients with ETR, there is a marked upregulation of proinflammatory and vasoregulatory genes (8). The inflammatory infiltrate, which is present in all 4 subtypes, is still poorly characterised. In ETR, a lymphomonocytic infiltrate consisting of predominantly CD3⁺ T cells (70–80%), 10–20% CD20⁺ B cells, and a few histiocytes, has been described (7). However, a more precise immunohistochemical characterisation of all subtypes of rosacea would be desirable. Comparing ETR, PPR and PhR, an increase in mast cell numbers has been described in all of these subtypes (7, 16). An increased infiltrate of dendritic cells has been described for rosacea (35). Our data indicate that increased numbers of CD4⁺ type 1 helper T cells (Th1), macrophages and mast cells can be found in these 3 subtypes, whereas B-cell expression is variable, and possibly related to microbial involvement in certain patients (36). Whether these changes are found in patients with an increased density of *Demodex* mites or bacteria such as *B. oleronius*, which may trigger an inflammatory response, needs to be clarified (37). In ETR, it is thought that there is an early involvement of the innate immune system and, to a lesser extent, the adaptive immune system (8). However, upregulation of both adaptive and innate immune response genes has been demonstrated in patients with ETR, PPR and PhR (1, 8); thus, a contribution of the adaptive immune system is likely, although it is still poorly understood (1).

The mixed inflammatory infiltrate associated with PPR is characterised by Th1 cells, macrophages and mast cells. Plasma cells are only occasionally seen and neutrophils are limited to pustules (7, 36). When comparing samples from healthy skin with those from patients with PPR, it has been noted that there is an increase in levels of bioactive cathelicidin antimicrobial peptides (in particular LL-37) and the cathelicidin-processing serine protease kallikrein-5 (31). LL-37 is a potent modulator of the innate immune response and modulates the pro-inflammatory UV response in rosacea (21, 38). Accordingly, gene expression of cathelicidin and kallikrein-5, and activity of serine proteases was inhibited during treatment of rosacea with azelaic acid 15% gel (39). Toll-like receptor 2 (TLR2; known to increase kallikrein-5 expression) is also elevated in PPR (40). TLR2 activates the nucleotide-binding oligomerisation domain (NOD)-like receptor family, pyrin domain

containing 3 (NLRP3) inflammasome, thus initiating caspase-1 activation, release of the pro-inflammatory cytokine IL-1 β and subsequent downstream inflammatory responses (41). TLRs are expressed on sensory neurons and may be responsible for a link between nerve stimulation and augmented innate immunity (42–44).

This pathway of increased cathelicidin expression and increased production of LL-37 peptides has been linked to the endoplasmic reticulum (ER) stress response. ER stress has been suggested as a key factor in the pathogenesis of rosacea, and in fact, all clinical rosacea trigger factors induce ER stress (45). TLR2 expression and activity is increased in response to ER stress (46), demonstrating its role in augmented innate immunity and also providing a link to enhanced nociception. ER stress stimulates cathelicidin production and the synthesis of LL-37 in keratinocytes and epithelial cells via a novel nuclear factor-kappa B (NF κ B) pathway (via downstream activation of the cathelicidin gene promoter) (47). The lipid mediator SIP is upregulated in ER stress and is responsible for this increase in cathelicidin (48). This increased activity associated with cathelicidin expression and metabolism promotes chemoattraction of inflammatory cells and angiogenesis, and may alter the expression of certain components of the extracellular matrix (31, 49).

LL-37 works in synergy with IL-1 β to modulate the immune response (50). The NLRP3 inflammasome is responsible for the production of IL-1 β ; therefore, ER stress leading to TLR2 upregulation (and production of LL-37) is directly connected to NLRP3 inflammasome activation and inflammation in the skin (41). The attenuation of ER stress-mediated TLR2 signalling by anti-rosacea treatment provides evidence for the role of ER stress in the augmented immune response of rosacea (45).

Gene array and real-time PCR analysis of healthy skin compared with ETR, PPR and PhR indicate that a number of different factors are involved in the dysregulation of the inflammatory response in rosacea, including cytokines, chemokines, metalloproteinases, proteases, ROS, alcohol and lipid metabolites (1). However, a systematic genetic profiling of the inflammatory mediators involved in the different subtypes of rosacea is still lacking (36). When available, it will be critical to correlate these mRNA studies with quantitative immunohistochemical and protein data in order to understand the complex phases of inflammatory responses in the different subtypes of rosacea.

Another potentially important element in the pathophysiology of rosacea is an impaired stratum corneum barrier function (8). Increased stratum corneum permeability is probably structurally and functionally linked to an aggravated innate immune response in patients with rosacea. It is possible that the innate immune system is activated as a homeostatic counter-regulatory response to an impaired stratum corneum barrier, resulting in increased trans-epidermal water loss and an increase

in mRNA expression levels, as well as secretion of cathelicidin peptides (LL-37) (34). Future experiments will have to verify the exact role of the innate immune system in all subtypes of rosacea.

VASCULAR CHANGES

Clinically, different vascular changes have to be differentiated in rosacea patients: a) transient flushing that lasts for minutes to hours; b) persistent erythema that lasts for days to weeks; c) perilesional erythema around papules or pustules. A fourth vascular reaction that can occur concurrently in rosacea patients and often leads to confusion is “blushing”. Blushing is a more pinkish, lighter erythema that is not predominantly located in the facial T-zone (central face), but more homogeneously distributed in the central face and peripheral cheeks, as well as behind the ears, which is not present in flushing. Blushing is mediated by the sympathetic nervous system as a response to emotional or stressful events (51). We believe that the pathophysiological mechanism of blushing is the same in rosacea patients as in the healthy population and, importantly, that it is different from the flushing mechanism. Blushing is transient and not associated with inflammation (51), but its occurrence can be a confounding factor in rosacea. In contrast, flushing triggered by stimulation of the sensory nerves through release of neuropeptides may also result in acute inflammation (neurogenic inflammation). The fact that patients with ETR already have a marked mast cell infiltrate and significant local increase of inflammatory neuromediators and cytokines (16, 52) indicates that flushing is an acute inflammatory process induced by sensory nerves, known since the early works of Jancsó et al. (53) (reviewed by Roosterman et al. (15)). Therefore, it must be assumed that a different pathomechanism underlies each vascular mechanism (1). This hypothesis is also supported by a recent human study in which laser Doppler was used to detect blood flow after iontophoresis of acetylcholine. The results indicate that an axon reflex mechanism is responsible for enhanced flushing in patients with the most severe rosacea symptoms (54).

Vasoregulatory mediators

The critical mediators that induce sustained flushing in rosacea patients may be potent vasoregulatory neuropeptides such as pituitary adenylate cyclase-activating polypeptide (PACAP), vasoactive intestinal peptide (VIP) or calcitonin gene-related peptide (CGRP), as well as lipid or alcohol metabolites that can also induce prolonged vasodilation (1, 9, 13, 15, 27, 55, 56). Substance P (SP) may also contribute to the oedema, as seen in all 3 subtypes of rosacea at the microscopic level (16, 57). Other potent vasodilators of skin blood vessels are ROS and proteases (13, 31). All 3 skin-subtypes of

rosacea demonstrate similar histopathological changes with enlarged, dilated arterioles, capillaries and venules in the upper dermis (7, 16), postcapillary oedema and transmigration of leukocytes (predominantly T cells and monocytes) (7–9). MMPs that are abundantly enhanced at the mRNA level (up to 300-fold) in all 3 skin-subtypes of rosacea, especially MMP-12, -1 and -9 may critically contribute to tissue destruction and development of telangiectasias (9, 16). mRNA levels of markers for angiogenesis or lymphatic vessel regulation such as vascular endothelial growth factor A (VEGFA), CD31, podoplanin or lymphatics (D2-40) are also increased in rosacea patients (8). However, these mRNA levels do not correlate positively with morphometric immunohistochemistry data that indicate marked vasodilation in ETR and PPR without evidence of angiogenesis (although it is present in PhR) (16). Whether this argues for an existing subtype progression from ETR/PPR to PhR through chronic inflammatory processes that result in the fibrotic changes in PhR will have to be assessed in the future. Despite all structural changes, functional vascular responsiveness in rosacea patients remains intact, with aggravated and sustained vasodilation in response to the above-mentioned trigger factors still operational in ETR, PPR and PhR (1, 8, 14).

TRP channels

One of the hallmarks of rosacea is increased vasodilation in response to various trigger factors (8). As previously described, many of the trigger factors for rosacea (particularly spicy food, heat, noxious cold, exercising and alcohol) also activate ion channels such as members of the TRP receptor family, including TRPV1 and TRPA1, which are located on nociceptive nerve endings and are involved in prolonged vasodilation and neurogenic inflammation (1, 13, 14, 58). Their activation by these trigger factors may lead to transient flushing even in healthy individuals. Patients with rosacea, however, may experience a sustained activation of TRP channels on nociceptors, resulting in flushing and neurogenic inflammation with leukocyte infiltration. It has been noted that patients with rosacea have a high density of TRPV1-positive nerve fibres and increased levels of TRPV1 mRNA expression (1). As TRPV1 is expressed by sensory nerves, endothelial cells (as shown in mice) and keratinocytes (possibly associated with skin inflammatory responses), the primary source for TRPV1 dysfunction may be the sensory nerve or the endothelium itself (1, 59, 60). Future studies in humans are required to clarify this important question.

Pathophysiological mechanisms of persistent erythema

Taken together, in addition to the transient “flushing” of rosacea patients and the transient “blushing” in healthy humans due to sympathetic activation, there

are 3 different types of persistent erythema that have to be differentiated because of different underlying regulatory mechanisms: *i*) persistent facial erythema of rosacea patients; *ii*) perilesional erythema around papules and pustules in rosacea band also in acne or other diseases (i.e. not rosacea-specific) and *iii*) other “erythematous” inflammatory origins that can sometimes coincide with rosacea (2, 6). Examination of the location of inflammation combined with knowledge of the patient’s history can often identify the latter as eczematous (e.g. seborrhoeic dermatitis, atopic dermatitis, other eczemas or tinea). Perilesional erythema is solely associated with inflammatory lesions such as papules and pustules, and disappears in conjunction with the clearance of the inflammatory lesions (8).

After the differentiation of the different variants, what exactly is the pathophysiology of persistent erythema? Although the details of this mechanism remain unknown, persistent erythema appears to be unaffected by anti-inflammatory treatments with systemic or topical antibiotics, azelaic acid or sulphur and mostly outlasts the apparent resolution of inflammatory lesions (8). But does this mean that persistent erythema has no inflammatory component? Not necessarily, because we know that the inflammatory lympho-monocytic, mast-cell rich infiltrate of ETR patients needs a relatively long time to resolve, as compared with transient flushing, and also that the erythema diminishes in correlation with the reduction of the inflammatory infiltrate (61).

Moreover, several mediators involved in inflammation and innate immunity such as proteases and antimicrobial peptides contribute to rosacea. The cutaneous vasculature can become structurally altered due to continuous vasodilatory stimulation and secondary inflammatory responses, caused by mediators such as LL-37, VEGF and some MMPs (8). The mechanism by which LL-37 enhances the release of inflammatory mediators and promotes angiogenesis is through NLRP3 inflammasome activation (21). IL-1 β modifies angiogenesis by decreasing angiopoietin-1 mRNA expression (62) and LL-37 and IL-1 β can work synergistically to enhance the angiogenic function of endothelial cells (21). The vicious circle of vascular and inflammatory changes causes a persistent dilation of blood and lymphatic vessels, neoangiogenesis, telangiectasia formation and dermal matrix degradation (8).

Neurogenic vasoregulation in erythema

Facial skin perfusion in humans is modulated by neuronal (sympathetic, parasympathetic and nociceptive) and non-neuronal (local inflammatory) mechanisms (Fig. 2). The sympathetic vascular innervation has a mainly thermoregulatory function with vasoconstriction being mediated by the release of noradrenaline and neuropeptide Y (63), aided by local vasoconstriction upon cooling by α_{2c} -receptors (64) and counteracted by ac-

tivation of β_2 -adrenoceptors. In contrast, the mediators of active sympathetic vasodilation – important for heat dissipation and also for emotional blushing – are not yet identified (candidates include VIP, nitric oxide (63) and PACAP (55)). Cholinergic parasympathetic reflex vasodilation is induced by irritation in the eyes, mouth, nose (65) and also following strong gustatory stimuli (66). In addition, skin nociceptors being activated by local inflammatory mediators release vasodilatory neuropeptides (CGRP and SP) in their innervation territory (“axon-reflex” effector). Skin perfusion in facial skin is more complex due to arteriole–venule anastomoses that are controlled by combined sympathetic and nociceptive innervation (67). If dilated, the arteriole–venule shunts

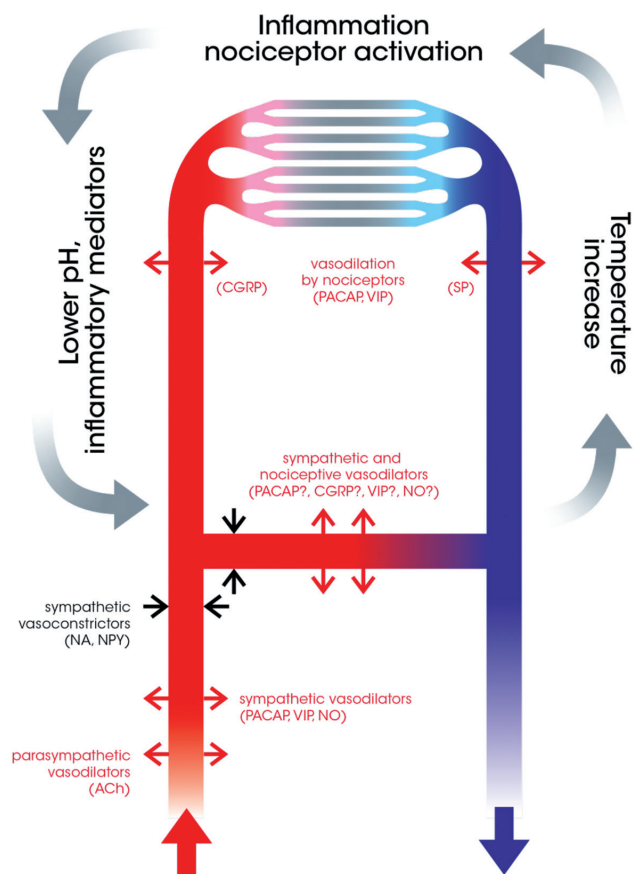


Fig. 2. Mechanisms of facial skin perfusion. Facial skin perfusion is modulated by neuronal and non-neuronal mechanisms. Sympathetic vasoconstriction is mediated by noradrenaline and neuropeptide Y (NPY), whereas mediators of active sympathetic vasodilation are not completely clarified, but probably include pituitary adenylate cyclase-activating polypeptide (PACAP), vasoactive intestinal peptide (VIP) and nitric oxide (NO). Acetylcholine (ACh) mediates the parasympathetic vasodilation response to irritation. Substance P (SP) and calcitonin gene-related peptide (CGRP) released from nociceptive nerve endings induce vasodilation of blood vessels in their innervation territory. Perfusion of facial skin is more complex due to arteriole–venule shunts, innervated by sympathetic and nociceptive nerve fibres. Sympathetic vasodilators may dilate the shunt which shortcuts the nutritive superficial blood flow, leading to skin temperature changes and a loop of inflammation (by nociceptor activation), and an increase in inflammatory mediators. NA: noradrenaline.

increase skin temperature and shortcut the nutritive superficial blood flow. In patients with chronic pain, increased expression of α_{2c} -adrenoceptors on nociceptors innervating these arteriole-venule shunts have been reported (67). Even though there is no evidence for disturbed alpha-adrenergic signalling in rosacea flushing, facial erythema can be reduced by the cutaneous application of an α -adrenoceptor agonist (6, 68).

TREATMENT OPTIONS

This section will focus on treatment options for transient or persistent erythema, based on our current knowledge of this symptom, as discussed above. Table SI¹ summarises the range of treatment options for patients with erythema of rosacea.

General therapeutic strategies (including those targeting inflammatory perilesional erythema of papules and pustules) have been recently discussed in detail elsewhere (2, 69–73). Firstly, both transient and persistent erythema are due to vasodilation. Secondly, we do not know to what extent the vasodilation of transient flushing is inflammatory. Recent publications have emphasised that erythema is an inflammatory skin condition and not just a cosmetic problem (1, 14, 16, 34). Therapeutic success is hindered by the fact that until recently, there have been no effective anti-inflammatory topicals that control the inflammation or vasodilation without the severe adverse effects that treatments such as topical glucocorticosteroids induce (74). Similarly, topical calcineurin inhibitors, although sometimes effective, can also induce or aggravate rosacea (75, 76). Laser therapy has proven to be an effective therapeutic strategy for facial erythema in some cases (77), although evidence-based information is limited (78). Anecdotally, although evidence-based data are lacking, adverse events of laser therapy, particularly post-treatment purpura, may also occur. In the opinion of the authors, this may be due to an aggravation of the inflammation present. A therapeutic strategy may be to combine laser therapy with an anti-inflammatory regimen, e.g. with modified-release doxycycline or other anti-inflammatory antibiotics. Randomised, controlled studies to support this combination strategy are critically needed.

Brimonidine 0.33% topical gel (Mirvaso[®], Galderma, Paris, France) is a topical pharmacological treatment specifically developed and indicated for the persistent facial erythema of rosacea (79). Due to a salt policy enacted in the United States and European Union, the strength is expressed in terms of the active moiety (brimonidine 0.33%) rather than the salt-strength equivalent that was used in the clinical trials (brimonidine tartrate 0.5%). It is, however, the same drug concentration (80). In phase 2 and phase 3 (including long-term) clinical trials, the efficacy of brimonidine 0.33% topical gel over vehicle has been demonstrated. In these studies, brimo-

nidine 0.33% reduced facial erythema significantly, as soon as 30 min after topical application. The effect was transient, with facial erythema reappearing after 9–12 h (81, 82). Adverse events reported in long-term studies following patients for up to 52 weeks were generally mild or moderate in intensity, and tachyphylaxis was not observed (83). A few patients experienced worsening of erythema shortly after application of brimonidine gel. It is unclear at present which patients could be at risk for this adverse event.

It should be noted that antihypertensive drugs may also be used in the treatment of rosacea. For example, beta blockers, which may cause vasoconstriction of the cutaneous arterial blood vessels (via blocking the arterial β_2 -adrenergic receptor) are used off-label for the treatment of erythema (84). Calcium channel activation induces vasodilation by acting on vascular smooth muscle. The use of calcium channel blockers in the treatment of rosacea is not encouraged, based on the observation that these agents may induce or enhance symptoms (85), although a link could not be established for triggering or exacerbation of rosacea symptoms with calcium channel blockers in a recent study (86). In the same study, it was shown that beta blockers such as atenolol and bisoprolol were associated with slightly reduced risks during drug use (86).

Most approved agents and off-label medical therapies targeting inflammatory lesions (Table SI¹) are known to have additional benefits in terms of perilesional erythema (34). The recent update of the Cochrane review of interventions for rosacea concluded that there was high-quality evidence to support the effectiveness of the following approved agents in this setting, i.e. azelaic acid, doxycycline, ivermectin and brimonidine (78).

To conclude, management strategies in rosacea should be based on individual patient symptoms; the psychological and psychosocial impact of the disease should also be considered (11, 87). It is important to educate patients, to identify and avoid possible trigger factors and convey the importance of everyday skin care to maintain the integrity of the skin barrier (while avoiding agents that could exacerbate symptoms) (11).

CONCLUSIONS AND FUTURE DIRECTIONS

Transient or persistent diffuse vascular erythema is the most common symptom of rosacea and has been a considerable unmet need in many patients with rosacea (10). Although the precise causes of the different subtypes of erythema in patients with rosacea and their pathophysiologies are still a topic of investigation and can vary between patients, the most consistent findings in rosacea patients are vascular abnormality and facial erythema (88). The welcome addition of brimonidine tartrate to the armamentarium of treatments for rosacea can offer relief from the symptoms of facial erythema

for patients with rosacea. Recent long-term studies have shown brimonidine 0.33% topical gel to be safe, well tolerated and effective for the treatment of transient as well as persistent erythema in rosacea patients. Future studies will need to demonstrate additional efficacy for facial (not papule or pustule-associated) erythema, which can be observed in all subtypes of rosacea, including OR. Due to the purely symptomatic nature of this effective therapy, research is still required to develop a pathophysiology-based therapy for erythema and inflammation in rosacea.

ACKNOWLEDGEMENTS

MSt has received research support and/or honoraria from Galderma, LaRoche Posay, GSK, Leo Pharm, Bayer, Regeneron, Pfizer, Avon and L'Oreal. JS has received honoraria and/or research support from Galderma, LaRoche Posay, GSK and Noxxon. MSc has no relevant disclosures. Funding for the study was provided by Galderma Laboratories LP. Medical writing support was provided by Claire Ryall, PhD, Natasha Singh Kent, PhD and Jen Lewis, PhD at Havas Life Medicom and was funded by Galderma Laboratories LP.

REFERENCES

- Steinhoff M, Buddenkotte J, Aubert J, Sulk M, Novak P, Schwab VD, et al. Clinical, cellular, and molecular aspects in the pathophysiology of rosacea. *J Invest Dermatol Symp Proc* 2011; 15: 2–11.
- Baldwin HE. Diagnosis and treatment of rosacea: State of the art. *J Drugs Dermatol* 2012; 11: 725–730.
- Tan J, Blume-Peytavi U, Ortonne JP, Wilhelm K, Marticou L, Baltas E, et al. An observational cross-sectional survey of rosacea: clinical associations and progression between subtypes. *Br J Dermatol* 2013; 169: 555–562.
- Wilkin J, Dahl M, Detmar M, Drake L, Liang MH, Odom R, et al. Standard grading system for rosacea: Report of the National Rosacea Society Expert Committee on the Classification and Staging of Rosacea. *J Am Acad Dermatol* 2004; 50: 907–912.
- Wilkin J, Dahl M, Detmar M, Drake L, Feinstein A, Odom R, et al. Standard classification of rosacea: Report of the National Rosacea Society Expert Committee on the Classification and Staging of Rosacea. *J Am Acad Dermatol* 2002; 46: 584–587.
- Del Rosso JQ. Management of facial erythema of rosacea: What is the role of topical α -adrenergic receptor agonist therapy? *J Am Acad Dermatol* 2013; 69: S44–56.
- Cribier B. Rosacea under the microscope: characteristic histological findings. *J Eur Acad Dermatol Venereol* 2013; 27: 1336–1343.
- Del Rosso JQ. Advances in understanding and managing rosacea: part 1: connecting the dots between pathophysiological mechanisms and common clinical features of rosacea with emphasis on vascular changes and facial erythema. *J Clin Aesthet Dermatol* 2012; 5: 16–25.
- Steinhoff M, Schaubert J, Leyden JJ. New insights into rosacea pathophysiology: A review of recent finding. *J Am Acad Dermatol* 2013; 69: S15–26.
- Del Rosso JQ. Advances in understanding and managing rosacea: part 2: the central role, evaluation, and medical management of diffuse and persistent facial erythema of rosacea. *J Clin Aesthet Dermatol* 2012; 5: 26–36.
- Odom R, Dahl M, Dover J, Draelos Z, Drake L, Macsai M, et al. Standard management options for rosacea, part 1: overview and broad spectrum of care. *Cutis* 2009; 84: 43–47.
- Lin Q, Li D, Xu X, Zou X, Fang L. Roles of TRPV1 and neuropeptidergic receptors in dorsal root reflex-mediated neurogenic inflammation induced by intradermal injection of capsaicin. *Mol Pain* 2007; 3: 30.
- Aubdool AA, Brain SD. Neurovascular aspects of skin neurogenic inflammation. *J Invest Dermatol Symp Proc* 2011; 15: 33–39.
- Sulk M, Seeliger S, Aubert J, Schwab VD, Cevikbas F, Rivier M, et al. Distribution and expression of non-neuronal transient receptor potential (TRPV) ion channels in rosacea. *J Invest Dermatol* 2012; 132: 1253–1262.
- Roosterman D, Goerge T, Schneider SW, Bunnett NW, Steinhoff M. Neuronal control of skin function: the skin as a neuroimmunoendocrine organ. *Physiol Rev* 2006; 86: 1309–1379.
- Schwab VD, Sulk M, Seeliger S, Nowak P, Aubert J, Mess C, et al. Neurovascular and neuroimmune aspects in the pathophysiology of rosacea. *J Invest Dermatol Symp Proc* 2011; 15: 53–62.
- Gupta AK, Chaudhry MM. Rosacea and its management: an overview. *J Eur Acad Dermatol Venereol* 2005; 19: 273–285.
- Chang AL, Raber I, Xu J, Li R, Spitale R, Chen J, et al. Assessment of the genetic basis of rosacea by genome-wide association study. *J Invest Dermatol* 2015; 135: 1548–1555.
- Yazici AC, Tamer L, Ikizoglu G, Kaya TI, Api H, Yildirim H, et al. GSTM1 and GSTT1 null genotypes as possible heritable factors of rosacea. *Photodermatol Photoimmunol Photomed* 2006; 22: 208–210.
- Yamasaki K, Gallo RL. The molecular pathology of rosacea. *J Dermatol Sci* 2009; 55: 77–81.
- Salzer S, Kresse S, Hirai Y, Koglin S, Reinholz M, Ruzicka T, et al. Cathelicidin peptide LL-37 increases UVB-triggered inflammasome activation: Possible implications for rosacea. *J Dermatol Sci* 2014; 76: 173–179.
- Parodi A, Paolino S, Greco A, Drago F, Mansi C, Rebora A, et al. Small intestinal bacterial overgrowth in rosacea: clinical effectiveness of its eradication. *Clin Gastroenterol Hepatol* 2008; 6: 759–764.
- Forton FM. Papulopustular rosacea, skin immunity and Demodex: pityriasis folliculorum as a missing link. *J Eur Acad Dermatol Venereol* 2012; 26: 19–28.
- Blount BW, Pelletier AL. Rosacea: a common, yet commonly overlooked, condition. *Am Fam Physician* 2002; 66: 435–440.
- National Rosacea Society. Rosacea Triggers Survey 2014 [17/03/2014]. Available from: <http://www.rosacea.org/patients/materials/triggersgraph.php>.
- Gerber PA, Buhren BA, Steinhoff M, Homey B. Rosacea: The cytokine and chemokine network. *J Invest Dermatol Symp Proc* 2011; 15: 40–47.
- Toda N, Ayajiki K. Vascular actions of nitric oxide as affected by exposure to alcohol. *Alcohol Alcohol* 2010; 45: 347–355.
- Melnik BC. Rosacea: the blessing of the celts – an approach to pathogenesis through translational research. *Acta Derm Venereol* 2016; 96: 147–156.
- Aleman R, Kleuser B, Ruwisch L, Danneberg K, Lass H, Hashemi R, et al. Depolarisation induces rapid and transient formation of intracellular sphingosine-1-phosphate. *FEBS Lett* 2001; 509: 239–244.
- Reinholz M, Tietze JK, Kilian K, Schaller M, Schofer

- H, Lehmann P, et al. Rosacea – S1 guideline. *J Dtsch Dermatol Ges* 2013; 11: 768–780.
31. Yamasaki K, Di Nardo A, Bardan A, Murakami M, Ohtake T, Coda A, et al. Increased serine protease activity and cathelicidin promotes skin inflammation in rosacea. *Nat Med* 2007; 13: 975–980.
 32. Jones MP, Knable AL, White MJ, Durning SJ. *Helicobacter pylori* in rosacea: Lack of an association. *Arch Dermatol* 1998; 134: 511.
 33. Herr H, You CH. Relationship between *Helicobacter pylori* and rosacea: it may be a myth. *J Korean Med Sci* 2000; 15: 551–554.
 34. Del Rosso JQ, Gallo RL, Kircik L, Thiboutot D, Baldwin HE, Cohen D. Why is rosacea considered to be an inflammatory disorder? The primary role, clinical relevance, and therapeutic correlations of abnormal innate immune response in rosacea-prone skin. *J Drugs Dermatol* 2012; 11: 694–700.
 35. Brown TT, Choi EY, Thomas DG, Hristov AC, Chan MP. Comparative analysis of rosacea and cutaneous lupus erythematosus: histopathologic features, T-cell subsets, and plasmacytoid dendritic cells. *J Am Acad Dermatol* 2014; 71: 100–107.
 36. Buhl T, Sulk M, Nowak P, Buddenkotte J, McDonald I, Aubert J, et al. Molecular and morphological characterization of inflammatory infiltrate in rosacea reveals activation of Th1/Th17 pathways. *J Invest Dermatol* 2015; 135: 2198–2208.
 37. Lacey N, Delaney S, Kavanagh K, Powell FC. Mite-related bacterial antigens stimulate inflammatory cells in rosacea. *Br J Dermatol* 2007; 157: 474–481.
 38. Scott MG, Davidson DJ, Gold MR, Bowdish D, Hancock REW. The human antimicrobial peptide LL-37 Is a multifunctional modulator of innate immune responses. *J Immunol* 2002; 169: 3883–3891.
 39. Coda AB, Hata T, Miller J, Audish D, Kotol P, Two A, et al. Cathelicidin, kallikrein 5, and serine protease activity is inhibited during treatment of rosacea with azelaic acid 15% gel. *J Am Acad Dermatol* 2013; 69: 570–577.
 40. Yamasaki K, Kanada K, Macleod DT, Borkowski AW, Morizane S, Nakatsuji T, et al. TLR2 expression is increased in rosacea and stimulates enhanced serine protease production by keratinocytes. *J Invest Dermatol* 2011; 131: 688–697.
 41. Segovia J, Sabbah A, Mgbemena V, Tsai S-Y, Chang T-H, Berton MT, et al. TLR2/MyD88/NF- κ B pathway, reactive oxygen species, potassium efflux activates NLRP3/ASC inflammasome during respiratory syncytial virus infection. *PLoS ONE* 2012; 7: e29695.
 42. Liu T, Gao YJ, Ji RR. Emerging role of Toll-like receptors in the control of pain and itch. *Neurosci Bull* 2012; 28: 131–144.
 43. Kim D, Kim MA, Cho IH, Kim MS, Lee S, Jo EK, et al. A critical role of toll-like receptor 2 in nerve injury-induced spinal cord glial cell activation and pain hypersensitivity. *J Biol Chem* 2007; 282: 14975–14983.
 44. Guerrero AT, Cunha TM, Verri WA, Jr., Gazzinelli RT, Teixeira MM, Cunha FQ, et al. Toll-like receptor 2/MyD88 signaling mediates zymosan-induced joint hypernociception in mice: participation of TNF- α , IL-1 β and CXCL1/KC. *Eur J Pharmacol* 2012; 674: 51–57.
 45. Melnik BC. Endoplasmic reticulum stress: key promoter of rosacea pathogenesis. *Exp Dermatol* 2014; 23: 868–873.
 46. Shimasaki S, Koga T, Shuto T, Suico MA, Sato T, Watanabe K, et al. Endoplasmic reticulum stress increases the expression and function of toll-like receptor-2 in epithelial cells. *Biochem Biophys Res Commun* 2010; 402: 235–240.
 47. Park K, Elias PM, Oda Y, Mackenzie D, Mauro T, Holleran WM, et al. Regulation of cathelicidin antimicrobial peptide expression by an endoplasmic reticulum (ER) stress signaling, vitamin D receptor-independent pathway. *J Biol Chem* 2011; 286: 34121–34130.
 48. Park K, Elias PM, Shin KO, Lee YM, Hupe M, Borkowski AW, et al. A novel role of a lipid species, sphingosine-1-phosphate, in epithelial innate immunity. *Mol Cell Biol* 2013; 33: 752–762.
 49. Yamasaki K, Schaubert J, Coda A, Lin H, Dorschner RA, Schechter NM, et al. Kallikrein-mediated proteolysis regulates the antimicrobial effects of cathelicidins in skin. *FASEB J* 2006; 20: 2068–2080.
 50. Yu J, Mookherjee N, Wee K, Bowdish DME, Pistolic J, Li Y, et al. Host defense peptide LL-37, in synergy with inflammatory mediator IL-1 β , augments immune responses by multiple pathways. *J Immunology* 2007; 179: 7684–7691.
 51. Drummond PD, Minosora K, Little G, Keay W. Topical ibuprofen inhibits blushing during embarrassment and facial flushing during aerobic exercise in people with a fear of blushing. *Eur Neuropsychopharmacol* 2013; 23: 1747–1753.
 52. Casas C, Paul C, Lahfa M, Livideanu B, Lejeune O, Alvarez-Georges S, et al. Quantification of *Demodex folliculorum* by PCR in rosacea and its relationship to skin innate immune activation. *Exp Dermatol* 2012; 21: 906–910.
 53. Jancsó N, Jancsó-Gábor A, Szolcsányi J. Direct evidence for neurogenic inflammation and its prevention by denervation and by pretreatment with capsaicin. *Br J Pharmacol* 1967; 31: 138–151.
 54. Drummond PD, Su D. Endothelial and axon reflex vasodilatation to acetylcholine in rosacea-affected skin. *Arch Dermatol Res* 2012; 304: 133–137.
 55. Seeliger S, Buddenkotte J, Schmidt-Choudhury A, Rognoli C, Shpacovitch V, von Armim U, et al. Pituitary adenylate cyclase activating polypeptide: an important vascular regulator in human skin in vivo. *Am J Pathol* 2010; 177: 2563–2575.
 56. Brain SD, Grant AD. Vascular actions of calcitonin gene-related peptide and adrenomedullin. *Physiol Rev* 2004; 84: 903–934.
 57. Powell FC, Corbally N, Pwell D. Substance P and rosacea. *J Am Acad Dermatol* 1993; 28: 132–133.
 58. Koivisto A, Chapman H, Jalava N, Korjamo T, Saarnilehto M, Lindstedt K, et al. TRPA1: a transducer and amplifier of pain and inflammation. *Basic Clin Pharmacol Toxicol* 2014; 114: 50–55.
 59. Fernandes ES, Fernandes MA, Keeble JE. The functions of TRPA1 and TRPV1: moving away from sensory nerves. *Br J Pharmacol* 2012; 166: 510–521.
 60. Denda M, Tsutsumi M. Roles of transient receptor potential proteins (TRPs) in epidermal keratinocytes. *Adv Exp Med Biol* 2011; 704: 847–860.
 61. Bjerring P. Comparison of the bioactivity of mometasone furoate 0.1% fatty cream, betamethasone dipropionate 0.05% cream and betamethasone valerate 0.1% cream in humans. Inhibition of UV-B-induced inflammation monitored by laser Doppler blood flowmetry. *Skin Pharmacol* 1993; 6: 187–192.
 62. Fan F, Stoeltzing O, Liu W, McCarty MF, Jung YD, Reinmuth N, et al. Interleukin-1 β regulates angiopoietin-1 expression in human endothelial cells. *Cancer Res* 2004; 64: 3186–3190.
 63. Charkoudian N. Mechanisms and modifiers of reflex induced cutaneous vasodilation and vasoconstriction in

- humans. *J Appl Physiol* 2010; 109: 1221–1228.
64. Honda M, Suzuki M, Nakayama K, Ishikawa T. Role of alpha₂C-adrenoceptors in the reduction of skin blood flow induced by local cooling in mice. *Br J Pharmacol* 2007; 152: 91–100.
 65. Drummond PD. Sweating and vascular responses in the face: normal regulation and dysfunction in migraine, cluster headache and harlequin syndrome. *Clin Auton Res* 1994; 4: 273–285.
 66. Drummond PD. Mechanism of gustatory flushing in Frey's syndrome. *Clin Auton Res* 2002; 12: 144–146.
 67. Albrecht PJ, Hou Q, Argoff CE, Storey JR, Wymer JP, Rice FL. Excessive peptidergic sensory innervation of cutaneous arteriole-venule shunts (AVS) in the palmar glabrous skin of fibromyalgia patients: implications for widespread deep tissue pain and fatigue. *Pain Med* 2013; 14: 895–915.
 68. Tanghetti EA, Jackson JM, Belasco KT, Friedrichs A, Hougier F, Johnson SM, et al. Optimizing the use of topical brimonidine in rosacea management: panel recommendations. *J Drugs Dermatol* 2015; 14: 33–40.
 69. Baldwin HE. Systemic therapy for rosacea. *Skin Therapy Lett* 2007; 12: 1–5, 9.
 70. Chang BP, Kurian A, Barankin B. Rosacea: an update on medical therapies. *Skin Therapy Lett* 2014; 19: 1–4.
 71. Del Rosso JQ, Baum EW. Comprehensive medical management of rosacea: an interim study report and literature review. *J Clin Aesthet Dermatol* 2008; 1: 20–25.
 72. Del Rosso JQ, Thiboutot D, Gallo R, Webster G, Tanghetti E, Eichenfield LF, et al. Consensus recommendations from the American Acne & Rosacea Society on the management of rosacea, part 3: a status report on systemic therapies. *Cutis* 2014; 93: 18–28.
 73. Layton A, Thiboutot D. Emerging therapies in rosacea. *J Am Acad Dermatol* 2013; 69: S57–65.
 74. Henge UR, Ruzicka T, Schwartz RA, Cork MJ. Adverse effects of topical glucocorticosteroids. *J Am Acad Dermatol* 2006; 54: 1–15.
 75. Teraki Y, Hitomi K, Sato Y, Izaki S. Tacrolimus-induced rosacea-like dermatitis: a clinical analysis of 16 cases associated with tacrolimus ointment application. *Dermatology* 2012; 224: 309–314.
 76. Yoon TY, Kim HJ, Kim MK. Pimecrolimus-induced rosacea-like demodicidosis. *Int J Dermatol* 2007; 46: 1103–1105.
 77. Liu J, Liu J, Ren Y, Li B, Lu S. Comparative efficacy of intense pulsed light for different erythema associated with rosacea. *J Cosmet Laser Ther* 2014; 16: 324–327.
 78. van Zuuren EJ, Fedorowicz Z, Carter B, van der Linden MMD, Charland L. Interventions for rosacea. *Cochrane Database Syst Rev* 2015; CD003262.
 79. European Medicines Agency Committee for Medicinal Products for Human Use. Assessment report (EMA/CHMP/115246/2014) [November 2014]. Available from: http://www.ema.europa.eu/docs/en_GB/document_library/EPAR_-_Public_assessment_report/human/002642/WC500163196.pdf.
 80. Center for Drug Evaluation and Research Policies and Procedures. Naming of drug product containing salt drug substances 2013 [November 2014]. Available from: <http://www.fda.gov/downloads/AboutFDA/CentersOffices/OfficeofMedicalProductsandTobacco/CDER/ManualofPoliciesProcedures/UCM340273.pdf>.
 81. Fowler J, Jarratt M, Moore A, Meadows K, Pollack A, Steinhoff M, et al. Once-daily topical brimonidine tartrate gel 0.5% is a novel treatment for moderate to severe facial erythema of rosacea: results of two multicentre, randomized and vehicle-controlled studies. *Br J Dermatol* 2012; 166: 633–641.
 82. Fowler J, Jr., Jackson M, Moore A, Jarratt M, Jones T, Meadows K, et al. Efficacy and safety of once-daily topical brimonidine tartrate gel 0.5% for the treatment of moderate to severe facial erythema of rosacea: results of two randomized, double-blind, and vehicle-controlled pivotal studies. *J Drugs Dermatol* 2013; 12: 650–656.
 83. Moore A, Kempers S, Murakawa G, Weiss J, Tauscher A, Swinyer L, et al. Long-term safety and efficacy of once-daily topical brimonidine tartrate gel 0.5% for the treatment of moderate to severe facial erythema of rosacea: results of a 1-year open-labeled study. *J Drugs Dermatol* 2014; 13: 56–61.
 84. Hsu CC, Lee JY. Pronounced facial flushing and persistent erythema of rosacea effectively treated by carvedilol, a nonselective beta-adrenergic blocker. *J Am Acad Dermatol* 2012; 67: 491–493.
 85. Natale F, Cirillo C, Granato C, Concilio C, Siciliano A, Credendino M, et al. Worsening of rosacea in patients treated with dihydropyridine calcium channel blockers: a clinical observation. *Hypertens Res* 2011; 34: 790–791.
 86. Spoendlin J, Voegel JJ, Jick SS, Meier CR. Antihypertensive drugs and the risk of incident rosacea. *Br J Dermatol* 2014; 171: 130–136.
 87. Baldwin H. Psychosocial implications of rosacea. *The Dermatologist* 2012; Supplement: 2–4.
 88. Dayan SH, Pritzker RN, Arkins JP. A new treatment regimen for rosacea: onabotulinumtoxinA. *J Drugs Dermatol* 2012; 11: e76–79.
 89. Shanler SD, Ondo AL. Successful treatment of the erythema and flushing of rosacea using a topically applied selective alpha₁-adrenergic receptor agonist, oxymetazoline. *Arch Dermatol* 2007; 143: 1369–1371.
 90. Elewski BE, Draelos Z, Dreno B, Jansen T, Layton A, Picardo M. Rosacea – global diversity and optimized outcome: proposed international consensus from the Rosacea International Expert Group. *J Eur Acad Dermatol Venereol* 2011; 25: 188–200.
 91. Thiboutot D, Thieroff-Ekerdt R, Graupe K. Efficacy and safety of azelaic acid (15%) gel as a new treatment for papulopustular rosacea: results from two vehicle-controlled, randomized phase III studies. *J Am Acad Dermatol* 2003; 48: 836–845.
 92. Wolf JE, Jr., Del Rosso JQ. The CLEAR trial: results of a large community-based study of metronidazole gel in rosacea. *Cutis* 2007; 79: 73–80.
 93. Sauder D, Miller R, Gratton D, Danby W, Griffiths C, Phillips S. The treatment of rosacea: the safety and efficacy of sodium sulfacetamide 10% and sulfur 5% lotion (Novacet) is demonstrated in a double-blind study. *J Dermatolog Treat* 1997; 8: 79–85.
 94. Wilkin JK, DeWitt S. Treatment of rosacea: topical clindamycin versus oral tetracycline. *Int J Dermatol* 1993; 32: 65–67.
 95. Altinyazar HC, Koca R, Tekin NS, Esturk E. Adapalene vs. metronidazole gel for the treatment of rosacea. *Int J Dermatol* 2005; 44: 252–255.
 96. Stein Gold L, Kircik L, Fowler J, Tan J, Draelos Z, Fleischer A, et al. Efficacy and safety of ivermectin 1% cream in treatment of papulopustular rosacea: results of two randomized, double-blind, vehicle-controlled pivotal studies. *J Drugs Dermatol* 2014; 13: 316–323.
 97. Zhang X, Song Y, Ci X, An N, Ju Y, Li H, et al. Ivermectin inhibits LPS-induced production of inflammatory cytokines and improves LPS-induced survival in mice. *Inflamm Res* 2008; 57: 524–529.

98. Crump A, Omura S. Ivermectin, 'wonder drug' from Japan: the human use perspective. *Proc Jpn Acad Ser B Phys Biol Sci* 2011; 87: 13–28.
99. Schaubert J, Homey B, Steinhoff M. [Current insights into the pathophysiology of rosacea]. *Hautarzt* 2013; 64: 481–488.
100. Picardo M, Ottaviani M. Skin microbiome and skin disease: the example of rosacea. *J Clin Gastroenterol* 2014; 48 Suppl 1: S85–86.
101. Schafer M, Werner S. The cornified envelope: a first line of defense against reactive oxygen species. *J Invest Dermatol* 2011; 131: 1409–1411.
102. Huggenberger R, Detmar M. The cutaneous vascular system in chronic skin inflammation. *J Invest Dermatol Symp Proc* 2011; 15: 24–32.
103. Helfrich YR, Maier LE, Cui Y, Fisher GJ, Chubb H, Fligiel S, et al. Clinical, histologic, and molecular analysis of differences between erythematotelangiectatic rosacea and telangiectatic photoaging. *JAMA Dermatol* 2015; 151: 825–836.
104. Muto Y, Wang Z, Vanderberghe M, Two A, Gallo RL, Di Nardo A. Mast cells are key mediators of cathelicidin-initiated skin inflammation in rosacea. *J Invest Dermatol* 2014; 134: 2728–2736.
105. Liu PT, Stenger S, Li H, Wenzel L, Tan BH, Krutzik SR, et al. Toll-like receptor triggering of a vitamin D-mediated human antimicrobial response. *Science* 2006; 311: 1770–1773.