



Confocal laser endomicroscopy in head and neck cancer: steps forward?

Veronika Volgger^a, Christian Conderman^b, and Christian Stephan Betz^a

Purpose of review

Confocal laser endomicroscopy (CLE) is a novel, noninvasive technique used to obtain microanatomical images of the inner lining of hollow organs. It has been used in a variety of clinical specialties to aid in the diagnosis and treatment planning of inflammatory and neoplastic processes. Our intent is to provide an up-to-date review of the literature in the setting of head and neck diseases as well as describing our own initial results and areas of future research.

Recent findings

With increasing experience using CLE in the upper aerodigestive tract (UADT), evidence is mounting that this method can be a useful adjunct to standard endoscopy and other diagnostic techniques. Recent publications have shown that by using CLE, microanatomical structures of healthy and diseased mucosa can easily be identified, allowing for a differentiation of dysplastic/neoplastic and benign mucosal lesions. Standardized diagnostic protocols as well as clinically relevant classification systems for the UADT have not yet been described.

Summary

CLE is an imaging modality that allows real-time visualization of mucosal cellular architecture and other histologic characteristics. First reports on its use in the UADT have yielded promising results, but the true value of this method is yet to be determined.

Keywords

acriflavine, confocal laser endomicroscopy, fluorescein, in-vivo imaging, squamous cell carcinoma

INTRODUCTION

Endoscopic examination followed by invasive tissue biopsy is the current gold standard in the evaluation of lesions of the upper aerodigestive tract (UADT). In more diffuse or widespread lesions, over or under-treatment is possible when their extent is not clearly identifiable. Therefore, novel optical techniques have been developed to reveal in-situ information about the histologic characteristics of tissues.

Confocal laser endomicroscopy (CLE) is one of the techniques that has found its way into routine clinical use in gastroenterology and its further application is currently under investigation in other fields. CLE allows high-resolution, microanatomical analysis of tissue ('optical biopsies') in real time during endoscopy [1,2]. The utility of this new technology is highlighted by its capacity to differentiate tissue types and entities on the basis of histologic characteristics of the mucosa and sub-mucosal vasculature [3]. These findings could serve to reduce unnecessary biopsies and identify lesions needing further treatment. Moreover, by

determining the exact extent of lesions, a more precise treatment can be rendered and unwanted effects from over and underresection minimized.

TEXT OF REVIEW

In the following, a brief technical background is provided on CLE, it is compared with other novel diagnostic methods, and relevant clinical applications in the head and neck field are presented.

^aDepartment of Otorhinolaryngology, Head & Neck Surgery, Klinikum der Universität München, Munich, Germany and ^bDepartment of Otolaryngology, Head & Neck Surgery, University of California – Irvine Medical Center, Irvine, California, USA

Correspondence to Dr Christian Stephan Betz, Department of Otorhinolaryngology, Head & Neck Surgery, Klinikum der Universität München, Marchioninistr. 15, 81377 Munich, Germany. Tel: +49 89 7095 0; e-mail: christian.betz@med.uni-muenchen.de

Curr Opin Otolaryngol Head Neck Surg 2013, 21:164–170

DOI:10.1097/MOO.0b013e32835df135

KEY POINTS

- Confocal laser scanning endomicroscopy (CLE) is a noninvasive, high-resolution imaging method for the endoscopic examination of the most superficial tissue layers *in vivo*.
- There are two commercially available CLE systems on the market, which work with intravenous fluorescein as a contrast agent.
- CLE has become a diagnostic adjunct to endoscopic examination in the diagnostic workup of Barrett's oesophagus and colorectal neoplasms.
- Although still on a low level of evidence, CLE seems to be helpful to differentiate normal mucosa from dysplastic/early invasive epithelial lesions of the UADT.

Technical background

Confocal microscopy was first described in 1955, but only when the concept was further developed some 20 years later did the first confocal microscopes become commercially available [4].

Confocal laser scanning microscopy (CLSM) provides high-resolution images by scanning a laser focus laterally across a sample and collecting induced fluorescence or (less commonly) reflectance whilst rejecting all out-of-focus light by a pinhole in front of the detector (Fig. 1). With high numerical aperture objectives, submicron resolution can be achieved in all planes. CLE transfers these principles into a miniaturized endoscopic version [5^a].

In CLE, two-dimensional tissue scanning is possible at speeds up to video rate and down to a depth (adjustable or fixed) of approximately

250 μm . In contrast to the cross-sectional orientation of histological slides, CLE images are oriented parallel to the tissue surface ('en face' images). Due to the miniaturization, there are tradeoffs between resolution, field of view and probe size. Nevertheless, lateral and axial resolutions to 0.5 and 3 μm , respectively, fields of view as large as 800 \times 450 μm and probe diameters to 1.0 mm have been achieved [5^a].

Confocal imaging usually relies on tissue fluorescence, requiring the administration of a fluorescent dye to achieve sufficient morphological contrast. The brightness of the resulting image thereby corresponds to the intensity of detected fluorescence.

Comparison of confocal laser endomicroscopy with other optical diagnostic imaging methods

In order to put the method into context for the clinician, the diagnostic capabilities of CLE are compared with those of conventional and other non-invasive optical diagnostic imaging methods. In this review, methods evaluating the tissue surface only are differentiated from sectional imaging techniques. As all techniques provide different information, they should be viewed to complement, and not exclude, each other.

Optical diagnostic techniques evaluating the tissue surface

Autofluorescence imaging (AFI) is based on two-dimensional imaging of fluorescence emitted to the surface by the main tissue fluorophores. It is the difference in distribution of these molecules that

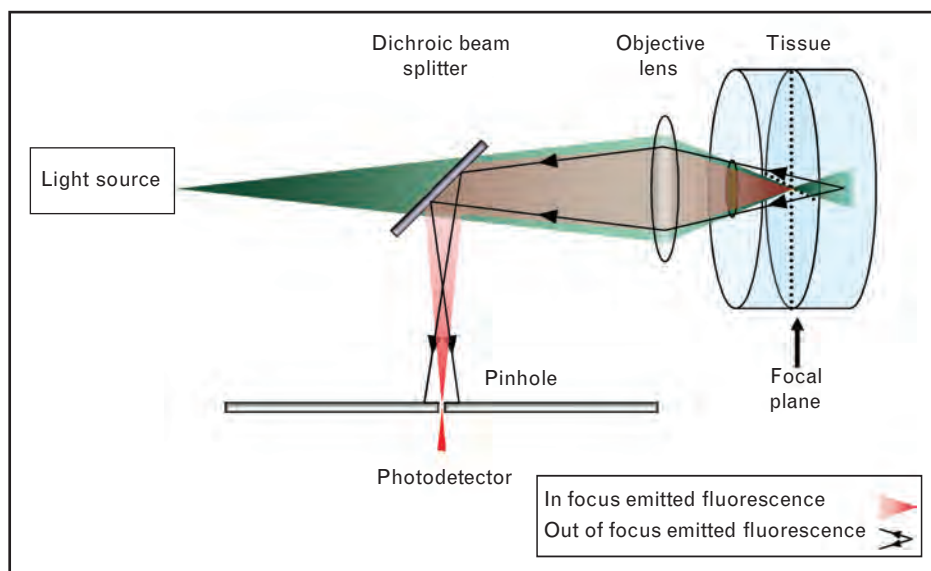


FIGURE 1. Setup of a confocal (endo)microscope.

allows tissue-specific diagnosis. In enhanced fluorescence imaging (EFI), tumour-specific fluorophores are exogenously applied to enhance the contrast. In the UADT, both AFI and EFI have been shown to be a highly sensitive, yet unspecific adjunct to regular endoscopy that highlights and delineates pathologic mucosal changes [6,7].

By filtering the illumination in small bands, narrow band imaging (NBI) highlights the superficial mucosal microvasculature. According to various trials, NBI seems to be another sensitive adjunct method for early detection of dysplasia and cancer in the UADT [8–10].

Sectional imaging methods

Optical coherence tomography (OCT) devices measure the intensity of backscattered light from within the tissue, producing cross-sectional images similar to ultrasound B-scans [11]. For intraluminal applications (e.g. UADT), flexible OCT probes provide resolutions on the order of $10\ \mu\text{m}$ and penetration depths of 2 mm into soft tissues. The predominant diagnostic feature is the recognition of the integrity of the basement membrane, identifying early invasive lesions by the loss of contrast between the epithelial and connective tissue layers with a high sensitivity [12–14].

Photo-acoustic imaging (PAI) is a hybrid biomedical imaging method that can overcome limitations in tissue penetration of other optical methods [15]. Short laser pulses induce thermoelastic expansions within tissue structures that have absorbed the pulses. The propagating sound waves can then be detected, and images to a depth of 5 cm and a resolution of $50\ \mu\text{m}$ can be generated. Even though PAI seems well suited for diagnostic use in the UADT, no such attempts have been published thus far.

Figure 2 provides an overview of the various sectional optical imaging and conventional diagnostic

techniques with respect to their penetration depth and resolution.

Fluorescent contrast agents for confocal laser endomicroscopy

To date, various fluorescent dyes with different staining characteristics have been used in clinical and experimental settings.

The only licensed contrast agent for use with CLE is intravenously applied fluorescein. The optimal dose for obtaining high-quality images (of the colon) seems to be 5 ml of a 10% sodium fluorescein solution [16], but body weight adapted dosing is being discussed [17]. The contrast agent quickly diffuses across capillaries and highlights both blood vessels and interstitial spaces for up to 30 min; however, the image quality deteriorates after 8 min [18]. Serious adverse events such as acute hypotension or anaphylaxis are rare [19,20]. A larger analysis showed mild adverse reactions in 1.4%, but no serious adverse events [21^a].

Intracellular as well as nuclear staining of the uppermost mucosa can be achieved by using topical contrast agents. They are easily applied and do not regularly carry the risk of systemic side effects, yet no agent is officially licensed for in-vivo use in humans and they typically do not penetrate deeply into the mucosa [3]. The most commonly used agent is acriflavine [22–24], which stains the nuclei and is typically applied as acriflavine hydrochloride 0.05%. By combining fluorescein and topical acriflavine, it is possible to calculate nuclear cytoplasmic ratios, which is a useful indicator for cellular differentiation. However, there is a considerable concern about a potential mutagenic effect, which has limited its use in humans [25].

Other topical dyes (or precursors) that have been used for CLE are cresyl violet, hypericin, 5-amino-levalulinic acid, topical fluorescein and 2-NBDG (2-[N-(7-nitrobenz-2-oxa-1,3-dioxol-4-yl)amino]-2-deoxyglucose) [26–30].

Apart from these nonspecific stains, fluorescing probes directed against certain disease-specific biomarkers are being investigated in experimental settings [1]. The successful use of mAbs targeted against the epidermal growth factor receptor (EGFR) or vascular endothelial growth factor (VEGF) has been reported in organ cultures, tissue samples and human tumours grown in mice [31–33]. This might help to target high-risk lesions during endoscopy and to predict response to targeted treatment [33].

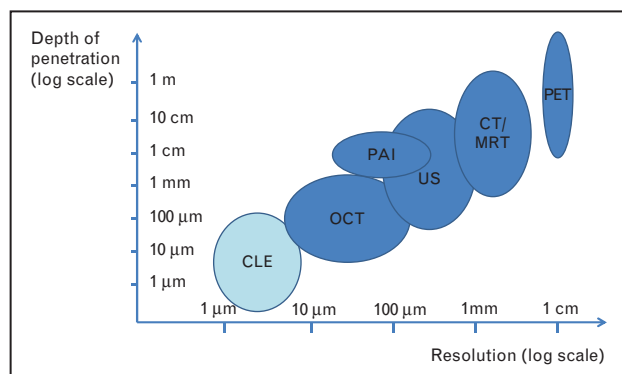


FIGURE 2. Comparative characteristics of sectional optical techniques and conventional imaging methods used for diagnosis of premalignant and malignant changes in the upper aerodigestive tract.

Clinically certified systems

Currently, there are two clinically certified, Communauté Européenne (CE)-marked and Food and

Drug Administration (FDA)-approved CLE systems on the market.

One of them is the ISC 100 Endomicroscope (Pentax Life Care, Tokyo, Japan, and Optiscan Pty Ltd., Noting Hill, Victoria, Australia). The CLE system is integrated into the distal tip of a conventional, large bore, flexible endoscope; this type of system is referred to as an endoscope-based confocal laser endomicroscope (eCLE). The Pentax system provides continuous scanning depths from 0 to 250 μm [8], has an excellent lateral resolution of 0.7 μm and a fixed field of view of $475 \times 475 \mu\text{m}$ [5[†]].

The other system is a probe-based CLE (pCLE) system called Cellvizio (Mauna Kea Technologies, Paris, France). A variety of miniprobes with variable diameters and optical characteristics can be inserted through the working channels of any standard endoscope. In contrast to the Pentax system, the focal plane of each confocal miniprobe is fixed.

The optical characteristics of both systems are compared in Table 1. Both devices function at an excitation of 488 nm and have a detection bandwidth in the upper visible range. Advantages of the Pentax system are a higher resolution and a variable penetration depth. Disadvantages are the large diameter and the inflexible distal tip, limiting its utility in confined anatomical areas [22]. The disadvantages of the probe-based system include a limited lifespan of 20 procedures per miniprobe, which increases the maintenance costs. Advantages are the faster image acquisition rate (12 versus 0.8–1.6 frames/s) and the mosaic function, where single images are stitched together.

According to Optiscan, a third commercial CLE system – built into a rigid endoscope – is currently being developed in cooperation with Carl Zeiss Meditec AG (Jena, Germany), and FDA and CE-clearance is targeted in mid-2013.

Clinical applications

By far, most clinical studies on CLE have been published in gastroenterology. Hallmark indications

with high sensitivities and specificities and good interobserver reliabilities are the differentiation of Barrett's dysplastic lesions from nondysplastic mucosa in the oesophagus [26] and the detection of colorectal neoplasms, especially in follow-up situations [34]. Furthermore, CLE has been successfully studied to evaluate hepatobiliary strictures, gastric cancer, celiac disease and inflammatory bowel disease. For most indications, classification systems have been defined that help to evaluate the obtained results. Furthermore, the American Medical Association has recently approved three CPT (current procedural terminology) codes to cover the use of CLE for the observation of intestinal mucosa during endoscopic procedures. This will facilitate the reimbursement process in the USA and may lead to more widespread acceptance and use of this technology.

Further fields with significant scientific output on CLE are pulmonology, urology and gynaecology. In pulmonology, CLE has been used for early detection of neoplastic changes in the bronchial tree with a high accuracy (91.0%) [24]. In urology, marked differences in microanatomical structures have been reported for normal urothelium and high-grade tumours [35], and diagnostic criteria to facilitate interpretation of CLE images have been defined [36]. A prospective study in gynaecology revealed good results with a sensitivity for the detection of cervical intraepithelial neoplasia (CIN) of 97% [37].

Compared with other fields, literature on CLE in the context of head and neck cancer is sparse. Its use was first described in 2004 using Protoporphyrin IX (PPIX) as a fluorescent marker in three patients with squamous cell carcinoma (SCC) of the tongue, and the findings were compared with healthy mucosa [28]. Using a prototype-rigid CLE system by Optiscan Pty Ltd, the authors noted a higher rate of PPIX synthesis and increases in cellular size and density in cancerous lesions compared with normal mucosa. In 2007, Thong *et al.* [38] used the same system on normal oral mucosa and SCC in humans and in a murine model. They used PPIX and fluorescein as

Table 1. Optical characteristics of commercially available confocal laser endomicroscopy systems

	Cellviziosystem				Pentaxsystem
	Gastro/Coloflex	Gastro/Coloflex UHD	Cholangioflex	Alveoflex	
Imaging rate (frames/s)			12		0.8–1.6
Probe/endoscope diameter (mm)	2.6 (probe)	2.7 (probe)	1.0 (probe)	1.4 (probe)	12.8 (endoscope)
Depth of imaging (μm)	70–130 (fixed)	55–65 (fixed)	40–70 (fixed)	0–50 (fixed)	0–250 (variable)
Lateral resolution (μm)	3.5	1	3.5	3.5	0.7
Field of view (μm)	\varnothing 600	\varnothing 240	\varnothing 325	\varnothing 600	475×475

UHD, Ultra High Definition.

contrast agents, and determined that CLE with both stains seems suitable to distinguish between normal and dysplastic/cancerous tissue.

Following several ex-vivo studies using CLSM for the differentiation of UADT lesions, a group from Rice University (Houston, Texas, USA) published a preliminary report on the use of a prototype pCLE system working in reflectance mode on eight patients with oral SCC in 2008 [39]. Using acetic acid for contrast enhancement, nuclear morphology distinctly differed for normal mucosa and cancerous lesions.

From 2009 onwards, a group from the Institut Gustave Roussy in Villejuif, France (M. Abbaci *et al.*), have repeatedly presented their ex-vivo research on human UADT cancers using the Cellvizio system at various international platforms, but without having put out citable publications. On the basis of more than 100 fresh specimens and using a variety of morphological (fluorescein, acriflavine, cresyl violet, methylene blue, toluidine blue), functional (2-NBDG) and molecular (fluorescent EGFR antibody) stains, they were able to discern dysplastic/cancerous lesions from normal controls. The features that determined (pre)-malignancy were visible after morphological staining and included changes in nuclear sizes and shapes, changes in nuclear cytoplasmic ratio and disorders of keratinization; the preliminary results of functional and molecular staining were more inconsistent. The authors also determined a high degree of correlation (sensitivities 92–97%, specificities 85–97%) when comparing CLE images (dually stained with fluorescein and acriflavine) and conventional H&E slides in blinded evaluations.

In recent years, a clinical group from Mainz/Wiesbaden in Germany published two preliminary reports on the use of the Pentax eCLE system with intravenous fluorescein in 18 patients with SCC of the UADT [40,41*]. In SCC, they were able to visualize neo-angiogenesis, irregular cellular architecture and poorly defined cell borders. In addition, they used acriflavine in ex-vivo specimens and demonstrated differences in nuclear morphology and rates of mitoses in normal and dysplastic specimens. Despite these promising findings, they experienced difficulties in the proper placement of the endoscope in the UADT, and initially in interpreting the obtained images (learning curve).

In the early 2000s, Just *et al.* [42] had published on the use of CLSM for different pathologic states of the UADT. Being hindered by the bulkiness of the system, they have recently developed a prototype rigid CLE system and have applied it in a murine UADT cancer model and in selected human laryngeal diseases *in vivo* [42,43]. In 58 mice

with various states of dysplasia, they were able to differentiate low/moderate from high-grade dysplasia with a sensitivity of 73% and a specificity of 88%, and a moderate interobserver agreement of κ equal to 0.59. In volume scans of human vocal cords, they were able to show typical features of normal and pathologic states.

Again in 2012, Thong *et al.* [44] expanded upon their prior study [38] and developed a prototype endomicroscope-embedded computing system for 3-D visualization of tissue. This was applied in a murine model and subsequently in healthy volunteers, in whom certain UADT regions were examined following topical application of hypericin or fluorescein. Impressively, their setup produced high-quality 3-D renderings of filiform papillae and cellular mucosal structures at video rates.

In an initial, unpublished pilot study, our own group looked at dysplastic/early invasive lesions and normal mucosa (nine subsites of the UADT) in 10 patients and five healthy volunteers using the Cellvizio system after intravenous application of 2.5-ml fluorescein. Supported by an oral pathologist, we managed to visualize tissue architecture at a subcellular level, thus allowing us to differentiate normal and neoplastic mucosa. Due to the contrast agent applied, these distinctions were mostly based on changes in cellular sizes and shapes (Fig. 3). Epithelial definition of normal mucosa appeared to be of highest quality when imaging was performed against a rigid backdrop such as in the hard palate and alveolar ridge. Currently, we anticipate to




FIGURE 3. In-vivo probe-based confocal laser endomicroscopy (CellVizio, Mauna Kea Technologies, Paris, France) with fluorescein (2.5 ml of a 10% solution; Alcon GmbH, Freiburg, Germany) of normal squamous epithelium at the left posterior vocal cord (left panel) and microinvasive squamous cell carcinoma at the left anterior vocal cord (right panel) in a 72-year-old, male patient.

intensify our research activities by launching a prospective clinical trial to better define the role of this method in the diagnosis of primary superficial mucosal lesions and an ex-vivo study on human tissue specimens comparing various stains as for their usefulness and applicability in the UADT.

CONCLUSION

CLE is a promising new, noninvasive diagnostic method providing microanatomical images of superficial tissue layers *in vivo*. The method has established itself in gastroenterology, but numbers of publications in other fields are on the rise. In the UADT, CLE has shown promising results for the differentiation of normal mucosa and dysplastic/microinvasive lesions, but the described methods and the results are hardly comparable. The method has its limitations: in the vertical assessment of tissue changes and because of a rather significant learning curve associated with image interpretation. Further studies are needed to better define the role of CLE in the UADT by standardizing diagnostic protocols concerning the type of system (pCLE or eCLE) and contrast agent (unspecific or targeted) used and by developing and implementing useful classification systems.

Acknowledgements

None.

Conflicts of interest

None declared.

REFERENCES AND RECOMMENDED READING

Papers of particular interest, published within the annual period of review, have been highlighted as:

- of special interest
- of outstanding interest

Additional references related to this topic can also be found in the Current World Literature section in this issue (p. 181).

1. Paull PE, Hyatt BJ, Wassef W, Fischer AH. Confocal laser endomicroscopy: a primer for pathologists. *Arch Pathol Lab Med* 2011; 135:1343–1348.
 2. Goetz M, Watson A, Kiesslich R. Confocal laser endomicroscopy in gastrointestinal diseases. *J Biophotonics* 2011; 4:498–508.
 3. Humphris J, Swartz D, Egan BJ, Leong RWL. Status of confocal laser endomicroscopy in gastrointestinal disease. *Trop Gastroenterol* 2012; 33:9–20.
 4. Minsky M. Memoir on inventing the confocal scanning microscope. *Scanning* 1988; 10:128–138.
 5. Jabbour JM, Saldua MA, Bixler JN, Maitland KC. Confocal endomicroscopy: ■ instrumentation and medical applications. *Ann Biomed Eng* 2012; 40:378–397.
- An up-to-date, comprehensive review on CLE instrumentation and clinical applications.
6. Betz CS, Stepp H, Janda P, *et al.* A comparative study of normal inspection, autofluorescence and 5-ALA-induced PPIX fluorescence for oral cancer diagnosis. *Int J Cancer* 2002; 97:245–252.
 7. Kraft M, Betz CS, Leunig A, Arens C. Value of fluorescence endoscopy for the early diagnosis of laryngeal cancer and its precursor lesions. *Head Neck* 2011; 33:941–948.

8. Yoshimura N, Goda K, Tajiri H, *et al.* Diagnostic utility of narrow-band imaging endoscopy for pharyngeal superficial carcinoma. *World J Gastroenterol* 2011; 17:4999–5006.
 9. Yang SW, Lee YS, Chang LC, *et al.* Diagnostic significance of narrow-band imaging for detecting high-grade dysplasia, carcinoma in situ, and carcinoma in oral leukoplakia. *Laryngoscope* 2012; 122:2754–2761.
 10. Piazza C, Del Bon F, Peretti G, Nicolai P. Narrow band imaging in endoscopic evaluation of the larynx. *Curr Opin Otolaryngol Head Neck Surg* 2012; 20:472–476.
 11. Huang D, Swanson EA, Lin CP, *et al.* Optical coherence tomography. *Science* 1991; 254:1178–1181.
 12. Wong BJ, Jackson RP, Guo S, *et al.* In vivo optical coherence tomography of the human larynx: normative and benign pathology in 82 patients. *Laryngoscope* 2005; 115:1904–1911.
 13. Kraft M, Glanz H, von Gerlach S, *et al.* Clinical value of optical coherence tomography in laryngology. *Head Neck* 2008; 30:1628–1635.
 14. Volgger V, Stepp H, Ihrlir S, *et al.* Evaluation of optical coherence tomography to discriminate lesions of the upper aerodigestive tract. *Head Neck* 2012.
 15. Beard P. Biomedical photoacoustic imaging. *Interface Focus* 2011; 1:602–631.
 16. Shahid MW, Crook JE, Meining A, *et al.* Exploring the optimal fluorescein dose in probe-based confocal laser endomicroscopy for colonic imaging. *J Interv Gastroenterol* 2011; 1:166–171.
 17. Wallace MB, Sharma P, Lightdale C, *et al.* Preliminary accuracy and inter-observer agreement for the detection of intraepithelial neoplasia in Barrett's esophagus with probe-based confocal laser endomicroscopy. *Gastrointest Endosc* 2010; 72:19–24.
 18. Becker V, von Delius S, Bajbouj M, *et al.* Intravenous application of fluorescein for confocal laser scanning microscopy: evaluation of contrast dynamics and image quality with increasing injection-to-imaging time. *Gastrointest Endosc* 2008; 68:319–323.
 19. Kwan AS, Barry C, McAllister IL, Constable I. Fluorescein angiography and adverse drug reactions revisited: the Lions Eye experience. *Clin Experiment Ophthalmol* 2006; 34:33–38.
 20. O'goshi K, Serup J. Safety of sodium fluorescein for in vivo study of skin. *Clin Experiment Ophthalmol* 2006; 34:33–38.
 21. Wallace MB, Meining A, Canto MI, *et al.* The safety of intravenous fluorescein ■ for confocal laser endomicroscopy in the gastrointestinal tract. *Aliment Pharmacol Ther* 2010; 31:548–552.
- An important publication concerning the safety of intravenously applied fluorescein, the most commonly used contrast agent for CLE.
22. Polglase A, McLaren WJ, Skinner SA, *et al.* A fluorescence confocal endomicroscope for in vivo microscopy of the upper and lower GI-tract. *Gastrointest Endosc* 2005; 62:686–695.
 23. Kiesslich R, Burg J, Vieth M, *et al.* Confocal laser endoscopy for diagnosing intraepithelial neoplasias and colorectal cancer in vivo. *Gastroenterology* 2004; 127:706–713.
 24. Fuchs FS, Zirikli S, Hildner K, *et al.* Confocal laser endomicroscopy for diagnosing lung cancer in vivo. *Eur Respir J* 2012.
 25. Kantsevov SV, Adler DG, Conway JD *et al.*; ASGE Technology Committee. Confocal laser endomicroscopy. *Gastrointest Endosc* 2009; 70:197–200.
 26. Dunbar KB. Endomicroscopy in the evaluation of Barrett's esophagus. *Curr Opin Gastroenterol* 2011; 27:374–382.
 27. Olivo M, Lau W, Manivasager V, *et al.* Macro-microscopic fluorescence of human bladder cancer using hypericin fluorescence cystoscopy and laser confocal microscopy. *Int J Oncol* 2003; 23:983–990.
 28. Zheng W, Harris M, Kho KW, *et al.* Confocal endomicroscopic imaging of normal and neoplastic human tongue tissue using ALA-induced-PPIX fluorescence: a preliminary study. *Oncol Rep* 2004; 12:397–401.
 29. Wang TD, Friedland S, Sahbaie P, *et al.* Functional imaging of colonic mucosa with a fibered confocal microscope for real time in vivo pathology. *Clin Gastroenterol Hepatol* 2007; 5:1300–1305.
 30. Gorospe EC, Leggett CL, Sun G, *et al.* Diagnostic performance of two confocal endomicroscopy systems in detecting Barrett's dysplasia: a pilot study using a novel bioprobe in ex vivo tissue. *Gastrointest Endosc* 2012; 76:933–938.
 31. Hsu ER, Gillenwater AM, Hasan MQ, *et al.* Real-time detection of epidermal growth factor receptor expression in fresh oral cavity biopsies using a molecular-specific contrast agent. *Int J Cancer* 2006; 118:3062–3071.
 32. Goetz M, Ziebart A, Foersch S, *et al.* In vivo molecular imaging of colorectal cancer with confocal endomicroscopy by targeting epidermal growth factor receptor. *Gastroenterology* 2010; 138:435–446.
 33. Foersch S, Kiesslich R, Waldner MJ, *et al.* Molecular imaging of VEGF in gastrointestinal cancer in vivo using confocal laser endomicroscopy. *Gut* 2010; 59:1046–1055.
 34. Su P, Liu Y, Lin S, *et al.* Efficacy of confocal laser endomicroscopy for discriminating colorectal neoplasms from nonneoplasms: a systematic review and meta-analysis. *Colorectal Dis* 2012; 27:374–382.

35. Sonn GA, Jones SN, Tarin TV, *et al.* Optical biopsy of human bladder neoplasia with in vivo confocal laser endomicroscopy. *J Urol* 2009; 182:1299–1305.
36. Wu K, Liu JJ, Adams W, *et al.* Dynamic real-time microscopy of the urinary tract using confocal laser endomicroscopy. *Urology* 2011; 78:225–231.
37. Tan J, Quinn MA, Pyman JM, *et al.* Detection of cervical intraepithelial neoplasia in vivo using confocal endomicroscopy. *BJOG* 2009; 116:1663–1670.
38. Thong PS, Olivo M, Kho KW, *et al.* Laser confocal endomicroscopy as a novel technique for fluorescence diagnostic imaging of the oral cavity. *J Biomed Opt* 2007; 12:014007.
39. Maitland KC, Gillenwater AM, Williams MD, *et al.* In vivo imaging of oral neoplasia using a miniaturized fiber optic confocal reflectance microscope. *Oral Oncol* 2008; 44:1059–1066.
40. Haxel BR, Goetz M, Kiesslich R, Gosepath J. Confocal endomicroscopy: a novel application for imaging of oral and oropharyngeal mucosa in human. *Eur Arch Otorhinolaryngol* 2010; 267:443–448.
41. Pogorzelski B, Hanenkamp U, Goetz M, *et al.* Systematic intraoperative application of confocal endomicroscopy for early detection and resection of squamous cell carcinoma of the head and neck: a preliminary report. *Arch Otolaryngol Head Neck Surg* 2012; 138:404–411.
The first journal article to detail CLE descriptive characteristics and compare these with histologic findings in the UADT.
42. Just T, Stave J, Stachs O, *et al.* Rigid confocal endoscopy of the larynx. In: Wang C-C, editor. *Laser scanning, theory and applications*. Rijeka, Croatia: InTech; 2011. pp.97–112.
43. Farahati B, Stachs O, Prall F, *et al.* Rigid confocal endoscopy for in vivo imaging of experimental oral squamous intra-epithelial lesions. *J Oral Pathol Med* 2010; 39:318–327.
44. Thong PS, Tandjung SS, Movania MM, *et al.* Toward real-time virtual biopsy of oral lesions using confocal laser endomicroscopy interfaced with embedded computing. *J Biomed Opt* 2012; 17:056009.