

Magnetic Resonance Imaging–Guided Focused Ultrasound Treatment of Symptomatic Uterine Fibroids

Impact of Technology Advancement on Ablation Volumes in 115 Patients

Christoph G. Trumm, MD,* Robert Stahl, MD,* Dirk-André Clevert, MD,* Peter Herzog, MD,† Irene Mindjuk, MD,‡ Sabine Kornprobst,† Christina Schwarz,† Ralf-Thorsten Hoffmann, MD,‡ Maximilian F. Reiser, MD,* and Matthias Matzko, MD†

Objectives: The aim of this study was to assess the impact of the advanced technology of the new ExAblate 2100 system (Insightec Ltd, Haifa, Israel) for magnetic resonance imaging (MRI)–guided focused ultrasound surgery on treatment outcomes in patients with symptomatic uterine fibroids, as measured by the nonperfused volume ratio.

Materials and Methods: This is a retrospective analysis of 115 women (mean age, 42 years; range, 27–54 years) with symptomatic fibroids who consecutively underwent MRI-guided focused ultrasound treatment in a single center with the new generation ExAblate 2100 system from November 2010 to June 2011. Mean \pm SD total volume and number of treated fibroids (per patient) were 89 ± 94 cm³ and 2.2 ± 1.7 , respectively. Patient baseline characteristics were analyzed regarding their impact on the resulting nonperfused volume ratio.

Results: Magnetic resonance imaging–guided focused ultrasound treatment was technically successful in 115 of 123 patients (93.5%). In 8 patients, treatment was not possible because of bowel loops in the beam pathway that could not be mitigated ($n = 6$), patient movement ($n = 1$), and system malfunction ($n = 1$). Mean nonperfused volume ratio was $88\% \pm 15\%$ (range, 38%–100%). Mean applied energy level was 5400 ± 1200 J, and mean number of sonications was 74 ± 27 . No major complications occurred. Two cases of first-degree skin burn resolved within 1 week after the intervention. Of the baseline characteristics analyzed, only the planned treatment volume had a statistically significant impact on nonperfused volume ratio.

Conclusions: With technological advancement, the outcome of MRI-guided focused ultrasound treatment in terms of the nonperfused volume ratio can be enhanced with a high safety profile, markedly exceeding results reported in previous clinical trials.

Key Words: MRI-guided focused ultrasound, leiomyoma, uterine fibroid, ablation, nonperfused volume

(*Invest Radiol* 2013;48: 359–365)

Uterine leiomyomas (fibroids) represent a common benign myometrial tumor found in 25% to 77% of women of childbearing age.^{1,2} Symptoms occur in approximately 25% of the female population with fibroids, including menorrhagia, dysmenorrhea, bulk-

related symptoms such as pelvic pain and an increased urinary frequency, and infertility. Besides hysterectomy and myomectomy, minimally invasive surgical techniques such as hysteroscopic or laparoscopic myomectomy and uterine artery embolization have become available.³ However, postprocedural pain and fever are common with patients undergoing a recovery period of up to several weeks.⁴ Moreover, severe periprocedural complications have been observed.^{5,6}

Magnetic resonance imaging (MRI)–guided focused ultrasound (MRgFUS) surgery is a noninvasive thermal ablation technology for percutaneous high-intensity focused ultrasound tumor ablation under Magnetic Resonance Imaging Guidance and Thermal Monitoring.⁷ The MRgFUS device ExAblate 2000 (Insightec Ltd, Haifa, Israel) was approved by the US Food and Drug Administration (FDA) in 2004 for the treatment of symptomatic uterine fibroids. During MRgFUS treatment, a high-intensity focused ultrasound beam induces the selective, rapid heating of multiple sequential foci leading to thermocoagulation only within the targeted tumor tissue while neighboring structures along the beam path are preserved.⁸ The combination of the heat-generating focused ultrasound technology with a magnetic resonance (MR) system allows for the anatomically precise definition of a target volume, real-time thermal monitoring of the ablation process, and postprocedural evaluation of the treatment result.

In women with symptomatic uterine fibroids, the coagulative necrosis, followed by a gradual resorption, size reduction, and functional loss of the fibroid tissue, accounts for an effective relief of symptoms.^{9,10} Morphologically, the success of MRgFUS treatment can be assessed by calculating the nonperfused volume (NPV) ratio (ie, the posttreatment ratio of nonperfused fibroid volume divided by the pretreatment fibroid volume). It has been shown that a higher NPV ratio is correlated with a better reduction in fibroid-related symptoms and a reduced probability of further fibroid treatments.¹¹

Several anatomical and technical constraints have repeatedly been reported that impeded optimization of the NPV ratio in a significant ratio of patients¹²: Bowel loops are impassable by the focused ultrasound beam and may be interposed between the transducer and the fibroid, requiring particular mitigation techniques or precluding any treatment. Treating fibroids near the sacrum may be painful because of far-field heating of the neighboring sacral nerves.^{13,14} In case of patient movement, the entire treatment plan has to be adapted, increasing the overall patient time on the treatment table. Large fibroids require large sonication spot sizes to cover their volume and avoid 2 sonication layers. Fibroids with a high signal intensity (SI) in T2-weighted (T2w) MRI seem to be less susceptible to efficient MRgFUS treatment.^{15,16}

To overcome the above-mentioned limitations, several technical modifications and improvements have been implemented in the new generation ExAblate 2100 system. These include a transducer that can be elevated closer to the abdominal wall, allowing for reduced energy density in the near- and far-field; a decreased average

Received for publication May 15, 2012; and accepted for publication, after revision November 28, 2012.

From the *Department of Clinical Radiology, Klinikum der Ludwig-Maximilians-Universität München-Großhadern, München; †Department of Diagnostic and Interventional Radiology, Klinikum Dachau, Dachau; and ‡Department and Policlinics of Diagnostic Radiology, Universitätsklinikum Carl Gustav Carus Dresden, Dresden, Germany.

Conflicts of interest and sources of funding: none declared.

Reprints: Christoph G. Trumm, MD, Department of Clinical Radiology, Klinikum der Ludwig-Maximilians-Universität München-Großhadern, Marchioninistrasse 15, 81377 Munich, Germany. E-mail: christoph.trumm@med.lmu.de.

Copyright © 2013 by Lippincott Williams & Wilkins

ISSN: 0020-9996/13/4806-0359

focal distance; and an increased maximum energy level. Selective transducer elements are automatically disabled by the system in case risk structures are detected in the beam path. Together with an improved energy dispersion, the maximum sonication spot size has been enlarged to 70 mm to facilitate treatment of larger fibroid volumes. Moreover, a 3-dimensional treatment planning software optimizing the use of different spot sizes and energy levels has been introduced. In case patient movement is detected by the system during the treatment, the primary treatment plan can be directly transferred to the newly acquired T2w planning images.

Besides technological advances, mitigation techniques such as rectal filling with ultrasound gel, introducing inflatable balloons into the rectum, and bladder filling with sterile saline to push the uterus anteriorly and to minimize the presence of bowel loops along the beam path have been developed. In addition, patient management techniques were optimized to reduce the preparation time, patient pain, and movement.¹⁴

In this article, we report the NPV and safety results of, to the best of our knowledge, the first 115 patients who were treated with the new ExAblate 2100 system in a single center.

MATERIALS AND METHODS

Patients

This study includes all patients who completed MRgFUS treatment of symptomatic uterine fibroids using the ExAblate 2100 system (InSightec Ltd) from November 2010 to June 2011 in a single center. Because this study was a retrospective analysis, approval by the local ethical committee was not required. The principles of the Declaration of Helsinki were followed. Indication for MRgFUS treatment was regularly confirmed by a multidisciplinary team of interventional radiologists and gynecologists in accordance with selection criteria published elsewhere.^{13,14} Pregnant women and those with a contraindication to MRI were excluded. Women with the desire for future pregnancy were counseled with respect to the limited data for pregnancy after MRgFUS treatment.¹⁷ Relative exclusion criteria, according to the screening MRI examination, were extensive scars within the anterior abdominal wall, bowel interposed along the ultrasound beam pathway, and fibroids located near the sacral surface.

A total of 123 women with symptomatic uterine fibroids were consecutively admitted for MRgFUS treatment. All patients had undergone a screening MRI examination to determine the suitability and accessibility for MRgFUS treatment and to confirm the correlation with the patients' symptoms.

Table 1 shows the baseline characteristics of the patient cohort (n = 115) who completed treatment. In 45 patients, 1 symptomatic fibroid was treated; in 43 patients, 2 to 4 fibroids; and in 27 patients, 5 or more symptomatic fibroids. Table 2 shows the size distribution of the treated fibroids.

Treatment Device

The MRgFUS device operates in conjunction with a standard 1.5-T MRI system (General Electric HealthCare, Milwaukee, WI) for preprocedural and postprocedural image acquisition, as well as for intraprocedural image guidance with thermal MR images.¹⁸ In comparison with the ExAblate 2000 system, the second-generation ExAblate 2100 UF V2 system is characterized by the following technical properties:

- The transducer can be elevated closer to the abdominal wall (within a 4-cm distance from the patient skin). Together with a reduced thickness of the gel pad of 2.5 cm (previously 4 cm), the energy density on the patient skin and on the sacral nerves is reduced, making treatment near these sensitive regions feasible. As a consequence,

TABLE 1. Baseline Characteristics of the MRgFUS Treatment Group (n = 115)

Characteristic	
Age, y	42.4 ± 6.4
Body mass index, kg/m ²	23.5 ± 3.0
Menopausal status	
Premenopausal	110 (95.7)
Postmenopausal	5 (4.3)
Race	
White	109 (94.8)
Black	3 (2.6)
Asian	3 (2.6)
Number of fibroids	
1	45 (39.1)
2–4	43 (37.4)
≥5	27 (23.5)
Diameter of the largest fibroid, cm	5.4 ± 2.2
SI (T2w) of the largest fibroid*	
Type 1	84 (73)
Type 2	31 (27)
Fibroid structure (largest fibroid)	
Homogeneous	62 (53.9)
Heterogeneous	53 (46.1)
Contrast enhancement of the largest fibroid	
Lower than myometrium (type 1)	71 (61.7)
Comparable with myometrium (type 2)	44 (38.3)
Symptoms	
Pain	75 (65.2)
Bleeding	54 (47.0)
Bulk-related symptoms	44 (38.3)
Not specified	19 (16.5)

Data are presented as mean ± SD or n (%).

*According to Funaki et al.¹⁵

at the same time, the average focal distance has been reduced from 17 to 11.5 cm (Figs. 1A, B).

- In case the planned ultrasound beam path passes through risk structures such as bowels or pubic bone, selective transducer elements are automatically disabled by the system (Fig. 1C, D).
- Larger sonication spots (length up to 70 mm; previously 45 mm), combined with an improved energy dispersion, allow for the ablation of larger fibroid volumes within the same time frame. The 3-dimensional treatment planner optimizes the use of different spot sizes and energy levels within a drawn treatment volume (Fig. 1E)
- The maximum energy level of sonications has been increased to 7200 J.
- In case of patient movement during the treatment, the primary treatment plan (ie, drawing of the treatment volume and risk structures) can be transferred to the newly acquired T2w images to account for the changed anatomical situation.

MRgFUS Treatment

Informed consent was obtained from all patients 24 hours and directly before the MRgFUS intervention after extensive explanation of the method, its potential complications, and alternative treatments. On the treatment day, patients were prepared for the MRgFUS procedure as previously reported.^{9,11,19–21} After patient positioning on the treatment table, localizer images were acquired to verify uterine

TABLE 2. Size Distribution of the Treated Fibroids (n = 115 Patients)

Fibroid Volume, cm ³		Patients, n (%)
Range	Mean	
0–50	25	55 (47.8)
51–100	74	24 (20.9)
101–150	123	16 (13.9)
151–200	169	4 (3.5)
201–250	218	5 (4.3)
251–300	269	4 (3.5)
301–350	326	3 (2.6)
351–400	371	3 (2.6)
401–450	418	1 (0.9)

position and fibroid accessibility. If needed, mitigation techniques were implemented to modify the uterine position to remove bowel loops in the beam path. T2-weighted MR images were acquired in 3 planes for treatment planning. On all acquired images, the operating radiologist delineated the volume of the fibroids to be treated. Sensitive organs were also highlighted. Then, the system automatically created an optimized 3-dimensional treatment plan characterized by sonication spots of different sizes, angles, and transducer apertures to avoid transmission of the beam path through sensitive organs (Fig. 1). After performing a low-energy test sonication to verify system accuracy, therapeutic-level sonications were performed according to the treatment plan in an interleaved mode. This is a technique that

minimizes the time for skin cooling between sonications. During each sonication, gradient echo thermal images were obtained every 3.4 seconds, including a reference image before energy delivery subsequently followed by several images to verify the correct energy deposition within the targeted fibroid volume. The automatic sonication energy level of the used ExAblate 2100 system was routinely set to 120% (based on our clinical experience, this setting has been proven to be safe and efficient); that is, an increased energy level in relation to the system's preset energy level was used. In addition, the energy was optimized according to the fibroid characteristics (ie, fibroid SI on T2w images and contrast enhancement on T1w images), to achieve sufficient temperature rise. After treatment, all patients were given 7.5 mL of contrast agent (Gadovist 1.0; Bayer Schering Pharma AG, Berlin, Germany), and contrast-enhanced T1w fat-suppressed MR images were acquired to quantify the NPV ratio of all treated fibroids. Any adverse events (ie, skin burns, sciatica) occurring during or immediately after the treatment were documented in the final radiologic report.

Assessment of Technical Treatment Outcome

The success of MRgFUS treatment was determined based on the NPV ratio of the treated fibroids. The NPV ratio was measured using the NPV after treatment, as measured by the posttreatment T1-weighted contrast-enhanced MR images, divided by the treated fibroid volume, as measured by pretreatment T2w MR images. The respective volumes were calculated by manual slice-by-slice area measurements, multiplied by the slice thickness. Treatment was regarded successful if an overall NPV ratio of 60% or more was achieved. It has been shown that an NPV of more than 60% is




FIGURE 1. Technical properties of the system used. A and B, The transducer can be elevated to the abdominal wall within a 4-cm distance (arrows). Together with a reduced thickness of the gel pad, the near- and far-field energy density is reduced. C and D, Selective transducer elements are automatically disabled in case the ultrasound beam path (blue) passes through risk structures such as bowel (arrows) or pubic bone. Panel C shows the sagittal view, whereas panel D shows the coronal view of the beam path, with selectively disabled transducer elements being depicted as missing sector sections. E, 3-dimensional treatment planner: Longer sonication spots (up to 70 mm) combined with an improved energy dispersion allow for the ablation of larger fibroid volumes within the same time frame. Different spot sizes and energy levels are used within a drawn treatment volume.

correlated with a probability of less than 15% of undergoing additional treatments during the 24 months posttreatment.^{11,19,20}

Assessment of Clinical Treatment Outcome

Before treatment and at 6-month follow-up, patients were asked to voluntarily complete the 8-item section of the Uterine Fibroid Symptom and Quality-of-Life questionnaire to assess a symptoms severity score (SSS) with respect to fibroid-related symptoms. The follow-up questionnaires were collected by postal mail. The presence and intensity of both bleeding and bulk-related symptoms were assessed on a 5-point Likert scale (with responses in a range from 1 = not at all to 5 = a very great deal). The sum of the scores was transformed into a 0 to 100 scale for comparison, with 100 points representing a maximum symptom severity.¹¹

Statistical Analysis

For statistical analysis, IBM SPSS 20.0 for Windows (IBM Corp, Armonk, NY) was used. A level of significance of $\alpha = 0.05$ was used throughout the study.

Impact of Patient Baseline Characteristics on NPV Ratio

Several patient baseline characteristics were examined with respect to their relation with the resulting NPV ratio. For that, the following groups were formed and Student *t* tests were applied to assess differences in the NPV (in case of interval-scaled variables, the median value was chosen as limit):

- number of fibroids per patient (1 vs >1 fibroid)
- diameter of the largest fibroid (<5 vs ≥ 5 cm)
- T2w SI of the largest fibroid (low SI [type 1] vs intermediate SI [type 2])¹⁵
- homogeneity of the largest fibroid (homogeneous vs heterogeneous)
- contrast enhancement of the largest fibroid (lower than myometrium [type 1] vs comparable with myometrium [type 2])
- planned treatment volume (<50 vs ≥ 50 cm³)
- applied energy (<5500 vs ≥ 5500 J)
- presence of bowel loops (with vs without use of mitigation techniques)

Clinical Treatment Outcome

Data were initially assessed for normality with the Kolmogorov-Smirnov test. On the basis of these results, we decided to use a nonparametric procedure to compare the change in the transformed SSSs. Therefore, the Wilcoxon signed-rank test was applied.

RESULTS

In a cohort of 123 women with symptomatic uterine fibroids treated consecutively, MRgFUS treatment was successfully completed in 115 patients (93.5%) (Figs. 2 and 3). In 8 patients (6.5%), treatment was not possible because of the following reasons: 6 patients presented with bowel in the beam pathway that could not be mitigated by modification of the transducer or patient positioning (using both bladder filling with saline and rectal filling with ultrasound gel, respectively). In 1 patient, the procedure had to be aborted because of continuous patient movement despite conscious sedation. In another patient, the treatment was not completed because of a system malfunction.

Of the 115 treated patients, rectal filling with ultrasound gel was applied in 64 (55.7%) patients and temporary filling of the bladder using sterile saline was applied before treatment in 51 (44.3%) patients. A total of 48 patients (41.7%) received a combination of both. Rectal filling and bladder filling were performed only for the purpose of removing bowel loops in front of the uterus. In case the initial injection and reaspiration of sterile saline into the bladder was not sufficient to move the bowel loops out of the beam pathway, an additional rectal filling was administered to move the uterus anteriorly. Only if the combination of temporary bladder filling and rectal filling failed to remove the interposed bowel loops was an intraprocedural bladder filling used to create an acoustic treatment window.

Eleven patients (9.6%) presented with scars of the abdominal wall that were mitigated using a scar patch or through tilting of the transducer.²²

On average, 74 ± 27 sonications (range, 20–146) were performed per treatment. Mean sonication time (ie, time from first to last sonication) and overall procedure time (including patient positioning and imaging) were 3.3 ± 1.2 hours (range, 1.1–6.6 hours) and 4.1 ± 1.1 hours (range, 1.7–6.8 hours), respectively. Mean applied energy

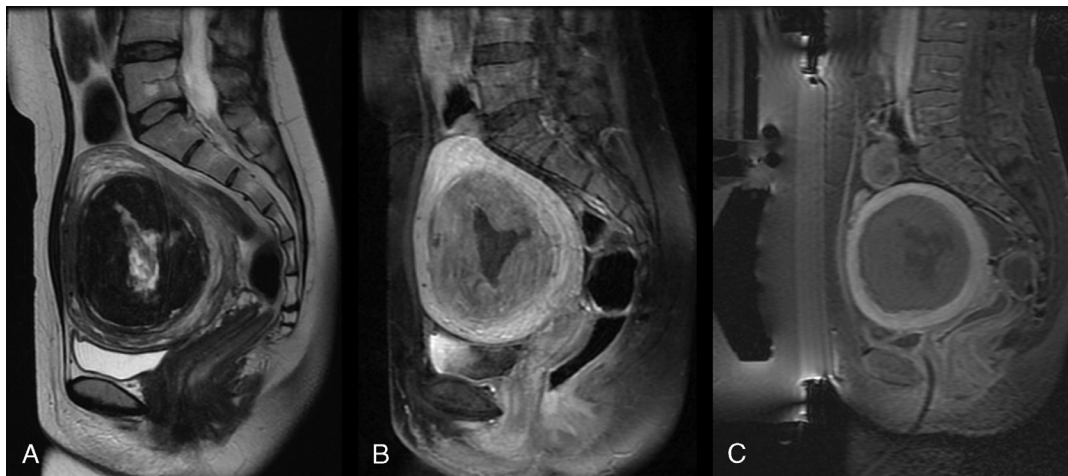


FIGURE 2. A 45-year-old woman with a 418-cm³ fibroid experiencing gradually worsening pelvic pressure and hypermenorrhea. A, Sagittal T2w MR image obtained before treatment shows predominantly hypointense fibroid (type 1) with hyaline degeneration of the central area. B, Sagittal contrast-enhanced fat-suppressed MR image before treatment shows homogeneous enhancement of vital fibroid tissue. C, Sagittal contrast-enhanced fat-suppressed MR image acquired immediately after treatment shows a completely nonperfused fibroid tissue.

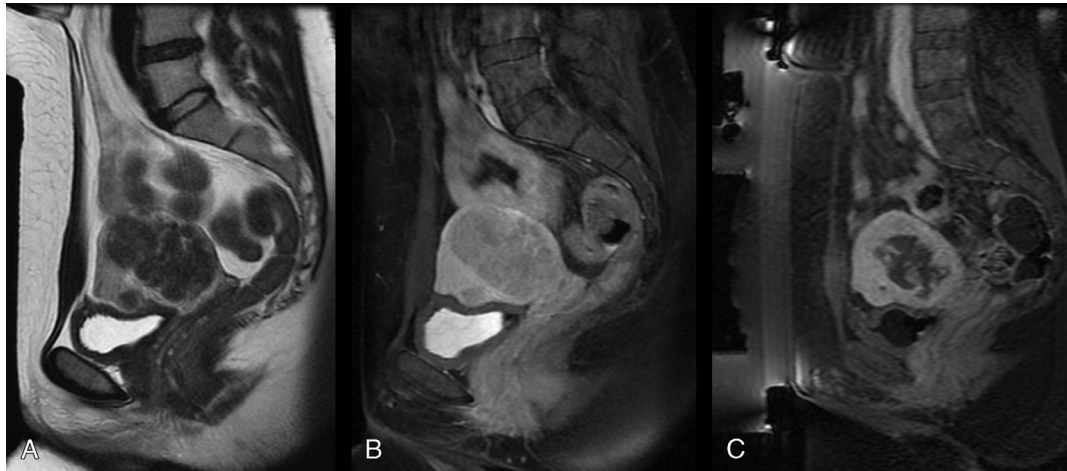


FIGURE 3. A 34-year-old woman with 75 cm³ of fibroid tissue experiencing hypermenorrhea. A, Sagittal T2w MR image obtained before treatment shows several hypointense intramural fibroids. B, Sagittal contrast-enhanced fat-suppressed MR image before treatment shows a strong enhancement of the vital fibroid tissue. C, Sagittal contrast-enhanced fat-suppressed MR image acquired after treatment. Because of strong vascularity of fibroid tissue and intramyomal septations, an NPV ratio of only 51% was achieved.

level was 5400 ± 1200 J (range, 2500–7400 J). Mean energy level in fibroids with a low T2w SI (type 1) was 5400 ± 1200 J (range, 2500–7400 J) and in fibroids with an intermediate T2w SI (type 2) was 5600 ± 1000 J (range, 3600–7100 J).

The mean total NPV ratio was 88% ± 15% (range, 38%–100%) (Table 3). Ninety percent of the treated patients (n = 103) showed an NPV of more than 60%.

The statistical analysis of the influence of patient baseline characteristics on the NPV results was significant only for the planned fibroid volume ($P = 0.037$), with better NPV results in fibroid volumes smaller than 50 cm³. Regarding the remaining baseline characteristics (number of fibroids, diameter of largest fibroid [Fig. 2], T2w SI of the largest fibroid, contrast enhancement of the largest fibroid [Fig. 2], homogeneity of the largest fibroid [Fig. 3], applied energy, and presence of intestine loops that could be mitigated), no significant difference was observed (Table 4).

Adverse Events

There were no serious adverse events observed during or after the treatments. Two treatments resulted in first-degree skin burns. One patient with a fibroid characterized by an intermediate T2w SI and an elevated contrast enhancement showed a skin erythema and a small blister. The applied maximum energy level in this patient was 4600 J, which is well below the maximum energy level of 7100 J in the corresponding subset of treated type 2 fibroids. The other patient had a history of a previous cesarean section and had undergone treatment with a scar patch. In this patient, the applied maximum energy level was 6500 J, leading to a skin burn at the edges of the patch. Both skin burns resolved without any interventions until the 1-week follow-up visit. There were no other procedure-related adverse events or complications.

Clinical Treatment Outcome

After a mean follow-up period of 6.5 months, the SSS (median value [25th percentile, 75th percentile]) of the 72 patients (62.6%) who voluntarily sent back the questionnaire decreased significantly ($P < 0.0001$) from 62.5 (37.5, 72.5) to 37.5 (25.0, 44.375).

DISCUSSION

To the best of our knowledge, this retrospective single-center study presents the results of MRgFUS surgery of symptomatic

uterine fibroids performed in the first larger clinical series of 115 patients using the second-generation ExAblate 2100 system. In comparison with its predecessor ExAblate 2000, in the new system, several major technical modifications have been implemented to compensate for both technical and anatomical limitations previously restricting suitability and accessibility of symptomatic uterine fibroids. In particular, these new technical features comprise a transducer that can be moved closer (ie, up to 4 cm) to the abdominal wall, reducing energy density on the patient skin and on the sacral nerves. The selective disabling of transducer elements facilitates sonications close to sensitive structures such as bowel loops delineated in the treatment plan. The maximum sonication spot size has been increased from 45 to 70 mm to allow for the treatment of larger fibroid volumes within the same time frame. Whereas in the first-generation system, the primary treatment plan was characterized by standard sonication spots regarding size and energy level (often requiring a manual optimization of each sonication by the operator), the 3-dimensional treatment planning software automatically fills out the delineated volume of treatment with different sonication spot sizes and energy levels, which accelerates the approval of the individual sonications by the operator and helps to reduce the total treatment time. The transfer of the primary treatment plan onto the newly acquired T2w planning images in case of patient movement contributes to further decrease the total procedure time. Although the new MRgFUS system allows for an increased maximum sonication energy of 7200 J, only 2 minor skin burns were observed in our patient cohort.

With increasing experience and the implementation of new techniques and technologies, the NPV ratio measured immediately

TABLE 3. Distribution of NPV Ratio of Fibroids Immediately After Treatment (n = 115 Patients)

NPV Ratio, %		Patients, n (%)
Range	Mean	
0–25	0	0 (0)
26–50	45.8	6 (5.2)
51–75	66.5	18 (15.5)
76–100	94.3	91 (79.4)

TABLE 4. Impact of Baseline Characteristics on NPV Ratio

Characteristic	P*
Presence of intestine loops that could be mitigated (with vs without use of mitigation techniques)	0.999
Homogeneity of largest fibroid (homogeneous vs heterogeneous)	0.940
Number of fibroids per patient (1 vs >1 fibroid)	0.793
Applied energy (<5500 vs ≥5500 J)	0.629
T2w SI of the largest fibroid (type 1 vs type 2)†	0.224
Contrast enhancement of the largest fibroid (type 1 vs type 2)‡	0.056
Diameter of the largest fibroid (<5 vs ≥5 cm)	0.051
Planned treatment volume (<50 vs ≥50 cm ³)	0.037

*A level of significance of $\alpha = 0.05$ was used.

†Type 1, low T2w SI (comparable with that of skeletal muscle); type 2, intermediate T2w SI (lower than myometrium, but higher than skeletal muscle).¹⁵

‡Type 1, contrast enhancement lower than myometrium; type 2, contrast enhancement comparable with myometrium.

after MRgFUS treatment has increased.²⁰ This NPV ratio has been shown to be a predictor of both fibroid volume and symptom reduction,^{11,23} which suggests a strong correlation between the success of MRgFUS treatment and devascularization, as has been suggested in uterine fibroid embolization.²⁴

Early clinical studies conducted before FDA approval of the first-generation ExAblate 2000 system were limited by several restrictive safety measures to minimize the likelihood of adverse events. These included a restriction of treatment volume (to 100 cm³ and 33% of the total fibroid volume, respectively) and a limitation of treatment duration to a total table time of 3 hours.^{9,11} Stewart et al¹¹ reported that 57% of the patients treated under these restricted guidelines had an NPV ratio of 20% or less, and fewer than 3% of the patients had an NPV ratio of 70% or more.

The growing experience with MRgFUS treatment along with the implementation of the less restrictive modified FDA commercial treatment guidelines facilitated improved clinical results while maintaining a high safety profile of the technique.^{19,25,26}

In their cohort of 80 patients, applying more relaxed treatment guidelines, LeBlang et al²⁵ achieved a mean NPV ratio of 55%. For all groups of fibroids, independent of size, it was possible to obtain an NPV ratio of at least 50%, whereas larger NPV ratios of more than 60% were predominantly seen after treatment of smaller fibroid volumes (ie, <100 cm³). The authors reported 2 cases of first-degree skin burns and 1 case of mild sciatica.

Morita et al²⁶ retrospectively analyzed 83 patients to determine the safety of treating closer to the serosal surface and thereby increasing the treatment volume. Measuring the distance between the treatment spots and the serosa, they found that 79% and 37% of the sonications were located less than 15 and 10 mm from the serosal surface, respectively. During a 1-year follow-up period, the authors observed no unexpected or serious adverse events.

In our institution, we applied a minimum spot distance of 5 mm from the serosal surface, which provided an expanded treatment volume with no concurrent serious adverse events observed. As Morita et al²⁶ stressed, the distance between the sonication spot and the serosa should be determined on a case-by-case basis (eg, in case of fibroids close to the serosal surface) by careful assessment of neighboring sensitive structures such as bowel in the pretreatment MR images. In our experience, potential damage can be circumvented by using small or tilted spots and by paying special attention to the spot location using the real-time temperature maps and the anatomical images to verify that no patient movement has occurred.

The recent work by Okada et al²⁰ has underlined the impact of the learning curve on the technical outcome and complication rates of MRgFUS over time. Their retrospective evaluation included 287 patients who underwent treatment of uterine fibroids with ExAblate 2000 in 4 different Japanese institutions over a 4-year period. The authors found a significant ($P < 0.001$) increase in the NPV ratio from 39.3% (first 2-year period) to 54.0% (second 2-year period) and a significant reduction in the proportion of patients who underwent alternative treatments at 1-year follow-up (9% vs 4.2%). Furthermore, the skin burn profile markedly improved, with a 5-fold frequency of skin burns (n = 10) observed in the first period. These results correspond to our observations, as NPV results have also markedly improved in our institution with increased operator experience.

Technical modifications of the ExAblate 2000 device already improved treatment outcomes through the introduction of reduced intersonication cooling times for sonications located a large distance apart, as well as enlarged focal regions through enhanced beam steering during sonication.²³ The 3-dimensional planning software introduced with the second-generation ExAblate 2100 system, used in our study, automatically generates a plan that enhances the NPV, through the use of angled ultrasound beam targeting, optimization of the spot energy and distribution, adequate packing of the planned sonications, and ablation of all accessible fibroid regions.²⁰

However, there are still various patient- and fibroid-related factors that may negatively influence the eligibility and accessibility of patients, and affect the technical outcome of the MRgFUS procedure, or require particular mitigation techniques before treatment.^{14,27} As Funaki et al¹⁵ showed, the efficacy of MRgFUS correlates with the fibroid SI on T2w MR images, suggesting an increased fibroid vascularity.²⁸ In type 1 (low T2 SI) and 2 (intermediate T2 SI) fibroids, the technically achievable NPV ratio is comparable. However, type 3 (high T2 SI) fibroids are characterized by a significantly lower NPV ratio,¹⁶ a higher necessary level of mean acoustic power,²³ and a higher reintervention rate.^{29,30}

In our patient cohort, we observed a markedly increased mean NPV ratio compared with previously reported results,^{11,20,25,29} with a high safety profile. Baseline characteristics that had been considered as limiting factors of MRgFUS treatments, such as large number of fibroids, fibroids with high T2w SI or heterogeneous fibroids, as well as bowels lying in the ultrasound beam pathway, had no statistically significant impact on the NPV results achieved.³¹ Moreover, in more than half of the cases, mitigation techniques that have been developed due to the experience collected in our hospital facilitated treatment of patients not amenable to MRgFUS according to previously reported criteria.³¹

Together with both the experience accumulated with the first-generation MRgFUS system, ExAblate 2000, particularly regarding the routine use of mitigation techniques, and a strict selection of suitable patients, the combined technical improvements of the new ExAblate 2100 system have markedly contributed to achieve the improved results presented in this study. The larger spot types with an improved energy dispersion profile have turned out to be particularly advantageous in cases with large fibroid volume ablations. The dedicated treatment planning schemes for fibroids with different signal intensities allow for the effective treatment of “bright” fibroids. Moving the transducer closer to the patient enables a higher energy density in the focus and, thus, an improved ablation. Selectively shutting down transducer elements facilitates treatments close to sensitive regions such as bowel loops.

Limitations

There are a few limitations that have to be underlined.

The current study presents only the immediate results of MRgFUS treatment conducted with the ExAblate 2100 system in

terms of the posttreatment NPV ratio of the treated fibroids as well as regarding adverse events observed after the procedure. On the basis of these initial results, we expect that symptom relief will be highly effective and durable. However, it is important to examine the clinical long-term effect of the high NPV ratios observed in our patient cohort.^{11,29,32}

Although to date (ie, May 2012), 8 of the 115 patients have undergone a secondary MRgFUS treatment in our institution because of recurrence of fibroid-related symptoms (corresponding to a 7% MRgFUS reintervention rate), we did not perform a dedicated evaluation regarding the incidence of alternative surgical or minimally invasive catheter-based treatments. The individual reasons for the secondary MRgFUS treatments of the above-mentioned patients were an incomplete primary ablation due to a location of the treated fibroids in the posterior uterine wall near the sacrum ($n = 3$) or due to a subserosal location ($n = 3$), a treatment of a small remaining fibroid in a woman without clinical symptoms who wanted to get pregnant ($n = 1$), and a planned secondary MRgFUS procedure in a patient who had presented with a primarily inaccessible fibroid ($n = 1$).

CONCLUSIONS

This retrospective single-center analysis of, to our best knowledge, the largest patient series treated with the ExAblate 2100 system to date shows that the outcome of MRgFUS treatment in terms of the NPV ratio can be enhanced with a high safety profile, markedly exceeding results reported in previous clinical trials. As relief of fibroid-related symptoms is directly correlated with the NPV ratio, the results achieved in our patient cohort are encouraging and warrant further follow-up studies.

REFERENCES

- Buttram VC Jr, Reiter RC. Uterine leiomyomata: etiology, symptomatology, and management. *Fertil Steril*. 1981;36:433–445.
- Cramer SF, Patel A. The frequency of uterine leiomyomas. *Am J Clin Pathol*. 1990;94:435–438.
- van der Kooij SM, Ankum WM, Hehenkamp WJ. Review of nonsurgical/minimally invasive treatments for uterine fibroids. *Curr Opin Obstet Gynecol*. 2012;24:368–375.
- Pron G, MocarSKI E, Bennett J, et al. Tolerance, hospital stay, and recovery after uterine artery embolization for fibroids: the Ontario Uterine Fibroid Embolization Trial. *J Vasc Interv Radiol*. 2003;14:1243–1250.
- Lemyre M, Bujold E, Lathi R, et al. Comparison of morbidity associated with laparoscopic myomectomy and hysterectomy for the treatment of uterine leiomyomas. *J Obstet Gynaecol Can*. 2012;34:57–62.
- Schirf BE, Vogelzang RL, Chrisman HB. Complications of uterine fibroid embolization. *Semin Intervent Radiol*. 2006;23:143–149.
- Hesley GK, Gorny KR, Woodrum DA. MR-guided focused ultrasound for the treatment of uterine fibroids. *Cardiovasc Intervent Radiol*. 2012. [Epub ahead of print].
- Hesley GK, Gorny KR, Henrichsen TL, et al. A clinical review of focused ultrasound ablation with magnetic resonance guidance: an option for treating uterine fibroids. *Ultrasound Q*. 2008;24:131–139.
- Hindley J, Gedroyc WM, Regan L, et al. MRI guidance of focused ultrasound therapy of uterine fibroids: early results. *AJR Am J Roentgenol*. 2004;183:1713–1719.
- Tempany CM, Stewart EA, McDannold N, et al. MR imaging-guided focused ultrasound surgery of uterine leiomyomas: a feasibility study. *Radiology*. 2003;226:897–905.
- Stewart EA, Gostout B, Rabinovici J, et al. Sustained relief of leiomyoma symptoms by using focused ultrasound surgery. *Obstet Gynecol*. 2007;110(2 pt 1):279–287.
- Arleo EK, Khilnani NM, Ng A, et al. Features influencing patient selection for fibroid treatment with magnetic resonance-guided focused ultrasound. *J Vasc Interv Radiol*. 2007;18:681–685.
- Yoon SW, Lee C, Cha SH, et al. Patient selection guidelines in MR-guided focused ultrasound surgery of uterine fibroids: a pictorial guide to relevant findings in screening pelvic MRI. *Eur Radiol*. 2008;18:2997–3006.
- Zaher S, Gedroyc WM, Regan L. Patient suitability for magnetic resonance guided focused ultrasound surgery of uterine fibroids. *Eur J Obstet Gynecol Reprod Biol*. 2009;143:98–102.
- Funaki K, Fukunishi H, Funaki T, et al. Magnetic resonance-guided focused ultrasound surgery for uterine fibroids: relationship between the therapeutic effects and signal intensity of preexisting T2-weighted magnetic resonance images. *Am J Obstet Gynecol*. 2007;196:184.e1–184.e6.
- Machtinger R, Inbar Y, Cohen-Eylon S, et al. MR-guided focus ultrasound (MRgFUS) for symptomatic uterine fibroids: predictors of treatment success. *Hum Reprod*. 2012;3425–3431.
- Rabinovici J, David M, Fukunishi H, et al. Pregnancy outcome after magnetic resonance-guided focused ultrasound surgery (MRgFUS) for conservative treatment of uterine fibroids. *Fertil Steril*. 2010;93:199–209.
- McDannold N, Tempany CM, Fennessy FM, et al. Uterine leiomyomas: MR imaging-based thermometry and thermal dosimetry during focused ultrasound thermal ablation. *Radiology*. 2006;240:263–272.
- Fennessy FM, Tempany CM, McDannold NJ, et al. Uterine leiomyomas: MR imaging-guided focused ultrasound surgery—results of different treatment protocols. *Radiology*. 2007;243:885–893.
- Okada A, Morita Y, Fukunishi H, et al. Non-invasive magnetic resonance-guided focused ultrasound treatment of uterine fibroids in a large Japanese population: impact of the learning curve on patient outcome. *Ultrasound Obstet Gynecol*. 2009;34:579–583.
- Tempany CM. From the RSNA refresher courses: image-guided thermal therapy of uterine fibroids. *Radiographics*. 2007;27:1819–1826.
- Yoon SW, Seong SJ, Jung SG, et al. Mitigation of abdominal scars during MR-guided focused ultrasound treatment of uterine leiomyomas with the use of an energy-blocking scar patch. *J Vasc Interv Radiol*. 2011;22:1747–1750.
- Lenard ZM, McDannold NJ, Fennessy FM, et al. Uterine leiomyomas: MR imaging-guided focused ultrasound surgery—imaging predictors of success. *Radiology*. 2008;249:187–194.
- Pelage JP, Guaou NG, Jha RC, et al. Uterine fibroid tumors: long-term MR imaging outcome after embolization. *Radiology*. 2004;230:803–809.
- LeBlang SD, Hoctor K, Steinberg FL. Leiomyoma shrinkage after MRI-guided focused ultrasound treatment: report of 80 patients. *AJR Am J Roentgenol*. 2010;194:274–280.
- Morita Y, Takeuchi S, Hikida H, et al. Decreasing margins to the uterine serosa as a method for increasing the volume of fibroids ablated with magnetic resonance-guided focused ultrasound surgery. *Eur J Obstet Gynecol Reprod Biol*. 2009;146:92–95.
- Behera MA, Leong M, Johnson L, et al. Eligibility and accessibility of magnetic resonance-guided focused ultrasound (MRgFUS) for the treatment of uterine leiomyomas. *Fertil Steril*. 2010;94:1864–1868.
- Kim YS, Lim HK, Kim JH, et al. Dynamic contrast-enhanced magnetic resonance imaging predicts immediate therapeutic response of magnetic resonance-guided high-intensity focused ultrasound ablation of symptomatic uterine fibroids. *Invest Radiol*. 2011;46:639–647.
- Funaki K, Fukunishi H, Sawada K. Clinical outcomes of magnetic resonance-guided focused ultrasound surgery for uterine myomas: 24-month follow-up. *Ultrasound Obstet Gynecol*. 2009;34:584–589.
- Funaki K, Sawada K, Maeda F, et al. Subjective effect of magnetic resonance-guided focused ultrasound surgery for uterine fibroids. *J Obstet Gynaecol Res*. 2007;33:834–839.
- Taran FA, Hesley GK, Gorny KR, et al. What factors currently limit magnetic resonance-guided focused ultrasound of leiomyomas? A survey conducted at the first international symposium devoted to clinical magnetic resonance-guided focused ultrasound. *Fertil Steril*. 2010;94:331–334.
- Kim HS, Baik JH, Pham LD, et al. MR-guided high-intensity focused ultrasound treatment for symptomatic uterine leiomyomata: long-term outcomes. *Acad Radiol*. 2011;18:970–976.