

DIAGNOSIS OF VENOUS INCOMPETENCE IN ERECTILE DYSFUNCTION

Comparative Study of Cavernosography and Doppler Ultrasound

H. GALL, M.D.

C. H. SPARWASSER, M.D.

C. G. STIEF, M.D.

W. BÄHREN, M.D.

W. SCHERB, M.D.

G. HOLZKI, M.D.

From the Departments of Dermatology, Urology, Radiology, and Neurology, BWK, Academic Hospital of the University, Ulm, F.R. Germany

ABSTRACT—In 26 of 214 patients with erectile dysfunction and proved venous incompetence by cavernosography, an additional bidirectional Doppler ultrasound was performed also to demonstrate venous outflow disturbances. All except one leakage in the superficial and deep dorsal veins could be demonstrated as well as 4 of 6 cavernosum-glandular shunts. Bidirectional Doppler ultrasound visualized a continuous retrograde blood flow from the sulcus coronarius to the root of the penis in superficial and deep dorsal penile veins as well as in ectopic penile veins, an orthograde blood flow in the sulcus coronarius in cavernosum-glandular shunt.

An erection is hemodynamically based on dilatation of the arteries, relaxation of cavernosal sinusoids, and reduction of venous outflow.¹⁻³ Venous insufficiency of the corpora cavernosa is the second most common cause of erectile dysfunction after arterial inflow disturbances.⁴ To diagnose inflow disturbances, Doppler examination of the penile arteries is performed in association with the injection of vasoactive substances.⁵ The test with intracavernous injection of vasoactive drugs (IIVD) has proved effective in the recognition of venous insufficiency.⁶ With cavernosometry induction and maintenance flow can be assessed, cavernosography visualizes the venous leakage.^{7,8} First hints that Doppler examination can be used to identify a venous leakage are to be found in the literature.⁹

Material and Methods

In 1986 and 1987, suspected venous insufficiency was diagnosed on the basis of a negative IIVD test (with 2 mL solution = 30 mg papaverine + 1 mg phentolamine) in 214 patients

following multidisciplinary evaluation of erectile dysfunction. For verification, dynamic cavernosography or pharmaco-cavernosography was performed. In artificial erection the corpus cavernosum was perfused with a non-ionic contrast medium (Ultravist 300) and the venous outflow displayed in two projections (anteroposterior and half-sided image).

In 26 of 214 patients examined by means of cavernosography, an additional Doppler ultrasound was performed to demonstrate venous outflow disturbances (Doppler flowmeter 762 by Kranzbühler). The Doppler flow pattern was visually displayed and documented on graph paper. Doppler examination was performed after maximal stimulation of arterial inflow with intracavernous injection of 2 mL solution of the vasoactive drugs. Routinely we searched for a pathologic retrograde blood flow over the dorsal penile veins and for cavernosum-glandular shunts (orthograde blood flow). The penile anatomy does not allow Doppler localization of the vena profunda sive cavernosa.

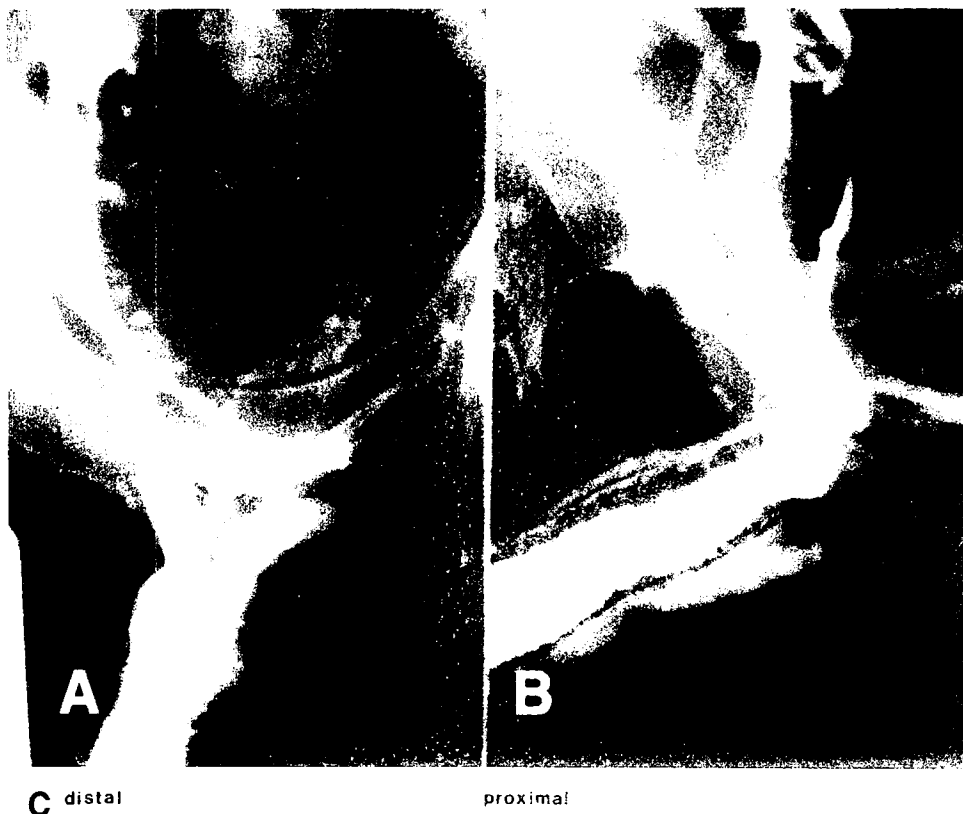


FIGURE 1. Course of deep dorsal penile vein (A and B) cavernosography, and (C) Doppler ultrasound.

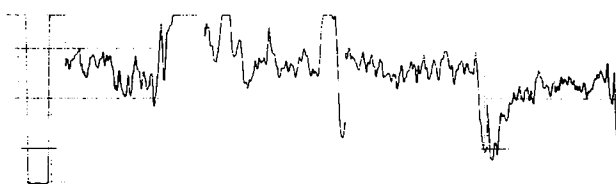


FIGURE 2. Localization of deep dorsal penile vein by means of Doppler ultrasound.

Results

In 26 patients, cavernosography detected pathologic drainage over the deep dorsal penile vein in 18 cases to the vesicoprostatic plexus and vena pudenda interna (isolated 13 times, 5 times in combination with a cavernosum-glandular shunt); 7 times isolated over the superficial venous system (ectopic penile vein and superficial dorsal penile vein) to the vena femoralis, and once a cavernosum-glandular shunt following a priapism operation. All except one of the outflow disturbances in the 25 dorsal veins could be visualized with Doppler examination; definite topographic classification was possible for all deep dorsal veins and for 5 veins of the superficial venous system. Doppler examination was successfully used to identify a

cavernosum-glandular shunt on 4 occasions (Table I). Doppler examination visualizes pathologic drainage over the dorsal penile veins in the dorsum penis. Retrograde blood flow in the deep dorsal penile veins often can be detected over a considerable length: it begins in the distal region near the sulcus coronarius and passes at increasing speed to the root of the penis (Fig. 1).

TABLE I. Identification of pathologic venous outflow

Venous Outflow	Cavernosography	Doppler Examination
Deep dorsal penile vein	18	17
Superficial venous system (ectopic penile vein or superficial dorsal penile vein)	7	7 dorsal veins (topographic classification was possible in 5 cases)
Cavernosum-glandular shunt	6	4

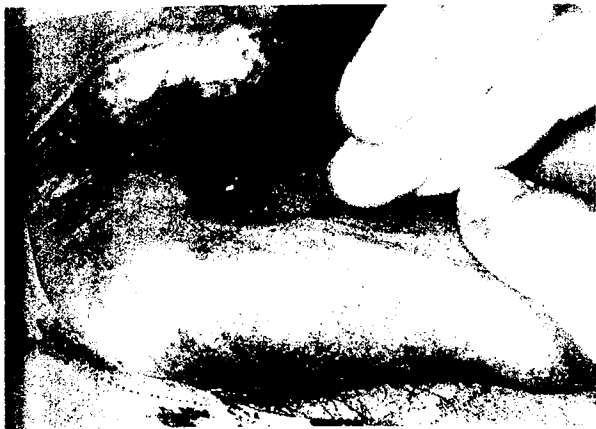

FIGURE 3. Clinical illustration of superficial dorsal penile vein.



A




FIGURE 4. Course of superficial dorsal penile vein: (A) cavernosography, and (B) Doppler ultrasound.

By means of Doppler ultrasound, the deep penile vein can be proved between the right and left arteria dorsalis penis (Fig. 2). While the deep dorsal penile vein can be localized only acoustically, the superficial venous system is visible. Ectopic penile veins and the superficial dorsal penile vein appear through the skin as subcutaneous veins. The superficial dorsal penile vein originates at the sulcus coronarius and continues paramedially to the dorsal root of the penis (Fig. 3). Doppler examination detected retrograde blood flow in afferent branches and in the main trunk from distal to proximal (Fig. 4). The ectopic penile veins in the



A

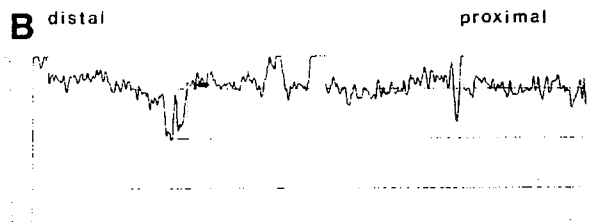

FIGURE 5. Course of ectopic penile vein on right side: (A) cavernosography, and (B) Doppler ultrasound.



A

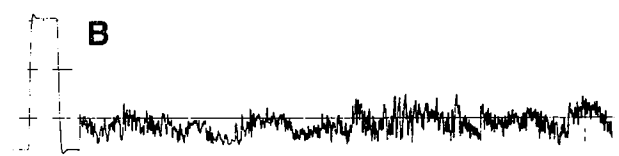

FIGURE 6. Cavernosum-glandular shunt: (A) cavernosography: contrast medium depicts corpus cavernosum and corpus spongiosum (glans penis), and (B) Doppler ultrasound: orthograde blood flow at sulcus coronarius.

dorsum penis lateral to the dorsal artery could also be visualized. The retrograde blood flow also passed from distal to proximal to the root of the penis (Fig. 5).

In 3 cases the course of the visible superficial dorsal vein was marked with a colored pen and

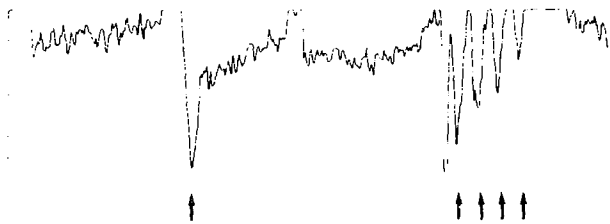


FIGURE 7. Doppler ultrasound reveals increased venous flow rate during contraction of bulbocavernosus and ischiocavernosus muscles (arrows).

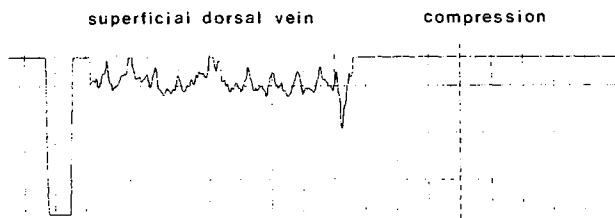


FIGURE 8. Doppler ultrasound: stop of blood flow by compression of superficial dorsal penile vein.

the vein was then ligated under local anesthesia.⁹ A shunt between corpus cavernosum and corpus spongiosum mainly occurred in association with dorsal vein insufficiency. An example of an isolated shunt is depicted in the iatrogenic communication of corpus cavernosum and glans penis in priapism operation by Winter-Ebbehøj. In this case Doppler examination identified orthograde blood flow at the sulcus coronarius. Orthograde blood flow passed from the corpus cavernosum to the glans penis (= cavernosum-glandular shunt, Fig. 6).

Pathologic venous outflow was detected within a few seconds after injection of IIVD-solution and continually traced for over thirty minutes. Venous flow speed ranged from approximately 3 cm/sec to 6 cm/sec. Contraction of the bulbocavernosus and ischiocavernosus muscles caused a rise in intracavernosal pressure with a consecutively increased flow rate via the pathologic venous drainage (Fig. 7). Interruption of the venous outflow (Fig. 8), on the other hand, was achieved with manual compression of the visible subcutaneous veins or compression of all dorsal veins by applying a Sachse band (Fig. 9) to the root of the penis. In 5 patients with a leakage, intracavernosal pressure was measured during cavernosography. Values of only 7–12 cm of water were obtained, compared with 80 cm H₂O and above in potent men with full rigidity. These low-pressure values proved the decreased venous outflow resistance, which might be due to a complex



FIGURE 9. Applying Sachse band to root of penis.

cavernosal insufficiency. Cavernosography then only shows the secondarily involved outflow.

Conclusion

This was the first time that we performed specific Doppler examinations to identify pathologic venous drainage. The results were assessed using the valid invasive reference method of cavernosography. With one exception, Doppler examination showed retrograde venous outflow over the dorsal veins. Topographic classification to the deep dorsal penile vein or visible superficial venous system (ectopic penile veins and superficial dorsal penile veins) was possible in most cases. In individual cases the labeled superficial dorsal vein was ligated under local anesthesia. An orthograde cavernosum-glandular shunt was detected at the sulcus coronarius. Doppler ultrasound is generally well suited as a noninvasive method of identifying pathologic venous outflow disturbances.

Abteilung für Dermatologie
BWK, Oberer Eselsberg 40
D-7900 Ulm, F.R. Germany
(DR. GALL)

References

1. Lue TF, et al: Hemodynamics of canine corpora cavernosa during erection, *Urology* 24: 347 (1984).
2. Juenemann KP, Lue TF, Fournier GR, and Tanagho EA: Hemodynamics of papaverin- and phentolamin-induced erections, *J Urol* 136: 158 (1986).
3. Fournier GR, Juenemann KP, Lue TF, and Tanagho EA: Mechanisms of venous occlusion during canine penile erection, *J Urol* 137: 163 (1987).
4. Virag R: Angiogenic impotence, *Inter Angio* 3: 217 (1984).
5. Zorogniotti AW, and LeFleur RS: Autoinjection of the corpus cavernosum with a vasoactive drug combination for vasculogenic impotence, *J Urol* 133: 39 (1985).
6. Stief CG, Bühren W, Gall H, and Scherb W: Functional evaluation of penile hemodynamics, *J Urol* 139: 734 (1988).
7. Wespes E, and Schulman CC: Parameters of erection, *Br J Urol* 56: 416 (1984).
8. Lue TF, Hricak K, Schmidt RA, and Tanagho EA: Functional evaluation of penile veins by cavernosography in papaverine-induced erection, *J Urol* 135: 479 (1986).
9. Stief CG, Gall H, Scherb W, and Bühren W: Erectile dysfunction due to an ectopic penile vein, *Urology* 31: 300 (1988).