

1989

Prospect Hill: Skeletal Remains from a 19th-Century Methodist Cemetery, Newmarket, Ontario

S. Pfeiffer

J. C. Dudar

S. Austin

Follow this and additional works at: <http://orb.binghamton.edu/neha>



Part of the [Archaeological Anthropology Commons](#)

Recommended Citation

Pfeiffer, S.; Dudar, J. C.; and Austin, S. (1989) "Prospect Hill: Skeletal Remains from a 19th-Century Methodist Cemetery, Newmarket, Ontario," *Northeast Historical Archaeology*: Vol. 18 18, Article 4.
<https://doi.org/10.22191/neha/vol18/iss1/4> Available at: <http://orb.binghamton.edu/neha/vol18/iss1/4>

This Article is brought to you for free and open access by The Open Repository @ Binghamton (The ORB). It has been accepted for inclusion in Northeast Historical Archaeology by an authorized editor of The Open Repository @ Binghamton (The ORB). For more information, please contact ORB@binghamton.edu.

Prospect Hill: Skeletal Remains from a 19th-Century Methodist Cemetery, Newmarket, Ontario

Cover Page Footnote

We would like to convey special thanks to Eva McDonald, of Archaeological Services, Inc., for her valuable historical research. Figure 1 was prepared by Catherine Vanderburgh-Kerr, and Figure 2 was prepared by Andrew Allan, both of ASI.

PROSPECT HILL: SKELETAL REMAINS FROM A 19TH-CENTURY METHODIST CEMETERY, NEWMARKET, ONTARIO

S. Pfeiffer, J. C. Dudar, and S. Austin

During 1989-90, in response to disruption caused by a building site excavation in Newmarket, Ontario, archaeological and biological information was salvaged from a former church cemetery dating from 1824 or 1827 to 1879. The skeletal remains of 77 individuals indicate a population with high infant mortality and little access to medical or dental care. Nevertheless, the autopsy of a young pregnant woman and one gold dental filling indicate there was an incipient interest in biomedical activities. Insofar as economic development necessitates disturbance of such sites, it is important that mechanisms be available to allow the salvage of as much historical and biological information as possible.

Au cours de 1989-90, en réponse à des perturbations causées par l'excavation d'un chantier de construction à Newmarket (Ontario), on a récupéré des renseignements d'ordre archéologique et biologique provenant d'un ancien cimetière d'église datant de 1824 ou 1827 à 1879. Les ossements de 77 personnes indiquent que la population présentait une mortalité infantile élevée et n'avait guère accès à des soins médicaux ou dentaires. Néanmoins, l'autopsie (dès cette époque) des restes d'une jeune femme enceinte et l'obturation d'une dent avec de l'or montrent qu'on commençait à s'intéresser aux activités biomédicales. Pour autant que le développement économique oblige à perturber des sites de cette nature, il importe qu'il existe des mécanismes qui permettent de sauver autant de renseignements d'ordre historique et biologique que possible.

Introduction

If we are to enquire into history at all, if the past is truly a useful perspective for the present and future, then we have the dual commitment of honouring the dead and studying and describing them. (Brothwell 1986: 122)

There are many reasons why human remains which were thought to have been interred in their final resting place must sometimes be moved. Legislation exists at many governmental levels to assure an orderly, planned removal. Nevertheless, historical documentation is frequently incomplete and there continue to be instances of discovery of unanticipated human remains, found when the development of a property is well underway. The resulting confusion and uncertainty is clearly illustrated at the site described here, Prospect Hill. The construction of a large institutional residence was half completed when it became apparent that a nineteenth century church cemetery had been established on the site and then forgotten.

In such instances, there can be substantial tension between cemeterians and historians. The former wish to hasten the remains' orderly disinterment and reinterment. The latter wish

to learn about ancestors who failed to "reach the threshold of historic visibility" (Limp and Rose 1985: 1). At Prospect Hill, a compromise was reached. The inherent uncertainty regarding the extent of the cemetery necessitated a thorough archaeological excavation. However, the time and facilities subsequently allowed for biological investigation of the remains were severely constrained in the interests of following cemetery closure protocol. This report summarizes the data that could be salvaged from the skeletal remains prior to their reinterment.

Why should such remains be studied? Historic osteological studies in North America have not been as numerous as studies of prehistoric populations, but they have contributed valuable information about human genetics and adaptation. Building on Angel's extensive biohistorical work (Owsley 1990), researchers have documented interconnections between the cultural and physical environment, between demographic change and levels of health. Sometimes the populations studied represent focal historic events, such as wars and specific battles (cf. Sciulli and Gramly 1989 describe a Revolutionary War cemetery, Cybulski 1988 describes prisoners of war).

Other populations of interest represent historic periods that are poorly understood (cf. work on the descendants of American slaves such as that of Rose 1985, Angel et al. 1987). Historic population samples have been studied to test our hypotheses and methodologies, such as Lanphear's use of a nineteenth century poorhouse cemetery to test the accuracy of skeletal age estimation (1989).

Economic development in Southern Ontario has necessitated the excavation of several historic cemeteries in the past five years (cf. Cook, Gibbs and Spence 1985; Pearce 1989; Spence 1989; Lazenby and Saunders 1990; McKillop et al. 1989; Pfeiffer and Williamson 1991). While several of the skeletal samples studied are small, the gradual accumulation of data will allow us to do biohistorical studies of temporal series or cultural subsets, much as we approach hypothesis construction in prehistoric skeletal biology. The realization of major biohistorical contributions in this geographic region will require a concerted and persistent effort to convince all participants of the historic value of skeletal remains, and an effort to salvage whatever biohistorical information we can in all such excavations.

The Prospect Hill Site

In 1861, Newmarket, Ontario, was a village of 1388 people (FIG. 1). It supported seven places of worship. One of these was the Wesleyan Methodist Church (Newmarket Historical Society, n.d.). It had been erected in either 1824 or 1827, and continued in use until 1879, when the congregation relocated. At that time, the church cemetery was legally closed, and family members were asked to remove remains for reinterment in the Newmarket Cemetery. Subsequently, a public school was built on the site, and the cemetery area was used as a playground and driveway. Burial markers were gradually removed and/or destroyed and several burials were disturbed by small-scale construction (e.g., drainage pipes).

By 1989, the school had been demolished, and construction was begun on a privately owned retirement home development. The new landowners were unaware of the potential for the discovery of human remains. When remains were unearthed, Archaeological Services Inc., Toronto, was retained to perform

archaeological mitigation, defining and delimiting the cemetery site. All the human remains likely to be disturbed or damaged were to be removed from the construction area. However, the care of the remains was specified by the Ontario Cemeteries Act. This meant that burial features were identified and exposed, but could not be disinterred until arrangements could be made for their reinterment. Church records proved to be unavailable. No next of kin could be located through advertisement, so it was several months before such arrangements could be made. Meanwhile, heavy rains caused considerable damage to the archaeological context. Upon removal from the ground, the remains were held in a shed on the construction site (it having been designated as a cemetery by provincial officials) until the mechanics of the reburial could be established. Research access to the remains was limited to the period of 1 January to 1 February, 1990. There was no access to running water in the shed, and it was minimally heated. Subsequent to 1 February, the remains were reinterred in a concrete crypt buried in a corner of the property, in the proximity of a few graves (N = 21) that were not threatened by the construction and therefore left undisturbed.

Materials and Methods

The first step in determining the location and orientation of the burials at Prospect Hill was to remove the topsoil overburden at potentially sensitive areas with the aid of mechanical equipment (Gradall). In the underlying subsoil layer the outlines of individual grave shafts were clearly discernible. These shafts were each photographed, drawn and plotted using standard triangulation techniques (FIG. 2). The five-meter grid used in triangulation was fixed by transit to a permanent datum (iron survey bar). As the work proceeded, it was determined that one corner of the cemetery was not threatened by the construction, and could be retained undisturbed. Hence, grave shafts in that area were plotted, but remained unexcavated. Archaeological excavation proceeded on all grave shafts that had already been disturbed or were threatened.

FIGURE 1: Location of the Prospect Hill Cemetery, Newmarket, Ontario, Canada

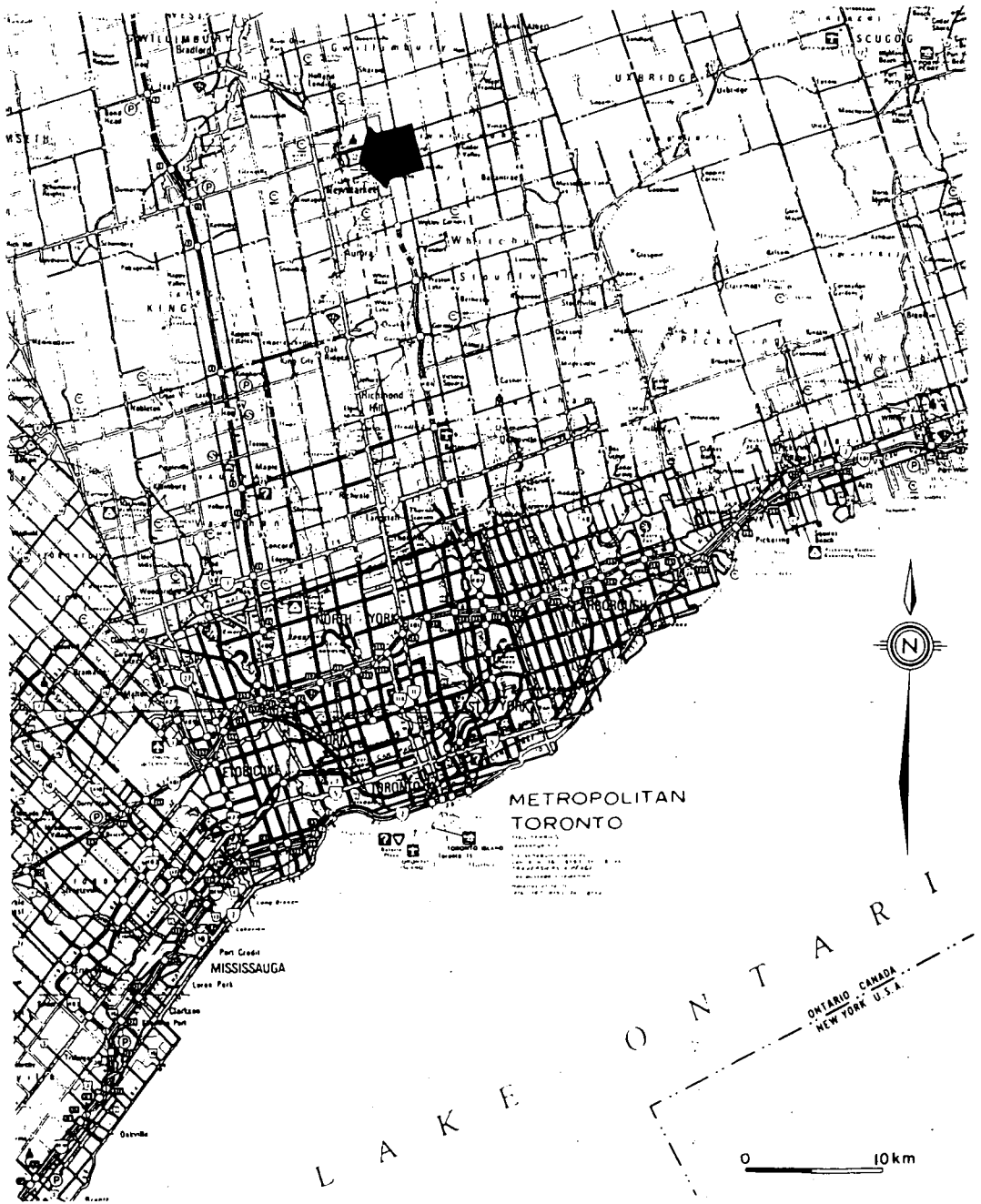

Figure 1. Location of the Prospect Hill Cemetery, Newmarket, Ontario, Canada.

FIGURE 2: Site Plan of the Prospect Hill Cemetery, Newmarket, Ontario, Canada

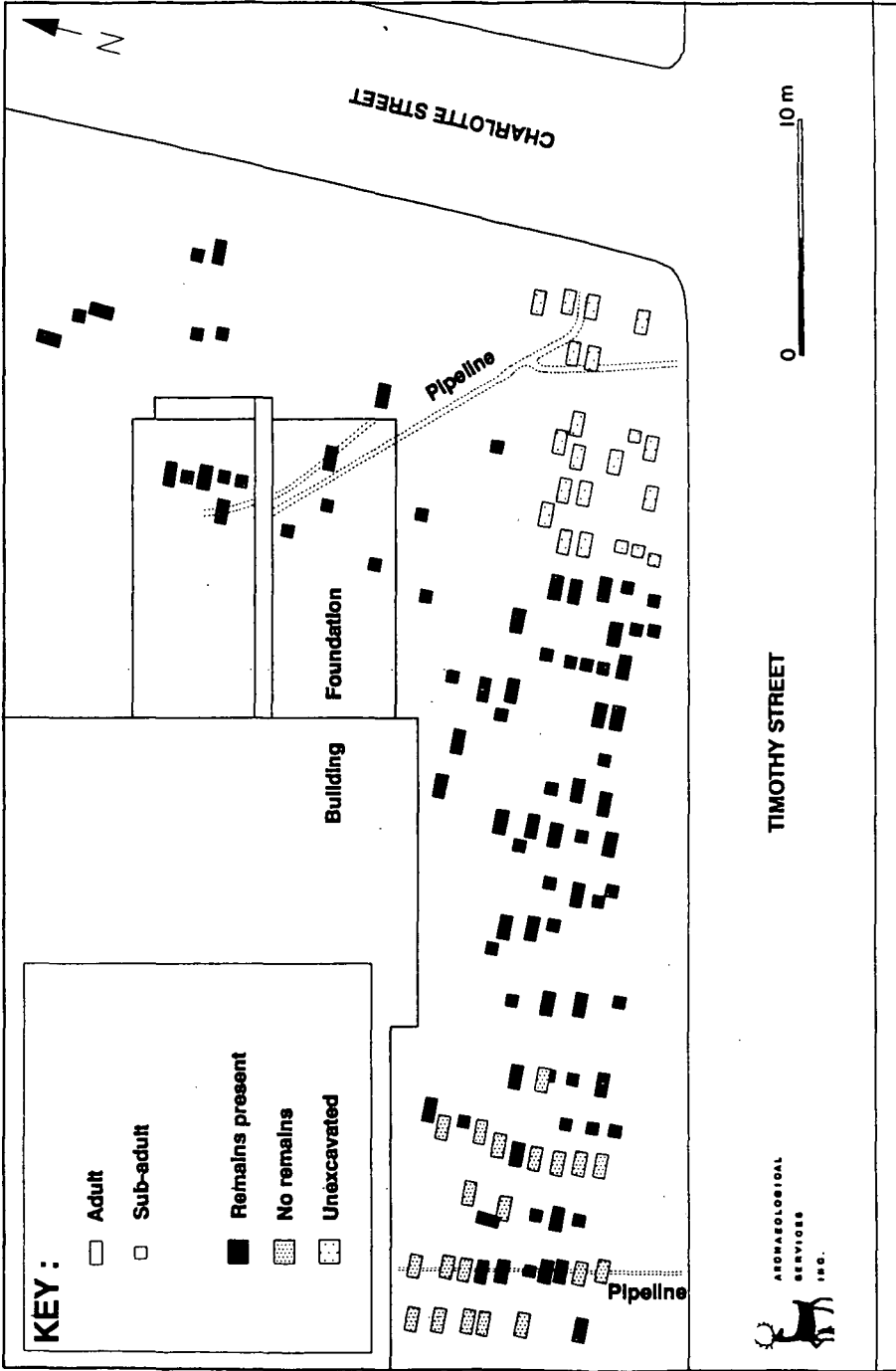


Figure 2. Site plan of the Prospect Hill Cemetery, Newmarket, Ontario, Canada.

A trench was hand excavated around the outside of each grave shaft down to the base of the feature. If human bone was encountered, photographs were taken, and measured drawings were executed. The horizontal and vertical provenience of all personal artifacts and coffin hardware was recorded. Preliminary assessment of age and sex was frequently performed. In a small number of instances, this field assessment was the only biological information gathered. There seems to have been a tendency for juveniles to be buried near one another. In no case was any newborn infant buried next to an adult female, as might have been the case if deaths occurred in association with childbirth (cf. Saunders and Lazenby, in press, for examples of such arrangements).

While many of the people interred at Prospect Hill were probably residents of the village of Newmarket, others may have been transported from distant rural settlements. Most of the graves yielded articulated, supine skeletons with hands to the side or folded in front. A few, however, yielded jumbles of semi-articulated and disarticulated bones (FIG. 3). Brothwell (1987) has argued that such "tumbled bone" may be the result of delayed burial combined with jostling, as might occur during a long wagon trip on bumpy roads. Transport from the country seems probable, given the rural orientation of the region at that time. However, burrowing rodent activity may also have disturbed some skeletons.

Permission to remove the skeletal material from the ground and store it temporarily on site was received in October, 1989. The process of exhumation in each case involved the labelling and packaging of individual bones or groups of bones within specific regions of the body. For example, crania and mandibles were always bagged separately, but many long bones (clavicles, humeri, femora, tibiae, and fibulae) were pooled by side per individual. Because separating right and left hand and foot bones would have been overly time consuming in the field, it was frequently necessary to combine the hands and combine the feet. The hip bones, sternum and sacrum from each burial were likewise bagged together. The same was true for ribs and vertebrae, but only if one or more epiphyses were not fused; in other words, if the skeleton in question was not fully matured. The ribs and vertebrae of adults were each sided




Figure 3. Grave shaft with jumbled bones and cranium.

and numbered, as far as possible. On a piece of masking tape, left and right ribs were each numbered from one to twelve. Similarly, a masking tape tag through the neural arch of each vertebra indicated "cervical 1" through "cervical 7", "thoracic 1" through "thoracic 12", and "lumbar 1" through "lumbar 5." As with any such labelling, if the order was uncertain, a letter sequence was used in place of numbers. Aluminum foil was wrapped around all immature jaws, in order to retain in place the formed and/or unerupted teeth. All these procedures expedited the subsequent rapid collection of biological information.

Examination subsequent to disinterment followed two patterns, depending on whether the remains were juvenile or adult. If juvenile, the long bones were examined and measured for maximum lengths, various skeletal elements were assessed for maturational status, and the dentitions were carefully cleaned for age and dental health assessment. Both dental formation (Moorrees, Fanning, and Hunt 1963 as found in Bennett 1987) and dental eruption standards (as per Ubelaker 1978) were applied, with formation results preferred because they are more accurate. Juvenile crania were

partially cleaned and examined for *cribra orbitalia* and porotic hyperostosis. If the remains were those of an adult, once again the long bones were examined and measured for maximum lengths, and the dentitions were cleaned for dental health assessment. Crania and hips were assessed for indications of sex. The following areas were cleaned for age assessment: pubic symphyses, iliac auricular surfaces, sternal rib ends and cranial vault sutures (Moore-Janzen and Jantz 1986). Several instances of noteworthy pathology required more extensive cleaning and photography. Bone tissue samples for isotopic analysis were retained from each skeletal feature.

Results

Composition of the Skeletal Sample

A total of 77 skeletons or partial skeletons was disinterred. Forty-nine percent of these individuals were juveniles (up to 16 years of age). There were only four adults who were indisputably over sixty years of age (TAB. 1). Fifteen infants (20% of the total) appear to have died before the end of their first year of life. Among the adults, 37 were complete enough for the sex of the individual to be estimated: 22 males and 15 females.

This profile of age at death may give a misleading impression of the cemetery population for a number of reasons, an obvious one being the purposeful removal of many individuals when the cemetery was closed in 1879. We therefore attempted to estimate the age of the individuals that had been removed in the nineteenth century, and those left undisturbed, using the lengths of the coffin remnants and/or grave shafts.

A regression of approximate coffin length against estimated adult stature suggests that coffins were custom-built, and that their length approximates the stature of the deceased (N=18 pairs, $r=0.55$). However, a plot of age versus grave shaft length demonstrates a great deal of variability, especially among infants (FIG. 4). We concluded that a grave shaft length of less than 150 cm probably indicated a juvenile, while a grave shaft length of more than 200 cm probably indicated an adult. Lengths between 150 and 200 cm could not be confidently attributed to an age class. Using this approach, the empty or unexcavated

features that could be measured represent 25 juveniles, 12 adults and 6 individuals of undetermined age. This indicates that the remains of children were not less likely to have been relocated, as compared to adults. The proportion of juveniles within the original, complete cemetery may have been 60% or higher.

Adult Stature

Twenty-eight adults had long bones extant, suitable for measurement and subsequent estimation of stature. Adult cranial characteristics and long bone shapes were all consistent with a Caucasian racial classification, so the Trotter and Gleser (Bennett 1987) regression equations for male and female whites were applied, choosing in each case the equation with the lowest error. In most instances, this is the estimate based on the tibia or femur, with standard errors of the estimates of 3.7 cm (see TAB. 2). The mean statures of 161 cm for females and 173 cm for males suggests that this was a moderately tall population by world standards (Olivier 1969) with considerable sexual dimorphism.

Another way to express the size dimorphism is through the long bone measurements themselves (TAB. 2). The diameter of the head of the femur proved to be useful in corroborating other sex indicators, in that it followed a bimodal distribution (Stewart 1979).

Juvenile Long Bone Lengths

The examination of long bone lengths from juvenile individuals can offer an indication of not only general body size, but also the tempo of growth. Both bones and teeth develop in a manner that is determined by both genetic and environmental factors. However, dental development is less sensitive to environmental influences (cf. Demerjian 1986). Therefore, by comparing an individual's dental maturation against their skeletal growth, we can ascertain whether the skeleton is growing more quickly or less quickly than would be expected on the basis of the teeth.

In Figures 5 through 9, we have compared the lengths of Prospect Hill long bone shafts (diaphyses) against standards developed for

Feature Length versus Age Prospect Hill

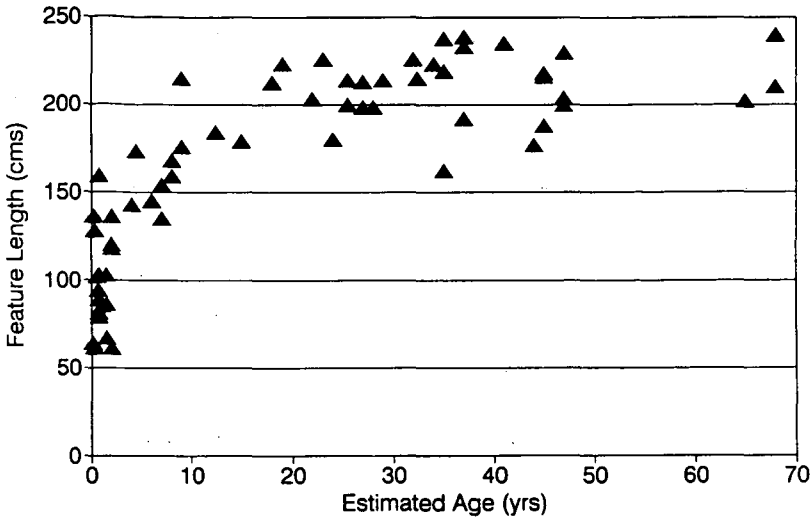


Figure 4. A comparison of age of deceased against grave shaft length.

Table 1. Ages of Prospect Hill individuals, based on mid-points of estimated age ranges for each individual.

<i>Age in years</i>	<i>N</i>	<i>Female</i>	<i>Male</i>	<i>?</i>
0-1	15	-	-	-
1-2	7	-	-	-
2-5	3	-	-	-
5-16	13	-	-	-
16-25	5	2	3	-
25-40	19	5	14	-
40-60	9	8	1	-
60+	4	-	2	2
adult	2	-	2	-
<i>Totals</i>	<i>77</i>	<i>15</i>	<i>22</i>	<i>2</i>

Table 2. Stature and long bone lengths of Prospect Hill adults.

<i>Measurement</i>	<i>Female</i>	<i>Male</i>
Stature (est) (cm)	x = 161.1 sd = 4.9 N = 11	173.4 4.4 17
Max. femur length (mm)	430.3 19.4 10	460.5 18.9 14
Femur head diameter (mm)	41.7 2.3 9	47.3 1.6 10
Max. tibia length (mm)	343.3 16.8 11	378.1 19.6 13
Max. humerus length (mm)	305.1 18.1 7	332.9 19.7 14
Humerus max. head diameter (mm)	40.2 1.8 5	46.7 2.3 8
Max. ulna length (mm)	237.9 9.8 8	261.1 17.5 13
Max. radius length (mm)	219.9 8.8 8	246.7 12.7 13
Max. clavicle length (mm)	142.0 11.3 4	143.3 7.7 11

Table 3. Prospect Hill: teeth decayed and lost pre-mortem.

	<i>Mandible</i>		<i>Maxilla</i>	
	Lost	Caries	Lost	Caries
Adults N=17	17.9% (41/229)	28.8% (49/170)	21.7% (52/240)	26.9% (39/145)
Juveniles* N=11	6.8% (8/117)	27.0% (20/74)	0.0% (0/117)	31.1% (23/74)

*Only dental arcades of 10 to 12 erupted teeth (ages 2-11 years).

FEMUR

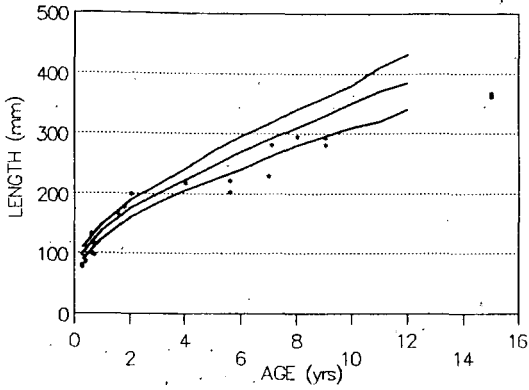


Figure 5. Femur: comparative lengths.

TIBIA

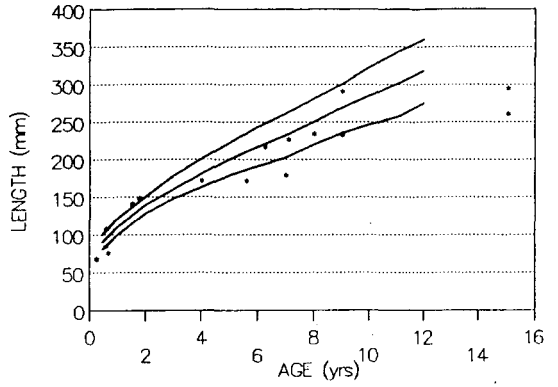


Figure 6. Tibia: comparative lengths.

HUMERUS

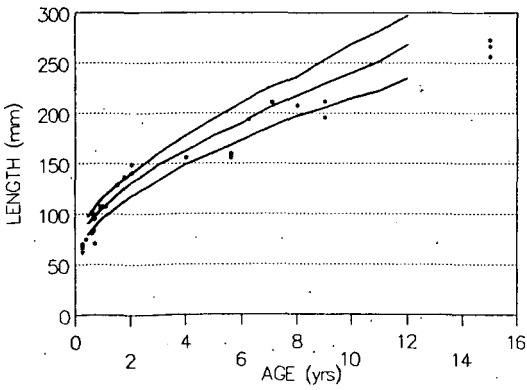


Figure 7. Humerus: comparative lengths.

RADIUS

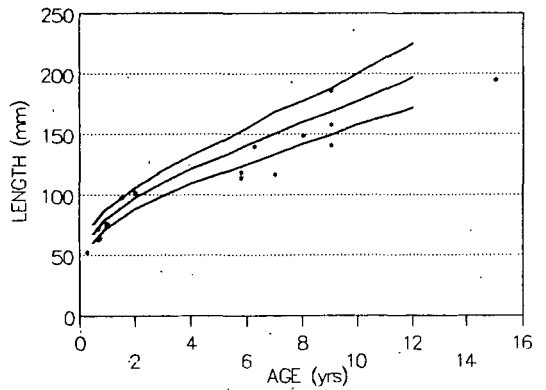


Figure 8. Radius: comparative lengths.

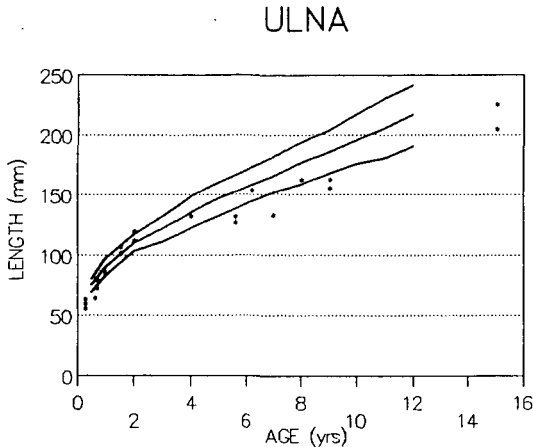


Figure 9. Ulna: comparative lengths.

modern North Americans (Hoffman 1979). The curves are taken from radiographs of 334 children studied in a longitudinal study in Colorado, 1927-1967. The modern diaphysis lengths are from the girls only, and there is a 2-3% magnification error resulting from radiography. On each figure, the mean and the 95% confidence intervals are plotted. Prospect Hill individuals are plotted by the midpoints of the dental age estimates (formation standards). The number of individuals with diaphyses available for comparison ranged from 17 for the radius to 28 for the humerus.

The femur shows the most rapid growth of any long bone, and so is a frequent focus of interest in such studies (cf. Cook 1979). Clearly, there are a number of Prospect Hill children whose femora are exceptionally short for their "age" (i.e. dental development). This pattern of reduced skeletal growth is mirrored in all the plots of diaphysis lengths versus age. There are two ways that such an outcome could occur: the children represented here could have been growing slowly throughout childhood, or they could have been growing at a normal pace until beset by a bout of serious ill health which slowed or stopped growth and ultimately caused death. In other words, growth retardation could have been chronic or acute.

We expect children of the previous century to show slower growth and maturation than contemporary children. This phenomenon is known as the secular trend. The Prospect Hill

children aged at circa 15 years whose long bones are the size of those of a modern 12 year old had probably not yet experienced their adolescent growth spurt. This pattern of generally slower growth remains unexplained, but is probably attributed to dietary, hygienic and disease factors (vanWieringen 1986). Nevertheless, there are a few Prospect Hill individuals whose growth is so dramatically slowed that the difference cannot be attributed to the secular trend. The four children who show consistent dramatic retardation in mid-childhood are Burials 33, 49, 73, and 108. One of these (Burial 49) was only examined in the field, due to time constraints after disinterment.

The other three showed no gross skeletal abnormalities upon examination in the shed. Of the three, two (Burials 73 and 108) showed early loss of some deciduous molar teeth, apparently because of caries.

We would tentatively suggest that the growth retardation seen here was the result of acute factors. This argument is based on the relative paucity of chronic stress indicators such as enamel hypoplasia and skeletal responses to anemia, plus the relatively large body size of the adults. Radiographs of the Prospect Hill juvenile bones, which could have yielded measures of cortical thickness and lines of growth arrest/recovery, would have been helpful in exploring this point, but were unavailable because we were not allowed to move the bones off the construction/cemetery site.

Dental Health

Throughout both adult and juvenile dentitions, there was extensive evidence of caries and premortem tooth loss. Some of the premortem tooth loss among the adults may have been associated with preparation for dentures. While we recovered no appliances, the remodeling of the alveolar bone was often consistent with the accommodation of a partial or full plate. In other instances, uneven dental wear patterns and dental migration indicated lengthy absence of any teeth or alternate device.

Two of the eleven dentitions examined during excavation were completely devoid of

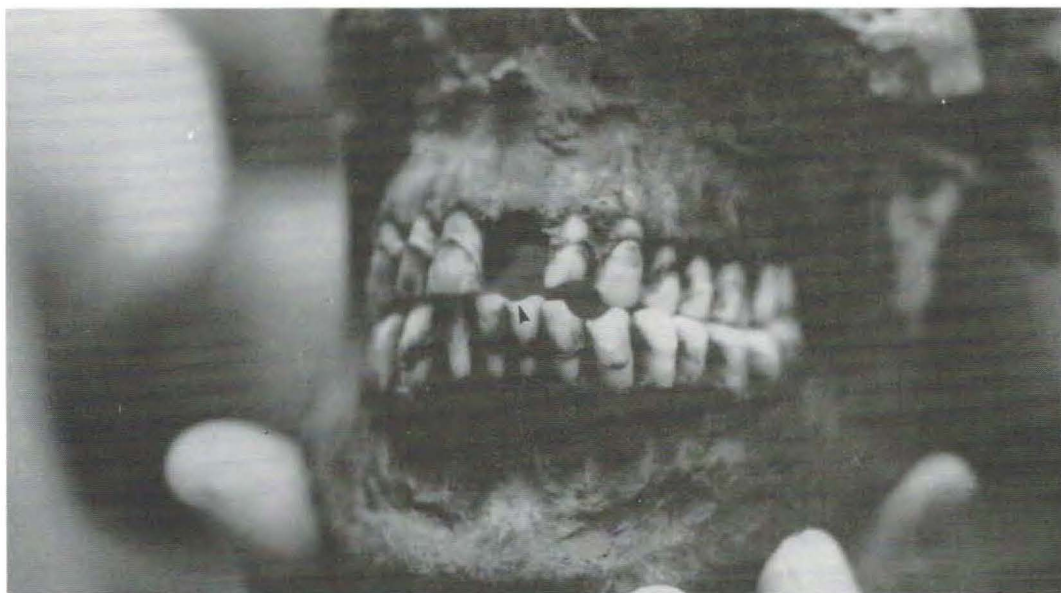

Figure 10. Dental wear facets from pipe smoking (Burial 50A). Note two sets of notches that would have accommodated the clay pipe stem. An arrow points to the smaller, more central notch. The maxillary incisor was lost post-mortem. Calculus had accumulated along the gum line. Note, too, the heavy layer of dirt adhering to the skull, typical of material from this site.

teeth (edentulous). Because of time limitations, we applied a simple "decayed, missing, filled" index to dentitions examined after exhumation. With one exception, this is in fact a measure of the proportions of only decayed and missing teeth. The only direct evidence of dental care was a very small gold filling on a maxillary right first molar (mesial interproximal surface) in the mouth of a middle-aged woman (Burial 1). She was also the only person in the cemetery to have been buried in a brick vault, constructed around a wooden coffin. This special treatment may be an indication of higher socioeconomic class.

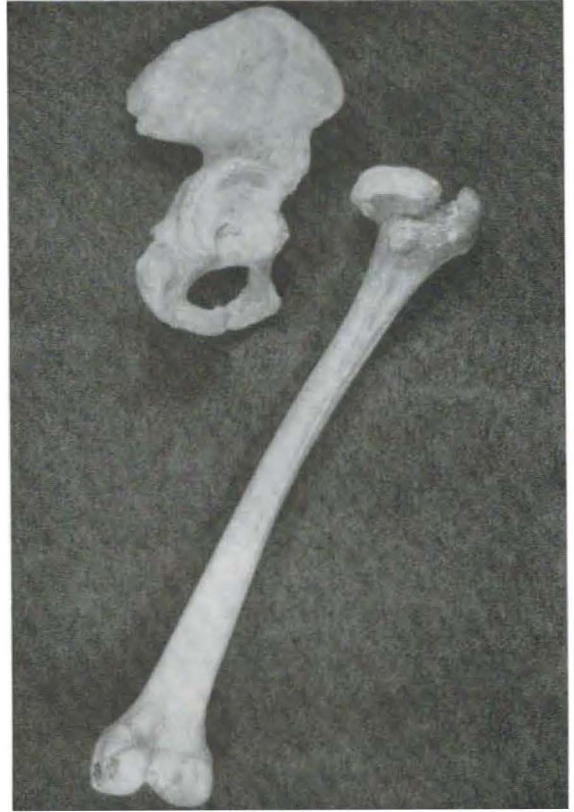We were able to examine seventeen adult dentitions after exhumation, not including the two edentulous individuals previously noted. Dental loss and decay are summarized in Table 3. About 20% of the permanent teeth had been lost, and of the remainder, almost 30% were decayed. These dentitions included only one completely edentulous maxilla. Most had a mixture of decay and loss. Only one individual, a male aged 40-50 years, had no decay or tooth loss. Three dentitions, all apparently male, showed the curved occlusal wear surface that is

characteristic of habitual pipe smoking. In two men the pipe facets were on the left, in one it was on the right (FIG. 10). It has been suggested that such facets occur on the same side as the hand that habitually holds the pipe (St. Hoyme and Iscan 1989). Hence, left sided pipe facets indicate that the right hand was free for work and/or that the person was right-handed.

Among juveniles with ten or more teeth erupted, the proportions of lost teeth are lower, but decay is very common. Of the eleven individuals examined, no dentition was devoid of decay. Indeed, by age six (first permanent molar), loss of some deciduous mandibular molars because of caries was a common situation. For example, one child estimated to be 5 to 6.5 years old showed the premortem loss of three deciduous molars from the mandible, and extensive decay of three deciduous molars in the maxilla.

We noted sporadic heavy calculus (plaque) deposits, but only one case of moderate or severe enamel hypoplasia (Burial 108, a child who also showed slowed growth). Hence, the poor dental health demonstrated here is most likely the result of a cariogenic diet, perhaps

Figure 11. Shallow acetabulum, mushroom-shaped head of femur indicating partial dislocation (Burial 57). The left hip appeared normal. However, the pelvis was slightly asymmetrical, suggesting that this was a chronic condition, to which the pelvis had accommodated.



combined with poor habits of dental hygiene, rather than poor quality enamel.

Trauma and Illness

Just as there is minimal evidence for dental care, so there is minimal evidence for medical care in the Prospect Hill sample. The most common pathological conditions are fractures of long bones.

The soil surrounding the burials had been a very sticky clay, and administrative demands necessitated that most of the bones were removed when the soil was very wet. Hence, when the clay dried, it fell away from the bone in large, hard chunks. This left the long bones dusty, but free of most adhering dirt. While a survey of such bones may have missed some well aligned very well healed fractures, it should offer a reasonably accurate minimal count.

Of the approximately 260 complete long bones examined, five showed evidence of old fractures. A fragmentary adult male had pseudoarthroses of the distal portions of the right radius and ulna. That is, the forearm had been fractured and the breaks had not knit, but rather had formed new "false joints". One adult female had sustained a fracture of the distal third of the left tibia and fibula. While the bones healed with no sign of infection, the oblique fractures caused the mended bones to foreshorten by about 30 mm compared to the right tibia and fibula. While the anterior tibia callus was smooth and rounded, there is a sharp protruding bony eminence posteriorly. The shafts were bowed medially as well as shortened. This would have caused a pronounced limp, as well as possible muscle pain. A young adult male from a fragmentary feature appears to have sustained trauma to his right elbow, probably before growth was

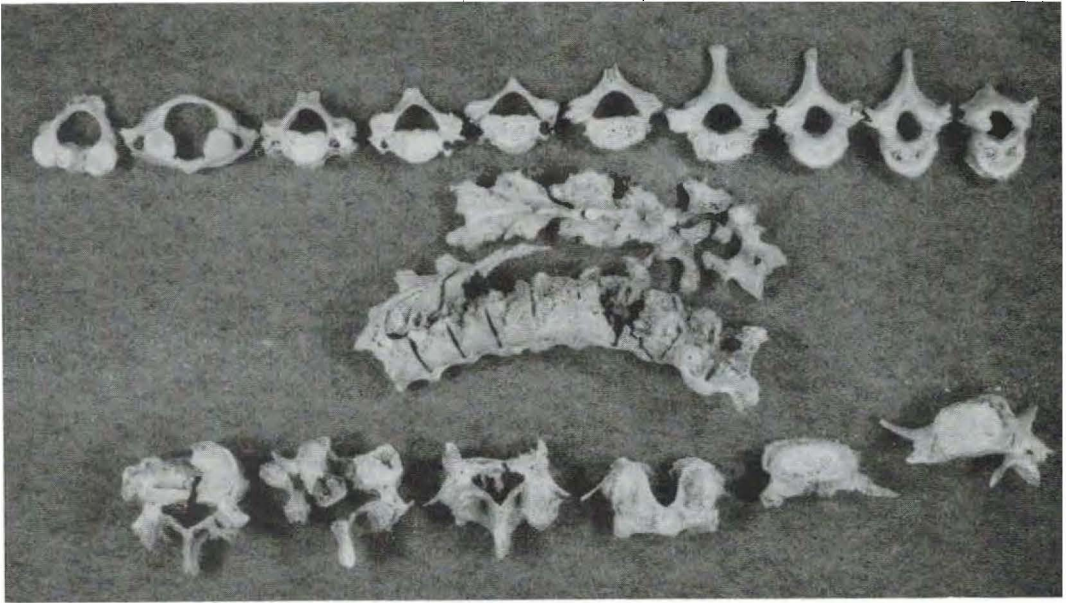


Figure 12. Vertebral column affected by ankylosing spondylitis (Burial 68). From upper left, vertebrae are arranged sequentially in superior view. The 3rd and 4th cervicals are fused. The major fusion includes T5 through L1. The lower row includes L2 through S1 (L5 is in two fragments).

complete. This led to some remodeling of the distal humerus and a length disparity of 17 mm between it and the left humerus. The forearm bones were missing from this disturbed grave.

Other indications of trauma include a dislocated hip sustained by a young adult male (FIG. 11), and a large ossified subperiosteal hematoma (a bone lump, formed in response to serious bruising) found on the left external anterior parietal bone of a middle aged adult female. Several other features, such as a fused sacrum and hip bone and a "lumbarized" first sacral vertebra, may be the results of trauma or they may be normal developmental variables. No clear evidence of trauma was found on any of the immature bones.

Because we were unable to clean the bones systematically, we may have missed subtle indications of various diseases that may affect the skeleton. Only quite dramatic changes were sure to be noticed. One such dramatic case was the vertebral column of an edentulous male aged at least sixty years (Burial 68). Unfortunately, this rather shallow grave was located beneath the school driveway and was badly fragmented. Nevertheless, it is clear

that at least nine vertebrae in the lower spine had fused (T5-L1) with a reduction in disk space and moderate dorsal kyphosis (FIGS. 12, 13). Two of the cervical vertebrae (C3-C4) were also fused, although this may be an unrelated developmental anomaly. The most dramatic new bone formation was apparent along the anterior vertebral bodies, as smooth new bone formed a "dripping candle wax" pattern. The spinous processes in this large segment were also fused together, although with little new bone growth. The ribs were badly fragmented, but there were definitely some sites at which there had been vertebra-rib fusion. The right auricular surface of the ilium was fused to the sacrum. No long bones showed clear signs of marked osteoarthritis or ankylosis. All the bone was quite light (osteoporotic). These features are all characteristic of ankylosing spondylitis (a.k.a. Marie-Strumpell's disease) (Ortner and Putschar 1981: 411). The sacroiliac fusion and the reduction in the intervertebral spaces distinguish it from diffuse idiopathic skeletal hyperostosis (DISH) (Resnick and Niwayama 1976). Ankylosing spondylitis is an arthritic

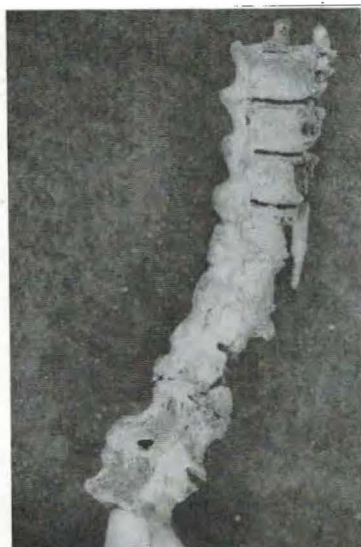


Figure 13. Close-up of fused vertebrae, featuring the smooth, "dripping candle wax" pattern of new bone. Note compression of intervertebral disk space.

condition that would have limited this individual's mobility, and could have been quite painful.

Among the juvenile remains, two infants (Burial 36 and 105) were noteworthy for changes to the cranial bones (FIGS. 14, 15). While not identical in appearance, these two cases seem similar enough to be discussed together, as possible manifestations of the same or similar phenomena. Both were about nine months of age when they died. Both showed possible slight expansion and/or periostitis of some long bones and ribs, and a dramatic pattern of outer table expansion and erosion on the cranium. The inner table of the cranium looks normal, except for perforations extending from the outer table. The focus of greatest change is the frontal bone, especially the roofs of the orbits. The occipital area is relatively unaffected. While some expansion of the diploic (cancellous) bone is apparent, the dominant feature is erosion of the normal external surface. The one extant mandible appeared normal.

The extensive changes to the orbits, frontals and parietals is reminiscent of a number of juvenile metabolic/nutritional

deficiency conditions. We reasoned that these two individuals might be manifesting a community nutritional problem (e.g., rickets, scurvy, anemia). To explore this further, we systematically examined most juvenile and adult crania for the presence of *cribra orbitalia* and porotic hyperostosis. The former is a spongy expansion of the roof of the orbit, associated with anemic conditions of various origins. The latter is associated with more pronounced anemic states. In conditions of anemia, the body's usual response is to create more hemopoietic marrow. This results in the deposition of new trabecular (spongy) bone, either within existing marrow cavities, or on top of the cortical bone covering of the skull.

Of twenty-three apparently healthy juveniles, three showed a trace of porosity in this area and two showed slight-to-moderate *cribra orbitalia*. Of the adults, only one young adult female (Burial 38, discussed further below) showed moderate *cribra orbitalia*. There was no evidence of active or healed porotic hyperostosis. These frequencies are moderate to low and may be interpreted as evidence against a pervasive nutritional deficiency. The pattern of bone remodeling seen in Burials 36 and 105 does not appear to be clearly diagnostic of any specific syndrome. The focus of lesions in the frontal and parietal regions of the skull bone is consistent with rickets, but the proliferative disorganized new bone growth and orbital involvement is inconsistent with the rickets pattern. The proliferation is consistent with infantile cortical hyperostosis, but in this condition the mandible is involved in 70–90% of all cases (Zachariades et al. 1986), and the long bones frequently show prominent swelling. The extensive cranial remodeling may be indicative of a hypercalcemic state, which is very serious in an infant. Symptoms would include irritability, nausea, weight loss and growth failure. The long bone diaphyses of both these infants are well below the reference values discussed earlier. If the cause of the disruption were an illness like infantile cortical hyperostosis, there would also be a high fever. The ultimate cause of death could have been dehydration or renal failure (Harrison and Harrison 1979). Because the pathological changes seen in these two infants are so similar, it is tempting to suggest the presence of a congenital metabolic defect following a



Figure 14. Right parietal bone of Burial 36, showing expansion of diploic bone and areas of destruction of outer table.

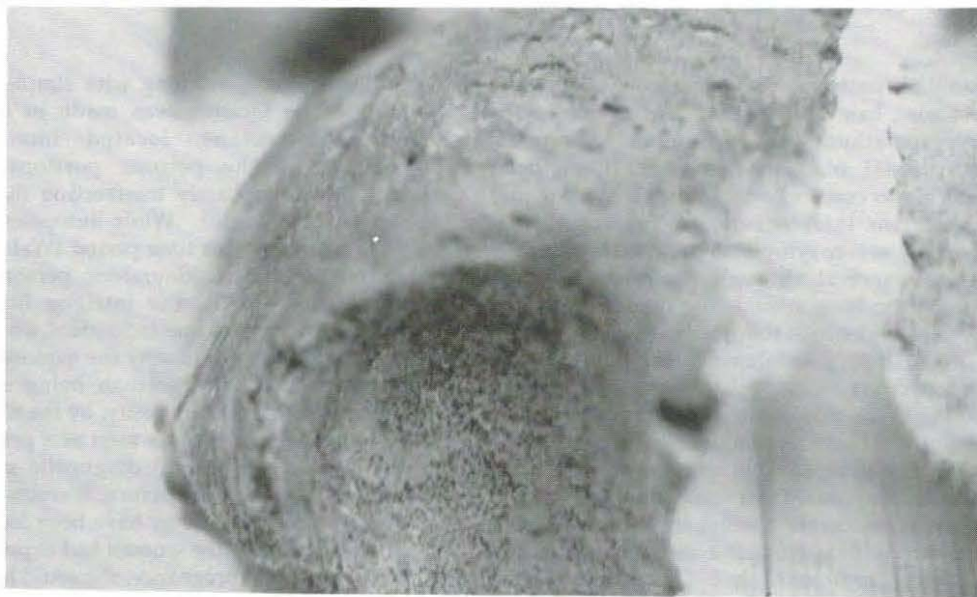


Figure 15. Close-up of right orbit and frontal bone, Burial 105, showing spongy new bone and destruction of outer table. The metopic suture is still open, with is normal at this young age.



Figure 16. Burial 38, a young adult female, on whom an autopsy had been performed.

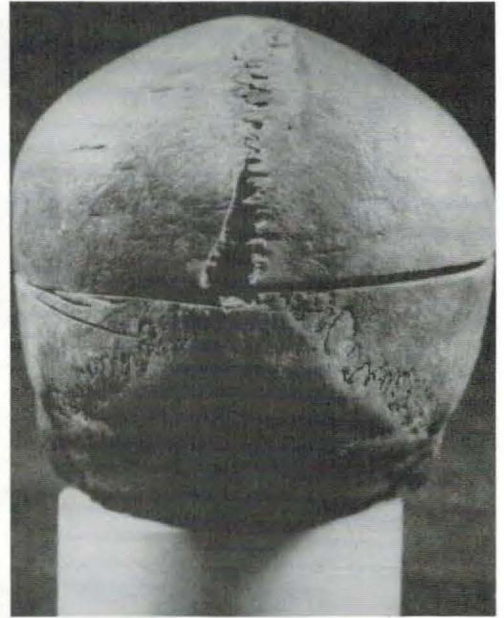

Figure 17. Posterior view of Burial 38. Note the numerous saw cuts, illustrating the technique used to perform the craniotomy with minimal destruction of the brain tissue.

familial pattern. Infantile cortical hyperostosis has a familial form, as does hyperparathyroidism. Alternately, dramatic nutritional inadequacies could have been specific to certain households. It is clear that these two infants suffered prolonged and possibly severe symptoms prior to their deaths. Their survival through the weeks during which the bone remodeling occurred may be seen as evidence of solicitous care.

Burial 38, a female who died at 25–30 years of age offers an intriguing, if puzzling, picture of life in the mid-nineteenth century. She was delicately built, yet moderate in stature (157 cm). She suffered from impacted third molars and an abscessed front tooth, and she showed signs of moderate anemia (*cribra orbitalia*). In the pelvic area were the remains of a foetal skeleton, approximately 6–7 months gestation. After she died, her body had been at least partially autopsied. A craniotomy had been performed on the skull, but the ribs showed no sign of the opening of the chest cavity. The saw marks around the calvarium indicate a careful,

skillful surgeon, working with simple manual tools. The incision was made in a single, horizontal plane, located immediately superior to the petrous portions of the temporals and barely intersecting the frontal sinus (FIGS. 16–18). While autopsies are not unknown from this time period (Waldron and Rogers 1987; S. R. Saunders, personal communication, 1990), the intrigue here is to ascertain why this one individual would have been a candidate, and why the exploration was not complete. Rather than being simply a reflection of morbid curiosity, by the nineteenth century the autopsy was seen as a progressive contribution to clinical diagnostic medicine. While it is purely conjecture, it seems possible that the pathologist may have been looking for brain changes. If the woman had experienced a toxic reaction to pregnancy, she could have been experiencing seizures at or around the time of death. Did they know she was pregnant? Did they elect to avoid disturbing the foetus? Of course we do not know. This case illustrates behavior in a period during which medical and

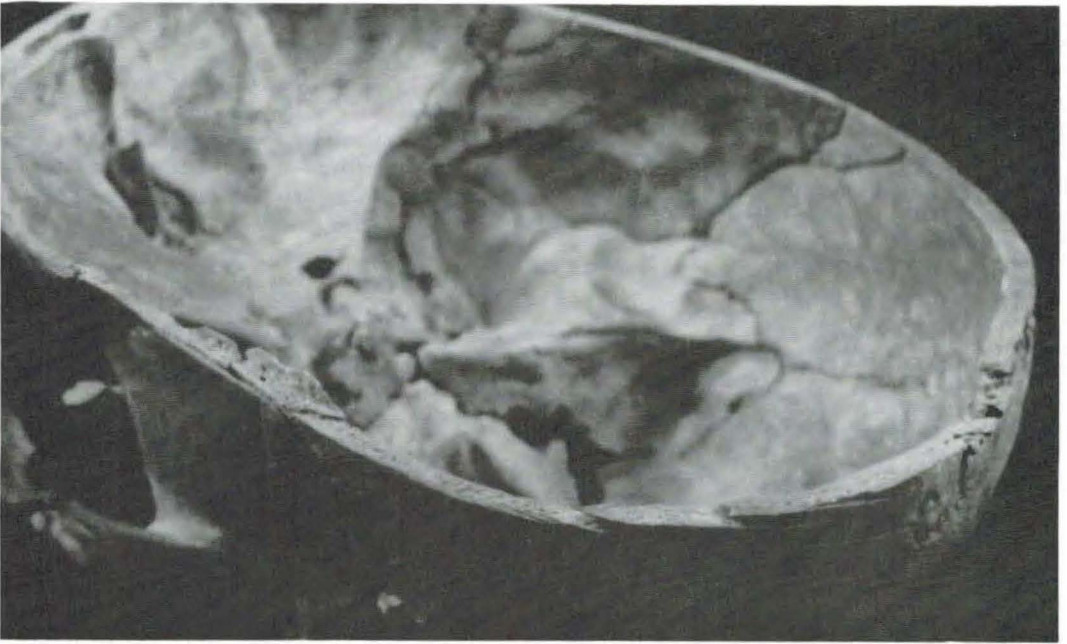


Figure 18. Close-up of the cut surface of the cranium, Burial 38. Note the saw marks on the bone surface and the bone "tab" above the left temporal region.

dental practitioners were contributing to community health, but in a very preliminary way.

Conclusions

The disinterment of the Prospect Hill remains furnished a brief glimpse of the lives and deaths of Southern Ontario immigrants during the mid-19th century. Precise historic reconstruction is precluded by the absence of church records and next of kin. Generalizations must therefore be drawn from the brief salvage analysis of bones and teeth described herein.

A principle feature of the sample is its youth. The age-at-death profile indicates that of the infants born, over half died before reaching adulthood. Deductions of approximate age at death made from the size of both the empty and unexcavated archaeological features confirm this observation. Among the recovered skeletons, almost a quarter died during the first year of life. This short life expectancy is not accompanied by indications of chronic ill

health. While dental health is poor, there are no pervasive indicators of poor quality enamel. Although juvenile long bones are short for age, adult stature is moderate to tall, suggesting slowed maturation but not stunted growth. There are no consistent indicators of nutritional deficiencies or anemia.

It is regrettable that we were unable to thoroughly clean and examine all the material for indications of chronic diseases and/or active foci of infection. Nevertheless, we can state with some confidence that no moderate to severe bone infection was present. This apparent sparsity of chronic complaints plus low life expectancy suggests that the most common sources of mortality may have been serious accidents and/or acute diseases. Diseases such as diphtheria, typhus and other acute infectious agents are all possibilities. If medical attention was not sought for the setting of broken bones, it may not have been sought for disease treatment either; and, if it had been sought, it might not have been efficacious. The limited growth of the juvenile long bones would then reflect acute growth arrest associated with the illness that caused the death.

Nevertheless, we see in the one gold filling and the partial autopsy the beginnings of the involvement of biomedical practitioners in health maintenance. As socioeconomic conditions and quality of medical care improved, subsequent generations of Newmarket Methodists would enjoy better health and longer lives.

Historian W. H. Graham has recently written that

the doings and sayings of political leaders, great divines and successful businessmen do not tell us much about their societies because such people are exceptions. We need to hear from "the middle of humanity", but unhappily the voices of ordinary mortals of the past are muffled by mortality itself and the world they lived in is obscured by the accumulations of the years. (Graham 1988: 7)

Situations like the salvage excavation of the Prospect Hill cemetery can offer opportunities to explore this obscured world. However, the legislative environment must allow for the incorporation of biological research into projects of this nature. Simply, if the project team had been given the opportunity to thoroughly clean the bones and to temporarily remove them for radiography and systematic study it would now be possible to offer a great deal more information about this population. For example, patterns of joint change and osteoarthritis can indicate habitual activities; adult cranial size and shape, plus genetically influenced skeletal traits can be used to study population relationships. The careful, methodical study of human skeletal remains prior to their reinterment is neither disruptive or disrespectful. It should be incorporated into the normal protocol when moving historic cemeteries.

Acknowledgments

We would like to convey special thanks to Eva McDonald, of Archaeological Services, Inc., for her valuable historical research. Figure 1 was prepared by Catherine Vanderburgh-Kerr, and Figure 2 was prepared by Andrew Allan, both of ASI.

References

- Angel, J. L., J. O. Kelley, M. Parrington, and S. Pinter
1987 Life Stresses of the Free Black Community as Represented by the First African Baptist Church, Philadelphia, 1823-1841. *American Journal of Physical Anthropology* 74: 213-229.
- Archaeological Services Inc.
1990 Archaeological Mitigation of the Prospect Hill Cemetery, Town of Newmarket, Regional Municipality of York. Ms. on file, Archaeological Services Inc., 662 Bathurst St., Toronto.
- Bennett, K. A.
1987 *A Field Guide for Human Skeletal Identification*. Charles C. Thomas, Springfield, IL.
- Brothwell, D.
1987 Decay and Disorder in the York Jewbury Skeletons. In *Death, Decay and Reconstruction: Approaches to Archaeology and Forensic Science*, ed. by A. Boddington, A.N. Garland and R.C. Janaway, 22-26. Manchester University Press, Manchester.
- Brothwell, D.
1986 *The Bog Man and the Archaeology of People*. Harvard University Press, Cambridge, MA.
- Cook, D. C.
1979 Subsistence Base and Health in the Prehistoric Illinois Valley: Evidence from the Human Skeleton. *Medical Anthropology* 4: 109-124.
- Cook, M., L. Gibbs, and M. W. Spence
1985 Age and Sex Identification in the Stirrup Court Cemetery. *Kewa* (The Newsletter of the London Chapter of the Ontario Archaeological Society) 3-19.
- Cybulski, Jerome S.
1988 Skeletons in the Walls of Old Québec. *Northeast Historical Archaeology* 17: 61-84.

Demirjian, Arto

- 1986 Dentition. In *Human Growth: A Comprehensive Treatise*, Volume 2, ed. by F. Falkner and J.M. Tanner, 269-300. 2nd edition. Plenum Press, NY.

Graham, W. H.

- 1988 *Greenbank: Country Matters in 19th Century Ontario*. Broadview Press, Peterborough, Ontario.

Harrison, H. E., and H. C. Harrison

- 1979 *Disorders of Calcium and Phosphate Metabolism in Childhood and Adolescence*. W. B. Saunders Co., Philadelphia.

Hoffman, J. M.

- 1979 Age Estimations from Diaphyseal Lengths: Two Months to Twelve Years. *Journal of Forensic Science* 24: 461-469.

Krogman, W. M.

- 1962 *The Human Skeleton in Forensic Medicine*. Charles C. Thomas, Springfield, IL.

Lanphear, K. M.

- 1989 Testing the Value of Skeletal Samples in Demographic Research: A Comparison with Vital Registration Samples. *International Journal of Anthropology* 4: 185-193.

Lazenby, R. A., and S. R. Saunders

- 1990 Historiography and Osteobiography of a 19th Century Pioneer Cemetery from Southwestern Ontario. *American Journal of Physical Anthropology* 81: 256.

Limp, W. F., and J. Rose

- 1985 Introduction. In *Gone to a Better Land*, ed. by J. Rose, 1-5. Arkansas Archaeological Survey, Fayetteville.

McKillop, H., S. Marshall, G. Boyce, and S. Saunders

- 1989 "Excavations at St. Thomas Church, Belleville, Ontario: A 19th Century Cemetery." Paper presented at Ontario Archaeological Society Symposium, October 28-29, London, Ontario.

Moore-Jansen, H., and R. L. Jantz

- 1986 A Computerized Skeletal Data Bank for Forensic Anthropology. Department of Anthropology, University of Tennessee, Knoxville, TN.

Newmarket Historical Society

- n.d. *Newmarket 1861: A Village in Transition*. Vol. 1, No. 3, Newmarket, Ontario.

Olivier, G.

- 1969 *Practical Anthropology*. Charles C. Thomas, Springfield, IL.

Ortner, D. J., and W. G. J. Putschar

- 1981 *Identification of Pathological Conditions in Human Skeletal Remains*. Smithsonian Institution Press, Washington, DC.

Owsley, D. W.

- 1990 The Skeletal Biology of North American Historical Populations. In *A Life in Science: Papers in Honor of J. Lawrence Angel*, ed. by J. E. Buikstra, 171-190. Scientific Papers 6. Center for American Archaeology, Kampsville, IL.

Pearce, R.

- 1989 "The Wise Family Cemetery, Richmond Hill." Paper presented at Ontario Archaeological Society Symposium, October 28-29, London, Ontario.

Pfeiffer, S., and R. W. Williamson, eds.

- 1991 *Snake Hill: An Investigation of a Military Cemetery from the War of 1812*. Dundurn Press, Totonto, Ontario.

Resnick, D., and G. Niwayama

- 1976 Radiographic and Pathological Features of Spinal Involvement in Diffuse Idiopathic Skeletal Hyperostosis (DISH). *Radiology* 119: 559.

Rose, J., ed.

- 1985 *Gone to a Better Land*. Arkansas Archaeological Survey, Fayetteville.

St. Hoyme, L.E. and M.Y. Iscan

- 1989 Determination of Sex and Race: Accuracy and Assumptions. In *Reconstruction of Life from the Skeleton*, ed. by M. Y. Iscan and K. A. R. Kennedy, 53-94. Alan R. Liss, New York.

Saunders, S. R., and R. A. Lazenby

- n.d. The Links that Bind: The Harvie Family Nineteenth Century Burying Ground. Occasional Papers in Northeastern Archaeology. Copetown Press, Dundas, Ontario. In press.

Sciulli, P. W., and M. Gramly

- 1989 Analysis of the Ft. Laurens, Ohio, Skeletal Sample. *American Journal of Physical Anthropology* 80: 11-24.

Spence, M. W.

- 1989 The Osteology of the Wise Cemetery. Ms. on file, Museum of Indian Archaeology, London, Ontario.

Stewart, T. D.

- 1979 *Essentials of Forensic Anthropology Especially as Developed in the United States*. Charles C. Thomas, Springfield, IL.

Ubelaker, D. H.

- 1978 *Human Skeletal Remains*. Aldine Publishing Co., Chicago.

vanWieringen, J. C.

- 1986 Secular Growth Changes. In *Human Growth: A Comprehensive Treatise*, Volume 3, ed. by F. Falkner and J.M. Tanner, 307-332. 2nd edition. Plenum Press, NY.

Waldron, T., and J. Rogers

- 1987 Iatrogenic Palaeopathology. *Journal of Palaeopathology* 1: 117-129.

Zachariades, N., A. Skordalaki, S. Papanicolaou, and A. Xypolyta

- 1986 Infantile Cortical Hyperostosis: Report of Two Cases. *Journal of Oral and Maxillofacial Surgery* 44: 644-648.

S. Pfeiffer

School of Human Biology
University of Guelph
Guelph, Ontario
Canada N1G 2W1

J. C. Dudar

School of Human Biology
University of Guelph
Guelph, Ontario
Canada N1G 2W1

S. Austin

Archaeological Services Inc.
662 Bathurst Street
Toronto, Ontario
Canada M5S 2R3