

Electronic Thesis and Dissertation Repository

3-19-2019 5:00 PM

Radial Head Stability in Anterior Monteggia Injuries: An In Vitro Biomechanical Study

Armin Badre
The University of Western Ontario

Supervisor
King, Graham J.W.
The University of Western Ontario Co-Supervisor
Johnson, James A.
The University of Western Ontario

Graduate Program in Surgery
A thesis submitted in partial fulfillment of the requirements for the degree in Master of Science
© Armin Badre 2019

Follow this and additional works at: <https://ir.lib.uwo.ca/etd>



Part of the [Orthopedics Commons](#)

Recommended Citation

Badre, Armin, "Radial Head Stability in Anterior Monteggia Injuries: An In Vitro Biomechanical Study" (2019). *Electronic Thesis and Dissertation Repository*. 6051.
<https://ir.lib.uwo.ca/etd/6051>

This Dissertation/Thesis is brought to you for free and open access by Scholarship@Western. It has been accepted for inclusion in Electronic Thesis and Dissertation Repository by an authorized administrator of Scholarship@Western. For more information, please contact wlsadmin@uwo.ca.

Abstract

Anterior Monteggia fracture-dislocations are frequently complicated by persistent radial head instability leading to suboptimal outcomes. In this biomechanical investigation using a cadaveric elbow motion simulator, we examined the effects of ulnar extension angulation, soft tissue disruption, biceps loading and elbow motion on radial head translation. Our results showed significant anterior radial head translation with progressive ulnar extension angulation, with greater soft tissue injuries and increased biceps loading ($P=.000$). There was no significant difference in radial head translation between simulated active and passive elbow flexion ($P=.251$). These findings support the importance of an anatomic reduction of the ulnar fracture. However, in cases with significant soft tissue disruption, even an anatomic reduction of the ulna may not be sufficient to restore radial head alignment. Moreover, postoperative immobilization with the elbow in a flexed position to avoid elbow motion and to relax the biceps should be considered in patients with unstable Monteggia injuries.

Keywords

Monteggia, Radial Head, Subluxation, Dislocation, Instability, Anterior, Angulation, Annular Ligament, Interosseous Membrane

Co-Authorship Statement

Chapter 1:

Sole Author: Armin Badre

Manuscript Review: Kenneth Faber, Jim Johnson, Graham King

Chapter 2:

Study Design: Armin Badre, David Axford, Clare Padmore, Kenneth Faber, Jim Johnson, Graham King

Specimen Preparation: Armin Badre

Data Collection: Armin Badre, David Axford, Clare Padmore, Carolyn Berkmortel

Data Analysis: Armin Badre, Clare Padmore

Statistical Analysis: Armin Badre

Manuscript Preparation: Armin Badre

Manuscript Review: Kenneth Faber, Jim Johnson, Graham King

Chapter 3:

Study Design: Armin Badre, David Axford, Clare Padmore, Kenneth Faber, Jim Johnson, Graham King

Specimen Preparation: Armin Badre

Data Collection: Armin Badre, David Axford, Clare Padmore, Carolyn Berkmortel

Data Analysis: Armin Badre, Clare Padmore

Statistical Analysis: Armin Badre

Manuscript Preparation: Armin Badre

Manuscript Review: Kenneth Faber, Jim Johnson, Graham King

Chapter 4:

Sole Author: Armin Badre

Manuscript Review: Kenneth Faber, Jim Johnson, Graham King

Acknowledgments

This project would not have been possible without the hard work, dedication and generous support of many individuals. First and foremost, I would like to thank my supervisors, Dr. Graham King and Dr. Jim Johnson. They provided me with unparalleled support, mentorship and guidance throughout my training at the Roth-McFarlane Hand and Upper Limb Centre. It is not only their knowledge and expertise but their attitude and collaboration that makes this a world-class facility. I am humbled to have had the opportunity to work with these world leaders and am grateful for the opportunities they have given me. I would also like to thank Dr. Ken Faber who was part of my advisory committee and provided invaluable input in the design of this project and with manuscript review.

I would like to sincerely thank my research partners David Axford, Clare Padmore and Carolyn Berkmortel for all their help and efforts throughout this project. David, thank you for your impressive work on designing the jig for this project and for operating and troubleshooting the elbow simulator. Clare, thank you for bringing your expertise in optical tracking to the elbow team and for all your hard work in developing the programs required for our data analysis. Carolyn, thank you for all your help running the optical tracking program on testing days.

I would also like to thank our visiting medical student, Sheyla Abdic, for coming in early on some of the testing days to help me with specimen preparation.

I would like to express my deepest gratitude to my parents who have been my biggest role model and inspired me to work hard in achieving my goals.

Dedication

This manuscript is dedicated to my beautiful, loving and supportive wife Jillian Popel and our daughter Layla who is the pride and joy of our lives. I immensely appreciate all of my wife's support throughout my training and particularly in the last few months while completing this project.

Table of Contents

Radial Head Stability in Anterior Monteggia Injuries: An <i>In Vitro</i> Biomechanical Study .	i
Abstract	ii
Co-Authorship Statement.....	iii
Acknowledgments.....	iv
Dedication	iv
Table of Contents	v
List of Tables.....	viii
List of Figures	ix
Chapter 1	1
1 Introduction.....	1
1.1 Elbow and Forearm Anatomy.....	1
1.1.1 Bony Anatomy	1
1.1.2 Musculature.....	7
1.1.3 Capsular and Ligamentous Anatomy.....	10
1.2 Biomechanics of the Elbow and Forearm.....	15
1.2.1 Kinematics	15
1.2.2 Stability.....	17
1.3 Monteggia Injuries	18
1.3.1 Description.....	18
1.3.2 Proposed Mechanisms of Type I Monteggia Injuries	19
1.3.3 Management and Outcome of Monteggia Injuries	22
1.3.4 Current Biomechanical Studies.....	23
1.4 Thesis Rationale.....	25
1.5 Objectives & Hypotheses.....	26

1.6 Thesis Overview	27
1.7 References	28
Chapter 2	33
2 Effects of Ulnar Angulation and Soft Tissue Sectioning on Radial Head Stability in Anterior Monteggia Injuries.....	33
2.1 Introduction.....	33
2.2 Materials and Methods.....	35
2.2.1 Specimen Preparation	35
2.2.2 Experimental Motion Simulation and Testing Protocol	36
2.2.3 Kinematic Data Acquisition.....	39
2.2.4 Statistical Methods.....	41
2.3 Results.....	43
2.4 Discussion.....	50
2.5 Conclusions.....	54
2.6 References.....	55
Chapter 3	59
3 The Role of Biceps Loading and Muscle Activation on Radial Head Stability in Anterior Monteggia Injuries.....	59
3.1 Introduction.....	59
3.2 Materials and Methods.....	61
3.2.1 Specimen Preparation	61
3.2.2 Experimental Simulation	61
3.2.3 Testing Protocol	62
3.2.4 Kinematic Data Acquisition.....	63
3.2.5 Statistical Methods.....	64
3.3 Results.....	65

3.4 Discussion	70
3.5 Conclusions	73
3.6 References	74
Chapter 4	78
4 Thesis Conclusions	78
4.1 Summary of Chapter 2: Effects of Ulnar Angulation and Soft Tissue Sectioning on Radial Head Stability in Anterior Monteggia Injuries	79
4.2 Summary of Chapter 3: The Role of Biceps Loading and Muscle Activation on Radial Head Stability in Anterior Monteggia Injuries	81
4.3 Future Directions	82
4.4 References	83
Appendix 1: Glossary of Terms	84
Curriculum Vitae	86

List of Tables

Table 3.1: Effect of Biceps Loading on Radial Head Translation	67
Table 3.2: Effect of Muscle Activation on Radial Head Translation	69

List of Figures

Figure 1.1: Elbow Joint Articulations.....	1
Figure 1.2: Bony Anatomy of the Elbow Joint.....	2
Figure 1.3: Bony Anatomy of the Distal Humerus.....	3
Figure 1.4: Bony Anatomy of the Proximal Radius.....	4
Figure 1.5: Bony Anatomy of the Proximal Ulna.....	4
Figure 1.6: Articulations Between the Radius and Ulna.....	5
Figure 1.7: Coronal and Sagittal Orientations of the Proximal Ulna.....	6
Figure 1.8: Coronal and Sagittal Orientations of the Radial Shaft.....	7
Figure 1.9: Coronal Orientation of the Proximal Radius.....	7
Figure 1.10: Anterior Forearm Compartment Musculature.....	8
Figure 1.11: Posterior Forearm Compartment Musculature.....	9
Figure 1.12: The Supinator Muscle.....	9
Figure 1.13: Mobile Wad Musculature.....	10
Figure 1.14: Capsular Anatomy of the Elbow Joint.....	11
Figure 1.15: Lateral Collateral Ligament (LCL) of the Elbow.....	12
Figure 1.16: Anatomy of the Quadratus Ligament.....	12
Figure 1.17: Medial Collateral Ligament (MCL) of the Elbow.....	13
Figure 1.18: Interosseous Membrane (IOM) Anatomy.....	14
Figure 1.19: Flexion-Extension of the Elbow.....	15

Figure 1.20: Pronation-Supination of the Forearm.	16
Figure 1.21: Flexion-Extension Axis of the Elbow Joint.	16
Figure 1.22: Radiograph of Monteggia Fracture-Dislocation.....	18
Figure 1.23: Bado Classification of Monteggia Injuries.....	19
Figure 1.24: Evan’s Proposed Theory of Monteggia Injuries.....	20
Figure 1.25: Tompkins’ Proposed Theory of Monteggia Injuries.	22
Figure 2.1: Elbow Motion Simulator.....	36
Figure 2.2: Custom Designed Jig.....	39
Figure 2.3: Optotrak Motion Capture Camera System.	40
Figure 2.4: Radial Head Translation.	41
Figure 2.5: Radial head translation with progressive ulnar angulation of elbows with intact soft tissues during active elbow flexion.....	44
Figure 2.6: Effect of ulnar angulation on radial head translation with intact soft tissues.....	45
Figure 2.7: Radial head translation with progressive ulnar angulation in stage 1-4 soft tissue sectioning during active elbow flexion.	46
Figure 2.8: Effect of ulnar angulation and soft tissue sectioning on radial head translation.	47
Figure 2.9: Radial head translation with progressive soft tissue sectioning in 0°-30° of ulnar angulation during active elbow flexion.....	48
Figure 2.10: A three-dimensional representation of anterior radial head translation during elbow flexion with ulnar osteotomy at 20° of extension angulation and stage 3 soft tissue sectioning..	49
Figure 3.1: Radial head translation with staircase biceps loading.	66

Figure 3.2: Average radial head translation throughout the simulated active and passive elbow flexion. 68

Chapter 1

1 Introduction

The purpose of this thesis is to investigate the factors that affect the radial head stability in anterior Monteggia injuries using an in vitro biomechanical model.

This chapter reviews the relevant anatomy and biomechanics of the elbow joint. An overview of Monteggia fracture-dislocations with a focus on their patterns, proposed mechanisms of injury, management and outcomes are also presented. Finally, the rationale, objectives, hypotheses of this thesis are summarized.

1.1 Elbow and Forearm Anatomy

1.1.1 Bony Anatomy

The elbow joint is comprised of three articulations: the radiocapitellar, the ulnohumeral and the proximal radioulnar articulations (Figure 1.1). These articulations allow for flexion-extension of the elbow and supination-pronation of the forearm.

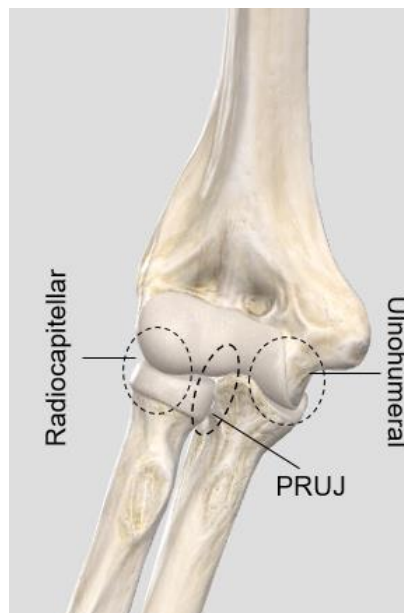


Figure 1.1: Elbow Joint Articulations.

The radiocapitellar, the ulnohumeral and the PRUJ are the three articulations that make up the elbow joint.

The three bones that contribute to these articulations are the distal humerus, the radial head and the proximal ulna (Figure 1.2). The articular surface of the distal humerus is formed by the capitellum laterally and the trochlea medially (Figure 1.3). The medial column contains the prominent medial epicondyle which serves as the origin of the medial collateral ligament (MCL) and the flexor-pronator muscle group. The lateral column contains the lateral epicondyle which serves as the origin of the lateral collateral ligament (LCL) and the supinator-extensor muscle group. Anteriorly, the radial fossa and the coronoid fossa accommodate the radial head and the coronoid process during maximal flexion of the elbow. Posteriorly, the olecranon fossa accommodates the olecranon process during maximal extension of the elbow.

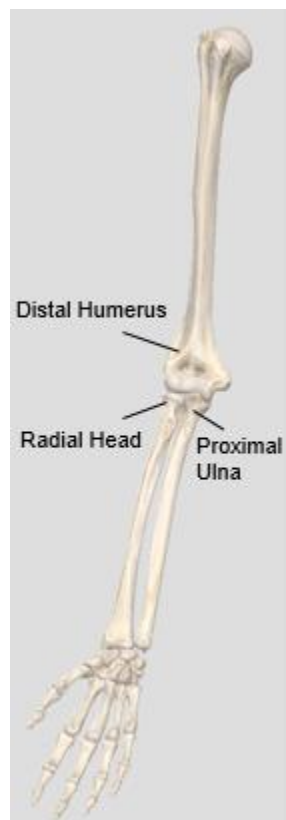


Figure 1.2: Bony Anatomy of the Elbow Joint.

The distal humerus, the radial head, and the proximal ulna form the three articulations of the elbow joint.

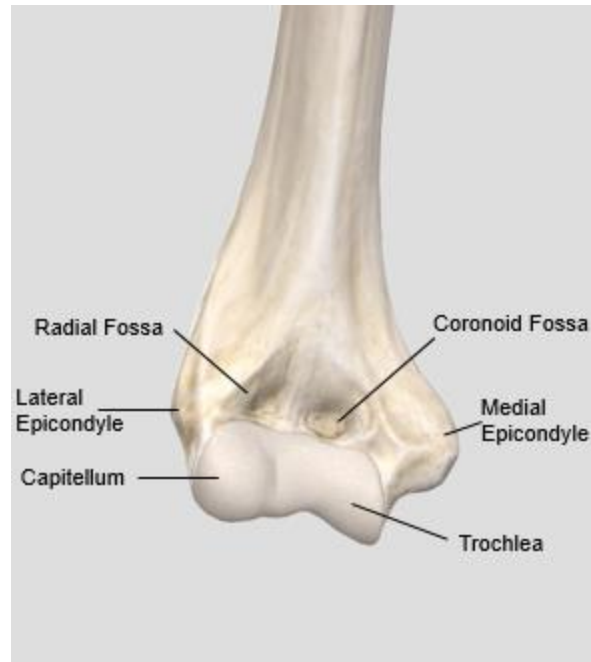


Figure 1.3: Bony Anatomy of the Distal Humerus.

The capitellum and trochlea form the articular surface of the distal humerus. The medial and lateral epicondyles serve as the origin of the flexor-pronator and the supinator-extensor muscle groups respectively. The anterior surface of the distal humerus contains the radial and coronoid fossae.

The proximal radius consists of the radial head, the radial neck and the radial tuberosity (Figure 1.4). The radial head has an elliptical articular surface with a central depression that allows articulation with the capitellum and forms the radiocapitellar articulation. The radial tuberosity (i.e. bicipital tuberosity) serves as the insertion of the biceps tendon.

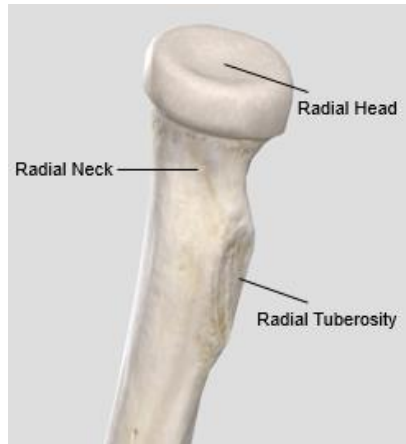


Figure 1.4: Bony Anatomy of the Proximal Radius.

The radial head articulates with the capitellum and the lesser sigmoid notch. The radial tuberosity is the site of insertion of the biceps brachii tendon.

The proximal ulna consists of the greater sigmoid notch, the lesser sigmoid notch (i.e. radial fossa of the proximal ulna), the olecranon process and the coronoid process (Figure 1.5). The greater sigmoid notch is the concave surface between the olecranon and the coronoid processes that articulates with the trochlea of the distal humerus and forms the ulnohumeral articulation. On the lateral aspect of the coronoid process, the lesser sigmoid notch articulates with the peripheral articular portion of the radial head and forms the proximal radioulnar joint (PRUJ). The olecranon process serves as the insertion of the triceps tendon. The coronoid process resists against posterior elbow instability and serves as the attachment of the brachialis tendon.

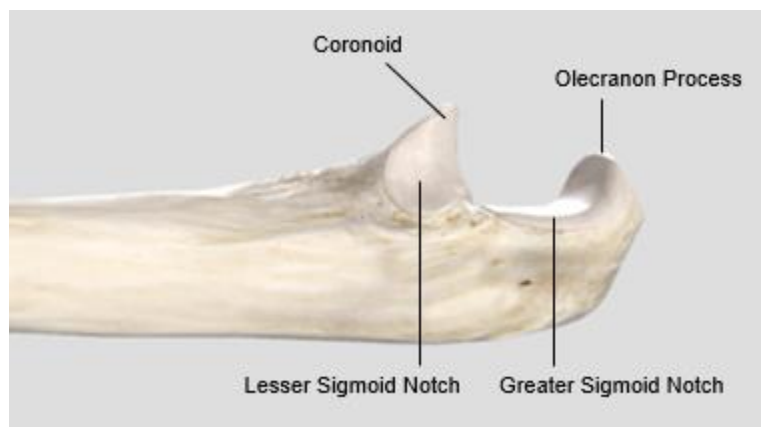


Figure 1.5: Bony Anatomy of the Proximal Ulna.

The greater sigmoid notch articulates with the trochlea while the lesser sigmoid notch articulates with the radial head. The coronoid and olecranon processes are also shown.

The forearm consists of two long bones, the radius and the ulna (Figure 1.6). In addition to their proximal articulation at the PRUJ, the radius and ulna articulate distally through the distal radioulnar joint (DRUJ).

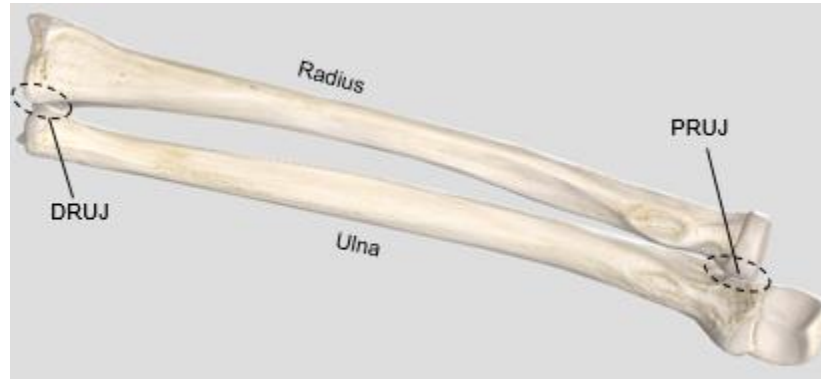

Figure 1.6: Articulations Between the Radius and Ulna.

The radius and the ulna articulate proximally at the PRUJ and distally at the DRUJ.

The proximal ulnar diaphysis has complex anatomy. In the sagittal plane, there is a proximal ulnar dorsal angulation (PUDA) averaging 5.7° with the apex of this angulation at an average of 47mm from the tip of the olecranon (Figure 1.7).¹ In the coronal plane, there is a varus bow averaging 17.7° with the apex at an average of 85mm from the tip of the olecranon (Figure 1.7).² The middle and distal portions of the ulnar diaphysis are relatively straight in the sagittal and coronal planes.

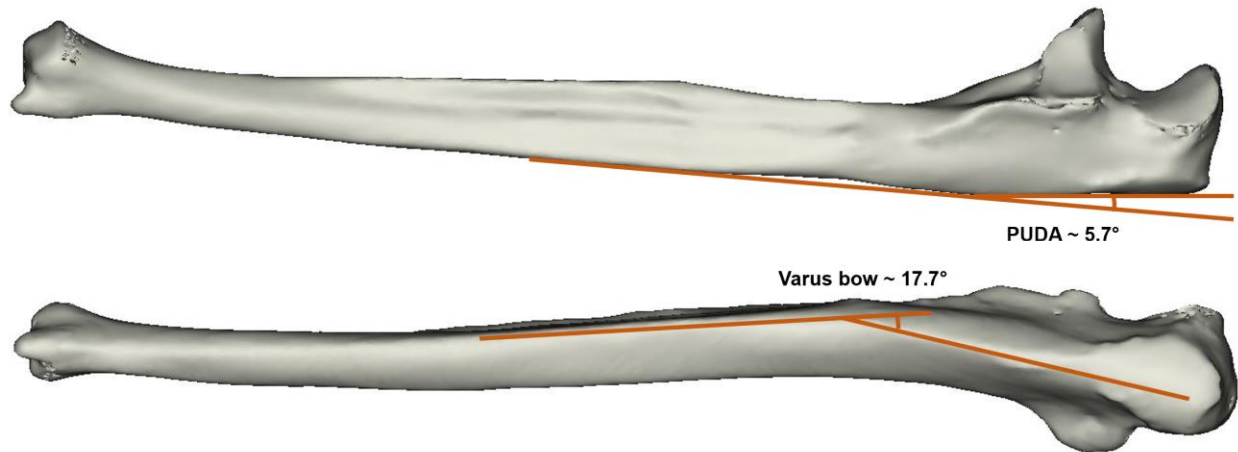


Figure 1.7: Coronal and Sagittal Orientations of the Proximal Ulna.

In the coronal plane, the proximal ulna has a varus bow. To quantify this varus angulation and determine its apex, two tangent lines are drawn, one collinear with the longitudinal axis of the olecranon and another collinear with the longitudinal axis of the ulnar shaft. In the sagittal plane, the proximal ulna has a dorsal angulation, PUDA. To quantify this dorsal angulation and determine its apex, two tangent lines are drawn, one along the dorsal aspect of the olecranon and another along the dorsal aspect of the ulna shaft.³

The radial diaphysis also has a bow in the sagittal and coronal planes. In the sagittal plane, there is an apex dorsal bow averaging 4.7° which is located at an average distance of 11.7cm from the radial head (Figure 1.8).⁴ In the coronal plane, the radius has an average bow of 10.3° located approximately in the middle third of the radius (Figure 1.8).⁴ Moreover, the radial neck is not collinear with the rest of the radial shaft and is angulated approximately 15° away from the radial tuberosity (Figure 1.9).⁵

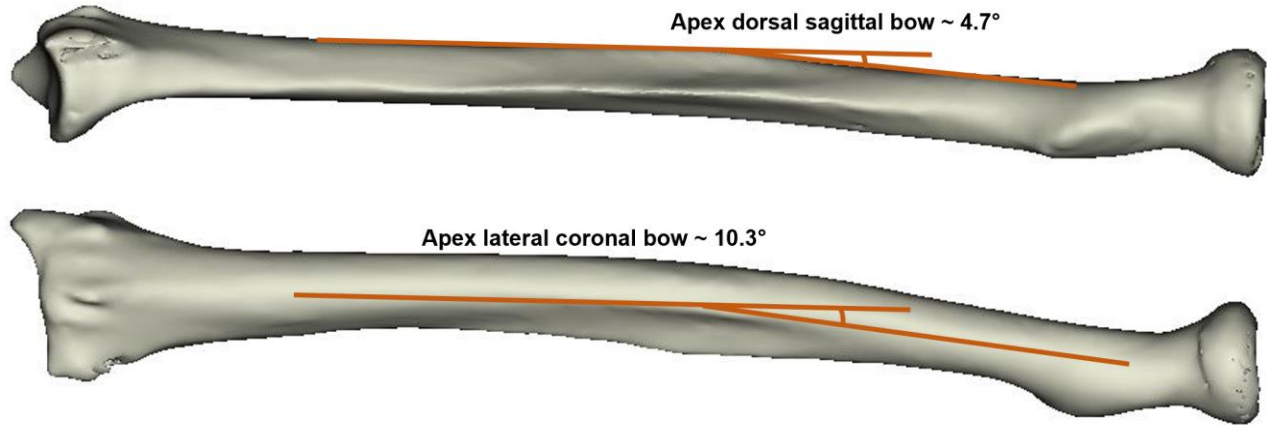


Figure 1.8: Coronal and Sagittal Orientations of the Radial Shaft.

In the coronal plane, the radial shaft has an apex lateral bow. In the sagittal plane, the radial shaft has an apex dorsal bow.

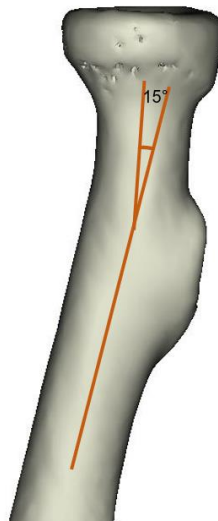


Figure 1.9: Coronal Orientation of the Proximal Radius.

In the coronal plane, the radial neck angulates about 15° from the radial shaft.⁵

1.1.2 Musculature

Muscles of the anterior compartment of the arm and forearm are primarily involved in elbow flexion, forearm pronation, wrist flexion and finger flexion (Figure 1.10). The main flexors of the elbow in the anterior compartment are the biceps brachii and the brachialis. Biceps brachii inserts at the bicipital tuberosity of the proximal radius. Brachialis inserts on the coronoid process and the

tuberosity of the ulna. The flexor-pronator muscle group originates from the medial epicondyle. The pronator teres (PT) is the main pronator of the forearm with a weak contribution to elbow flexion. The flexor carpi radialis (FCR), flexor carpi ulnaris (FCU), and the flexor digitorum superficialis (FDS) also originate from the medial epicondyle and primarily contribute to the wrist and finger flexion.

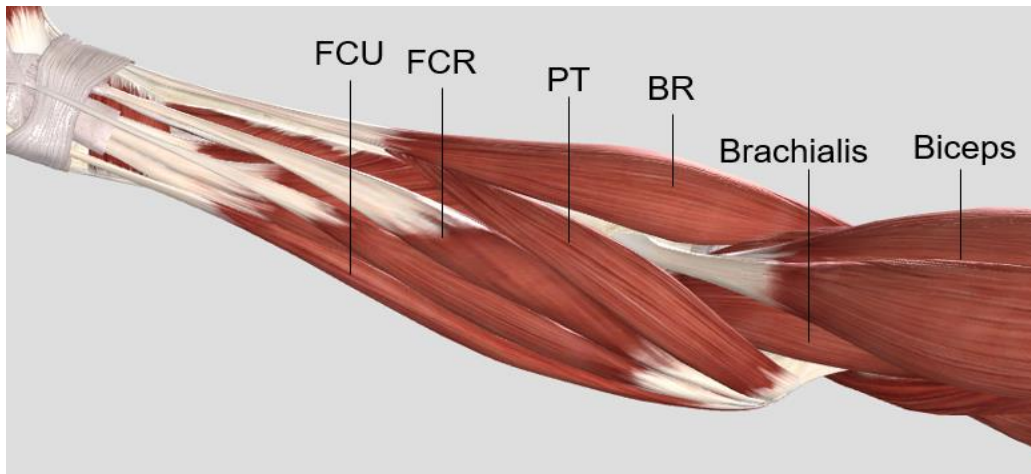


Figure 1.10: Anterior Forearm Compartment Musculature.

Muscles of the anterior compartment of the forearm are shown. BR: brachioradialis, PT: pronator teres, FCR: flexor carpi radialis, FCU: flexor carpi ulnaris

Muscles of the posterior compartment of the arm and forearm are primarily involved in elbow extension, forearm supination, wrist extension and finger extension (Figure 1.11). The main extensor of the elbow is the triceps brachii. The anconeus muscle also contributes to elbow extension. The extensor-supinator muscle group originates from the lateral epicondyle. The extensor carpi ulnaris (ECU), and the extensor digitorum communis (EDC) primarily contribute to the wrist and finger extension. The supinator muscle also originates from the lateral epicondyle and along with the biceps is one the main supinators of the forearm (Figure 1.12).

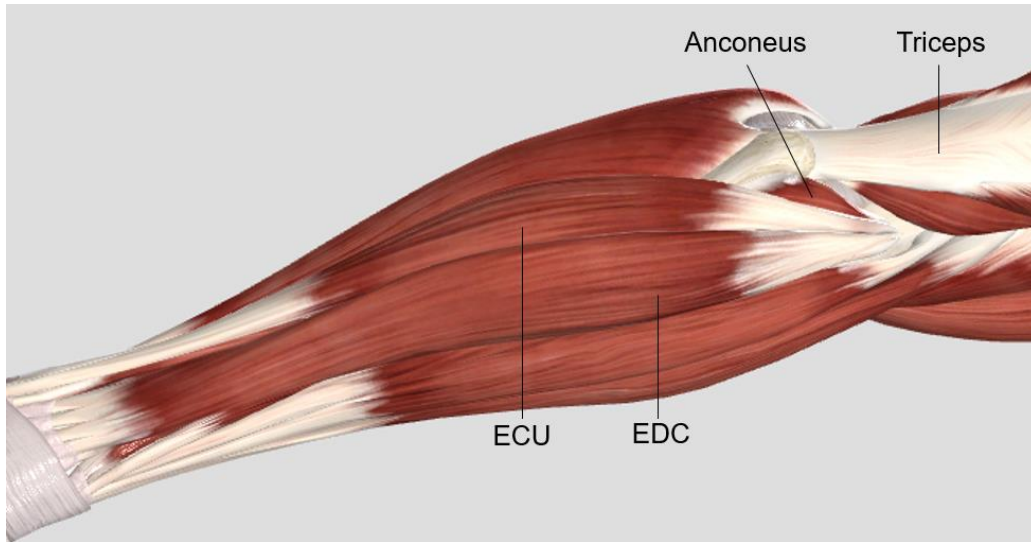


Figure 1.11: Posterior Forearm Compartment Musculature.

Muscles of the posterior compartment of the forearm are shown. EDC: extensor digitorum communis, ECU: extensor carpi ulnaris

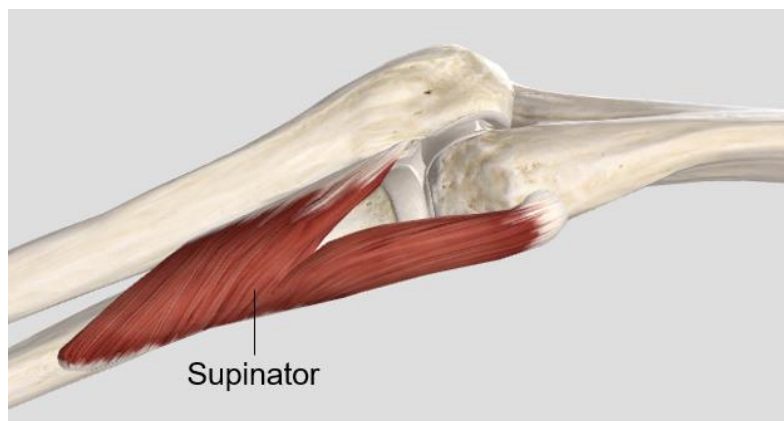


Figure 1.12: The Supinator Muscle.

The supinator muscle is located deep within the posterior compartment of the forearm.

The mobile wad is composed of the brachioradialis (BR), the extensor carpi radialis longus (ECRL), and the extensor carpi radialis brevis (ECRB) (Figure 1.13). The brachioradialis contributes to elbow flexion. The ECRL and ECRB contribute to wrist extension.

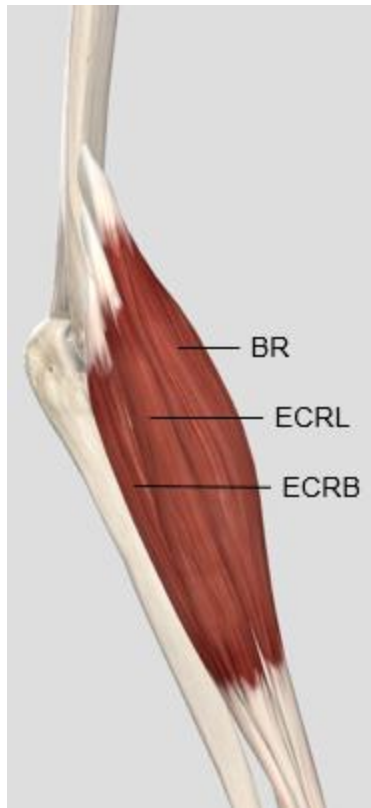

Figure 1.13: Mobile Wad Musculature.

Muscles of the mobile wad compartment of the forearm are shown. BR: brachioradialis, ECRL: extensor carpi radialis longus, ECRB: extensor carpi radialis brevis

1.1.3 Capsular and Ligamentous Anatomy

The elbow joint capsule surrounds all three articulations and is one of the static stabilizers of the elbow joint. The anterior capsule is attached proximally to the anterior aspect of the distal humerus just proximal to the coronoid and radial fossa and is attached distally onto the coronoid process and the annular ligament (Figure 1.14). The posterior capsule is attached proximally to the posterior aspect of the distal humerus just proximal to the olecranon fossa and is attached distally along the medial and lateral articular margins of the sigmoid notch (Figure 1.14). The collateral ligaments of the elbow are formed by the thickening of the medial and lateral joint capsule.

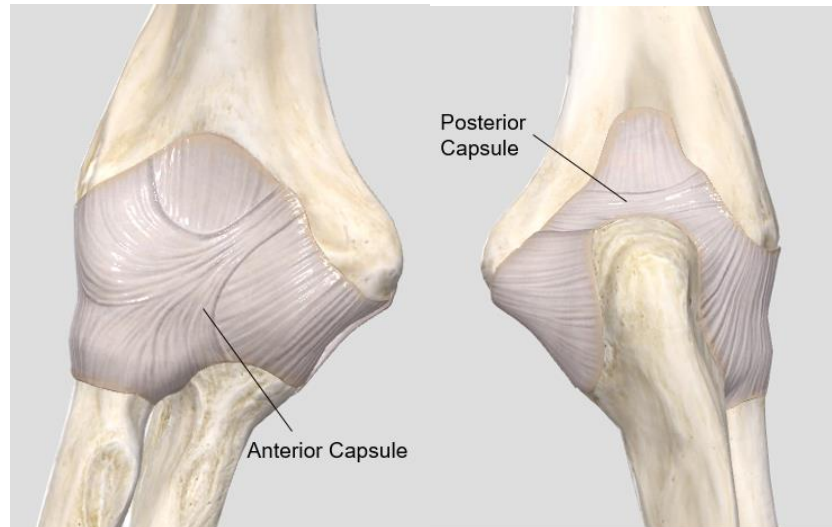


Figure 1.14: Capsular Anatomy of the Elbow Joint.

Figure 1.13a shows the anterior capsule covering the elbow joint articulations. Figure 1.13b shows the posterior capsule covering the elbow joint articulations.

The main components of the lateral collateral ligament (LCL) include the radial collateral ligament (RCL), the annular ligament, and the lateral ulnar collateral ligament (LUCL) (Figure 1.15).⁶ The RCL originates from the lateral epicondyle and inserts into the annular ligament. The annular ligament originates and inserts on the anterior and posterior margins of the lesser sigmoid notch. The LUCL originates from the lateral epicondyle and inserts onto the crista supinatoris of the ulna. The quadrate ligament, which is a thickening of the fibrous capsule of the elbow joint, lies just distal to the annular ligament. It extends from the lateral side of the ulna just distal to the PRUJ to the neck of the radius just distal to the articular margin (Figure 1.16).^{7,8} Some authors have described other portions of the LCL complex, including the accessory lateral collateral ligament, and the oblique cord.^{7,9,10} These structures are variably present, and their role is less well-defined. The LCL is the main stabilizer against the varus and posterolateral rotatory instability (PLRI) of the elbow.

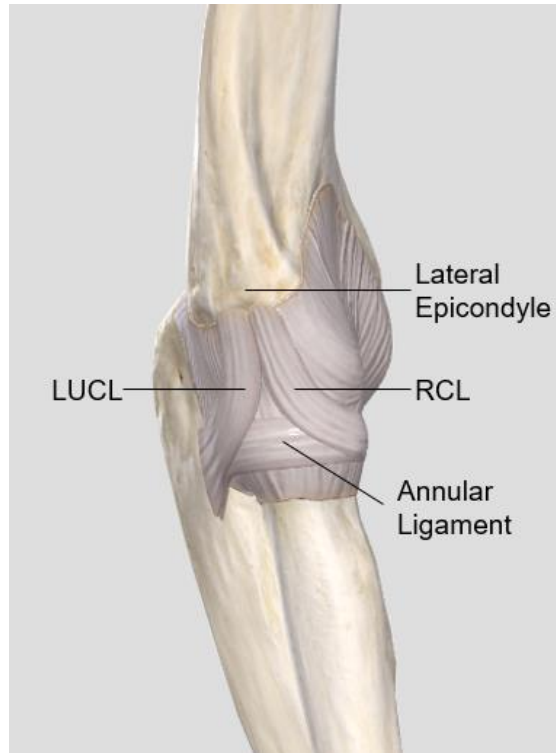


Figure 1.15: Lateral Collateral Ligament (LCL) of the Elbow.

The main components of the LCL are shown. RCL: radial collateral ligament, LUCL: lateral ulnar collateral ligament

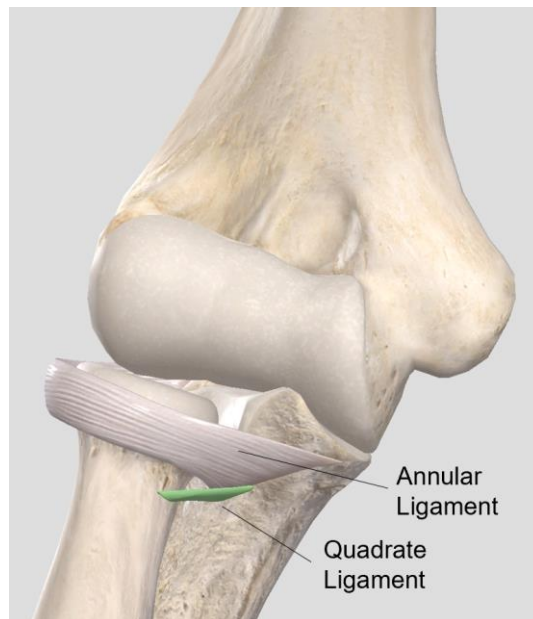


Figure 1.16: Anatomy of the Quadratum Ligament.

The Quadratum ligament is shown distal to the annular ligament.

The medial collateral ligament (MCL) is composed of three components: the anterior bundle, the posterior bundle and the transverse segment (Figure 1.17).⁶ The anterior bundle of the MCL originates from the anteroinferior surface of the medial epicondyle and inserts on the sublime tubercle of the coronoid. The anterior bundle is the most discrete and strongest portion of the MCL. The posterior bundle is a thickening of the medial capsule and inserts along the midportion of the medial margin of the greater sigmoid notch. The transverse segment is oriented horizontally between the coronoid and the tip of the olecranon. The MCL is the main constraint against the valgus instability of the elbow.

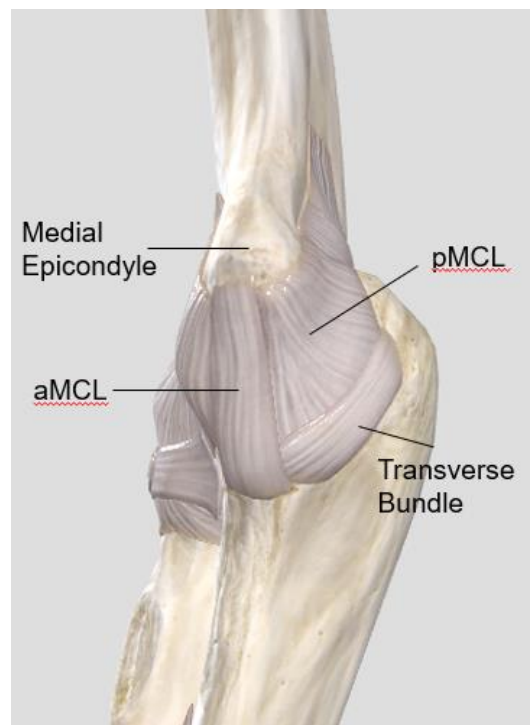


Figure 1.17: Medial Collateral Ligament (MCL) of the Elbow.

The components of the MCL are shown. aMCL: anterior bundle of the MCL, pMCL: posterior bundle of the MCL

The interosseous membrane (IOM) is a fibrous structure located deep in the forearm that connects the radius and ulna (Figure 1.18). It consists of three portions: the proximal membranous portion, the middle ligamentous complex and the distal portion. The proximal portion is comprised of the proximal oblique cord and the dorsal oblique cord.¹¹⁻¹³ The proximal oblique cord originates from the anterolateral aspect of the coronoid process and inserts just distal to the radial tuberosity.¹¹ The dorsal oblique cord originates from the junction of the proximal third and distal two-thirds of the

ulna and inserts into the interosseous crest of the radius.¹¹ The middle portion is comprised of the central band (CB) and the accessory band (AB).^{11,14} The central band is one of the most important functional components of IOM and is oriented obliquely from proximal-radial to distal-ulnar. Its radial origin lies at approximately 60% of the length of the radius from the styloid.¹⁵ The ulnar insertion is at approximately the junction of the middle two-thirds and the distal one-third of the ulna.¹⁵ The distal portion is comprised of the distal oblique bundle (DOB).¹¹ It originates from the ulna at approximately the level of the pronator quadratus and inserts along the inferior rim of the sigmoid notch and the DRUJ capsule.^{11,15} In addition to its role in the elbow and DRUJ stability, the IOM functions to transfer load from the radius to the ulna.^{16,17} At the wrist, most of the axial load is transmitted through the radius. In neutral rotation, 82% of the axial load is transmitted through the radiocarpal joint and 18% is transmitted through the ulnocarpal joint.¹⁸ The IOM shifts the load from the radius to the ulna such that at the elbow 70% of the axial load is borne by the radiocapitellar joint and 30% by the ulnohumeral joint with the forearm in neutral rotation.¹⁹

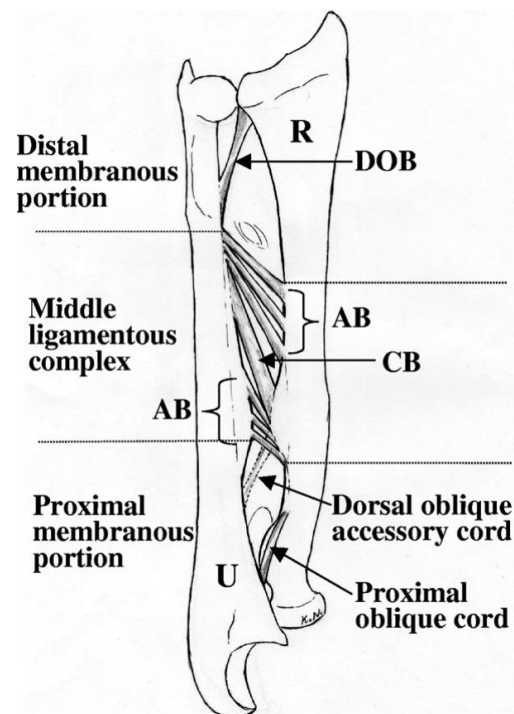


Figure 1.18: Interosseous Membrane (IOM) Anatomy.

Components of the proximal, middle and distal portions of the IOM are depicted. AB: accessory band, CB: central band, DOB: distal oblique bundle. “Reprinted from Noda K, Goto A, Murase T, Sugamoto K, Yoshikawa H, Moritomo H. Interosseous Membrane of the Forearm: An Anatomical Study of Ligament Attachment Locations, J Hand Surg Am. 2009; 34(3):415-422, with permission from Elsevier”

1.2 Biomechanics of the Elbow and Forearm

1.2.1 Kinematics

The elbow is a trochoginglymoid joint with two degrees of freedom: flexion-extension (Figure 1.19) and pronation-supination (Figure 1.20). The flexion-extension axis of the elbow passes through the centre of the arcs of capitellum and trochlea. Studies have shown variability in the flexion axis with the active and passive range of motion as well as forearm rotation.^{20,21} The average flexion axis is 3° to 8° internally rotated relative to the transepicondylar axis and is in 4° to 8° of valgus in relation to the long axis of the humerus (Figure 1.21).²²

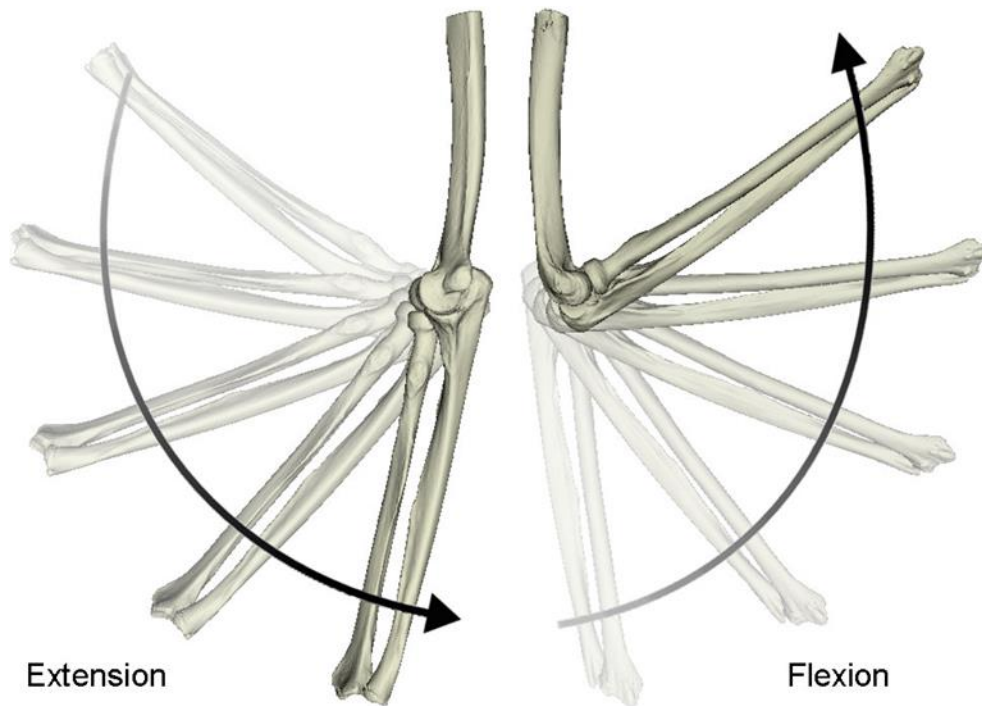


Figure 1.19: Flexion-Extension of the Elbow.

Medial (left) and lateral (right) views of a right elbow showing the flexion-extension arc of the elbow.²³

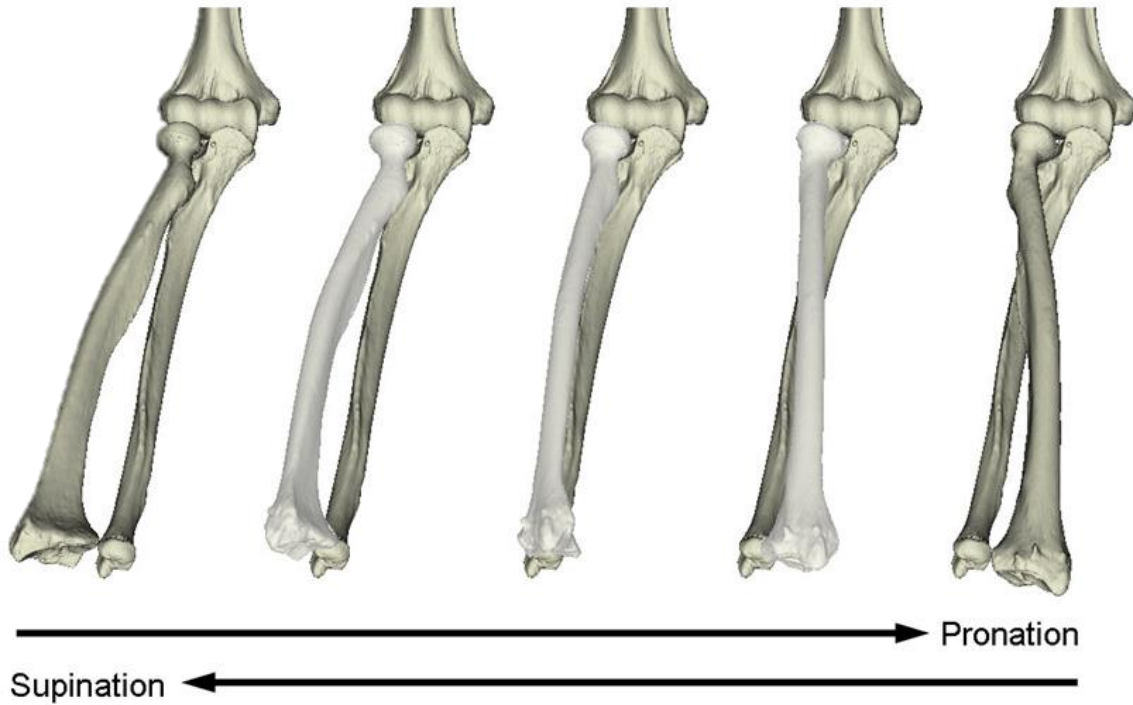


Figure 1.20: Pronation-Supination of the Forearm.

Anterior view of a right elbow showing the supination-pronation arc of forearm rotation.²³

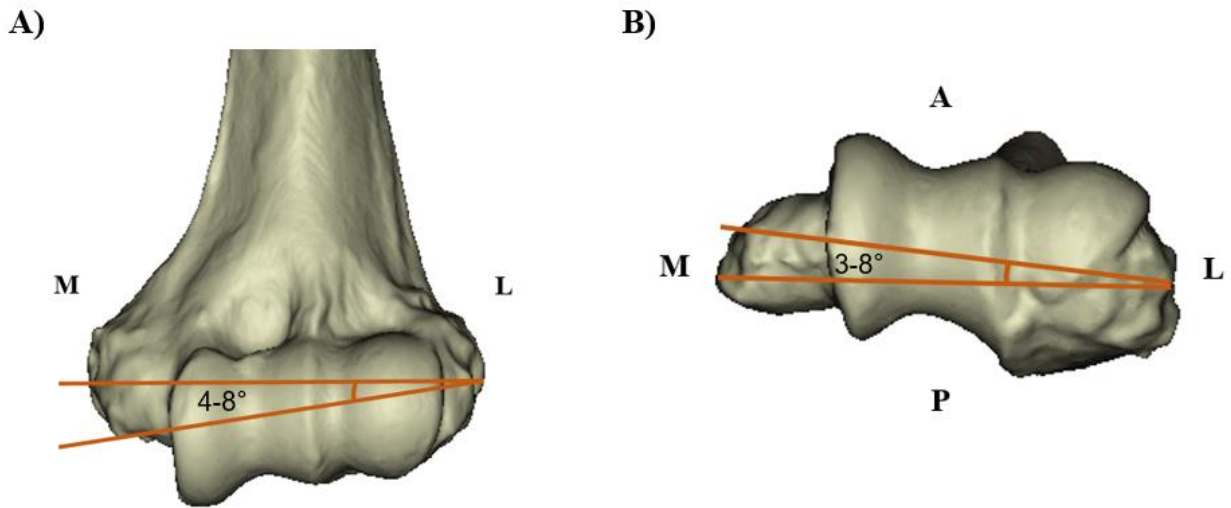


Figure 1.21: Flexion-Extension Axis of the Elbow Joint.

A) showing the coronal view of the distal humerus with the flexion-extension axis in 4-8° of valgus.

B) showing the axial view of the distal humerus with the flexion-extension axis in 3-8° of internal rotation.

M: medial side, L: lateral side, A: anterior side and P: posterior side.

The radiocapitellar and proximal radioulnar joints allow for pronation-supination. The axis of rotation of the forearm is from the centre of the radial head to the centre of the distal ulna. This axis of rotation is independent of the elbow position.^{24,25}

1.2.2 Stability

Both osseous and soft tissue structures contribute to elbow stability. The primary static stabilizers of the elbow are the ulnohumeral articulation and the medial and lateral collateral ligaments.^{17,26,27} Secondary static stabilizers are the radial head, joint capsule, flexor-pronator origin and extensor-supinator muscle origin.^{17,26,27} Dynamic stability is provided by the muscles that cross the elbow joint including the biceps brachii, brachialis, brachioradialis, triceps and the anconeus muscles.^{17,26-28}

Although numerous studies have investigated the role of structures that contribute to elbow stability, the structures that contribute to radial head stability within the radiocapitellar articulation and the PRUJ have not been fully explored. The annular ligament, interosseous membrane and the quadratus ligament have been proposed to play an important role in radial head stability.^{7,8,29-31} In a cadaveric anatomic study, Spinner and Kaplan showed that with an intact ulna, anterior dislocation of the radial head was only possible if the annular ligament, the posterior border of the quadratus ligament and the proximal third of the IOM were all sectioned.⁷ In a cadaveric biomechanical investigation examining radial head stability after sequential sectioning of the annular ligament, proximal IOM, central band and the distal IOM, Anderson and colleagues found significant radial head instability only after sectioning of the central band.³⁰ Moreover, they concluded that the order in which the soft tissues were sectioned (proximal to distal versus distal to proximal) did not significantly affect the radial head stability. However, another biomechanical study found significant radial head instability after the anterior joint capsule, annular ligament, quadratus ligament and the proximal half of the IOM were all sectioned.³¹ A significant limitation of these studies is that the cadaveric specimens were dissected free of all muscles and tendons; thus, the effects of these structures on radial head stability were not accounted for.

1.3 Monteggia Injuries

1.3.1 Description

Giovanni Monteggia first described a fracture of the proximal third of the ulna and an anterior dislocation of the radial head in 1814 (Figure 1.22).³² Louis Bado later expanded the definition of Monteggia fractures by classifying these lesions into 4 categories based on the location of the ulnar fracture, the direction of radial head displacement and the presence or absence of a concomitant proximal radius fracture (Figure 1.23).³³ Type I Monteggia injuries represent an apex anterior fracture of the proximal or middle third of the ulna and anterior dislocation of the radial head. Type II injuries represent an apex posterior fracture of the proximal or middle third of the ulna with posterior or posterolateral dislocation of the radial head. Type III injuries represent a fracture of the ulnar metaphysis with anterolateral dislocation of the radial head. Type IV injuries represent a fracture of the proximal radial shaft at the same level as the ulnar shaft fracture along with anterior dislocation of the radial head. Type I injuries are the most common type of Monteggia fracture in children; whereas type II injuries are the most common type in adults.³⁴ With regards to fracture characteristics, Ramski and colleagues in a multicenter study demonstrated that the most common location of the ulnar fracture was in the proximal third followed by the middle third of the ulna.³⁵ Moreover, the mean ulnar angulation was $19.6^{\circ} \pm 14.4^{\circ}$ based on the radiographs.³⁵

The focus of this thesis is on type I Monteggia injuries and the details provided are related only to this subtype of Monteggia injuries.

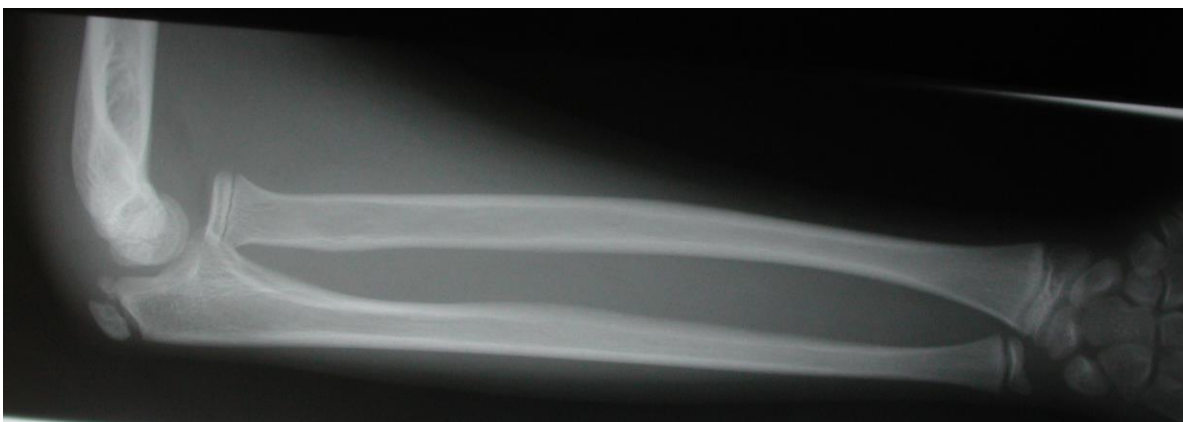


Figure 1.22: Radiograph of Monteggia Fracture-Dislocation.

Lateral radiograph showing proximal ulna fracture and anterior radial head dislocation.

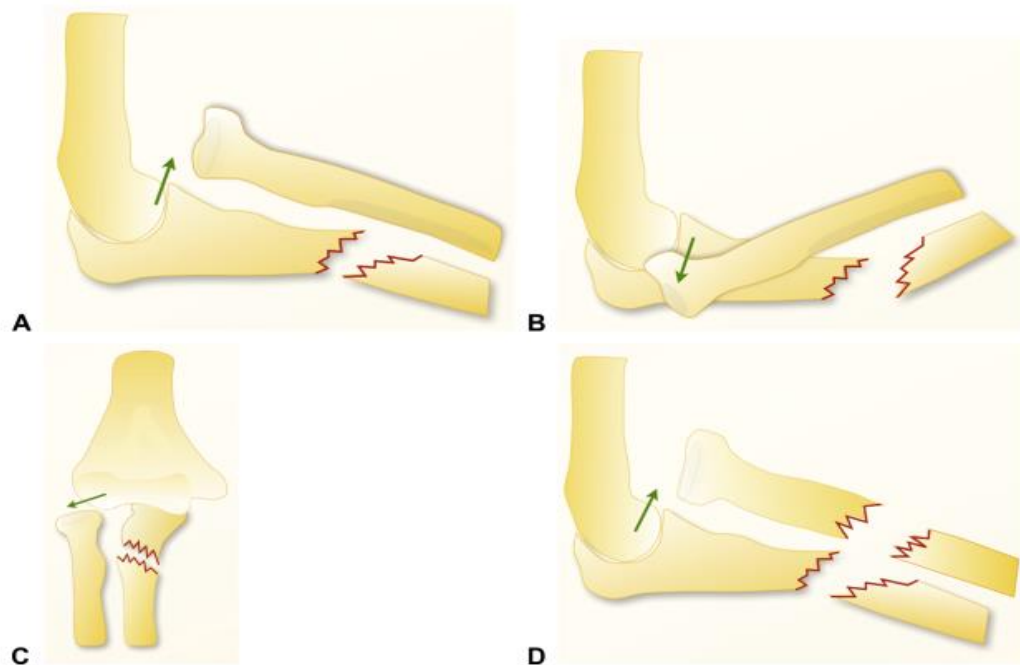


Figure 1.23: Bado Classification of Monteggia Injuries.

A) shows a type I Monteggia with an apex anterior ulna fracture and an anterior radial head dislocation. B) shows a type II Monteggia with an apex posterior ulna fracture and a posterior radial head dislocation. C) shows a type III Monteggia with metaphyseal ulna fracture and an anterolateral radial head dislocation. D) shows a type IV Monteggia with proximal radial shaft fracture at the same level as the ulnar shaft fracture and an anterior radial head dislocation. “Reprinted from Rehim S A, Maynard M A, Sebastin S J, Chung K C. Monteggia Fracture Dislocations: A Historical Review, J Hand Surg Am, 39(7): 1384-1394, with permission from Elsevier”

1.3.2 Proposed Mechanisms of Type I Monteggia Injuries

In 1940, Speed and Boyd proposed that Monteggia fractures are the result of a direct blow to the forearm which fractures the ulna at the point of impact and forces the radial head anteriorly.³⁶ Other authors have argued that this direct blow mechanism is unlikely for several reasons and may only occur in exceptional cases.³⁷ If these injuries were due to a direct blow, one would expect severe bruising or open injuries at the site of impact which are rare. Moreover, more comminution would be expected if the ulna fracture was due to a direct impact. In addition to a strong anterior radiocapitellar capsule, this joint is also protected by the supinator and brachialis muscles; thus, it would be unlikely for a direct blow force to be sufficient to cause both an ulna fracture as well as a radial head dislocation. In 1949, Evans showed that type I Monteggia lesions are due to a

hyperpronation force.³⁷ He proposed that when a patient falls onto the outstretched hand, the forearm is already pronated and at the moment of impact, the hand becomes relatively fixed to the ground. However, the rest of the body continues to rotate resulting in a relative hyperpronation of the forearm. The combination of the rotational force and axial load result in the ulnar fracture. As the ulna fractures and angulates, its apex forms a fulcrum that either levers the radial head out of the PRUJ or fractures the proximal third of the radius (Figure 1.24).

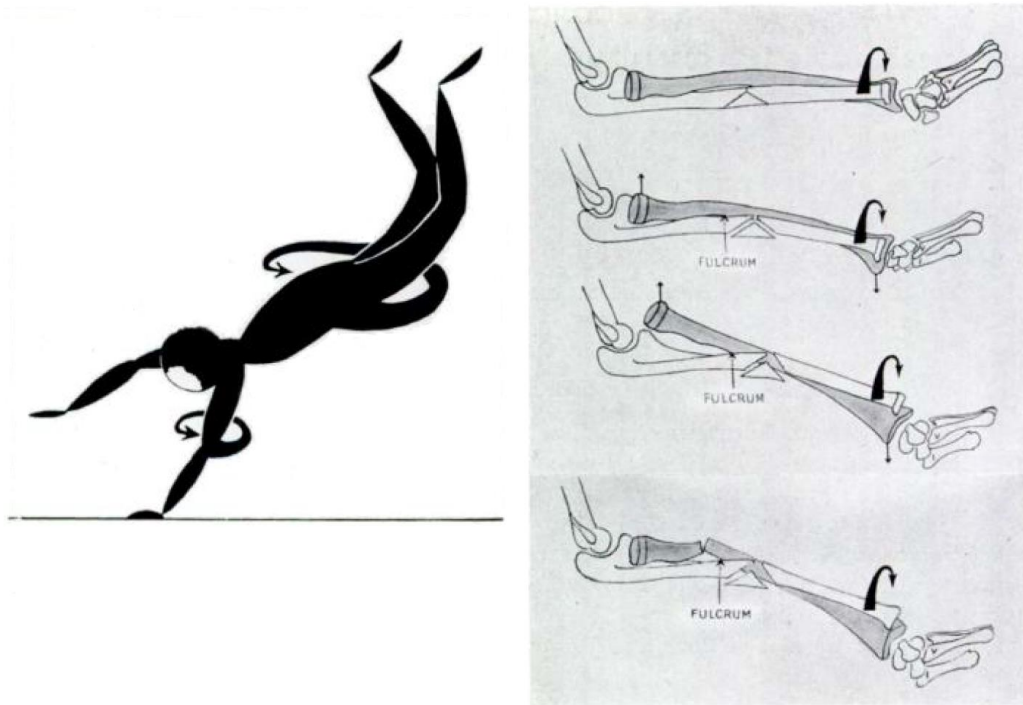


Figure 1.24: Evan's Proposed Theory of Monteggia Injuries.

With a fall on an outstretched hand, the hand becomes relatively fixed to the ground, but the rest of the body continues to rotate resulting in a hyperpronation force. This results in an ulnar fracture which forms a fulcrum that can lever the radial head out of the joint or result in proximal radial shaft fracture. "Reproduced from Evans E M. Pronation Injuries of the Forearm, with Special Reference to the Anterior Monteggia Fracture, JBJS(Br), 31B(4): 578-588, with permission of The British Editorial Society of Bone and Joint Surgery through PLSclear"

To investigate this theory, he conducted an experiment where 18 cadaveric specimens were stripped of all soft tissues from the elbow and forearm except the joint capsule, ligaments and the interosseous membrane. The humeral shaft was clamped, and the forearm was gripped above the wrist joint and slowly pronated. This resulted in the fracturing of the ulna in its middle third and an anterior dislocation of the radial head, reproducing type I Monteggia, in 12 cases. In the

remaining specimens, forearm pronation resulted in both-bone forearm fracture in 3 cases, isolated anterior radial head dislocation in 2 cases and an elbow dislocation in 1 case. In 1967, Bado presented clinical and radiographic support for the hyperpronation theory of type I Monteggia injuries.³³ He argued that clinically children with type I Monteggia injuries present with the forearm pronated suggesting pronation force as the mechanism of these injuries. Moreover, he argued that supination and slight traction, that often easily reduces these injuries is therapeutic proof that a pronation force is responsible for type I Monteggia lesions. Radiographically, he reported that posterior location of the bicipital tuberosity on the lateral radiograph of a type I Monteggia lesion indicates that the forearm is fully pronated and thus the underlying mechanism is that of pronation.

In 1971, Tompkins criticized Evans' proposed mechanism as his experiments were done by hyperpronation of specimens stripped of all muscles, eliminating their effects.³⁸ He also criticized that Evan's concept of body rotation around the fixed hand was not properly replicated in his experimental model as the specimens were clamped at the shaft of the humerus and the pronation force was applied to the forearm above the wrist joint. Moreover, Tompkins criticized the resultant spiral ulna fractures in Evans' experiment, since the pattern of ulna fractures in most type I Monteggia lesions are either transverse, oblique or comminuted with a posterior butterfly fragment. Tompkins also disputed Bado's argument that the position of bicipital tuberosity on radiographs is proof of the pronation theory.³⁸ He argued that on a lateral radiograph, the bicipital tuberosity is posterior with the forearm in neutral rotation and lateral in full pronation. In his radiographic review of patients presenting with type I Monteggia injuries, he found the forearm to be in neutral rotation or somewhat supinated in the majority of cases. Tompkins theorized that if the radius is not subluxated from the joint by a direct force and is not screwed out by a hyperpronation force, it may have been pulled out of the joint. He argued that the only conceivable traction force in that direction is from the contraction of the biceps muscle.³⁸ He reported that during a fall on an outstretched hand, the anterior dislocation of the radial head is due to a violent reflex contraction of the biceps and the forearm may be in any position of rotation. Once the radial head dislocates, the longitudinal compressive force on the ulna along with the pull of the intact interosseous membrane and simultaneous contraction of the brachialis result in fracture and anterior angulation of the ulna (Figure 1.25). Tompkins supported his theory based on the

observation that the radial head is easily reduced with the relaxation of the biceps once the elbow is flexed beyond 90 degrees.

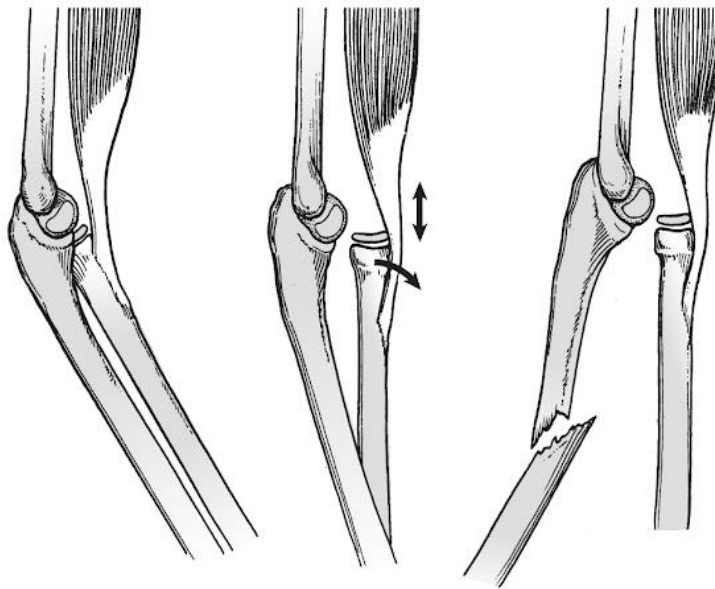


Figure 1.25: Tompkins' Proposed Theory of Monteggia Injuries.

During a fall, biceps contraction results in dislocation of the radial head. The longitudinal compressive force on the ulna then results in the ulnar fracture. "Reprinted from Rockwood and Wilkins' Fractures in Children, 8th Ed., Monteggia Fracture-Dislocation in Children, 2014, with permission from Wolters Kluwer Health" ³⁹

1.3.3 Management and Outcome of Monteggia Injuries

Although closed reduction and cast immobilization may be considered for acute Monteggia injuries with an incomplete fracture of the ulna (plastic deformation, buckle-type or greenstick fracture) in children, surgical management is recommended for acute Monteggia injuries with a complete fracture of the ulna in children and adults.⁴⁰⁻⁴³ In general, restoration of ulnar length, and alignment as well as counteracting the deforming forces (e.g. flexion of the elbow to relax the biceps) will allow for closed reduction of the radial head.⁴² Occasionally, open reduction of the radial head may be required but should be considered only after ensuring that the ulna fracture is appropriately reduced. In such circumstances, entrapment of soft tissue structures including the annular ligament, capsule, biceps tendon or the radial nerve has been shown to prevent reduction of the radial head despite an anatomic reduction of the ulna fracture.⁴⁴⁻⁵⁰ Although good results have been reported with appropriate management of acute Monteggia lesions in the pediatric

population, the outcomes in the adult population are more variable with high rates of complications.^{34,51-60} Complications include recurrent radial head subluxation/dislocation, stiffness, loss of strength, malunion, nonunion, nerve palsies, and post-traumatic arthrosis.^{34,53,58}

Despite increased awareness of Monteggia injuries, approximately 25-50% of these injuries are initially missed.^{42,61} This results in poor long-term outcomes with complaints of pain, instability, stiffness, and loss of strength.⁶² Although surgical management of missed Monteggia injuries has been shown to improve clinical outcomes, high rates of potential complications have been reported in medium to long-term studies.^{49,61,63} Moreover, management of chronic Monteggia injuries is much more challenging. Numerous surgical procedures have been described including ulnar corrective osteotomy, ulnar bending osteotomy, combined ulnar bending and lengthening osteotomy, gradual lengthening and angulation of the ulna, radial osteotomy and various annular ligament reconstruction techniques.⁶⁴ However, there is no consensus on the best treatment protocol.

Although most studies have used 6 weeks of cast immobilization in the pediatric population, active elbow range of motion is generally recommended after 2-3 weeks of immobilization in adults.^{43,65-67} To our knowledge, no previous study has compared the effect of active or passive elbow motion in the postoperative rehabilitation of patients with anterior Monteggia injuries.

1.3.4 Current Biomechanical Studies

In a biomechanical study, Sandman and colleagues evaluated the effect of ulnar malalignment, elbow positions, forearm rotation and annular ligament integrity on radial head subluxation.⁶⁸ They investigated ulnar angulation in 5° increments from 10° of extension angulation to 10° of flexion angulation. They included four elbow positions (maximal extension, 45°, 90°, maximal flexion) and three forearm positions (neutral, pronation, supination). They found increasing anterior radial head subluxation with each of the progressive extension malalignment of the ulna, progressive elbow flexion and a torn annular ligament. The greatest mean radial head displacement was 61% which occurred with the elbow in maximal flexion, 10° of ulnar extension malalignment, and a ruptured annular ligament. Although they did not directly investigate the role of biceps contraction on radial head stability, they suspected that the effect of elbow flexion on anterior radial head subluxation is related to the pull of the biceps. However, loading of the biceps and the brachialis

was not physiologic as they employed a 50:50 ratio whereas studies have suggested loads vary in these muscles throughout elbow range of motion with the brachialis being the prime mover during elbow flexion.⁶⁹⁻⁷¹ Also, the contribution of other elbow flexors such as brachioradialis was not considered. To our knowledge, no other study has investigated the biomechanics of anterior Monteggia injuries.

1.4 Thesis Rationale

The outcomes of Monteggia injuries are quite variable and often suboptimal, particularly in the adult population. Although numerous surgical procedures have been proposed for the reconstruction of chronic Monteggia injuries, poor long-term outcomes with high rates of complications have been reported and no optimal reconstruction technique has been accepted. A better understanding of the biomechanics of Monteggia injuries would allow determination of the factors that contribute to the radial head instability in these injuries. This information can then be used to optimize surgical techniques and rehabilitation protocols to enhance patients' outcomes.

The purpose of this biomechanical investigation was to study the contribution of the factors that have been proposed to play a role in the stability of Monteggia injuries including ulnar malalignment, and biceps loading. Moreover, we aimed to investigate the role of soft tissues around the elbow, including the anterior joint capsule, annular ligament, quadratus ligament and the IOM, in the stability of the Monteggia injuries. Although the effect of annular ligament dysfunction on radial head instability in Monteggia injuries has been studied in a previous biomechanical investigation; to our knowledge, the role of other soft tissues, particularly the IOM, in the stability of the Monteggia injuries have not been fully investigated. These structures have been shown to contribute to radial head instability in biomechanical investigations of pure radial head dislocation and a better understanding of their contributions to the stability of Monteggia injuries is imperative.

1.5 Objectives & Hypotheses

The specific objectives of this thesis are as follows:

1. To determine the contribution of ulnar angulation on radial head instability in anterior Monteggia injuries (Chapter 2)
2. To determine the contribution of the anterior joint capsule, annular ligament, quadratus ligament, and the proximal and middle IOM on radial head instability in anterior Monteggia injuries (Chapter 2)
3. To determine the contribution of biceps contraction on radial head instability in anterior Monteggia injuries (Chapter 3)
4. To determine the contribution of muscle activation during simulated active compared to passive elbow flexion on radial head instability in anterior Monteggia injuries (Chapter 3)

The specific hypotheses of this investigation are as follows:

1. Increasing ulnar angulation increases anterior radial head translation in the setting of anterior Monteggia injuries
2. Sequential sectioning of the anterior capsule, annular ligament, and proximal and middle IOM increases anterior radial head instability in the setting of anterior Monteggia injuries
3. Biceps loading contributes to instability of the radiocapitellar joint in the setting of anterior Monteggia injuries
4. Simulated active elbow flexion increases anterior radial head translation compared to passive elbow flexion in the setting of anterior Monteggia injuries

1.6 Thesis Overview

This thesis examines the biomechanics of radial head stability in anterior Monteggia Injuries.

Chapter 2 presents an *in vitro* cadaver-based study which investigates the effects of ulnar angulation and sequential soft tissue sectioning on radial head stability using kinematic evaluation.

Chapter 3 presents an *in vitro* cadaver-based study which investigates the role of staircase loading of biceps tendon on radial head stability using kinematic evaluation. Moreover, the effect of simulated active and passive elbow flexion on radial head stability was examined.

Chapter 4 provides a final overview and discussion of the findings and potential future directions of the work.

1.7 References

1. Rouleau DM, Faber KJ, Athwal GS. The proximal ulna dorsal angulation: A radiographic study. *Journal of Shoulder and Elbow Surgery*. 2010;19:26-30.
2. Windisch G, Clement H, Grechenig W, Tesch NP, Pichler W. The anatomy of the proximal ulna. *J Shoulder Elbow Surg*. 2007;16(5):661-666.
3. Isa AD. *The Effect of Radial and Ulnar Length Change on Distal Forearm Loading*: Department of Surgery, Western University; 2017.
4. Rupasinghe SL, Poon PC. Radius morphology and its effects on rotation with contoured and noncontoured plating of the proximal radius. *J Shoulder Elbow Surg*. 2012;21(5):568-573.
5. Morrey BF, Sanchez-Sotelo J, Morrey ME. *The elbow and its disorders*. Fifth edition. ed. Philadelphia, PA: Elsevier; 2018.
6. Morrey BF, An KN. Functional anatomy of the ligaments of the elbow. *Clin Orthop Relat Res*. 1985(201):84-90.
7. Spinner M, Kaplan EB. The quadratus ligament of the elbow--its relationship to the stability of the proximal radio-ulnar joint. *Acta Orthop Scand*. 1970;41(6):632-647.
8. Tubbs RS, Shoja MM, Khaki AA, et al. The morphology and function of the quadratus ligament. *Folia Morphol (Warsz)*. 2006;65(3):225-227.
9. Seki A, Olsen BS, Jensen SL, Eygendaal D, Sojbjerg JO. Functional anatomy of the lateral collateral ligament complex of the elbow: configuration of Y and its role. *J Shoulder Elbow Surg*. 2002;11(1):53-59.
10. Martin BF. The oblique cord of the forearm. *J Anat*. 1958;92(4):609-615.
11. Noda K, Goto A, Murase T, Sugamoto K, Yoshikawa H, Moritomo H. Interosseous membrane of the forearm: an anatomical study of ligament attachment locations. *J Hand Surg Am*. 2009;34(3):415-422.
12. Nakamura T, Yabe Y, Horiuchi Y. Functional Anatomy of the Interosseous Membrane of the Forearm - Dynamic Changes During Rotation. *Hand Surg*. 1999;4(1):67-73.
13. Mori K. Experimental study on rotation of the forearm--functional anatomy of the interosseous membrane. *Nihon Seikeigeka Gakkai zasshi*. 1985;59(6):611-622.
14. Skahen JR, 3rd, Palmer AK, Werner FW, Fortino MD. The interosseous membrane of the forearm: anatomy and function. *J Hand Surg Am*. 1997;22(6):981-985.
15. Adams JE. Forearm Instability: Anatomy, Biomechanics, and Treatment Options. *J Hand Surg Am*. 2017;42(1):47-52.

16. Matthias R, Wright TW. Interosseous Membrane of the Forearm. *J Wrist Surg.* 2016;5(3):188-193.
17. Zimmerman NB. Clinical application of advances in elbow and forearm anatomy and biomechanics. *Hand Clin.* 2002;18(1):1-19.
18. Palmer AK, Werner FW. Biomechanics of the distal radioulnar joint. *Clin Orthop Relat Res.* 1984(187):26-35.
19. Birkbeck DP, Failla JM, Hoshaw SJ, Fyhrie DP, Schaffler M. The interosseous membrane affects load distribution in the forearm. *J Hand Surg Am.* 1997;22(6):975-980.
20. Duck TR, Dunning CE, King GJ, Johnson JA. Variability and repeatability of the flexion axis at the ulnohumeral joint. *J Orthop Res.* 2003;21(3):399-404.
21. Bottlang M, Madey SM, Steyers CM, Marsh JL, Brown TD. Assessment of elbow joint kinematics in passive motion by electromagnetic motion tracking. *J Orthop Res.* 2000;18(2):195-202.
22. Bryce CD, Armstrong AD. Anatomy and biomechanics of the elbow. *Orthop Clin North Am.* 2008;39(2):141-154, v.
23. Ferreira LM. *Development of an Active Elbow Motion Simulator and Coordinate Systems to Evaluate Kinematics in Multiple Positions*: Biomedical Engineering, University of Western Ontario; 2011.
24. Hollister AM, Gellman H, Waters RL. The relationship of the interosseous membrane to the axis of rotation of the forearm. *Clin Orthop Relat Res.* 1994(298):272-276.
25. Kapandji A. Biomechanics of pronation and supination of the forearm. *Hand Clin.* 2001;17(1):111-122, vii.
26. O'Driscoll SW, Jupiter JB, King GJ, Hotchkiss RN, Morrey BF. The unstable elbow. *Instr Course Lect.* 2001;50:89-102.
27. de Haan J, Schep NW, Eygendaal D, Kleinrensink GJ, Tuinebreijer WE, den Hartog D. Stability of the elbow joint: relevant anatomy and clinical implications of in vitro biomechanical studies. *Open Orthop J.* 2011;5:168-176.
28. Safran MR, Baillargeon D. Soft-tissue stabilizers of the elbow. *J Shoulder Elbow Surg.* 2005;14(1 Suppl S):179s-185s.
29. Weiss AP, Hastings H, 2nd. The anatomy of the proximal radioulnar joint. *J Shoulder Elbow Surg.* 1992;1(4):193-199.
30. Anderson A, Werner FW, Tucci ER, Harley BJ. Role of the interosseous membrane and annular ligament in stabilizing the proximal radial head. *J Shoulder Elbow Surg.* 2015;24(12):1926-1933.

31. Hayami N, Omokawa S, Iida A, et al. Biomechanical study of isolated radial head dislocation. *BMC Musculoskelet Disord.* 2017;18(1):470.
32. Monteggia GB. Lussazioni della ossa delle estremita superiori. *Instituzioni Chirurgisches.* 1814;5:131-133.
33. Bado JL. The Monteggia lesion. *Clinical orthopaedics and related research.* 1967;50:71-86.
34. Beutel BG. Monteggia fractures in pediatric and adult populations. *Orthopedics.* 2012;35(2):138-144.
35. Ramski DE, Hennrikus WP, Bae DS, et al. Pediatric Monteggia Fractures: A Multicenter Examination of Treatment Strategy and Early Clinical and Radiographic Results. *J Pediatr Orthop.* 2014;00:1-6.
36. Speed JS, Boyd HB. Treatment of Fractures of Ulna With Dislocation of Head of Radius. *J Am Med Assoc.* 1940;115:1699.
37. Evans EM. Pronation injuries of the forearm, with special reference to the anterior Monteggia fracture. *The Journal of bone and joint surgery British volume.* 1949;31B:578-588, illust.
38. Tompkins DG. The anterior Monteggia fracture: observations on etiology and treatment. *The Journal of bone and joint surgery American volume.* 1971;53:1109-1114.
39. Rockwood CA, Beaty JH, Kasser JR. *Rockwood and Wilkins' fractures in children.* 7th ed. Philadelphia: Wolters Kluwer/Lippincott, Williams & Wilkins; 2010.
40. Ring D, Jupiter JB, Waters PM. Monteggia fractures in children and adults. *The Journal of the American Academy of Orthopaedic Surgeons.* 1998;6:215-224.
41. Athwal GS, Ramsey ML, Steinmann SP, Wolf JM. Fractures and dislocations of the elbow: a return to the basics. *Instr Course Lect.* 2011;60:199-214.
42. Bae DS. Successful Strategies for Managing Monteggia Injuries. *J Pediatr Orthop.* 2016;36 Suppl 1:S67-70.
43. Bae DS, Waters PM. Surgical Treatment of Acute and Chronic Monteggia Fracture-Dislocations. *Operative Techniques in Orthopaedics.* 2005;15(4):308-314.
44. Sasaki K, Miura H, Iwamoto Y. Unusual anterior radial head dislocation associated with transposed biceps tendon: a case report. *J Shoulder Elbow Surg.* 2006;15(6):e15-19.
45. Tanner C, Johnson T, Kolahi K, Husak L, Hoekzema N. Irreducible Monteggia fracture: interposed radial nerve and capsule. *JSES Open Access.* 1(2):85-89.

46. Yoshihara Y, Shiraishi K, Imamura K. Irreducible anteromedial dislocation of the radial head caused by biceps tendon clinging around the radial neck. *J Trauma*. 2002;53(5):984-986.
47. Veenstra KM, van der Eyken JW. Irreducible antero-medial dislocation of the radius. A case of biceps tendon interposition. *Acta Orthop Scand*. 1993;64(2):224-225.
48. Neviasser RJ, LeFevre GW. Irreducible isolated dislocation of the radial head. A case report. *Clin Orthop Relat Res*. 1971;80:72-74.
49. Rodgers WB, Waters PM, Hall JE. Chronic Monteggia lesions in children. Complications and results of reconstruction. *J Bone Joint Surg Am*. 1996;78(9):1322-1329.
50. Takase K, Mizuochi J. Irreducible dislocation of the radial head with undisplaced olecranon fracture in a child: a case report. *J Pediatr Orthop B*. 2011;20(5):345-348.
51. Ring D, Jupiter JB, Simpson NS. Monteggia fractures in adults. *J Bone Joint Surg Am*. 1998;80(12):1733-1744.
52. Guitton TG, Ring D, Kloen P. Long-term evaluation of surgically treated anterior monteggia fractures in skeletally mature patients. *J Hand Surg Am*. 2009;34(9):1618-1624.
53. Konrad GG, Kundel K, Kreuz PC, Oberst M, Sudkamp NP. Monteggia fractures in adults: long-term results and prognostic factors. *J Bone Joint Surg Br*. 2007;89(3):354-360.
54. Givon U, Pritsch M, Levy O, Yosepovich A, Amit Y, Horoszowski H. Monteggia and equivalent lesions. A study of 41 cases. *Clin Orthop Relat Res*. 1997(337):208-215.
55. Reynders P, De Groote W, Rondia J, Govaerts K, Stoffelen D, Broos PL. Monteggia lesions in adults. A multicenter Bota study. *Acta Orthop Belg*. 1996;62 Suppl 1:78-83.
56. Bae DS, Waters PM. Surgical treatment of acute and chronic monteggia fracture-dislocations. *Operative Techniques in Orthopaedics*. 2005;15:308-314.
57. Bae DS. Successful Strategies for Managing Monteggia Injuries. *J Pediatr Orthop*. 2016;36 Suppl 1:S67-70.
58. Chin K, Kozin SH, Herman M, et al. Pediatric Monteggia Fracture-Dislocations: Avoiding Problems and Managing Complications. *Instr Course Lect*. 2016;65:399-407.
59. Dormans JP, Rang M. The problem of Monteggia fracture-dislocations in children. *Orthop Clin North Am*. 1990;21(2):251-256.
60. Ring D, Waters PM. Operative fixation of Monteggia fractures in children. *J Bone Joint Surg Br*. 1996;78(5):734-739.

61. Goyal T, Arora SS, Banerjee S, Kandwal P. Neglected Monteggia fracture dislocations in children: a systematic review. *J Pediatr Orthop B*. 2015;24(3):191-199.
62. Rahbek O, Deutch SR, Kold S, Sojbjerg JO, Moller-Madsen B. Long-term outcome after ulnar osteotomy for missed Monteggia fracture dislocation in children. *J Child Orthop*. 2011;5(6):449-457.
63. Nakamura K, Hirachi K, Uchiyama S, et al. Long-term clinical and radiographic outcomes after open reduction for missed Monteggia fracture-dislocations in children. *J Bone Joint Surg Am*. 2009;91(6):1394-1404.
64. Nakamura K, Hirachi K, Uchiyama S, et al. Long-Term Clinical and Radiographic Outcomes After Open Reduction for Missed Monteggia Fracture-Dislocations in Children. *The Journal of Bone and Joint Surgery-American Volume*. 2009;91:1394-1404.
65. Lu X, Kun Wang Y, Zhang J, Zhu Z, Guo Y, Lu M. Management of missed Monteggia fractures with ulnar osteotomy, open reduction, and dual-socket external fixation. *J Pediatr Orthop*. 2013;33(4):398-402.
66. Lu X, Yan G, Wang Y, et al. Repositioning of the Annular Ligament in the Management of Missed Monteggia Fracture. *J Pediatr Orthop*. 2017;37(1):20-22.
67. Song KS, Ramnani K, Bae KC, Cho CH, Lee KJ, Son ES. Indirect reduction of the radial head in children with chronic Monteggia lesions. *J Orthop Trauma*. 2012;26(10):597-601.
68. Sandman E, Canet F, Petit Y, Laflamme GY, Athwal GS, Rouleau DM. Radial Head Subluxation After Malalignment of the Proximal Ulna. *J Orthop Trauma*. 2014;28:464-469.
69. Ferreira LM, Johnson JA, King GJ. Development of an active elbow flexion simulator to evaluate joint kinematics with the humerus in the horizontal position. *J Biomech*. 2010;43(11):2114-2119.
70. Johnson JA, Rath DA, Dunning CE, Roth SE, King GJ. Simulation of elbow and forearm motion in vitro using a load controlled testing apparatus. *J Biomech*. 2000;33(5):635-639.
71. Funk DA, An KN, Morrey BF, Daube JR. Electromyographic analysis of muscles across the elbow joint. *J Orthop Res*. 1987;5(4):529-538.

Chapter 2

2 Effects of Ulnar Angulation and Soft Tissue Sectioning on Radial Head Stability in Anterior Monteggia Injuries

Radial head instability continues to be a challenge in the management of anterior Monteggia injuries. The factors that contribute to this instability have not been fully investigated. This chapter examines the effect of ulnar extension angulation and sequential sectioning of the anterior radiocapitellar joint capsule, annular ligament, quadratus ligament, and the proximal and middle interosseous membrane on radial head stability in anterior Monteggia lesions.

2.1 Introduction

[NB: A portion of this material was presented in Chapter 1 and is also included here in order to ensure that this chapter is in “article” format]

Giovanni Monteggia first described a fracture of the proximal third of the ulna and an anterior dislocation of the radial head in 1814 (Chapter 1, Figure 1.22).¹ Louis Bado later expanded the definition of Monteggia fractures by classifying these lesions into 4 categories based on the location of the ulnar fracture, the direction of radial head displacement and the presence or absence of a concomitant proximal radius fracture (Chapter 1, Figure 1.23).² The Type I Monteggia injury, which is the focus of this investigation, represents an apex anterior fracture of the proximal or middle third of the ulna and an anterior dislocation of the radial head.

Although good results have been reported with appropriate management of acute Monteggia lesions in the pediatric population, their outcomes in the adult population are more variable with high rates of complications.³⁻¹³ Moreover, approximately 25-50% of these injuries are initially missed.^{14,15} Management of chronic Monteggia injuries are much more challenging and despite numerous surgical procedures, high rates of complications have been reported in medium to long-term follow-up studies.^{14,16,17} Complications include recurrent radial head subluxation/dislocation, stiffness, loss of strength, malunion, nonunion, nerve palsies, and post-traumatic arthrosis.^{5,8,11}

A better understanding of the biomechanics of Monteggia injuries would allow determination of the factors that contribute to the radial head instability in these injuries. This should allow the

development of better surgical techniques and rehabilitation protocols to enhance patients' outcomes. The aim of this biomechanical investigation was to study the effects of ulnar angulation and soft tissue insufficiency on radial head stability in anterior Monteggia injuries using an *in vitro* elbow motion simulator. We hypothesized that increasing extension angulation of the ulna results in a progressive anterior translation of the radial head. Moreover, we hypothesized that sequential sectioning of the anterior joint capsule, annular ligament, quadrate ligament, and the interosseous membrane (IOM) would cause progressive anterior translation of the radial head.

2.2 Materials and Methods

2.2.1 Specimen Preparation

Six fresh-frozen cadaveric left upper extremities (mean age at the time of death: 60 ± 8 years) amputated at the mid-humerus level were used. Computed tomography was performed to rule out pre-existing degenerative articular pathology or skeletal deformity. Specimens were stored at -20°C and thawed at room temperature ($22^{\circ}\text{C} \pm 2^{\circ}\text{C}$) for 18 hours prior to testing.

The distal tendons of the biceps, brachialis, brachioradialis, triceps, and pronator teres were sutured in a running locking fashion using an eight-strand braided fishing line (Hercules, CA, USA; 150lb). The supinator function was simulated using a suture anchor placed at the centre of the bicipital tuberosity and routing the attached suture through guide sleeves placed in the proximal ulna. The distal tendons of the wrist extensors (extensor carpi radialis longus and extensor carpi ulnaris) and then the wrist flexors (flexor carpi radialis and flexor carpi ulnaris) were sutured together. To maintain anatomic lines of action, all suture tendons were passed subcutaneously within their respective compartments. The sutures of the pronator teres and wrist flexors were passed through an alignment guide secured to the medial epicondyle using a unicortical 3.5mm cancellous screw. The sutures of the brachioradialis and the wrist extensors were passed through a second alignment guide secured to the supracondylar ridge of the lateral humerus in the same fashion. The cadaveric arm was rigidly mounted onto the elbow motion simulator by clamping the humerus (Figure 2.1). Stainless steel cables were used to connect the sutures of the biceps, brachialis and triceps to three computer-controlled servomotors. The remaining sutures were connected to five pneumatic actuators. The simulator base was positioned with the arm oriented in the vertical dependent position.

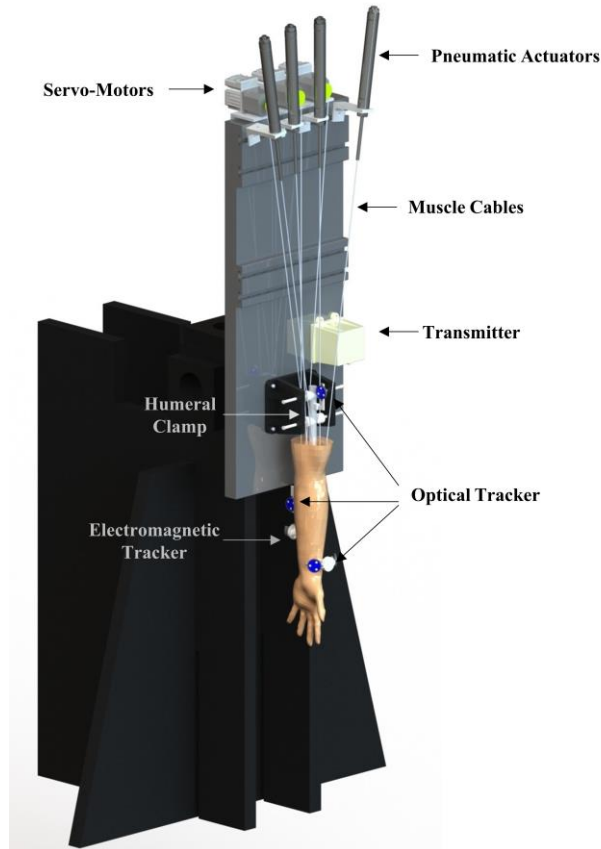


Figure 2.1: Elbow Motion Simulator.

The active elbow motion simulator allows for simulated active elbow flexion-extension using a combination of computer-controlled servomotors and pneumatic actuators. The arm is rigidly connected to the simulator base by a humeral clamp. An electromagnetic tracker fixed to the ulna was used to control the simulated active motion of the cadaveric arm. Optical trackers were placed on the radius, ulna and the humerus to develop a coordinate system to track the motion of the radial head.

2.2.2 Experimental Motion Simulation and Testing Protocol

A custom-designed LabVIEW program (National Instruments, Austin, TX, USA) was used to control the loading of relevant muscles. Simulated active elbow flexion with the forearm supinated was prescribed at a rate of $10^\circ/\text{s}$ based on previously established protocols that have been validated with this simulator.¹⁸⁻²¹ The brachialis was designated as the prime mover during each flexion trial. The load applied to the brachialis varied as a function of elbow flexion angle feedback. Loads applied to the biceps and the brachioradialis were a constant ratio of the load applied to the brachialis (biceps=52% of brachialis; brachioradialis=29% of brachialis). Loads applied to the supinator and biceps allowed for supination of the forearm during active elbow flexion. A 10N

load was applied to the wrist extensors and the wrist flexors to stabilize the wrist in a neutral position via pneumatic actuators.

Before testing, 5 simulated active preconditioning cycles of elbow flexion and extension with the forearm maintained in supination were performed. During definitive testing, two trials were conducted for each active motion and the average values were used for analysis.

Testing was first conducted for the intact state. A custom jig was designed to simulate apex anterior angulation deformities typically seen in anterior Monteggia injuries (Figure 2.2). The apex of this angulation was placed at the dorsal surface of the ulna. The exact location of the osteotomy was determined based on the measurements of the ulnar length from the preoperative CT images. This length was divided by 3 and the osteotomy was planned at the junction of the proximal and middle third of the ulna. The jig was placed such that its hinge was in line with the planned osteotomy site and fixed to the ulna using three 3.5mm cortical screws on each side of the osteotomy. A digital caliper (Empire, WI, USA) and a custom trigonometric program were used to achieve accurate angulation of the osteotomy site. A measurement point was etched in the centre of each of the pins housing the lead screw and the distance between these two points was measured using a digital caliper. A trigonometric formula was used to determine the distance between these two points for each desired angle of the osteotomy site. Once the appropriate distance was achieved by turning the lead screw, the nuts on each side of the pins were tightened to ensure that the desired osteotomy angulation was maintained. Once the jig was fixed to the ulna and the baseline distance between the two points on the pins were measured, the osteotomy was made using a surgical saw (ConMed, FL, USA; width: 9.5mm; thickness: 0.60mm). Testing was repeated with the osteotomy maintained at the initial alignment (labeled 0° angulation). Testing was then conducted with the jig adjusted to maintain the osteotomy at 10°, 20°, and 30° of extension angulation from the baseline (Figure 2.2B).

For soft tissue sectioning stages, dissection was carried out through an anterior Henry approach to gain access to the anterior radiocapitellar joint capsule, annular ligament, quadratus ligament and the IOM. In stage 1, the anterior joint capsule was sectioned horizontally from the lateral to medial width of the radial head. In stage 2, the annular ligament and the quadratus ligament, if present, were sectioned. In stage 3, the proximal portion of the IOM was sectioned. The proximal IOM is

comprised of the proximal and dorsal oblique cords.²²⁻²⁴ The proximal oblique cord originates from the anterolateral aspect of the coronoid process and inserts just distal to the radial tuberosity.²² The dorsal oblique cord originates from the junction of the proximal third and distal two-thirds of the ulna and inserts into the interosseous crest of the radius.²² In this stage, while protecting the biceps tendon insertion, the proximal portion of the IOM with its fibers oriented from proximal-ulnar to distal-radial was sectioned. In stage 4, the central band of the IOM was sectioned from its radial origin. The central band originates at approximately 60% of the length of the radius from the styloid and inserts at approximately the junction of the middle two-thirds and the distal one-third of the ulna.²⁵ It is oriented obliquely from proximal-radial to distal-ulnar which differentiates this portion of the IOM from the proximal IOM. Testing was repeated for each soft tissue sectioning stages with the ulnar osteotomy maintained at 0°, 10°, 20°, 30° of extension angulation.




Figure 2.2: Custom Designed Jig.

A) A custom jig was designed to maintain ulnar osteotomy at desired angulations. The distance between the two measurement points was recorded using a digital caliper and a trigonometric formula was used to obtain the desired osteotomy angulation by turning the lead screw. B) Represents various degrees of ulnar extension angulation using the custom designed jig.

2.2.3 Kinematic Data Acquisition

An optical tracking system (Optotrak Certus; Northern Digital, Waterloo, ON, Canada) was used to track the motion of the radial head.²⁶⁻²⁹ Optical position sensors were mounted on the radius, ulna and the humerus. The Optotrak motion capture camera system was used to track the sensors'

position throughout the elbow range of motion (ROM) (Figure 2.3). To maintain an in-plane accuracy of 0.1mm and 0.15mm perpendicular to the camera, a direct line of sight between the camera and the position sensors was maintained within 2.5m.



Figure 2.3: Optotrak Motion Capture Camera System.

The motion capture camera system tracks optical position sensors' position throughout the elbow ROM.

Upon completion of the testing protocol, each specimen was denuded of all soft tissues with the optical position sensors left attached for digitization. A clinically relevant coordinate system was created by digitizing anatomic landmarks with a calibrated tracked stylus.¹⁸

To quantify radial head translation, a coordinate system was placed on the radial head with the origin at the deepest point of the radial dish. The y-axis of this coordinate system represents translation along the anterior-posterior plane (Figure 2.4). The radial head translation for the intact and injured states was quantified as the distance between the deepest portion of the radial dish to the centre of the capitellum along the y-axis of the radial coordinate system. The centre of the capitellum was found by sphere-fitting a digitization of the capitellum and extracting the centre of the sphere.

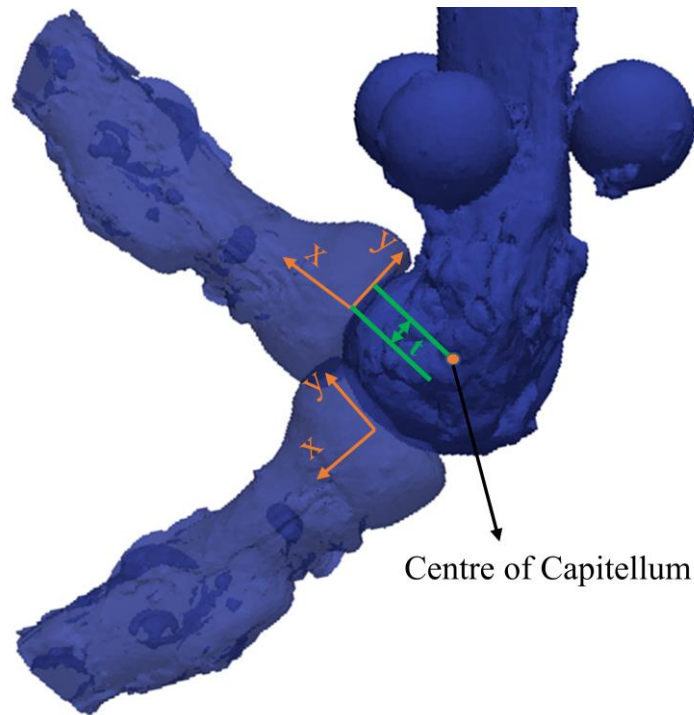


Figure 2.4: Radial Head Translation.

Reference coordinate system was placed on the radial head. X-axis represents proximal-distal translation (+ distal), y-axis represents anterior-posterior translation (+ anterior); and z-axis (not shown in this image) represents medial-lateral translation (+ medial). The radial head position at 30° and 130° of elbow flexion are shown to demonstrate the movement of the reference coordinate system during elbow flexion. Radial head translation (t) was quantified as the distance between the deepest point of the radial dish to the centre of the capitellum along the y-axis of the radial head.

2.2.4 Statistical Methods

Kinematic data were analyzed at 5° increments from 25-130° arc of active flexion with the forearm in supination using SPSS 23 statistical software (SPSS Inc, Chicago, IL, USA). A two-way repeated-measures analysis of variance (ANOVA) was performed to compare the effect of ulnar extension angulation without soft tissue injury and elbow flexion angles on radial head translation. If significance was found, post hoc analysis with a Bonferroni correction was conducted to compare the effects of various degrees of ulnar extension angulation to each other.

A three-way repeated-measures ANOVA with Bonferroni correction was performed to examine the effect of sequential soft tissue sectioning, ulnar extension angulation and elbow flexion angles on radial head translation. If significance was found, post hoc tests were conducted to compare the

effect of various degrees of ulnar extension angulation in the soft tissue sectioned elbow and the effect of sequential soft tissue sectioning stages to each other.

Data for the entire flexion-extension arc of motion was not always available due to line of sight issues with the optical tracking system most commonly at the extremes of the flexion-extension arc. Linear interpolation was used to estimate missing kinematic values when needed (approximately 2% of the data were interpolated). Statistical significance was set at $\alpha = .05$.

2.3 Results

With the soft tissues intact, there was a significant effect of ulnar extension angulation on radial head translation during active elbow flexion with the forearm supinated ($P=.000$). Post hoc analysis demonstrated that there was no significant difference between the intact state and ulnar osteotomy with 0° of angulation ($P=1.000$). However, each subsequent stage of ulnar extension angulation resulted in a significant incremental increase in anterior radial head translation (osteotomy angulation 10° vs. 0° : $P=.011$; osteotomy angulation 20° vs. 10° : $P=.012$; osteotomy angulation 30° vs. 20° : $P=.000$) (Figure 2.5 and 2.6). There was no significant effect of flexion angle on radial head translation ($P=.967$).

Since there was no significant difference between the intact state and 0° of ulnar angulation (mean difference = $0.1\text{mm} \pm 0.6\text{mm}$), ulnar osteotomy 0° state was only used in the three-way repeated measure ANOVA to analyze the effect of sequential soft tissue sectioning, ulnar extension angulation and elbow flexion angle on radial head translation. This analysis showed that both sequential soft tissue sectioning and ulnar extension angulation had a significant effect on radial head translation (ulnar angulation: $P=.000$; soft tissue sectioning: $P=.000$). Post hoc analysis demonstrated a significant incremental increase in anterior radial head translation with each subsequent stage of ulnar extension angulation (osteotomy angulation 10° vs. 0° : $P=.044$; osteotomy angulation 20° vs. 10° : $P=.006$; osteotomy angulation 30° vs. 20° : $P=.001$) (Figure 2.5, 2.7 and 2.8). Post hoc analysis, examining the effect of soft tissue sectioning, demonstrated no significant increase in radial head translation with sectioning of the anterior joint capsule ($P=1.000$) (Figure 2.8 and 2.9). However, additional sectioning of the annular ligament and the quadratus ligament, which was present in 4 of our specimens, approached but did not reach statistical significance ($P=.082$). Further sectioning of the proximal and middle IOM resulted in significant increases in anterior radial head translation compared to the intact soft tissue state (proximal IOM: $P=.025$; middle IOM: $P=.041$). Finally, this analysis showed a significant effect of elbow flexion angle on radial head translation with a greater amount of anterior translation observed in higher degrees of elbow flexion ($P=.000$) (Figure 2.10). However, there was a significant interaction between soft tissue sectioning and flexion angle; the increased anterior radial head translation observed in higher degrees of elbow flexion was mainly evident during later stages of soft tissue sectioning ($P=.000$). Moreover, there was a significant interaction between

ulnar angulation and flexion angle ($P=.000$). The increased anterior radial head translation observed in higher degrees of elbow flexion occurred primarily at larger magnitudes of ulnar extension angulation.

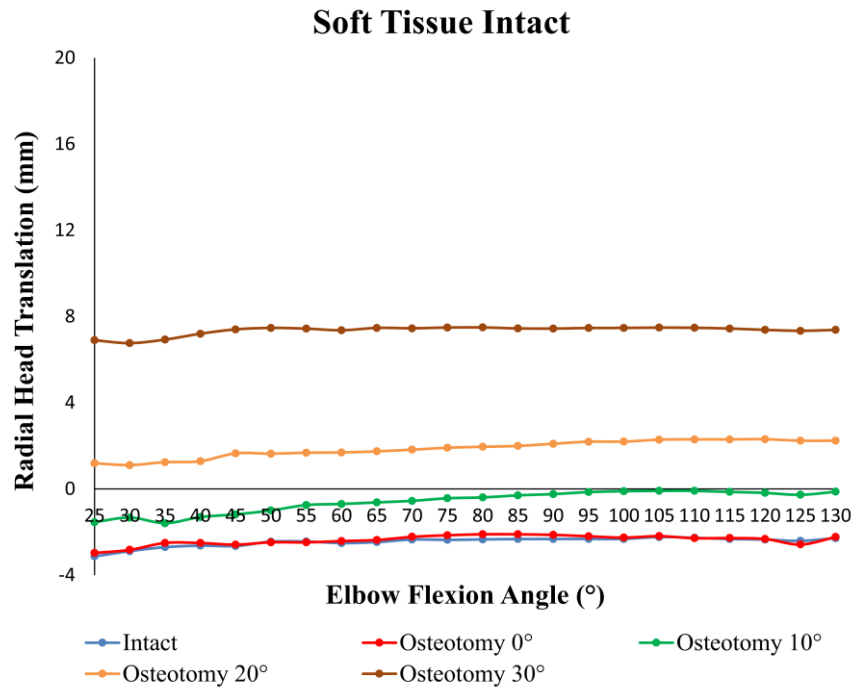


Figure 2.5: Radial head translation with progressive ulnar angulation of elbows with intact soft tissues during active elbow flexion.

There was no significant difference in radial head translation between osteotomy 0° and the intact state ($P=1.000$). Each subsequent ulnar extension angulation resulted in a significant incremental increase in anterior radial head translation (osteotomy angulation 10° vs. 0°: $P=.011$; osteotomy angulation 20° vs. 10°: $P=.012$; osteotomy angulation 30° vs. 20°: $P=.000$).

Increasing values of translation indicate anterior translation and decreasing values indicate posterior translation. The standard deviations (omitted from the graph for clarity) ranged from 3.9mm to 5.0mm.

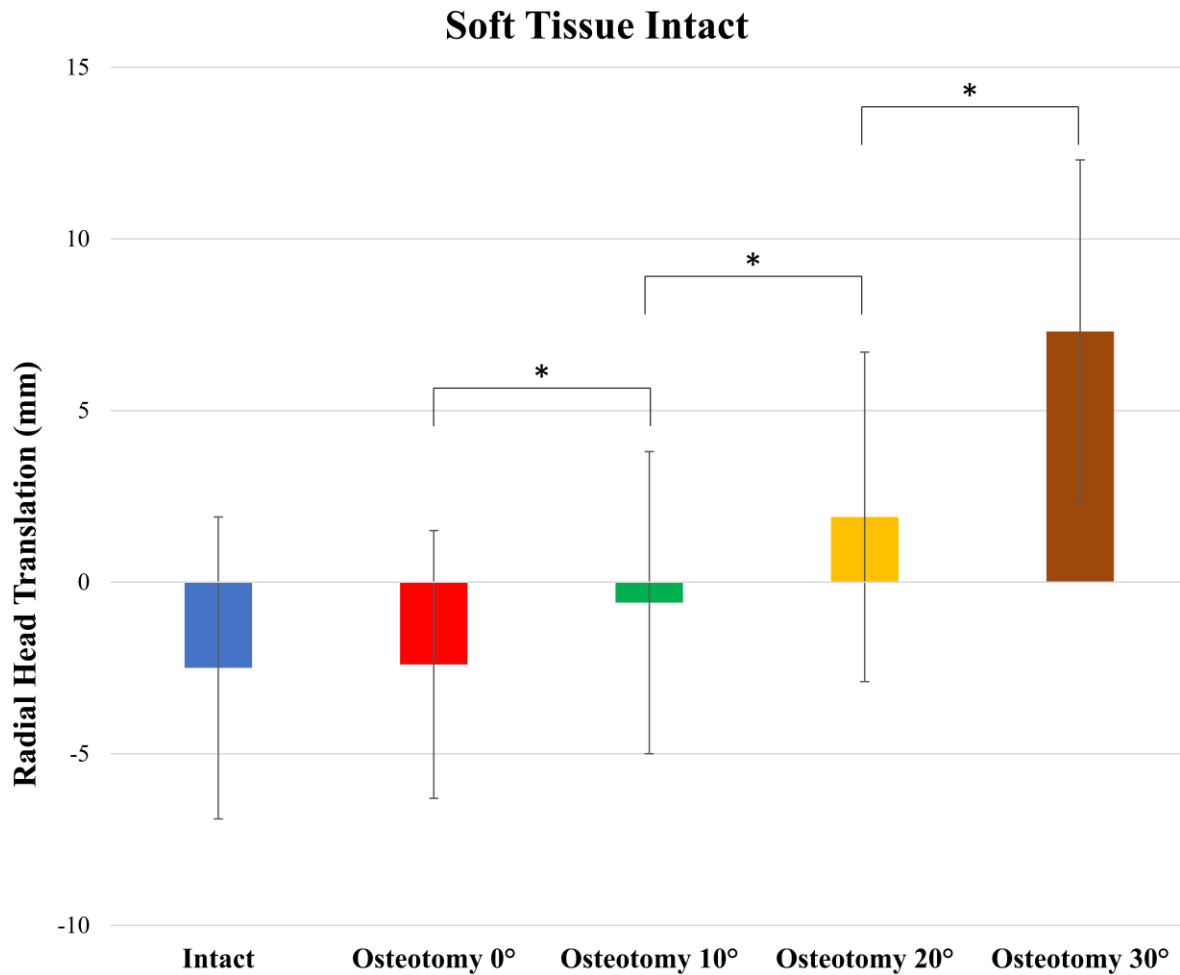


Figure 2.6: Effect of ulnar angulation on radial head translation with intact soft tissues.

The means and standard deviations of the radial head translation for each osteotomy stage are plotted. Increasing values of translation indicate anterior translation and decreasing values indicate posterior translation.

** indicates statistical significance ($P < .05$)*

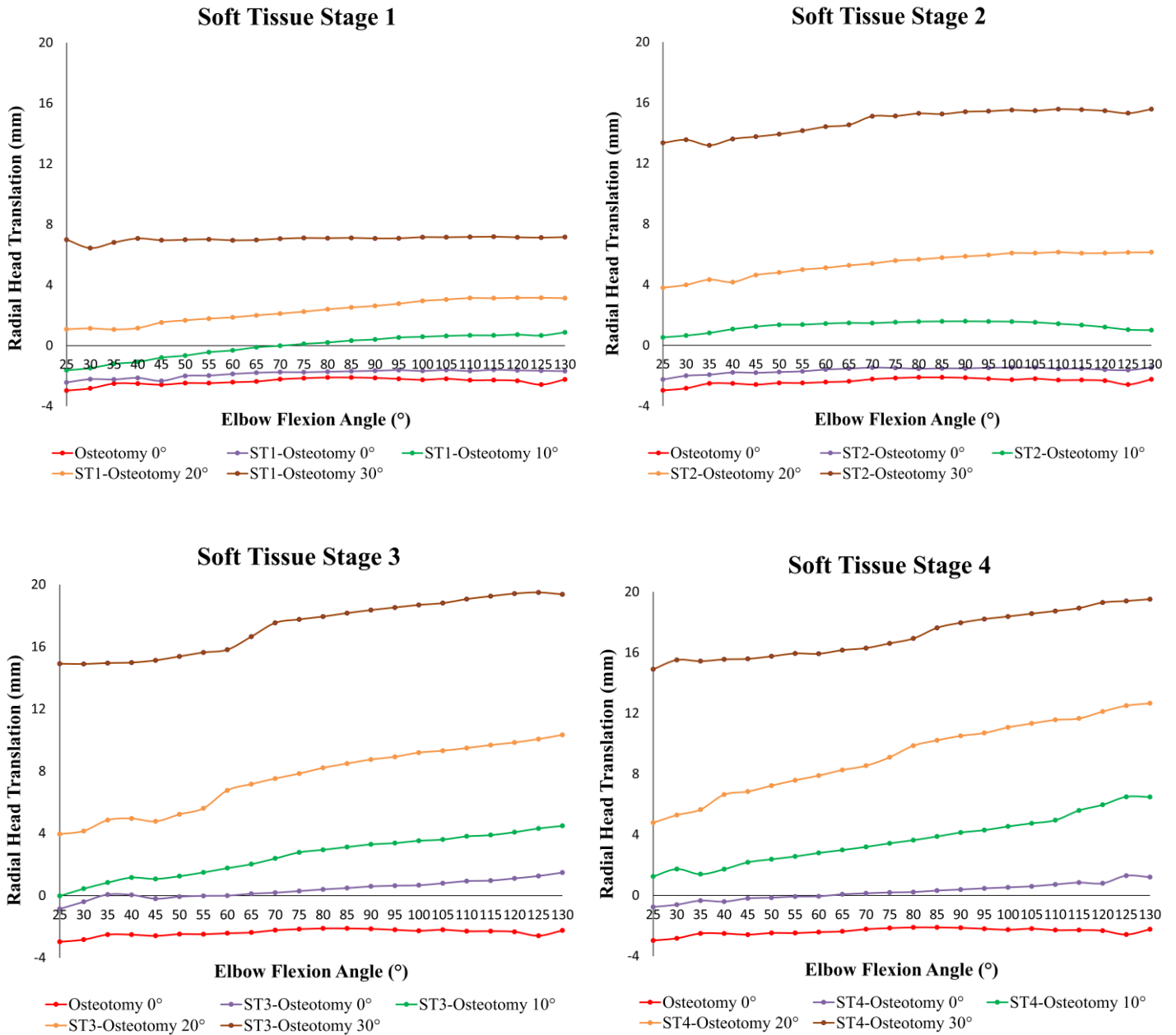


Figure 2.7: Radial head translation with progressive ulnar angulation in stage 1-4 soft tissue sectioning during active elbow flexion.

There was a significant increase in anterior radial head translation with progressive ulnar extension angulation (osteotomy angulation 10° vs. 0°: $P=.044$; osteotomy angulation 20° vs. 10°: $P=.006$; osteotomy angulation 30° vs. 20°: $P=.001$).

Increasing values of translation indicate anterior translation and decreasing values indicate posterior translation. The standard deviations (omitted from the graph for clarity) ranged from 3.4mm to 4.9mm. ST1: Soft tissue sectioning stage 1; ST2: Soft tissue sectioning stage 2; ST3: Soft tissue sectioning stage 3; ST4: Soft tissue sectioning stage 4.

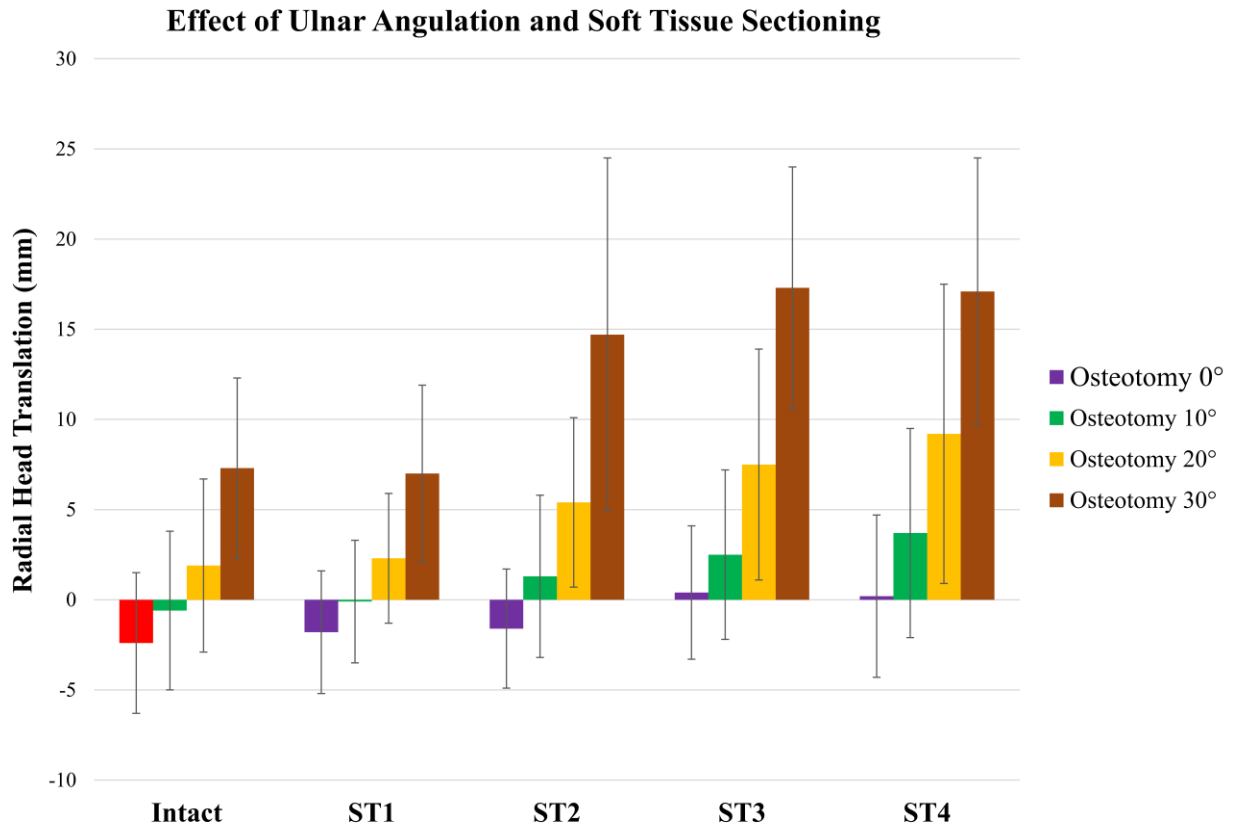


Figure 2.8: Effect of ulnar angulation and soft tissue sectioning on radial head translation. The means and standard deviations of the radial head translation for all osteotomy angulations during the intact and soft tissue sectioning stages are plotted. There was a significant increase in radial head translation with increasing ulnar angulation ($P=.000$). There was also a significant increase in radial head translation with sequential soft tissue sectioning ($P=.000$). Increasing values of translation indicate anterior translation and decreasing values indicate posterior translation. ST1: Soft tissue sectioning stage 1; ST2: Soft tissue sectioning stage 2; ST3: Soft tissue sectioning stage 3; ST4: Soft tissue sectioning stage 4.

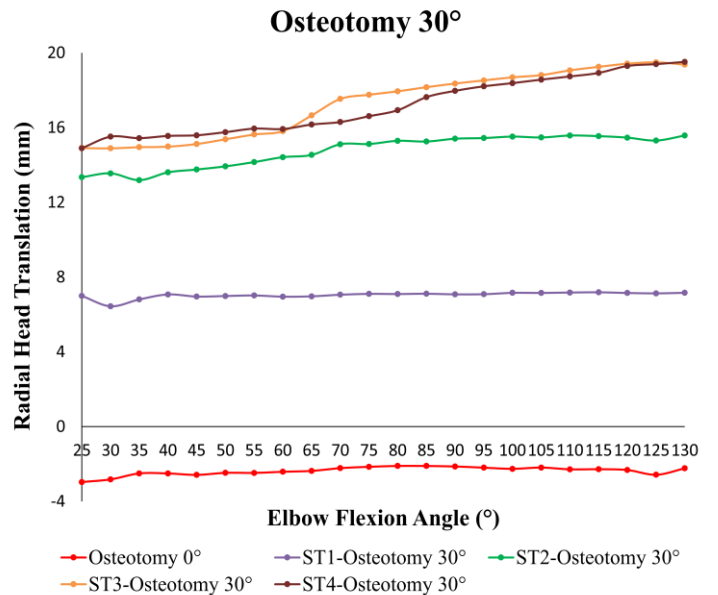
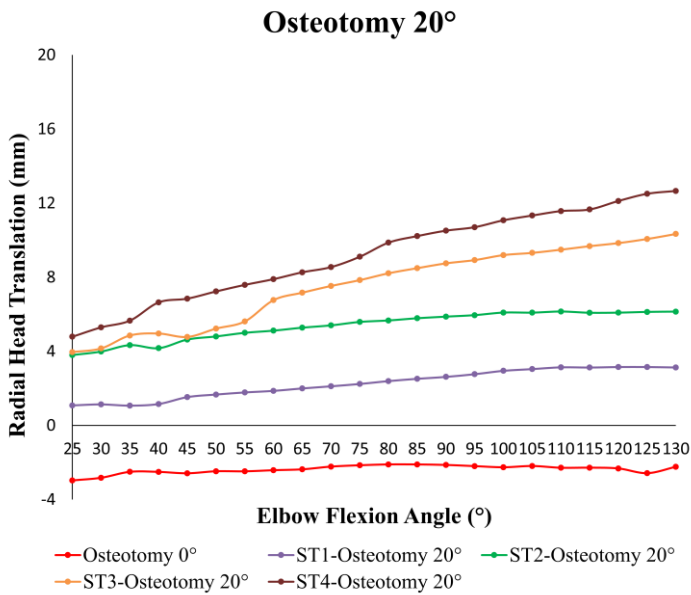
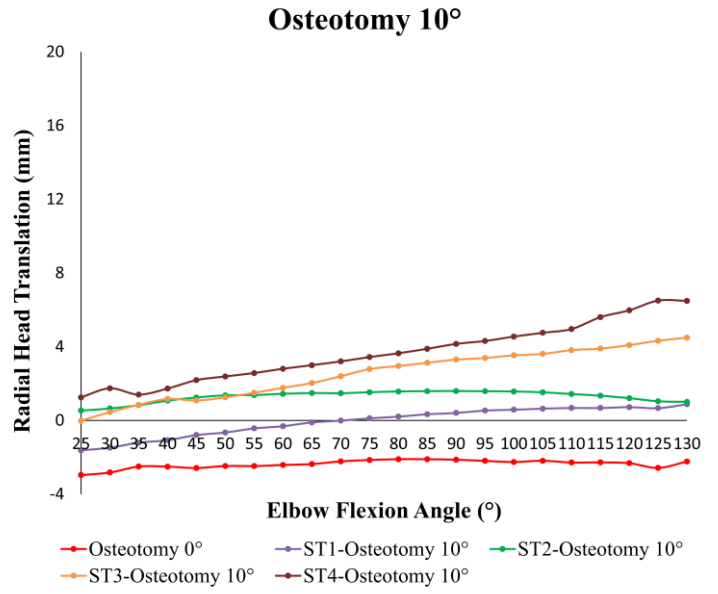
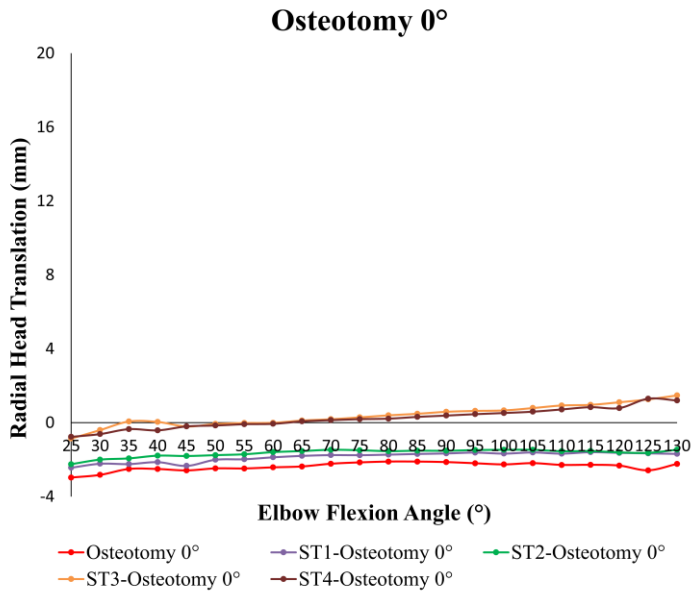


Figure 2.9: Radial head translation with progressive soft tissue sectioning in 0°-30° of ulnar angulation during active elbow flexion.

There was a significant increase in anterior radial head translation with ST3 and ST4 (ST1: $P=1.000$; ST2: $P=.082$; ST3: $P=.025$; ST4: $P=.041$).

Increasing values of translation indicate anterior translation and decreasing values indicate posterior translation. The standard deviations (omitted from the graph for clarity) ranged from 3.3mm to 4.5mm. ST1: Soft tissue sectioning stage 1; ST2: Soft tissue sectioning stage 2; ST3: Soft tissue sectioning stage 3; ST4: Soft tissue sectioning stage 4.

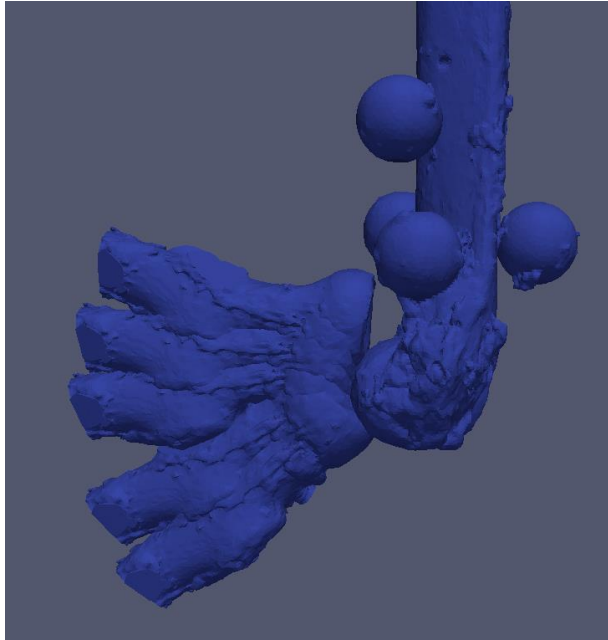


Figure 2.10: A three-dimensional representation of anterior radial head translation during elbow flexion with ulnar osteotomy at 20° of extension angulation and stage 3 soft tissue sectioning.

The three-dimensional images of the proximal radius represent the position of the radial head at 30°, 40°, 70°, 100°, and 130° of elbow flexion respectively. Note the increasing anterior translation of the radial head with increasing elbow flexion.

2.4 Discussion

Recurrent or persistent radial head subluxation/dislocation has been reported despite numerous surgical procedures that have been proposed for the management of anterior Monteggia injuries.^{8,12,14,30} A better understanding of the factors that contribute to this instability is essential to optimize the outcomes of these injuries.

This biomechanical investigation demonstrates that increasing extension angulation of the ulna with or without soft tissue injury results in progressive anterior radial head translation. A previous biomechanical study showed the same trend but only with up to 10° of ulnar extension malalignment.³¹ Moreover, they only considered the effect of annular ligament insufficiency during ulnar angulation and did not evaluate the impact of the anterior joint capsule and the IOM. Furthermore, the elbow motion was simulated with the application of a 50:50 load to only the biceps and brachialis. Other studies have suggested loads in these muscles vary throughout the elbow motion and the importance of brachioradialis in elbow flexion motion.^{18,21,32} Our results show that as little as 10° of ulnar extension angulation is sufficient to produce a significant anterior radial head translation. Interestingly, this effect was seen even in the absence of soft tissue injury. Clinically, anterior radial head dislocation has been observed in conjunction with subtle misalignment of the ulna and even with only a plastic deformation.³³⁻³⁵ Our results show a non-linear relationship in the magnitude of radial head translation between each subsequent stage of ulnar extension malalignment with a greater relative magnitude of radial head translation in higher degrees of ulnar extension angulation. In this model, higher degrees of ulnar angulation resulted in a relative lengthening of the ulna as the apex of the angulation was at the dorsal surface of the ulna. This lengthening allows for an axial traction force to be applied on the radius through the intact portion of the IOM resulting in the loss of concavity compression at the radiocapitellar joint. Without this concavity compression, greater magnitudes of radial head translation could occur.³⁶⁻
38

Evaluating the effects of progressive soft tissue insufficiency in Monteggia injuries, our study demonstrates no significant radial head translation with sectioning of the anterior joint capsule. Although clinically, an anterior capsular injury might be a part of the spectrum of soft tissue injuries in Monteggia lesions, an isolated capsular injury without injury to the annular ligament

would likely be rare due to the primary stabilizing effect of the annular ligament. In our experiment, additional sectioning of the annular ligament and the quadratus ligament resulted in an increase in anterior radial head translation which approached but did not reach statistical significance. This finding is consistent with previous anatomic and biomechanical studies which have shown worsening radial head subluxation with a torn annular ligament in Monteggia injuries.^{31,39} The lack of statistical significance in our study is likely related to our limited sample size. A larger sample size should be considered in future studies evaluating the role of these structures in the stability of anterior Monteggia injuries. Additional sectioning of the proximal and then the middle IOM resulted in a statistically significant anterior radial head translation. To our knowledge, no previous biomechanical study has investigated the contribution of the IOM to radial head stability in Monteggia injuries. However, other studies have shown significant contributions of the proximal and middle IOM to the instability pattern of pure radial head dislocations.^{40,41} Hayami et al. showed no significant radial head translation with sectioning of the anterior joint capsule, annular ligament and the quadratus ligament.⁴¹ However, significant anterior radial head translation occurred after sectioning of the proximal half of the IOM. Anderson et al. found significant anterior radial head translation only after sectioning of the central band of the IOM.⁴⁰ The major limitation of these studies is that the cadaveric specimens were dissected free of all muscles, tendons and skin; thus, the dynamic effect of these structures on radial head stability was not accounted for. Moreover, these experiments did not examine radial head stability during more physiologic loading conditions of simulated elbow flexion.

With the soft tissues intact, our results show no significant effect of elbow flexion angle on radial head translation even with up to 30° of ulnar extension angulation. This effect is likely due to the intact anterior soft tissue structures (i.e. anterior joint capsule and annular ligament). Although increasing extension angulation of the ulna resulted in an anterior translation of the radial head, these intact soft tissue structures prevented further translation of the radial head throughout elbow flexion. Interestingly, after soft tissue sectioning, our results show a worsening of the anterior radial head translation in higher degrees of elbow flexion particularly during later stages of soft tissue sectioning and at larger degrees of ulnar extension angulation. Deficient soft tissue stabilizers, particularly the IOM, permit greater displacement of the radius. In the setting of this increased instability, worsening radial head translation may be related to greater activation of the biceps muscle in higher degrees of elbow flexion.⁴²

Our study has several strengths. The previous biomechanical study investigating the effect of ulnar angulation on radial head stability only evaluated 0°, 5° and 10° of ulnar extension malalignment.³¹ However, a multicenter study evaluating fracture characteristics in 112 cases of acute Monteggia fractures reported the average ulnar angulation at presentation was 19.6°±14.4°.⁴³ Thus, we evaluated up to 30° of ulnar angulation in this study. Despite an anatomic reduction of the ulnar fracture in Monteggia injuries, persistent or recurrent subluxation/dislocation of the radial head has been reported.^{8,14,30,44} In such cases, disruption of other soft tissue structures in addition to the anterior joint capsule should be expected based on the results of the current investigation. Several studies have shown torn or incarcerated annular ligament in Monteggia injuries with the incidence ranging from 17-100%.^{7,17,44-48} However, the involvement of other soft tissue structures, such as the IOM, has not been fully investigated. Our results demonstrate that after sectioning of the anterior joint capsule, even with 30° of ulnar extension angulation, the average anterior radial head translation was only 9.5 mm relative to the intact state. Thus, in cases with a greater magnitude of anterior radial head translation, disruption of other soft tissue structures, such as the annular ligament, quadratus ligament and the IOM, should be considered. Future clinical studies should evaluate the integrity of the IOM in acute and chronic Monteggia injuries. A better characterization of the pattern of soft tissue injuries in anterior Monteggia lesions may provide further clues on the etiology of persistent radial head instability despite an anatomic reduction of the ulnar fracture.

This study is not without its limitations. In this cadaveric biomechanical model of anterior Monteggia injuries, a transverse osteotomy was performed and maintained in various degrees of extension angulation using a rigid custom-designed jig which would not allow for fracture collapse and shortening of the forearm length. However, other fracture patterns, such as oblique and comminuted fractures, are encountered clinically. Moreover, with fracture comminution and shortening, there is a change in forearm length relationship which may influence the magnitude of soft tissue injury and stability of Monteggia lesions. Furthermore, these injuries generally occur in younger individuals than the cadaveric specimens used in our study. Less soft tissue compliance in older specimens may underestimate the amount of radial head translation encountered clinically. The effect of a different sequence of soft tissue sectioning was not evaluated in this study. However, a previous biomechanical study examining the effect of these soft tissue structures on pure radial head dislocations concluded that the order in which these soft tissues were sectioned did not have a significant effect on radial head instability.⁴⁰ In our study, the lack of statistical

significance in radial head translation after annular ligament sectioning may be related to our sample size. A larger sample size should be considered in future studies. We had initially planned to examine these effects on eight cadaveric specimens; however, a complete set of data was not available for two specimens because of a failure to maintain 30° of ulnar extension angulation in the intact soft tissue state. Although ulnar extension angulation resulted in progressive anterior translation of the radial head with or without concomitant soft tissue disruptions, increasing force was required to achieve higher degrees of ulnar angulation with the soft tissues intact which resulted in the shaft of our jig to break upon angulating the ulnar osteotomy to 30° in the intact soft tissue state in the two experiments. However, we were able to easily angulate the ulnar osteotomy site even up to 30° with progressive stages of soft tissue disruption. Based on this observation, clinically it is unlikely for the ulnar fracture to maintain this degree of deformity when the soft tissues are intact. Finally, the effect of forearm rotation and muscle activation which could also play a role in radial head stability in Monteggia lesions were not investigated.

The results of this biomechanical investigation have several clinical implications. Our results demonstrate that residual angulation of the ulnar fracture contributes to radial head instability in anterior Monteggia injuries. Thus, an anatomic reduction and restoration of the ulnar alignment are crucial. Moreover, in cases with significant radial head displacement or persistent instability despite an anatomic reduction of the ulna, disruption of more than just the anterior joint capsule, particularly the annular ligament, quadrate ligament, and the IOM should be considered. Our results may also have implications for the surgical approaches and management of anterior Monteggia injuries. In such cases, the annular ligament, if possible, and the IOM should be protected; further studies evaluating the effectiveness of annular ligament and IOM repair or reconstruction are required.

2.5 Conclusions

This biomechanical investigation demonstrates that progressive ulnar extension angulation in anterior Monteggia injuries results in an incremental increase in anterior radial head translation. Moreover, increasing the magnitude of soft tissue disruption results in progressive anterior radial head instability. Injury to the annular ligament and the IOM should be suspected in anterior Monteggia lesions with a large amount of anterior radial head displacement or in patients with persistent anterior radial head translation despite an anatomic reduction of the ulna.

2.6 References

1. Monteggia GB. Lussazioni della ossa delle estremita superiori. *Instituzioni Chirurgisches*. 1814;5:131-133.
2. Bado JL. The Monteggia lesion. *Clinical orthopaedics and related research*. 1967;50:71-86.
3. Ring D, Jupiter JB, Simpson NS. Monteggia fractures in adults. *J Bone Joint Surg Am*. 1998;80(12):1733-1744.
4. Guitton TG, Ring D, Kloen P. Long-term evaluation of surgically treated anterior monteggia fractures in skeletally mature patients. *J Hand Surg Am*. 2009;34(9):1618-1624.
5. Konrad GG, Kundel K, Kreuz PC, Oberst M, Sudkamp NP. Monteggia fractures in adults: long-term results and prognostic factors. *J Bone Joint Surg Br*. 2007;89(3):354-360.
6. Givon U, Pritsch M, Levy O, Yosepovich A, Amit Y, Horoszowski H. Monteggia and equivalent lesions. A study of 41 cases. *Clin Orthop Relat Res*. 1997(337):208-215.
7. Reynders P, De Groote W, Rondia J, Govaerts K, Stoffelen D, Broos PL. Monteggia lesions in adults. A multicenter Bota study. *Acta Orthop Belg*. 1996;62 Suppl 1:78-83.
8. Beutel BG. Monteggia fractures in pediatric and adult populations. *Orthopedics*. 2012;35(2):138-144.
9. Bae DS, Waters PM. Surgical treatment of acute and chronic monteggia fracture-dislocations. *Operative Techniques in Orthopaedics*. 2005;15:308-314.
10. Bae DS. Successful Strategies for Managing Monteggia Injuries. *J Pediatr Orthop*. 2016;36 Suppl 1:S67-70.
11. Chin K, Kozin SH, Herman M, et al. Pediatric Monteggia Fracture-Dislocations: Avoiding Problems and Managing Complications. *Instr Course Lect*. 2016;65:399-407.
12. Dormans JP, Rang M. The problem of Monteggia fracture-dislocations in children. *Orthop Clin North Am*. 1990;21(2):251-256.
13. Ring D, Waters PM. Operative fixation of Monteggia fractures in children. *J Bone Joint Surg Br*. 1996;78(5):734-739.
14. Goyal T, Arora SS, Banerjee S, Kandwal P. Neglected Monteggia fracture dislocations in children: a systematic review. *J Pediatr Orthop B*. 2015;24(3):191-199.
15. Bae DS. Successful Strategies for Managing Monteggia Injuries. *J Pediatr Orthop*. 2016;36 Suppl 1:S67-70.

16. Nakamura K, Hirachi K, Uchiyama S, et al. Long-term clinical and radiographic outcomes after open reduction for missed Monteggia fracture-dislocations in children. *J Bone Joint Surg Am.* 2009;91(6):1394-1404.
17. Rodgers WB, Waters PM, Hall JE. Chronic Monteggia lesions in children. Complications and results of reconstruction. *J Bone Joint Surg Am.* 1996;78(9):1322-1329.
18. Johnson JA, Rath DA, Dunning CE, Roth SE, King GJ. Simulation of elbow and forearm motion in vitro using a load controlled testing apparatus. *J Biomech.* 2000;33(5):635-639.
19. Dunning CE, Duck TR, King GJ, Johnson JA. Simulated active control produces repeatable motion pathways of the elbow in an in vitro testing system. *J Biomech.* 2001;34(8):1039-1048.
20. Dunning CE, Gordon KD, King GJ, Johnson JA. Development of a motion-controlled in vitro elbow testing system. *J Orthop Res.* 2003;21(3):405-411.
21. Ferreira LM, Johnson JA, King GJ. Development of an active elbow flexion simulator to evaluate joint kinematics with the humerus in the horizontal position. *J Biomech.* 2010;43(11):2114-2119.
22. Noda K, Goto A, Murase T, Sugamoto K, Yoshikawa H, Moritomo H. Interosseous membrane of the forearm: an anatomical study of ligament attachment locations. *J Hand Surg Am.* 2009;34(3):415-422.
23. Nakamura T, Yabe Y, Horiuchi Y. Functional Anatomy of the Interosseous Membrane of the Forearm - Dynamic Changes During Rotation. *Hand Surg.* 1999;4(1):67-73.
24. Mori K. Experimental study on rotation of the forearm--functional anatomy of the interosseous membrane. *Nihon Seikeigeka Gakkai zasshi.* 1985;59(6):611-622.
25. Adams JE. Forearm Instability: Anatomy, Biomechanics, and Treatment Options. *J Hand Surg Am.* 2017;42(1):47-52.
26. Lalone EA, Peters TM, King GW, Johnson JA. Accuracy assessment of an imaging technique to examine ulnohumeral joint congruency during elbow flexion. *Comput Aided Surg.* 2012;17(3):142-152.
27. Lalone EA, McDonald CP, Ferreira LM, Peters TM, King GW, Johnson JA. Development of an image-based technique to examine joint congruency at the elbow. *Comput Methods Biomech Biomed Engin.* 2013;16(3):280-290.
28. Lalone EA, Giles JW, Alolabi B, Peters TM, Johnson JA, King GJ. Utility of an image-based technique to detect changes in joint congruency following simulated joint injury and repair: an in vitro study of the elbow. *J Biomech.* 2013;46(4):677-682.
29. Lalone EA. *An Image-Based Tool to Examine Joint Congruency at the Elbow: Biomedical Engineering*, The University of Western Ontario; 2012.

30. Nakamura K, Hirachi K, Uchiyama S, et al. Long-Term Clinical and Radiographic Outcomes After Open Reduction for Missed Monteggia Fracture-Dislocations in Children. *The Journal of Bone and Joint Surgery-American Volume*. 2009;91:1394-1404.
31. Sandman E, Canet F, Petit Y, Laflamme GY, Athwal GS, Rouleau DM. Radial Head Subluxation After Malalignment of the Proximal Ulna. *J Orthop Trauma*. 2014;28:464-469.
32. Funk DA, An KN, Morrey BF, Daube JR. Electromyographic analysis of muscles across the elbow joint. *J Orthop Res*. 1987;5(4):529-538.
33. Greer A, Lowry CJ, Ramlakhan S. Ipsilateral Plastic Deformation Monteggia and Galeazzi-Type Fracture in a Child: A Case Report. *Ann Emerg Med*. 2017;69(5):632-634.
34. Goh SH. Monteggia 'fracture'-dislocation with bowing of the ulna: a pitfall for the unwary emergency physician. *Eur J Emerg Med*. 2008;15(5):281-282.
35. Borden St. Traumatic bowing of the forearm in children. *J Bone Joint Surg Am*. 1974;56(3):611-616.
36. Pomianowski S, Morrey BF, Neale PG, Park MJ, O'Driscoll SW, An KN. Contribution of monoblock and bipolar radial head prostheses to valgus stability of the elbow. *J Bone Joint Surg Am*. 2001;83-a(12):1829-1834.
37. Judet T, Garreau de Loubresse C, Piriou P, Charnley G. A floating prosthesis for radial-head fractures. *J Bone Joint Surg Br*. 1996;78(2):244-249.
38. Chanlalit C, Shukla DR, Fitzsimmons JS, Thoreson AR, An KN, O'Driscoll SW. Radiocapitellar stability: the effect of soft tissue integrity on bipolar versus monopolar radial head prostheses. *J Shoulder Elbow Surg*. 2011;20(2):219-225.
39. Spinner M, Kaplan EB. The quadratus ligament of the elbow--its relationship to the stability of the proximal radio-ulnar joint. *Acta Orthop Scand*. 1970;41(6):632-647.
40. Anderson A, Werner FW, Tucci ER, Harley BJ. Role of the interosseous membrane and annular ligament in stabilizing the proximal radial head. *J Shoulder Elbow Surg*. 2015;24(12):1926-1933.
41. Hayami N, Omokawa S, Iida A, et al. Biomechanical study of isolated radial head dislocation. *BMC Musculoskelet Disord*. 2017;18(1):470.
42. Kleiber T, Kunz L, Disselhorst-Klug C. Muscular coordination of biceps brachii and brachioradialis in elbow flexion with respect to hand position. *Front Physiol*. 2015;6:215.
43. Ramski DE, Hennrikus WP, Bae DS, et al. Pediatric Monteggia Fractures: A Multicenter Examination of Treatment Strategy and Early Clinical and Radiographic Results. *J Pediatr Orthop*. 2014;00:1-6.

44. Tan JW, Mu MZ, Liao GJ, Li JM. Pathology of the annular ligament in paediatric Monteggia fractures. *Injury*. 2008;39(4):451-455.
45. Hamaker M, Zheng A, Eglseder WA, Pensy RA. The Adult Monteggia Fracture: Patterns and Incidence of Annular Ligament Incarceration Among 121 Cases at a Single Institution Over 19 Years. *J Hand Surg Am*. 2018;43(1):85 e81-85 e86.
46. Reckling FW. Unstable fracture-dislocations of the forearm (Monteggia and Galeazzi lesions). *J Bone Joint Surg Am*. 1982;64(6):857-863.
47. Boyd HB, Boals JC. The Monteggia lesion. A review of 159 cases. *Clin Orthop Relat Res*. 1969;66:94-100.
48. Smith FM. Monteggia fractures; an analysis of 25 consecutive fresh injuries. *Surg Gynecol Obstet*. 1947;85(5):630-640.

Chapter 3

3 The Role of Biceps Loading and Muscle Activation on Radial Head Stability in Anterior Monteggia Injuries

Little evidenced-based information is available to direct the optimal rehabilitation of patients with anterior Monteggia injuries. This chapter examines the effect of biceps loading on radial head stability in these injuries. Moreover, we studied the effect of simulated active and passive elbow motion on radial head translation in these injuries.

3.1 Introduction

[NB: A portion of this material was presented in Chapter 1 and Chapter 2 and is also included here in order to ensure that this chapter is in “article” format]

Bado type I Monteggia injuries represent an apex anterior fracture of the proximal or middle third of the ulna and an anterior dislocation of the radial head.¹ Various factors, such as ulnar extension angulation, hyperpronation of the forearm and biceps loading, have been proposed in the development and stability of these injuries.¹⁻⁴ In 1971, Tompkins proposed that during a fall on an outstretched hand, the radial head dislocates anteriorly due to a violent reflex contraction of the biceps (Chapter 1, Figure 1.25).³

Anatomic reduction of the ulnar deformity is critical to the successful management of these injuries.⁵⁻¹⁰ However, the optimal postoperative rehabilitation remains unknown. Muscle activation and early active motion has been shown to improve elbow instability following fractures and dislocations.¹¹⁻¹⁶ To our knowledge, no previous study has investigated whether active or passive elbow range of motion (ROM) can be safely employed in the postoperative rehabilitation of patients with anterior Monteggia injuries. It has been suggested that biceps tension may play a role in recurrent subluxation or dislocation of the radial head in Monteggia injuries, hence some authors recommend immobilization of the elbow in flexion following reduction of the ulna.^{17,18} The contribution of biceps contraction to radial head stability in anterior Monteggia injuries has not been investigated. A better understanding of the effect of biceps loading would allow optimization of the rehabilitation protocols for patients with these injuries. The aims of this biomechanical investigation were: 1) to quantify the effect of biceps loading on radial head

translation in anterior Monteggia injuries; and 2) to compare the effect of simulated active and passive elbow flexion on radial head stability in these injuries. We hypothesized that: 1) biceps loading increases anterior radial head instability in these injuries; and 2) simulated active elbow flexion results in a greater anterior radial head translation than passive motion.

3.2 Materials and Methods

3.2.1 Specimen Preparation

Six upper limb fresh-frozen cadaveric specimens (mean age at the time of death: 60 ± 8 years) were amputated at the mid-humerus level. Computed tomography was performed to rule out pre-existing elbow or wrist articular pathology and forearm skeletal deformity. Specimens were stored at -20°C and thawed at room temperature ($22^{\circ}\text{C} \pm 2^{\circ}\text{C}$) for 18 hours before testing.

An eight-strand braided fishing line (Hercules, CA, USA; 150lb) was used to suture the distal tendons of the biceps, brachialis, brachioradialis, triceps, and pronator teres in a running locking fashion. The supinator function was simulated using a suture anchor placed at the centre of the bicipital tuberosity. The suture attached to this anchor entered an interosseous tunnel near the supinator crest of the ulna through a guide sleeve and then exited the proximal aspect of the olecranon through another guide sleeve. The distal tendons of the extensor carpi radialis longus and extensor carpi ulnaris were sutured together. The distal tendons of the flexor carpi radialis and flexor carpi ulnaris were also sutured together. After passing the tendon sutures subcutaneously through their respective physiologic compartments, the sutures of the brachioradialis and the wrist extensors were passed through an alignment guide at the supracondylar ridge of the humerus. The sutures of the pronator teres and the wrist flexors were passed through a second alignment guide at the medial epicondyle. The humerus was rigidly mounted into a custom clamp on the base of the elbow motion simulator (Chapter 2, Figure 2.1). All sutures were connected by stainless steel cables to 3 computer-controlled servomotors (for each of biceps, brachialis, and triceps) and 5 pneumatic actuators (for the remaining tendons).

3.2.2 Experimental Simulation

Part I: Isometric Biceps Loading

The effect of biceps loading was examined with the elbow held at 90° of flexion on a platform with the forearm supinated. A custom-designed LabVIEW program (National Instruments, Austin, TX, USA) was used to apply 0N, 20N, 40N, 60N, 80N, and 100N of load to the biceps tendon in a staircase fashion using a servomotor. A compensatory load was applied to the triceps to maintain the elbow at 90° of flexion.

Part II: Simulated Active versus Passive Motion

Simulated active and passive elbow flexion motions were performed with the arm oriented in the vertical dependent position. Simulated active elbow flexion with the forearm supinated was prescribed at a rate of $10^{\circ}/s$ based on previously established protocols that have been validated with this simulator.^{11,19-21} In brief, brachialis was designated as the prime mover during each flexion trial with its load varying as a function of elbow flexion angle feedback. The load through the other elbow flexors was a constant ratio of the load through the prime mover, with the biceps load being 52% of the brachialis and the brachioradialis being 29% of the brachialis. Active supination was achieved by applying a 40N load to the supinator via a pneumatic actuator as well as the load through the biceps tendon. To stabilize the wrist in a neutral position, a 10N load was applied to the wrist extensors and the wrist flexors via pneumatic actuators. Simulated passive elbow motion was performed by one investigator (A.B.) by manually grasping the wrist to passively rotate the forearm into full supination until a definite endpoint of ROM was reached and then gently moving the elbow through flexion arc at approximately $10^{\circ}/s$.

3.2.3 Testing Protocol

Before testing, 5 simulated active and 5 passive preconditioning cycles of elbow flexion and extension with the forearm maintained in supination were performed. Two trials were conducted for each active and passive motion, and the average values were used for analysis. Data were collected for 5 seconds for each isometric biceps loading trial and the average values during that period were used for analysis.

Testing was first conducted for the intact state. A custom jig was used to maintain the osteotomized ulna in the same alignment as the intact ulna to simulate an anatomic reduction (labeled 0°) (Chapter 2, Figure 2.2). The osteotomy was planned at the junction of the proximal and middle third of the ulna. This location was determined based on the measurements of the ulnar length from the preoperative CT images. The jig was fixed to the ulna using three 3.5mm cortical screws on each side of the osteotomy. A measurement point was etched in the centre of each of the pins housing the lead screw and the distance between these two points was measured using a digital caliper (Empire, WI, USA). This distance was recorded and checked at each stage to ensure maintenance of the osteotomy site at its baseline alignment. Moreover, nuts were placed on each

side of the pins to maintain this alignment. The osteotomy was made using a surgical saw (ConMed, FL, USA; width 9.5mm; thickness 0.60mm).

For soft tissue sectioning stages, dissection was carried out through an anterior Henry approach to gain access to the anterior radiocapitellar joint capsule, annular ligament, quadrate ligament and the IOM. In stage 1, the anterior joint capsule was sectioned horizontally from the lateral to medial width of the radial head. In stage 2, the annular ligament and the quadrate ligament, which was present in 4 of our specimens, were sectioned. In stage 3, the proximal portion of the IOM was sectioned. The proximal IOM, which is comprised of the proximal and dorsal oblique cords, is orientated from proximal-ulnar to distal-radial.²²⁻²⁴ While protecting the biceps tendon insertion, the radial attachment of the proximal IOM was sectioned from the bicipital tuberosity to the interosseous crest of the radius. In stage 4, the central band of the IOM was sectioned. The central band has the opposite orientation compared to the proximal IOM and is oriented obliquely from proximal-radial to distal-ulnar. In this stage, the entire length of the radial origin of the central band at the interosseous crest was sectioned.^{22,25}

3.2.4 Kinematic Data Acquisition

An optical tracking system (Optotrak Certus; Northern Digital, Waterloo, ON, Canada) was used to track the motion of the radial head.²⁶⁻²⁹ The Optotrak motion capture camera system tracked infrared light that was emitted from optical position sensors mounted on the radius, ulna and the humerus (Chapter 2, Figure 2.3). To maintain an in-plane accuracy of 0.1mm and 0.15mm perpendicular to the camera, a direct line of sight between the camera and the position sensors was maintained within 2.5m.

Upon completion of the testing protocol, each specimen was denuded of all soft tissues with the optical position sensors left attached for digitization. A clinically relevant coordinate system was created by digitizing anatomic landmarks with a calibrated tracked stylus.¹⁹

To quantify radial head translation, a coordinate system was placed on the radial head with the origin at the deepest point of the radial dish. The y-axis of this coordinate system represents translation along the anterior-posterior plane (Chapter 2, Figure 2.4). The radial head translation was quantified as the distance between the deepest portion of the radial dish to the centre of the

capitellum along the y-axis of the radial coordinate system. The centre of the capitellum was found by sphere-fitting a digitization of the capitellum and extracting the centre of the sphere. In the biceps loading experiment, radial head translation for any given state was compared to the intact state. To utilize a comparable metric to the stationary bicep data at 90 degrees, the average radial head translation for the entire elbow flexion arc was determined for each injured state and compared to the intact state for the active and passive motion experiments.

3.2.5 Statistical Methods

Kinematic data were analyzed using SPSS 23 statistical software (SPSS Inc, Chicago, IL, USA). A two-way repeated-measures analysis of variance (ANOVA) with Bonferroni correction was performed to compare biceps loading and elbow states (intact, osteotomy 0°, soft tissue sectioning stage 1 with osteotomy 0° (ST1-Osteotomy 0°), soft tissue sectioning stage 2 with osteotomy 0° (ST2-Osteotomy 0°), soft tissue sectioning stage 3 with osteotomy 0° (ST3-Osteotomy 0°), soft tissue sectioning stage 4 with osteotomy 0° (ST4-Osteotomy 0°)). A one-way ANOVA was performed to compare biceps loading between different elbow states.

A two-way repeated-measures ANOVA was then performed to compare muscle activation (active versus passive motion) and above-mentioned elbow states.

Data for the entire flexion-extension arc of motion was not always available due to line of sight issues with the optical tracking system most commonly at the extremes of the flexion-extension arc. Linear interpolation was used to estimate missing values when needed (approximately 1% of active/passive data were interpolated). Statistical significance was set at $\alpha = .05$.

3.3 Results

Part I: Isometric Biceps Loading

Greater magnitudes of biceps loading significantly increased anterior radial head translation ($P=.000$). Post hoc analysis demonstrated that all the loads resulted in a significant increase in anterior radial head translation compared to no biceps loading (20N: $P=.043$; 40N: $P=.008$; 60N: $P=.005$; 80N: $P=.007$; 100N: $P=.004$) (Figure 3.1; Table 3.1). The progressive injury states had a significant effect on radial head translation ($P=.000$). Post hoc analysis demonstrated no significant difference in radial head translation between osteotomy 0° and the intact state ($P=1.000$). Moreover, there was no significant increase in radial head translation with sectioning of the anterior joint capsule, the annular ligament, the quadratus ligament and the proximal IOM (ST1-Osteotomy 0° : $P=1.000$; ST2-Osteotomy 0° : $P=1.000$; ST3-Osteotomy 0° : $P=.136$). However, additional sectioning of the middle IOM resulted in a significant increase in anterior radial head translation compared to the intact state ($P=.012$). There was no significant difference in radial head translation after progressive soft tissue sectioning with no biceps loading ($P=.463$).

Part II: Simulated Active versus Passive Motion

There was no significant difference in the average radial head translation throughout flexion between simulated active and passive motion with the forearm supinated ($P=.251$). However, there was a significant interaction between muscle activation and elbow states ($P=.016$). Thus, a paired t-test was performed between active and passive motion trials for each elbow state. This analysis demonstrated a significant increase in anterior radial head translation during passive elbow motion compared to simulated active motion in stage 4 soft tissue sectioning ($P=.039$). There were no significant differences between simulated active and passive elbow motion in other elbow states (Osteotomy 0° : $P=.691$; ST1-Osteotomy 0° : $P=.849$; ST2-Osteotomy 0° : $P=.791$; ST3-Osteotomy 0° : $P=.615$) (Figure 3.2; Table 3.2). There was a significant increase in anterior radial head translation with progressive injury states ($P=.003$).

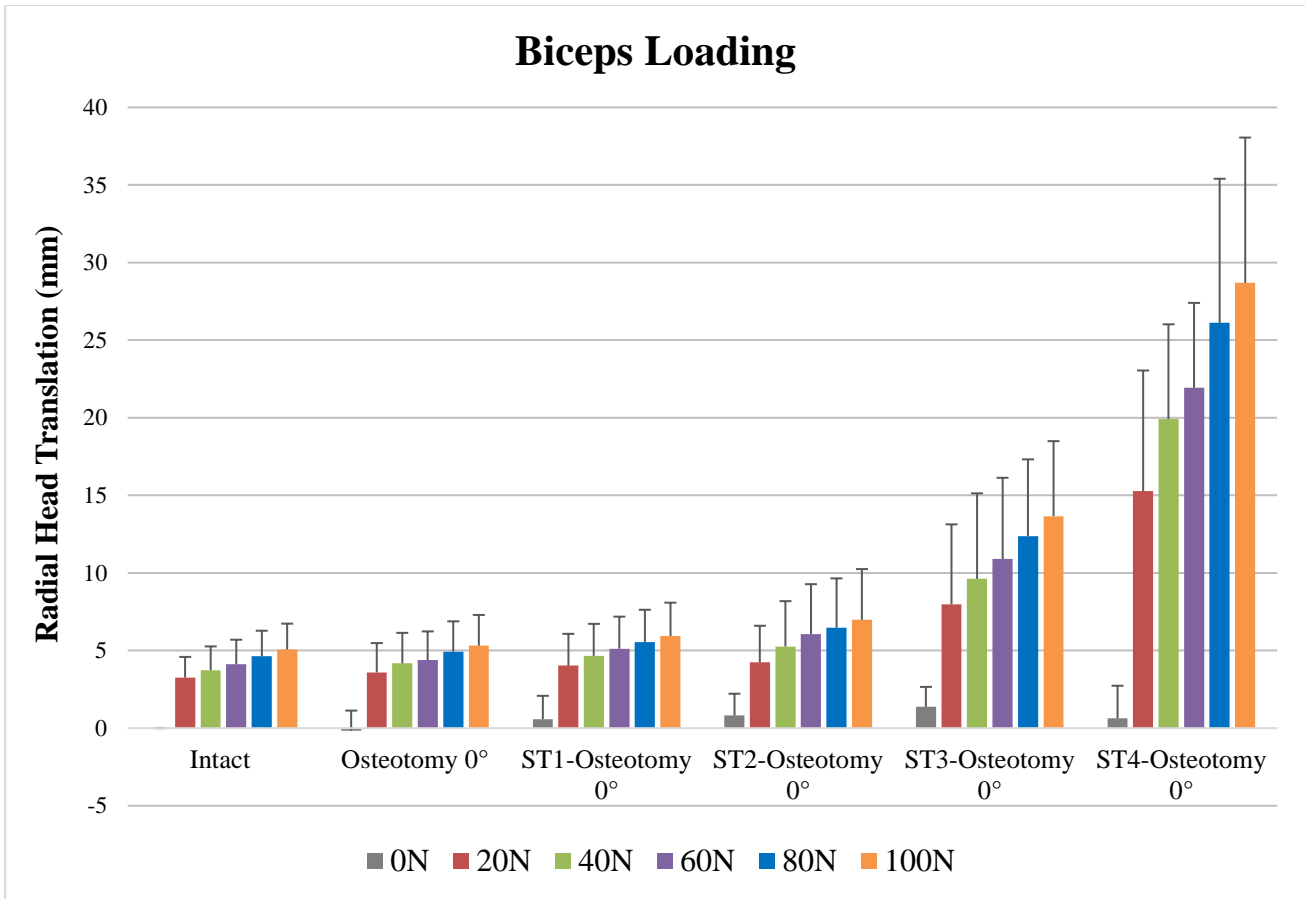


Figure 3.1: Radial head translation with staircase biceps loading.

Biceps loading resulted in a significant increase in anterior radial head translation compared to no biceps loading (20N: $P=.043$; 40N: $P=.008$; 60N: $P=.005$; 80N: $P=.007$; 100N: $P=.004$). There was no significant increase in radial head translation between the intact state and any of the progressive injury states other than in ST4-osteotomy 0° where additional sectioning of the middle IOM resulted in a significant increase in anterior radial head translation (Osteotomy 0°: $P=1.000$; ST1-Osteotomy 0°: $P=1.000$; ST2-Osteotomy 0°: $P=1.000$; ST3-Osteotomy 0°: $P=.136$; ST4-Osteotomy 0°: $P=.012$).

Positive values indicate anterior translation and negative values indicate posterior translation. ST1: Soft tissue sectioning stage 1; ST2: Soft tissue sectioning stage 2; ST3: Soft tissue sectioning stage 3; ST4: Soft tissue sectioning stage 4

Table 3.1: Effect of Biceps Loading on Radial Head TranslationMean±SD Radial Head Translation[†] (mm)

Biceps Load	Intact	Osteotomy 0°	ST1-	ST2-	ST3-	ST4-	<i>P</i>
			Osteotomy 0°	Osteotomy 0°	Osteotomy 0°	Osteotomy 0°	
0 N	0	-0.2±1.3	0.6±1.5	0.8±1.4	1.4±1.3	0.6±2.1	
20 N	3.3±1.3	3.6±1.9	4.0±2.0	4.2±2.4	8.0±5.2	15.3±7.8	.043*
40 N	3.7±1.5	4.2±2.0	4.7±2.1	5.3±2.9	9.6±5.5	19.9±6.1	.008*
60 N	4.1±1.6	4.4±1.8	5.1±2.1	6.1±3.2	10.9±5.5	21.9±5.5	.005*
80 N	4.6±1.6	4.9±2.0	5.5±2.1	6.5±3.2	12.4±4.9	26.1±9.3	.007*
100 N	5.1±1.7	5.3±2.0	5.9±2.1	7.0±3.3	13.7±4.8	28.7±9.4	.004*

SD, standard deviation; ANOVA, analysis of variance[†]For radial head translation, positive values indicate anterior translation and negative values indicate posterior translation*P*-values describe the significance of radial head translation (between biceps loading and no load) as the result of a two-way ANOVA with biceps loading and elbow states.* indicates significance (*P* < .05)

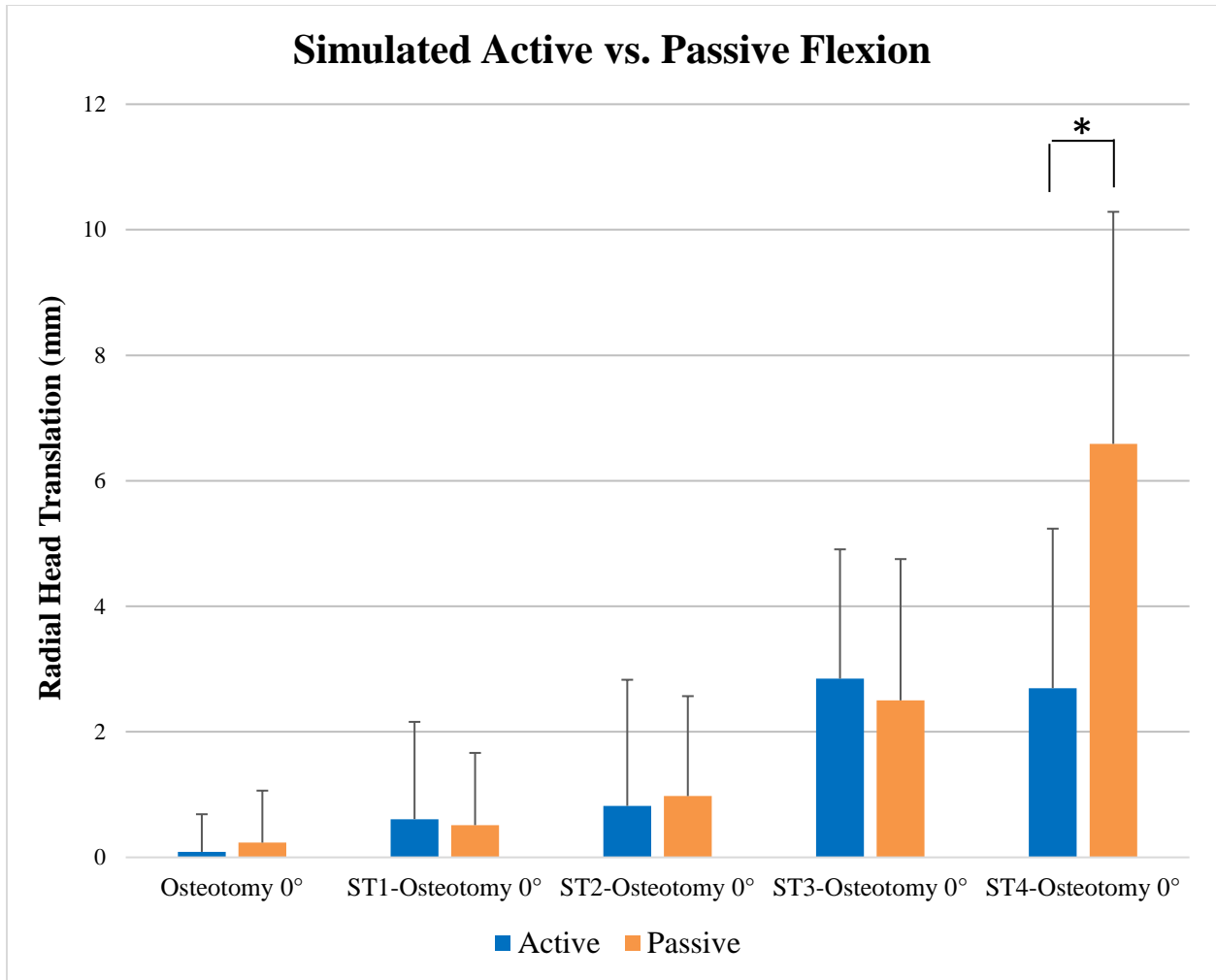


Figure 3.2: Average radial head translation throughout the simulated active and passive elbow flexion.

There was no significant difference in radial head translation between simulated active and passive flexion in all states except in ST4-osteotomy 0° where passive motion resulted in a significant increase in average anterior radial head translation (Osteotomy 0°: $P=.691$; ST1-Osteotomy 0°: $P=.849$; ST2-Osteotomy 0°: $P=.791$; ST3-Osteotomy 0°: $P=.615$; ST4-Osteotomy 0°: $P=.039$). There was a significant increase in anterior radial head translation with progressive soft tissue sectioning ($P=.003$).

Positive values indicate anterior translation and negative values indicate posterior translation. ST1: Soft tissue sectioning stage 1; ST2: Soft tissue sectioning stage 2; ST3: Soft tissue sectioning stage 3; ST4: Soft tissue sectioning stage 4.

** indicates statistical significance ($P<.05$)*

Table 3.2: Effect of Muscle Activation on Radial Head Translation

Muscle Activation	Mean±SD Radial Head Translation [†] (mm)					<i>P</i>	<i>P'</i>	<i>P''</i>	<i>P'''</i>	<i>P''''</i>
	Osteotomy 0°	ST1-Osteotomy 0°	ST2-Osteotomy 0°	ST3-Osteotomy 0°	ST4-Osteotomy 0°					
Active	0.1±0.6	0.6±1.5	0.8±2.0	2.8±2.1	2.7±2.5	.691	.849	.791	.615	.039*
Passive	0.2±0.8	0.5±1.2	1.0±1.6	2.5±2.3	6.6±3.7					

SD, standard deviation; ANOVA, analysis of variance

[†]For radial head translation, positive values indicate anterior translation and negative values indicate posterior translation

P-value describes the significance of radial head translation (between active and passive elbow motion) in Osteotomy 0° state as the result of a paired t-test.

P'-value describes the significance of radial head translation (between active and passive elbow motion) in ST1-Osteotomy 0° state as the result of a paired t-test.

P''-value describes the significance of radial head translation (between active and passive elbow motion) in ST2-Osteotomy 0° state as the result of a paired t-test.

P'''-value describes the significance of radial head translation (between active and passive elbow motion) in ST3-Osteotomy 0° state as the result of a paired t-test.

P''''-value describes the significance of radial head translation (between active and passive elbow motion) in ST4-Osteotomy 0° state as the result of a paired t-test.

* indicates significance ($P < .05$)

3.4 Discussion

Monteggia fracture-dislocations are complex injury patterns with suboptimal outcomes in medium- to long-term follow-up studies, particularly in adults.^{5-8,30-36} Missed injuries, which occur in approximately 25-50% of cases, have poorer outcomes.³⁷⁻³⁹ Although numerous surgical procedures have been proposed, recurrent subluxation/dislocation of the radial head continues to complicate these injuries even when an anatomic reduction of the fracture has been achieved.^{6,35,37,40}

This biomechanical investigation demonstrates that biceps loading has a significant effect on anterior radial head translation. Although no previous biomechanical study has directly investigated the impact of biceps loading on radial head translation, this effect was suggested by Tompkins in his observational hypothesis of anterior Monteggia injuries.³ Moreover, Sandman and colleagues found increasing anterior radial head subluxation with increasing elbow flexion and speculated that this effect might be related to the pull of the biceps during elbow flexion.⁴ Interestingly, loads as low as 20N had a significant effect on radial head translation in our study. Previous studies have shown varying loads in the biceps during active elbow flexion.^{11,19,41-44} In our simulator, the average load in the biceps was 70N with a maximum load of 130N during active elbow flexion. Thus, our static loading protocol applied clinically relevant loads which would likely be seen clinically with early active motion. In the absence of biceps loading, there was no significant radial head translation even in the higher injury states. This supports the clinical observation that relaxation of biceps by placing the elbow in a flexed and supinated position likely aids in maintaining the reduction of the radial head in anterior Monteggia injuries.^{3,45,46}

With the forearm supinated, our results show that there was no significant difference in radial head translation between simulated active and passive elbow motion except in soft tissue sectioning stage 4 where the anterior joint capsule, annular ligament, quadratus ligament, proximal IOM and the middle IOM have all been disrupted. To our knowledge, no previous study has examined the implications of active and passive elbow motion in anterior Monteggia injuries. Contrary to our hypothesis, we did not find greater radial head instability with simulated active elbow flexion, even though our static analysis showed a significant effect with the elbow at 90° of flexion. This discrepancy may be due to the concomitant activation of the supinator muscle in our simulated

active flexion trials. The supinator function was simulated by routing a suture attached to an anchor in the centre of the bicipital tuberosity over the anterior aspect of the radial neck and then through a guide sleeve near the supinator crest. This closely simulates the normal line of action of the supinator between the ulna and proximal radius. The supinator was loaded at 40N to maintain the forearm in supination during simulated active flexion. This likely counteracted the average biceps load of 70 N during active flexion trials to resist anterior translation of the radial head. This effect may also be responsible for the difference in radial head translation between active and passive motion in stage 4 soft tissue sectioning. In this stage, the significant soft tissue injury allowed for a greater amount of anterior radial head translation during passive elbow motion; while activation of the supinator likely prevented the radial head translation during simulated active elbow flexion.

Interestingly, our results show that progressive soft tissue injury caused a significant increase in anterior radial head translation despite maintenance of an anatomic reduction of the ulna. Thus, in the setting of a significant soft tissue injury, particularly with the involvement of the central band of the IOM, restoring the ulnar alignment might not be sufficient to maintain radial head stability. A previous biomechanical study showed that in the setting of annular ligament disruption, the restoration of the initial ulnar alignment was not sufficient to restore radial head alignment.⁴ Clinically, persistent or recurrent subluxation/dislocation of the radial head has been reported in Monteggia injuries despite an anatomic reduction of the ulna.^{6,37,40,47} Some authors have even described overcorrection of the ulna during surgical management of anterior Monteggia injuries.^{40,48,49} In such cases, disruption of the annular ligament, quadratus ligament, or the IOM should be suspected. Future clinical studies should consider evaluating the degree of soft tissue injury in unstable anterior Monteggia fracture-dislocations using magnetic resonance imaging.

To our knowledge, this is the first biomechanical study examining the effect of biceps loading and muscle activation on radial head stability in anterior Monteggia fracture-dislocations. However, this study is not without its limitations. The effects of varying degrees of ulnar extension angulation and forearm rotation were not examined in this study. Moreover, we did not examine the effect of varying loads through the supinator on radial head translation since its significant contribution to radial head stability was not an expected finding. Finally, these injuries generally occur in younger individuals than the cadaveric specimens used in our study. Less soft tissue compliance in older specimens may underestimate the amount of radial head translation encountered clinically.

The results of this biomechanical investigation have several implications in the surgical management and rehabilitation of patients with anterior Monteggia lesions. Our results demonstrate a significant increase in anterior radial head translation with biceps loading and with both simulated active and passive elbow flexion in higher stages of soft tissue injury. Thus, in patients with residual radial head instability after an anatomic reduction of the ulna, the elbow should likely be immobilized at 90° or greater of flexion with the forearm maintained in supination. This allows relaxation of the biceps and avoids movement of the elbow during the early postoperative rehabilitation. Our results also show that activation of the supinator muscle may stabilize the radial head in these injuries. Isometric forearm supination exercises may play a role in the rehabilitation of patients with unstable Monteggia injuries. That said, the ability to target supinator activation clinically and the potential effectiveness of such a rehabilitation protocol has not been established and is theoretical at best. Furthermore, our results demonstrate that anatomic reduction and restoration of the ulnar alignment may not be sufficient to restore radial head alignment particularly with higher degrees of soft tissue injury. Future clinical studies should clarify the pattern of soft tissue injuries in anterior Monteggia fracture-dislocations. A better understanding of this injury pattern may allow the development of better surgical techniques and rehabilitation protocols to enhance patients' outcomes.

3.5 Conclusions

This biomechanical investigation demonstrates that biceps muscle tension has a significant effect on radial head instability in anterior Monteggia injuries. Moreover, there was no significant difference in radial head stability between simulated active and passive elbow flexion except in the setting of significant soft tissue disruption which included sectioning of the central band of the IOM. In such cases, passive motion is preferred. Importantly, this study demonstrated that there was a significant worsening of the anterior radial head instability with progressive soft tissue disruption despite anatomic restoration of the ulnar alignment.

3.6 References

1. Bado JL. The Monteggia lesion. *Clinical orthopaedics and related research*. 1967;50:71-86.
2. Evans EM. Pronation injuries of the forearm, with special reference to the anterior Monteggia fracture. *The Journal of bone and joint surgery British volume*. 1949;31B:578-588, illust.
3. Tompkins DG. The anterior Monteggia fracture: observations on etiology and treatment. *The Journal of bone and joint surgery American volume*. 1971;53:1109-1114.
4. Sandman E, Canet F, Petit Y, Laflamme GY, Athwal GS, Rouleau DM. Radial Head Subluxation After Malalignment of the Proximal Ulna. *J Orthop Trauma*. 2014;28:464-469.
5. Guitton TG, Ring D, Kloen P. Long-term evaluation of surgically treated anterior monteggia fractures in skeletally mature patients. *J Hand Surg Am*. 2009;34(9):1618-1624.
6. Beutel BG. Monteggia fractures in pediatric and adult populations. *Orthopedics*. 2012;35(2):138-144.
7. Konrad GG, Kundel K, Kreuz PC, Oberst M, Sudkamp NP. Monteggia fractures in adults: long-term results and prognostic factors. *J Bone Joint Surg Br*. 2007;89(3):354-360.
8. Ring D, Jupiter JB, Simpson NS. Monteggia fractures in adults. *J Bone Joint Surg Am*. 1998;80(12):1733-1744.
9. Ring D, Jupiter JB, Waters PM. Monteggia fractures in children and adults. *The Journal of the American Academy of Orthopaedic Surgeons*. 1998;6:215-224.
10. Fayaz HC, Jupiter JB. Monteggia fractures in adults. *Acta Chir Orthop Traumatol Cech*. 2010;77(6):457-462.
11. Ferreira LM, Johnson JA, King GJ. Development of an active elbow flexion simulator to evaluate joint kinematics with the humerus in the horizontal position. *J Biomech*. 2010;43(11):2114-2119.
12. Manocha RH, Kusins JR, Johnson JA, King GJ. Optimizing the rehabilitation of elbow lateral collateral ligament injuries: a biomechanical study. *J Shoulder Elbow Surg*. 2017;26(4):596-603.
13. Fraser GS, Pichora JE, Ferreira LM, Brownhill JR, Johnson JA, King GJ. Lateral collateral ligament repair restores the initial varus stability of the elbow: an in vitro biomechanical study. *J Orthop Trauma*. 2008;22(9):615-623.

14. Pichora JE, Fraser GS, Ferreira LF, Brownhill JR, Johnson JA, King GJ. The effect of medial collateral ligament repair tension on elbow joint kinematics and stability. *J Hand Surg Am.* 2007;32(8):1210-1217.
15. Dunning CE, Zarzour ZD, Patterson SD, Johnson Ja, King GJ. Muscle forces and pronation stabilize the lateral ligament deficient elbow. *Clinical orthopaedics and related research.* 2001:118-124.
16. Pipicelli JG, Chinchalkar SJ, Grewal R, Athwal GS. Rehabilitation considerations in the management of terrible triad injury to the elbow. *Tech Hand Up Extrem Surg.* 2011;15(4):198-208.
17. Bae DS, Waters PM. Surgical Treatment of Acute and Chronic Monteggia Fracture-Dislocations. *Operative Techniques in Orthopaedics.* 2005;15(4):308-314.
18. Jepegnanam TS. Salvage of the radial head in chronic adult Monteggia fractures. Report of four cases. *The Journal of bone and joint surgery British volume.* 2006;88:645-648.
19. Johnson JA, Rath DA, Dunning CE, Roth SE, King GJ. Simulation of elbow and forearm motion in vitro using a load controlled testing apparatus. *J Biomech.* 2000;33(5):635-639.
20. Dunning CE, Duck TR, King GJ, Johnson JA. Simulated active control produces repeatable motion pathways of the elbow in an in vitro testing system. *J Biomech.* 2001;34(8):1039-1048.
21. Dunning CE, Gordon KD, King GJ, Johnson JA. Development of a motion-controlled in vitro elbow testing system. *J Orthop Res.* 2003;21(3):405-411.
22. Noda K, Goto A, Murase T, Sugamoto K, Yoshikawa H, Moritomo H. Interosseous membrane of the forearm: an anatomical study of ligament attachment locations. *J Hand Surg Am.* 2009;34(3):415-422.
23. Nakamura T, Yabe Y, Horiuchi Y. Functional Anatomy of the Interosseous Membrane of the Forearm - Dynamic Changes During Rotation. *Hand Surg.* 1999;4(1):67-73.
24. Mori K. Experimental study on rotation of the forearm--functional anatomy of the interosseous membrane. *Nihon Seikeigeka Gakkai zasshi.* 1985;59(6):611-622.
25. Adams JE. Forearm Instability: Anatomy, Biomechanics, and Treatment Options. *J Hand Surg Am.* 2017;42(1):47-52.
26. Lalone EA, Peters TM, King GW, Johnson JA. Accuracy assessment of an imaging technique to examine ulnohumeral joint congruency during elbow flexion. *Comput Aided Surg.* 2012;17(3):142-152.
27. Lalone EA, McDonald CP, Ferreira LM, Peters TM, King GW, Johnson JA. Development of an image-based technique to examine joint congruency at the elbow. *Comput Methods Biomech Biomed Engin.* 2013;16(3):280-290.

28. Lalone EA, Giles JW, Alolabi B, Peters TM, Johnson JA, King GJ. Utility of an image-based technique to detect changes in joint congruency following simulated joint injury and repair: an in vitro study of the elbow. *J Biomech.* 2013;46(4):677-682.
29. Lalone EA. *An Image-Based Tool to Examine Joint Congruency at the Elbow: Biomedical Engineering*, The University of Western Ontario; 2012.
30. Givon U, Pritsch M, Levy O, Yosepovich A, Amit Y, Horoszowski H. Monteggia and equivalent lesions. A study of 41 cases. *Clin Orthop Relat Res.* 1997(337):208-215.
31. Reynders P, De Groot W, Rondia J, Govaerts K, Stoffelen D, Broos PL. Monteggia lesions in adults. A multicenter Bota study. *Acta Orthop Belg.* 1996;62 Suppl 1:78-83.
32. Bae DS, Waters PM. Surgical treatment of acute and chronic monteggia fracture-dislocations. *Operative Techniques in Orthopaedics.* 2005;15:308-314.
33. Bae DS. Successful Strategies for Managing Monteggia Injuries. *J Pediatr Orthop.* 2016;36 Suppl 1:S67-70.
34. Chin K, Kozin SH, Herman M, et al. Pediatric Monteggia Fracture-Dislocations: Avoiding Problems and Managing Complications. *Instr Course Lect.* 2016;65:399-407.
35. Dormans JP, Rang M. The problem of Monteggia fracture-dislocations in children. *Orthop Clin North Am.* 1990;21(2):251-256.
36. Ring D, Waters PM. Operative fixation of Monteggia fractures in children. *J Bone Joint Surg Br.* 1996;78(5):734-739.
37. Goyal T, Arora SS, Banerjee S, Kandwal P. Neglected Monteggia fracture dislocations in children: a systematic review. *J Pediatr Orthop B.* 2015;24(3):191-199.
38. Bae DS. Successful Strategies for Managing Monteggia Injuries. *J Pediatr Orthop.* 2016;36 Suppl 1:S67-70.
39. Rahbek O, Deutch SR, Kold S, Sojbjerg JO, Moller-Madsen B. Long-term outcome after ulnar osteotomy for missed Monteggia fracture dislocation in children. *J Child Orthop.* 2011;5(6):449-457.
40. Nakamura K, Hirachi K, Uchiyama S, et al. Long-Term Clinical and Radiographic Outcomes After Open Reduction for Missed Monteggia Fracture-Dislocations in Children. *The Journal of Bone and Joint Surgery-American Volume.* 2009;91:1394-1404.
41. Roman-Liu D, Bartuzi P. Influence of type of MVC test on electromyography measures of biceps brachii and triceps brachii. *Int J Occup Saf Ergon.* 2018;24(2):200-206.
42. Kleiber T, Kunz L, Disselhorst-Klug C. Muscular coordination of biceps brachii and brachioradialis in elbow flexion with respect to hand position. *Front Physiol.* 2015;6:215.

43. Kotte SHP, Viveen J, Koenraadt KLM, The B, Eygendaal D. Normative values of isometric elbow strength in healthy adults: a systematic review. *Shoulder Elbow*. 2018;10(3):207-215.
44. Funk DA, An KN, Morrey BF, Daube JR. Electromyographic analysis of muscles across the elbow joint. *J Orthop Res*. 1987;5(4):529-538.
45. Wiley JJ, Galey JP. Monteggia injuries in children. *J Bone Joint Surg Br*. 1985;67(5):728-731.
46. Abe M, Kumano H, Kinoshita A, Hirofuji S. Irreducible Dislocation of the Radial Head Associated With Pediatric Monteggia Lesions. *Journal of the American Academy of Orthopaedic Surgeons Global research & reviews*. 2018;2(5):e035.
47. Tan JW, Mu MZ, Liao GJ, Li JM. Pathology of the annular ligament in paediatric Monteggia fractures. *Injury*. 2008;39(4):451-455.
48. Hirayama T, Takemitsu Y, Yagihara K. OPERATION FOR CHRONIC DISLOCATION OF THE RADIAL HEAD IN CHILDREN reduction by the osteotomy of the ulna. *Journal of Bone and Joint*. 1987;69:639-642.
49. Horii E, Nakamura R, Koh S, Inagaki H, Yajima H, Nakao E. Surgical treatment for chronic radial head dislocation. *J Bone Joint Surg Am*. 2002;84-A(7):1183-1188.

Chapter 4

4 Thesis Conclusions

Suboptimal outcomes have been reported in medium to long-term follow-up studies of anterior Monteggia injuries. High rates of complications including recurrent radial head subluxation/dislocation have been reported, particularly in chronic Monteggia lesions. There is a paucity of literature on factors that contribute to radial head instability in these injuries. The purpose of this *in-vitro* biomechanical research was to investigate some of the factors that may contribute to radial head instability in the setting of anterior Monteggia injuries.

This thesis fulfills the objectives presented in Chapter 1 which included:

1. To determine the contribution of ulnar angulation on radial head instability in anterior Monteggia injuries (Chapter 2)
2. To determine the contribution of the anterior joint capsule, annular ligament, quadrate ligament, and the proximal and middle IOM on radial head instability in anterior Monteggia injuries (Chapter 2)
3. To determine the contribution of biceps contraction on radial head instability in anterior Monteggia injuries (Chapter 3)
4. To determine the contribution of muscle activation during simulated active compared to passive elbow flexion on radial head instability in anterior Monteggia injuries (Chapter 3)

The hypotheses and findings described in Chapter 2 and 3 are summarized in the following sections.

4.1 Summary of Chapter 2: Effects of Ulnar Angulation and Soft Tissue Sectioning on Radial Head Stability in Anterior Monteggia Injuries

Our first objective was to study the effect of ulnar extension angulation on radial head stability in anterior Monteggia lesions. We hypothesized that increasing extension angulation of the ulna results in a significant increase in anterior radial head translation. We examined this effect in elbows with or without concomitant soft tissue injuries. Our results showed that increasing ulnar extension angulation with or without concomitant soft tissue disruptions results in a significant incremental increase in anterior radial head translation. Importantly, as little as 10° of ulnar malalignment was enough to cause significant radial head translation. This finding reinforces the importance of an anatomic reduction and restoration of the ulnar alignment in the surgical management of anterior Monteggia injuries.

The second objective of this research was to study the effect of sequential sectioning of the anterior radiocapitellar joint capsule, annular ligament, quadratus ligament, and the proximal and middle IOM on radial head stability in anterior Monteggia injuries. We hypothesized that this sequential soft tissue sectioning results in a significant increase in anterior radial head translation. Our results agreed with this hypothesis and showed that overall, this sequential soft tissue disruption results in a significant increase in anterior radial head translation. In the post hoc analysis, there was no significant difference in radial head translation after sectioning of the anterior joint capsule. This is likely due to the primary stabilizing effect of the remaining annular ligament. Although additional sectioning of the annular ligament and the quadratus ligament increased anterior radial head translation; this difference approached but did not reach statistical significance. This lack of statistical significance is likely related to our sample size. Future studies should further evaluate the effect of the annular ligament and the quadratus ligament disruptions on radial head stability using at least 8 cadaveric specimens based on our sample size calculation to detect statistical significance ($1-\beta=0.8$; $\alpha=0.05$). Additional sectioning of the proximal and then the middle IOM resulted in a significant increase in anterior radial head translation. It is important to note that after sectioning of the anterior joint capsule, even with 30° of ulnar extension angulation, the average anterior radial head translation was only 9.5mm compared to the intact state. Thus, in patients with

greater magnitudes of anterior radial head translation, disruption of the annular ligament, quadrate ligament or the IOM should be suspected.

4.2 Summary of Chapter 3: The Role of Biceps Loading and Muscle Activation on Radial Head Stability in Anterior Monteggia Injuries

Our third objective was to study the effect of biceps loading on radial head stability in anterior Monteggia injuries. We hypothesized that biceps loading results in a significant increase in anterior radial head translation. Our results agreed with this hypothesis and showed a significant increase in anterior radial head translation even with 20N of biceps loading. This is an important finding since higher biceps loads have been reported during active elbow flexion.¹⁻⁶ Interestingly, there was no significant difference in radial head translation in the absence of biceps loading even with greater degrees of soft tissue disruption. This finding supports a previously reported clinical observation that placement of the elbow in a flexed and supinated position to relax the biceps aids in maintaining the reduction of the radial head in anterior Monteggia injuries.⁷⁻⁹

The fourth objective of this research was to compare the effect of simulated active and passive elbow flexion on radial head stability in anterior Monteggia injuries. We hypothesized that there would be a significant increase in anterior radial head translation during simulated active elbow flexion compared to passive elbow flexion due to the effect of biceps activation. Our results did not agree with this hypothesis. There was no significant difference in radial head translation between simulated active and passive elbow flexion except in stage 4 soft tissue sectioning. In this stage, which involves sectioning of the middle IOM in addition to the anterior joint capsule, annular ligament, quadratus ligament and the proximal IOM, passive elbow flexion resulted in a greater anterior radial head translation than simulated active motion. This discrepancy between our results and our hypothesis is likely related to simulated activation of the supinator muscle to maintain the forearm in supination during active elbow flexion with the forearm supinated. Simulated activation of the supinator muscle may have counteracted the effect of the biceps pull preventing anterior translation of the radial head.

4.3 Future Directions

The findings of this research have implications for future clinical and biomechanical studies. The results of current investigation suggest that in patients with a large magnitude of radial head translation or those with persistent radial head instability despite an anatomic reduction of the ulna, disruption of other soft tissue structures in addition to the anterior radiocapitellar joint capsule should be expected. Injury of the annular ligament and the IOM are likely. Future clinical studies should clarify the soft tissue disruption in acute and chronic anterior Monteggia injuries with magnetic resonance imaging. A better understanding of the pattern of their soft tissue injury should allow the development of better surgical techniques and rehabilitation protocols to enhance patients' outcomes. Future biomechanical and clinical studies should evaluate the effectiveness of annular ligament and IOM repair or reconstruction in stabilizing the radial head in cases with persistent or recurrent instability despite an anatomic reduction of the ulnar fracture. Future studies evaluating the safety and clinical outcomes of postoperative immobilization versus early motion protocols in the management of patients with anterior Monteggia injuries are required. Finally, the effect of forearm rotation on radial head stability in anterior Monteggia injuries should be evaluated.

4.4 References

1. Roman-Liu D, Bartuzi P. Influence of type of MVC test on electromyography measures of biceps brachii and triceps brachii. *Int J Occup Saf Ergon.* 2018;24(2):200-206.
2. Kleiber T, Kunz L, Disselhorst-Klug C. Muscular coordination of biceps brachii and brachioradialis in elbow flexion with respect to hand position. *Front Physiol.* 2015;6:215.
3. Kotte SHP, Viveen J, Koenraadt KLM, The B, Eygendaal D. Normative values of isometric elbow strength in healthy adults: a systematic review. *Shoulder Elbow.* 2018;10(3):207-215.
4. Funk DA, An KN, Morrey BF, Daube JR. Electromyographic analysis of muscles across the elbow joint. *J Orthop Res.* 1987;5(4):529-538.
5. Ferreira LM, Johnson JA, King GJ. Development of an active elbow flexion simulator to evaluate joint kinematics with the humerus in the horizontal position. *J Biomech.* 2010;43(11):2114-2119.
6. Johnson JA, Rath DA, Dunning CE, Roth SE, King GJ. Simulation of elbow and forearm motion in vitro using a load controlled testing apparatus. *J Biomech.* 2000;33(5):635-639.
7. Tompkins DG. The anterior Monteggia fracture: observations on etiology and treatment. *The Journal of bone and joint surgery American volume.* 1971;53:1109-1114.
8. Wiley JJ, Galey JP. Monteggia injuries in children. *J Bone Joint Surg Br.* 1985;67(5):728-731.
9. Abe M, Kumano H, Kinoshita A, Hirofuji S. Irreducible Dislocation of the Radial Head Associated With Pediatric Monteggia Lesions. *Journal of the American Academy of Orthopaedic Surgeons Global research & reviews.* 2018;2(5):e035.

Appendix 1: Glossary of Terms

Active range of motion: The range of motion in which the patient moves his/her joints

Anterior: Located towards the front of the body in the sagittal plane

Biomechanics: The study of the mechanical laws relating to the movement or structures of living organisms

Coronal Plane: A vertical plane that divides the body into ventral and dorsal sections

Cadaveric: A part of a dead body used for scientific or medical research

Dislocation: When bones forming an articulation are completely separated

Distal: Located away from the centre of the body in the axial plane

Extensions: As it pertains to the arm, movement in a posterior direction in the sagittal plane

Flexion: As it pertains to the arm, movement in an anterior direction in the sagittal plane

In-vitro: Outside a living organism

Kinematics: The mechanical study of the motion of objects without considering the contributing forces

Lateral: Located away from the midline of the body in the coronal plane

Ligament: A fibrous tissue connecting two bones

Medial: Located towards the midline of the body in the coronal plane

Passive range of motion: The range of motion in which the joint is moved by someone other than the patient without any voluntary muscular efforts from the patient

Posterior: Located towards the back of the body in the sagittal plane

Pronation: As it pertains to the arm, movement of the forearm so that the palm is down

Proximal: Located closer to the centre of the body in the axial plane

Sagittal Plane: A longitudinal plane that divides the body into right and left sides.

Subluxation: A partial dislocation where the bones forming an articulation are still partially in contact

Supination: As it pertains to the arm, movement of the forearm so that the palm is up

Tendon: A fibrous tissue attaching a muscle to a bone

Curriculum Vitae

ARMIN BADRE

EDUCATION

2017 – Present	Master of Science in Surgery Schulich School of Medicine and Dentistry, Western University
2017 – 2018	Hand and Upper Extremity Fellowship Roth-McFarlane Hand and Upper Limb Centre, Western University
2012 – 2017	Orthopedic Surgery Residency Faculty of Medicine and Dentistry, University of Alberta
2008 – 2012	Doctor of Medicine Faculty of Medicine and Dentistry, University of Alberta
2004 – 2008	Bachelor of Science – Integrated Science Faculty of Science, Carleton University (2005-2008) Chancellor's Medal, Highest Honours; Faculty of Engineering and Design, Carleton University (2004-2005)

LICENSURE AND QUALIFICATIONS

2017 – Present	College of Physicians & Surgeons of Ontario (ID# 108322)
2012 – Present	College of Physicians & Surgeons of Alberta (ID# 019943)
2016	College of Physicians & Surgeons of British Columbia (ID# 043140)
2017	Fellow: Royal College of Physicians and Surgeons of Canada – Orthopaedic Surgery
2013	Licentiate of the Medical Council of Canada
2013	Medical Council of Canada Qualifying Examination Part II
2012	Medical Council of Canada Qualifying Examination Part I

COURSES AND CONFERENCES

2018	73 rd American Society for Surgery of the Hand (ASSH) Annual Meeting 73 rd Canadian Orthopaedic Association Annual Meeting Mayo/ASSH Hand and Wrist Arthroplasty Course Canadian Shoulder and Elbow Society Canadian Bone and Joint Conference
2017	1 st Canadian Peripheral Nerve Symposium 72 nd American Society for Surgery of the Hand (ASSH) Annual Meeting 35 th ASSH/AFSH Adrian E. Flatt Residents and Fellows Conference Canadian Shoulder and Elbow Society

Canadian Orthopaedic Resident Forum
Orthopaedic Resident Review in Reconstructive Surgery

2016 Orthopaedic Resident Review Trauma

PROFESSIONAL MEMBERSHIPS

American Society for Surgery of the Hand
Canadian Shoulder and Elbow Society
Canadian Orthopaedic Association
Fellow of Royal College of Surgeons of Canada
Alberta Medical Association
College of Physicians and Surgeons of Alberta
College of Physicians and Surgeons of Ontario

HONOURS AND AWARDS

2017	Physicians' Services Incorporated (PSI) Research Trainee Award \$50,000 awarded over 2 years
2017	ASSH/AFSH 72nd Annual Meeting/35th Adrian E. Flatt Residents and Fellows Conference Scholarship
2017	Ontario Graduate Scholarship Merit-based scholarship
2017	Dr. Hastings Mewburn Postgraduate Scholarship in Orthopedic Medicine Awarded annually to one graduating resident based on outstanding merit in the field of orthopedic medicine
2016	Resident Teaching Recognition Recognized by the Emergency Medicine Residency Program for contribution to off-service resident education during their orthopedic surgery rotation.
2013	Best Literature Review Award Awarded to the best literature review presentation at 40 th Annual Orthopedic Surgery Resident Research Day
2009	Dr. A J Pauly Bursary in Medicine Awarded to 3 students in first-year MD program for academic excellence
2008	Explore Program/French Language Bursary Program Awarded a bursary to participate in a five-week French Language learning program and explore a region of Canada (Victoria, BC)
2008	Chancellor's Medal Awarded to the undergraduate student with the second highest overall average among students from all faculties in 2008 graduations
2004 – 2008	Dean's Honours List

- 2004 – 2008 **Queen Elizabeth II Aiming for the Top Scholarship**
Awarded for academic excellence
- 2007 **NSERC Undergraduate Summer Research Award**
- 2007 – 2008 **Henry Marshall Tory Scholarship**
Awarded to an outstanding student in academics with broad extracurricular activities and leadership qualities
- 2006 – 2007 **Ian H. Griffith Scholarship**
Awarded for academic excellence
- 2004 – 2006 **Nortel Networks Scholarship for Excellence**
Awarded to 5 students for academic excellence
- 2004 – 2005 **Kenneth Tang Memorial Scholarship**
Awarded to 1 student in Electrical Engineering for academic excellence

RESEARCH

- 2018 – 2019 **Analysis of Three-Dimensional Anatomic Variance and Fit of the Distal Radius to Current Volar Locking Plate Designs**
Supervisors: Drs. N. Suh & E. Lalone, Bio-Engineering Research Laboratory, Roth-McFarlane Hand and Upper Limb Centre, Western University, London, ON
- 2017 – 2019 **Biomechanical Evaluation of Monteggia Fracture-Dislocations**
Supervisors: Drs. G. King, K. Faber & J. Johnson, Bio-Engineering Research Laboratory, Roth-McFarlane Hand and Upper Limb Centre, Western University, London, ON
- 2017 – 2018 **Biomechanical Evaluation of LCL Load Change in Various Arm Positions and Throughout the Elbow Range of Motion**
Supervisors: Dr. G. King & Dr. J. Johnson, Bio-Engineering Research Laboratory, Roth-McFarlane Hand and Upper Limb Centre, Western University, London, ON
- 2017 – 2018 **Effects of Torsional Moment to the Forearm on the Posterolateral Rotatory Instability of an LCL Deficient Elbow**
Supervisors: Dr. G. King & Dr. J. Johnson, Bio-Engineering Research Laboratory, Roth-McFarlane Hand and Upper Limb Centre, Western University, London, ON
- 2017 – 2018 **Biomechanical Evaluation of Anconeus Muscle in Elbow Stability**
Supervisors: Dr. G. King & Dr. J. Johnson, Bio-Engineering Research Laboratory, Roth-McFarlane Hand and Upper Limb Centre, Western University, London, ON

- 2017 – 2018 **Biomechanical Evaluation of a Custom Designed Elbow Brace**
Supervisors: Dr. G. King & Dr. J. Johnson, Bio-Engineering Research Laboratory, Roth-McFarlane Hand and Upper Limb Centre, Western University, London, ON
- 2016 – 2017 **Rate of Major Hardware Complications Following Open Reduction and Internal Fixation of Clavicle Fractures**
Supervisors: Dr. D. Sheps & Dr. L. Beaupre, Division of Orthopedic Surgery, University of Alberta, Edmonton, AB
- 2012 – 2016 **Alberta Foot and Ankle Surgical Wait Time**
Supervisor: Dr. E. Pedersen, Division of Orthopedic Surgery, University of Alberta, Edmonton, AB
- 2012 – 2015 **Comprehensive Review of Clinical Outcomes of Meniscal Scaffolds**
Supervisors: Dr. A. Adesida & Dr. N. Jomha, Division of Orthopedic Surgery, University of Alberta, Edmonton, AB
- 2013 – 2014 **Novel Scaffolds for Meniscus Tissue Engineering**
Supervisors: Dr. A. Adesida & Dr. N. Jomha, Division of Orthopedic Surgery, University of Alberta, Edmonton, AB
- 2010 – 2011 **Abdominal Compartment Syndrome in Trauma Patients**
Supervisors: Dr. M. Menon, Division of Orthopedic Surgery, University of Alberta; Dr. S. Widder, Division of General Surgery, University of Alberta, Edmonton, AB
- 2009 **Coronary Angiography vs. MIBI Perfusion Scintigraphy Scan in the Screening of Post Heart Transplant Coronary Vasculopathy**
Supervisor: Dr. G. Pearson, Faculty of Pharmacy and Pharmaceutical Sciences, Mazankowski Alberta Heart Institute, Edmonton, AB
- 2007 – 2008 **Effects of Inflammatory Priming of Herbicides and Pesticides on Dopaminergic Neurons Loss Associated with Parkinson's Disease**
Supervisor: Dr. S. Hayley, Department of Neuroscience, Carleton University, Ottawa, ON
- 2006 – 2008 **Natural History of Inoperable Large Aortic Aneurysms**
Supervisor: Dr. G. Hajjar, Division of Vascular Surgery, University of Ottawa, Ottawa, ON
- 2007 **Molecular Processes Involved in Yeast Aging**
Supervisor: Dr. A. Golshani, Department of Biology, Carleton University, Ottawa, ON

- 2007 **Smoking Cessation Strategies Based on the Biopsychosocial Model of Care**
Supervisor: Dr. G. Hajjar, Division of Vascular Surgery, University of Ottawa, Ottawa, ON
- 2006 **Proteins Involved in Hematopoietic Stem Cell Differentiation**
Supervisor: Dr. M. Brand, Ottawa Hospital Research Institute, Ottawa, ON
- 2005 **Person Identification Using Electrocardiogram**
Supervisor: Dr. A. Chan, Department of Systems and Computer Engineering, Carleton University, Ottawa, ON

PUBLICATIONS

Badre A, Perrin M, Albakri K, Suh N, Lalone E. (in preparation). Gender Differences in Distal Radius Morphology and its Effect on the Anatomic Fit of Standard Volar Locking Plates.

Badre A, Axford DT, Banayan S, Johnson JA, King GJW. (submitted). The Effect of Torsional Moments on the Posterolateral Rotatory Stability of a Lateral Ligament Deficient Elbow: An *In Vitro* Biomechanical Investigation.

Badre A, Axford DT, Banayan S, Johnson JA, King GJW. (2019). Role of Anconeus in the Stability of a Lateral Ligament and Common Extensor Origin Deficient Elbow: An *In Vitro* Biomechanical Study.

Badre A, Grewal R. (submitted). Thumb MPJ Collateral Ligament Reconstruction. In: P.K. Beredjiklian, *Hand Surgery: Tricks of the Trade*. 1st ed.

Badre A, Weeks C, Panaro C. (2011). Hip (Pain, Fractures & Dislocations). In: R. Gallagher, J. Pawa and D. Lesniak (Ed.), *Approach to the OSCE: The Edmonton Manual of Common Clinical Scenarios*. 2nd ed. Edmonton: University of Alberta Medical Students' Association. 352-3.

Badre A, Gazala S, de Gara C. (2011). Hernia. In: R. Gallagher, J. Pawa and D. Lesniak (Ed.), *Approach to the OSCE: The Edmonton Manual of Common Clinical Scenarios*. 2nd ed. Edmonton: University of Alberta Medical Students' Association. 350-1.

Badre A, Gazala S, Lazarescu A. (2011). Abdominal pain. In: R. Gallagher, J. Pawa and D. Lesniak (Ed.), *Approach to the OSCE: The Edmonton Manual of Common Clinical Scenarios*. 2nd ed. Edmonton: University of Alberta Medical Students' Association. 306-7.

Badre A, Asadi L, McMahon A. (2011). Hematuria. In: R. Gallagher, J. Pawa and D. Lesniak (Ed.), *Approach to the OSCE: The Edmonton Manual of Common Clinical Scenarios*. 2nd ed. Edmonton: University of Alberta Medical Students' Association. 348-9.

Badre A, Asadi L, Lazarescu A. (2011). Jaundice. In: R. Gallagher, J. Pawa and D. Lesniak (Ed.), *Approach to the OSCE: The Edmonton Manual of Common Clinical Scenarios*. 2nd ed. Edmonton: University of Alberta Medical Students' Association. 354-5.

Badre A. (2008). Inflammatory priming with a viral toxin influences the neurodegenerative effects of a dopaminergic toxin (Unpublished bachelor's thesis). Carleton University, Ottawa, Ontario.

Chan ADC, Hamdy MM, **Badre A**, Badee V. (2008). Wavelet distance measure for person identification using electrocardiograms. *IEEE Transactions on Instrumentation and Measurement*. 57 (2), 248-53

ABSTRACTS/PRESENTATIONS

Badre A, Padmore CE, Axford DT, Berkmortel C, Faber KJ, King GJW, Johnson JA. (submitted). The Role of Biceps Loading and Muscle Activation on Radial Head Stability in Anterior Monteggia Injuries. 2nd International Combined Meeting of Orthopaedic Research Societies, Montreal, QC, Canada

Badre A, Axford DT, Padmore CE, Berkmortel C, Faber KJ, Johnson JA, King GJW. (submitted). Effect of Ulnar Angulation and Soft Tissue Sectioning on Radial Head Stability in Anterior Monteggia Injuries. 2nd International Combined Meeting of Orthopaedic Research Societies, Montreal, QC, Canada

Badre A, Padmore CE, Axford DT, Berkmortel C, Faber KJ, King GJW, Johnson JA. (submitted). The Role of Biceps Loading and Muscle Activation on Radial Head Stability in Anterior Monteggia Injuries. Annual Meeting of the Orthopaedic Trauma Association, Denver, CO, USA

Badre A, Axford DT, Padmore CE, Berkmortel C, Faber KJ, Johnson JA, King GJW. (submitted). Effect of Ulnar Angulation and Soft Tissue Sectioning on Radial Head Stability in Anterior Monteggia Injuries. Annual Meeting of the Orthopaedic Trauma Association, Denver, CO, USA

Badre A, Padmore CE, Axford DT, Faber KJ, King GJW, Johnson JA. (submitted). The Role of Biceps Loading and Muscle Activation on Radial Head Stability in Anterior Monteggia Injuries. 74th Annual Meeting of the American Society for Surgery of the Hand, Las Vegas, NV, USA

Badre A, Axford DT, Padmore CE, Faber KJ, Johnson JA, King GJW. (submitted). Effect of Ulnar Angulation and Soft Tissue Sectioning on Radial Head Stability in Anterior Monteggia Injuries. 74th Annual Meeting of the American Society for Surgery of the Hand, Las Vegas, NV, USA

Badre A, Axford DT, Banayan S, Johnson JA, King GJW. (accepted). Role of Anconeus in the Stability of a Lateral Ligament Deficient Elbow: An *In Vitro* Biomechanical Study. 14th International Congress of Shoulder and Elbow Surgery, Buenos Aires, Argentina

Badre A, Banayan S, Axford DT, Johnson JA, King GJW. (accepted). Role of an Adjustable Hinged Elbow Orthosis in the Rehabilitation of a Lateral Collateral Ligament Deficient Elbow: An *In Vitro* Biomechanical Study. 14th International Congress of Shoulder and Elbow Surgery, Buenos Aires, Argentina

Badre A, Perrin M, Albakri K, Suh N, Lalone E. (accepted). Gender Differences in Distal Radius Morphology and its Effect on the Anatomic Fit of Standard Volar Locking Plates. 14th IFSSH & 11th IFSHT Triennial Congress, Berlin, Germany

Badre A, Banayan S, Axford DT, Johnson JA, King GJW. (accepted). Role of an Adjustable Hinged Elbow Orthosis in the Rehabilitation of a Lateral Collateral Ligament Deficient Elbow: An *In Vitro* Biomechanical Study. 14th IFSSH & 11th IFSHT Triennial Congress, Berlin, Germany

Badre A, Axford DT, Banayan S, Johnson JA, King GJW. (accepted). The Effect of Torsional Moment of Forearm Weight on the Posterolateral Rotatory Instability of a Lateral Collateral Ligament Deficient Elbow. A Novel Biomechanical Modeling and *In Vitro* Investigation. 14th IFSSH & 11th IFSHT Triennial Congress, Berlin, Germany

Badre A, Axford DT, Banayan S, Johnson JA, King GJW. (accepted). Role of Anconeus in the Stability of a Lateral Ligament Deficient Elbow: An *In Vitro* Biomechanical Study. 14th IFSSH & 11th IFSHT Triennial Congress, Berlin, Germany

Badre A, Perrin M, Albakri K, Suh N, Lalone E. (accepted). Gender Differences in Distal Radius Morphology and its Effect on the Anatomic Fit of Standard Volar Locking Plates. Canadian Orthopaedic Association Annual Meeting, Montreal, QC, Canada

Badre A, Axford DT, Banayan S, Johnson JA, King GJW. (accepted). The Effect of Torsional Moments to the Forearm on the Posterolateral Rotatory Instability of a Lateral Collateral Ligament Deficient Elbow. A Novel Biomechanical Modeling and *In Vitro* Investigation. Canadian Orthopaedic Association Annual Meeting, Montreal, QC, Canada

Badre A, Axford DT, Banayan S, Johnson JA, King GJW. (accepted). Role of Anconeus in the Stability of a Lateral Ligament Deficient Elbow: An *In Vitro* Biomechanical Study. Canadian Orthopaedic Association Annual Meeting, Montreal, QC, Canada

Badre A, Perrin M, Albakri K, Suh N, Lalone E. (submitted). Gender Differences in Distal Radius Morphology and its Effect on the Anatomic Fit of Standard Volar Locking Plates. 2nd International Combined Meeting of Orthopaedic Research Societies, Montreal, QC, Canada

Banayan S, **Badre A**, Axford DT, Johnson JA, King GJW. (accepted). Role of an Adjustable Hinged Elbow Orthosis in the Rehabilitation of a Lateral Collateral Ligament Deficient Elbow: An *In Vitro* Biomechanical Study. 2nd International Combined Meeting of Orthopaedic Research Societies, Montreal, QC, Canada

Badre A, Axford DT, Banayan S, Johnson JA, King GJW. (accepted). The Effect of Torsional Moments to the Forearm on the Posterolateral Rotatory Instability of a Lateral Collateral Ligament Deficient Elbow. A Novel Biomechanical Modeling and *In Vitro* Investigation. 2nd International Combined Meeting of Orthopaedic Research Societies, Montreal, QC, Canada

Badre A, Axford DT, Banayan S, Johnson JA, King GJW. (accepted). Role of Anconeus in the Stability of a Lateral Ligament Deficient Elbow: An *In Vitro* Biomechanical Study. 2nd International Combined Meeting of Orthopaedic Research Societies, Montreal, QC, Canada

Axford DT, Banayan S, Johnson JA, **Badre A**, King GJW. (2019). The Effect of Brace Hinge Angle on the Rehabilitation of a Lateral Collateral Ligament Deficient Elbow: An *In Vitro* Biomechanical Study. Ontario Biomechanics Conference

Badre A, Axford DT, Banayan S, Johnson JA, King GJW. (2018). Role of Anconeus in the Stability of an LCL Deficient Elbow: An *In Vitro* Biomechanical Study. The Robert Zhong Department of Surgery Research Day, Western University, London, ON, Canada

Badre A, Axford DT, Banayan S, Johnson JA, King GJW. (2018). Role of Anconeus in the Stability of an LCL Deficient Elbow: An *In Vitro* Biomechanical Study. Canadian Bone and Joint Conference, London, ON, Canada

Badre A, Pedersen E, Beaupre L. (2016). Edmonton Foot and Ankle Care: From Standard Care to Central Referral and Screening Clinic. 43rd Annual Orthopedic Surgery Resident Research Day, University of Alberta, Edmonton, Alberta, Canada

Badre A, Jomha N, Adesida A. (2014). Novel Scaffolds for Meniscus Tissue Engineering. 41st Annual Orthopedic Surgery Resident Research Day, University of Alberta, Edmonton, Alberta, Canada

Badre A, Jomha N, Adesida A. (2013). Literature Review of the Epidemiology and Risk Factors Associated with Meniscal Injury, and Outcome of Meniscectomy and Acellular Scaffold Implants for Treatment of Meniscal Lesions. 40th Annual Orthopedic Surgery Resident Research Day, University of Alberta, Edmonton, Alberta, Canada

Sernik J, Menon M, **Badre A**, Abou-Gaida M, Chan C, Widder S. (2011). Abdominal compartment syndrome in trauma patients admitted to the University of Alberta intensive care unit. 38th Annual Alberta Orthopedic Resident Research Day, University of Calgary, Calgary, Alberta.

Sharapov AA, **Badre A**, Hajjar G. (2008). Natural history of large aortic aneurysms. Collins Surgical Day, University of Ottawa, Ottawa, ON, Canada

Chan ADC, Hamdy MM, **Badre A**, Badee V. (2006). Personal identification using electrocardiograms. *IEEE Canadian Conference on Electrical and Computer Engineering*. Ottawa, ON, Canada, DRDC Workshop S. No. 1.