

Western  Graduate&PostdoctoralStudies

Western University
Scholarship@Western

Electronic Thesis and Dissertation Repository

11-16-2018 5:00 PM

Collared Vs. Collarless Total Hip Arthroplasty In Both Direct Anterior And Direct Lateral Approach Surgery: A Prospective Cohort Comparison Study

Seb Heaven
The University of Western Ontario

Supervisor
Lanting, Brent
The University of Western Ontario Co-Supervisor
Teeter, Matthew
The University of Western Ontario

Graduate Program in Surgery
A thesis submitted in partial fulfillment of the requirements for the degree in Master of Science
© Seb Heaven 2018

Follow this and additional works at: <https://ir.lib.uwo.ca/etd>

 Part of the [Orthopedics Commons](#)

Recommended Citation

Heaven, Seb, "Collared Vs. Collarless Total Hip Arthroplasty In Both Direct Anterior And Direct Lateral Approach Surgery: A Prospective Cohort Comparison Study" (2018). *Electronic Thesis and Dissertation Repository*. 5930.
<https://ir.lib.uwo.ca/etd/5930>

This Dissertation/Thesis is brought to you for free and open access by Scholarship@Western. It has been accepted for inclusion in Electronic Thesis and Dissertation Repository by an authorized administrator of Scholarship@Western. For more information, please contact wlsadmin@uwo.ca.

Abstract

Total hip arthroplasty (THA) is one of the most successful surgical procedures performed worldwide. Recent advances in implant technology and popularization of the muscle-sparing Direct Anterior (DA) approach to the hip has led to younger patients becoming candidates for hip arthroplasty surgery. Among the many considerations necessary for success in this patient population, implant design plays an important role in determining outcomes.

In this thesis, we prospectively evaluated patients who received a collared or collarless fully hydroxyapatite-coated femoral stem during THA with a standard RSA protocol to assess stem migration patterns following surgery.

Preliminary results indicate that collarless stems subside significantly more than collared stems within the first 2-4 post-operative weeks, with no differences in patient-reported outcome data between the two cohorts. Further study with longer-term follow-up is indicated to establish migration patterns within the first 2 post-operative years, and whether the discrepancies between cohorts manifest any clinical consequences.

Keywords

Total hip arthroplasty, collared, collarless, Radiostereometric analysis, migration patterns

Co-Authorship Statement

- Chapter 1 Sebastian Heaven – Sole Author
- Chapter 2 Sebastian Heaven – Sole Author
- Chapter 3 Sebastian Heaven – Sole Author
- Chapter 4 Sebastian Heaven – study design, data collection, radiographic analysis, statistical analysis, manuscript preparation
- Maxwell Perelgut – data collection, radiographic analysis
- Brent Lanting – study design, manuscript preparation
- Edward Vasarhelyi – study design, manuscript preparation
- James Howard – study design, manuscript preparation
- Matthew Teeter – study design, statistical analysis, manuscript preparation
- Chapter 5 Sebastian Heaven – study design, patient recruitment, statistical analysis, manuscript preparation
- Maxwell Perelgut – study design, patient recruitment, data collection
- Brent Lanting – study design, manuscript preparation
- Edward Vasarhelyi – study design, manuscript preparation
- Matthew Teeter – study design, data collection, manuscript preparation
- Chapter 6 Sebastian Heaven – Sole Author

Acknowledgments

I wish to extend my sincerest thanks to everyone who assisted me in bringing this thesis to completion. Without your considerable effort and dedication, none of this work would have been possible. I thank you all.

Dr's Lanting, Vasarhelyi and Teeter – as my supervisory committee you have helped me navigate the process of constructing this thesis, and in doing so have taught me an enormous amount both professionally and academically. Your guidance and teaching has furthered my knowledge no end, and has inspired me to continue to strive for academic excellence in my career. I hope to continue collaborating with you in the future.

Maxwell Perelgut – your assistance and expertise in helping analyze many hundreds of radiographs, and your central role in our prospective study has been key in producing the data that this thesis has presented. I sincerely appreciate your work and your continued positivity during our ongoing trial.

Dr. Howard – thank you for allowing us access to retrospective data on your patients, without which we could not have produced such a strong data set to draw from.

Finally, I would like to thank my family – Rebecca and James. Their constant support and understanding during a busy time working and studying in the Masters' program has been the real secret to any success I have achieved. My gratitude to them is boundless.

Table of Contents

COLLARED VS. COLLARLESS TOTAL HIP ARTHROPLASTY IN BOTH DIRECT ANTERIOR AND DIRECT LATERAL APPROACH SURGERY: A PROSPECTIVE COHORT COMPARISON STUDY.....	i
Abstract.....	i
Co-Authorship Statement.....	ii
Acknowledgments.....	iii
Table of Contents.....	iv
List of Tables.....	vii
List of Figures.....	viii
Chapter 1.....	1
1 Introduction:.....	1
1.1 Hip anatomy overview:.....	2
1.1.1 Bony anatomy:.....	2
1.1.2 Hip musculature anatomy:.....	5
1.1.3 Capsulo-labral anatomy:.....	8
1.2 Hip arthritis overview:.....	10
1.2.1 Etiologies of hip arthritis:.....	10
1.2.2 Clinical presentation of hip arthritis:.....	12
1.2.3 Non-surgical management of hip arthritis:.....	13
1.2.4 Surgical management of hip arthritis:.....	15
1.3 Common surgical approaches in total hip arthroplasty:.....	16
1.3.1 Anterior approach to the hip:.....	16
1.3.2 Lateral approach to the hip:.....	20
1.3.3 Posterior approach to the hip:.....	21

1.4 References	23
Chapter 2	28
2 Radiostereometric Analysis (RSA) Overview:	28
2.1 References.....	36
Chapter 3	39
3 Objectives.....	39
Chapter 4	40
4 Collared stems in Direct Anterior and Direct Lateral Primary Total Hip Arthroplasty: A Retrospective Cohort study.....	40
4.1 Introduction:.....	40
4.2 Materials and Methods:	41
4.3 Results:.....	43
4.4 Discussion:	49
4.5 Conclusion:.....	52
4.6 References:	53
Chapter 5	55
5 Collared vs. Collarless stems in Direct Anterior and Direct Lateral Primary Total Hip Arthroplasty: A Prospective Randomized Cohort study	55
5.1 Introduction:.....	55
5.2 Materials and Methods:	56
5.3 Results:	57
5.4 Discussion:	59
5.5 References:.....	62
Chapter 6	64
6 Conclusions	64

Appendix A: The UCLA Score	65
Appendix B: WOMAC	66
Appendix C: SF-12 Survery	67
Appendix D: Abbreviations list	68
Curriculum Vitae	70

List of Tables

Table 1.1 Risk factors for hip arthritis	10
Table 1.2 Hip Arthritis Aetiologies	11
Table 4.1 Patient demographics and information	44
Table 4.2 Demographic comparison between cohorts & statistical significance..	45
Table 4.3 Radiographical Analysis by Surgical Approach	48
Table 4.4 Indications for Revision surgery	48
Table 5.1. Mean UCLA Activity Score Improvement	56
Table 5.2 Mean RSA Maximum Total Point Motion.....	57
Table 5.3 Mean RSA Total Migration.....	Error! Bookmark not defined.

List of Figures

Figure 1.1 Bony anatomy of the proximal femur (AP View).....3

Figure 1.2 Pelvic anatomy and important bony landmarks (AP View).....3

Figure 1.3 Femoral neck and acetabular version (Axial view)5

Figure 1.4 Anterior hip musculature (AP view)6

Figure 1.5 Posterior hip musculature (PA view)8

Figure 1.6 Anterior capsular anatomy of the hip joint (AP View)9

Figure 1.7 Labral anatomy and hip joint articular cartilage (Sagittal view).....9

Figure 1.8 Total Hip Arthroplasty components 16

Figure 1.9 Traction table setup for anterior approach THA 19

Figure 1.10 Anterior hip approach (Oblique view) 19

Figure 1.11 Lateral hip approach (PA view)21

Figure 1.12 Posterior hip approach (PA view).....22

Figure 2.1 Radiographic analysis parameters.29

Figure 2.2 Calculating position in space based on 2 image and fixed focus points..
.....30

Figure 2.3 RSA Lab setup33

Figure 2.4 Fiducial bead marker cage.....33

Figure 2.5 RSA Software digitally projecting prosthesis position based on RSA
radiographs.34

Figure 4.1 Radiographic analysis parameters.	42
Figure 4.2 Patient follow-up Flow Diagram.....	46
Figure 5.1 Collarless and Collared Femoral Implants.	55

Chapter 1

1 Introduction

Hip arthritis has long been a significant problem in healthcare, with hundreds of thousands of patients every year being diagnosed and referred on to specialists for consideration of surgical treatment(1). The gold standard treatment for advanced degenerative arthritis of the hip is Total Hip Arthroplasty, with success rates surpassing any other contemporaneous elective procedure across orthopaedics(2) and, indeed, surgery as a discipline.

Traditionally, Total Hip Arthroplasty (THA) was reserved for patients of more advanced age due to technological limitations affecting the longevity and durability of the arthroplasty components(3). However, with recent advances in component design and manufacture, we are now able to offer THA in younger arthritis patients without overwhelming concern for component failure and possible revision surgery(4). These advances have changed the landscape of hip arthroplasty surgery - with a younger patient population receiving THA, how we determine successful outcomes must change with this shift in demographic. Younger patients are still in gainful employment, still playing recreational sports and overall are more active than the more traditional hip arthroplasty patient. Surgeons are increasingly required to consider these factors when offering THA(5).

One significant decision a surgeon must make in planning THA is the surgical approach. While posterior and lateral approaches to the hip are more widely used for this procedure(6), anterior approach THA has demonstrated advantages in recent literature of enhanced earlier recovery within the first 3 post-operative months(7,8,9). With this information freely available to patients, many younger surgical candidates are requesting this approach so that they can return to work or their favored recreational activity sooner after surgery. However, the anterior approach to the hip for THA presents a significant technical challenge to the surgeon(10), much of which is faced during preparation of the femur. The goal of this thesis is to investigate the effect of

different femoral THA component designs and surgical approach on the revision rate and radiographic & patient-reported outcome measures in THA patients.

In this introductory chapter, we will review the anatomy of the hip joint, hip arthritis as a disease process and review the different surgical approaches to the hip joint and their technical considerations. In the subsequent chapters, we will then discuss femoral component design, surgical approaches and review radiographic analysis methods of THA patients and their implications for predicting failures and revision surgery, and present early results of a clinical trial examining 2 distinct component designs and their early outcomes.

1.1 Hip Anatomy

The hip is a synovial joint containing cartilage on both femoral head and the acetabular surface. It is unique in that it connects the axial to the lower appendicular skeleton, and has a “ball-and-socket” type configuration. It allows for lower extremity movement in the coronal, sagittal and axial planes while maintaining higher levels of mechanical constraint than the shoulder joint, which connects the axial skeleton to the upper appendicular skeleton(11).

The anatomy of the hip can be sub-categorized into bony anatomy, muscular anatomy, and capsulo-labral anatomy.

1.1.1 Bony anatomy

The overall architecture of the hip joint can be summarized by an articulation between the proximal femur (Figure 1.1) and the acetabulum of the pelvis (Figure 1.2) (11,12). Each of these structures has unique bony landmarks that signify insertion and/or origins of important periarticular musculature(11,12).

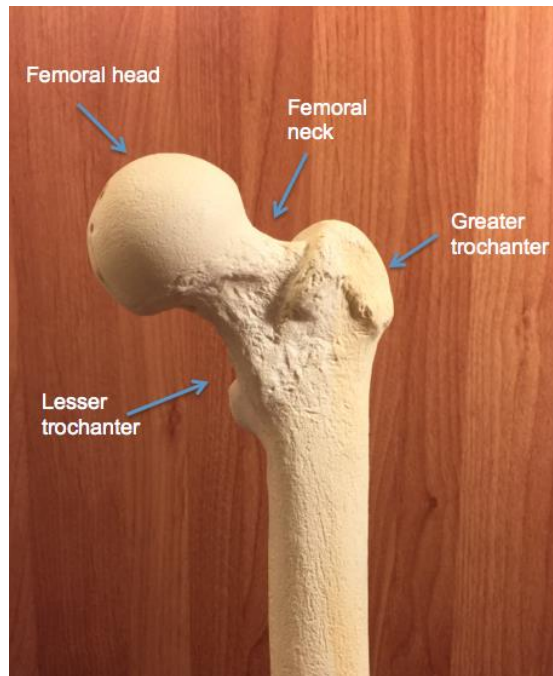


Figure 1.1 Bony anatomy of the proximal femur (AP view)

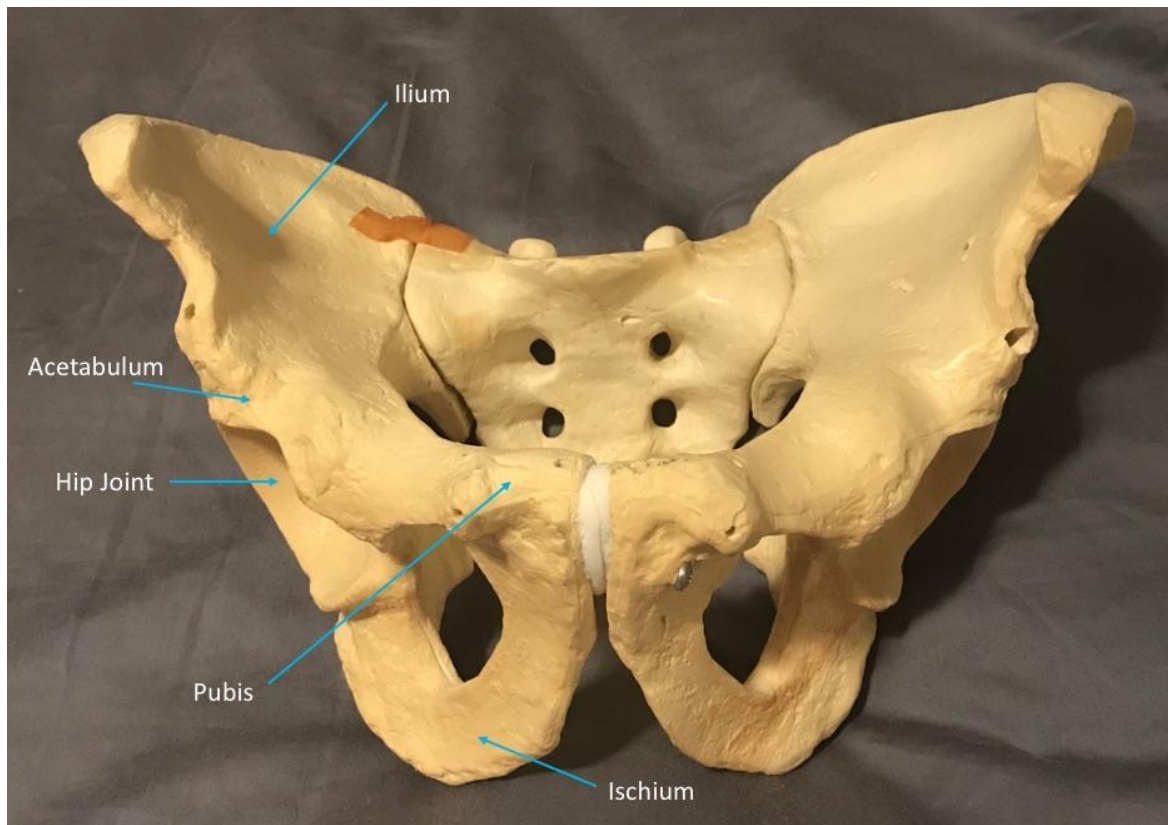


Figure 1.2 Pelvic anatomy and important bony landmarks (AP View)

Femur

The “ball” of the “ball-and-socket” hip joint, the femoral head is connected to the rest of the femur via the femoral neck, with the greater and lesser trochanters comprising important bony landmarks at the transition site between the femoral neck and the femoral shaft(13). The greater trochanter is situated postero-laterally to the axis of the femoral neck and is an important insertion site for the abductor group of muscles(11,13). The lesser trochanter sits postero-medial to the axis of the femoral neck and is the insertion site for the iliopsoas tendon, an important flexor of the hip(13). The orientation of the femoral neck relative to the femoral shaft and inter-epicondylar axis (a line drawn between the medial and lateral epicondyle in the distal femur) is between 8 and 12 degrees anteverted (Angle A in Figure 1.2) (14). The inferomedial aspect of the femoral neck is commonly referred to as the “calcar”, and is denoted by a dense arcade of predominantly cortical bone. This region of the femoral neck is considered to have the highest mechanical strength.

Acetabulum

Formed where the ischium, ilium and pubis meet and form the tri-radiate cartilage in early life, the acetabulum has a complex bony structure which is consolidated once the tri-radiate ossifies at skeletal maturity(11). It forms the “socket” part of the “ball-and-socket” joint and is lined with articular hyaline cartilage. It is orientated between 15 and 23 degrees anteverted (Angle B in Figure 1.2) from neutral relative to the coronal plane and 32-45 degrees abducted from neutral relative to the axial plane(15-17). The capsulo-labral complex attaches to the rim of acetabulum circumferentially.

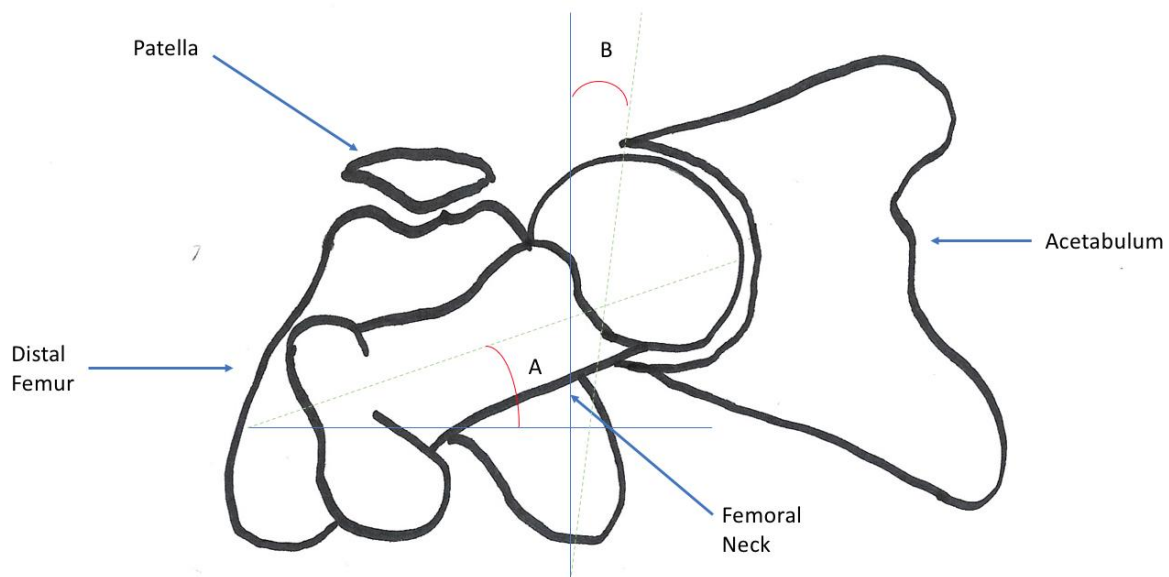


Figure 1.3 Femoral neck and Acetabular Version (Axial view)

1.1.2. Hip Muscular Anatomy

Detailed knowledge of the muscular anatomy surrounding the hip joint is essential for any surgeon wishing to perform THA safely. Preservation of muscular integrity is not only essential from a biomechanical perspective, but due consideration to associated nervous and vascular anatomy is also of paramount importance to achieve a successful outcome. We will discuss relevant muscular anatomy to the hip joint in this section.

Hip Flexors

Muscles that perform this function include Iliopsoas, Rectus Femoris, Tensor Fascia Latae and Sartorius(11). Iliopsoas has dual origin – from lumbar transverse processes as well as the inner table of the pelvis, more specifically from the medial aspect of the ilium. The psoas and iliacus respectively join to have a common insertion on the lesser trochanter. It is supplied by both the lumbar plexus of nerves from L1-L3 and the femoral nerve. Its blood supply is mostly from the medial femoral circumflex artery, with some supply from the iliolumbar artery(11). Rectus Femoris is a bipenniform muscle with two origins – a direct head originating from the anterior inferior iliac spine and an

indirect head originating from the acetabular rim and capsule. It receives nervous input from the femoral nerve and its blood supply is from the lateral femoral circumflex artery(11). Tensor Fascia Latae originates from the anterior superior iliac spine and inserts on the iliotibial band. It is innervated by the superior gluteal nerve and its blood supply comes from both the lateral femoral circumflex artery and the superior gluteal artery(11). The Sartorius muscle originates from the anterior superior iliac spine and inserts into the superomedial tibia as part of the pes anserinus. The femoral nerve and artery are its primary neurovascular supply(11).

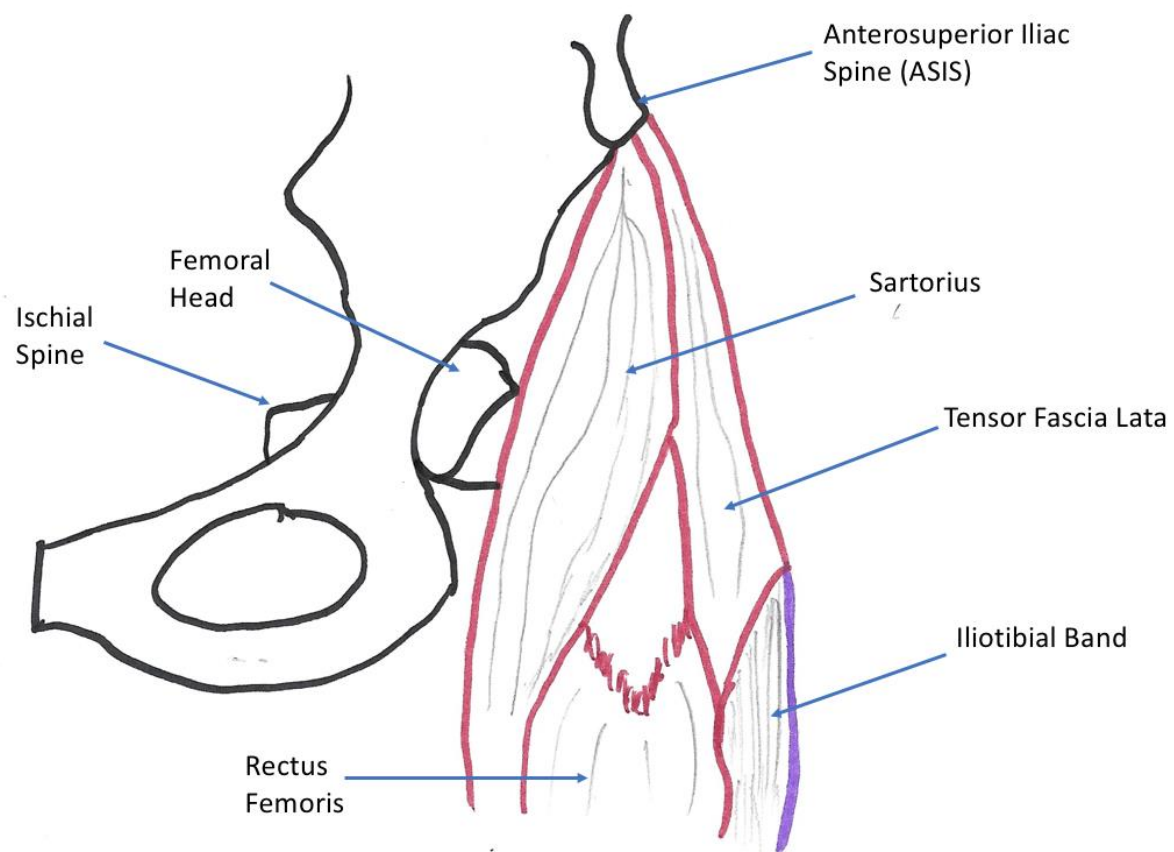


Figure 1.4 Anterior hip musculature (AP View)

Hip Extensors

This movement is achieved primary through Gluteus Maximus, the most powerful muscle in the body. It is a powerful hip extensor and external rotator. It originates from thoracolumbar fascia, ilium and sacrum and has two separate insertions – the iliotibial

band and the gluteal tuberosity of the femur. The inferior gluteal nerve provides innervation with blood supply coming from the superior and inferior gluteal arteries(11).

Hip Abductors

The primary hip abductors are the gluteus medius and minimus. With both muscle originating from the outer table of the ilium, the minimus origin lies inferior to the medius origin. They both insert onto the greater trochanter of the femur and both have strong abductor function, the minimus also having some internal rotation function. Both are supplied by differing branches of the superior gluteal nerve and the superior gluteal artery(11). The minimus is often found directly on the hip capsule.

External Rotators

Often referred to as the “short” external rotators, this group includes Piriformis, Obturator Internus, Superior and Inferior Gemelli, Obturator Externus and Quadratus Femoris(11). All these muscles receive innervation from numerous different levels in the lumbar and sacral plexi of nerves, and their blood supply comes from superior and inferior gluteal arteries and some have lateral sacral artery supply also. They have an intimate anatomical relationship with the sciatic nerve, where considerable variation in the nerves’ location relative to these muscles exists(12). The Piriformis originates from the anterior surface of the sacrum and inserts on the postero superior aspect of the greater trochanter. Obturator Internus originates from medial obturator membrane and the surrounding bone, and inserts on the medial aspect of the greater trochanter, usually bisecting the two gemelli. The superior gemellus originates from the ischial spine, while the inferior gemellus originates from the ischial tuberosity. They insert just superior and inferior respectively to the insertion point of obturator internus. This common insertion point is often referred to as the conjoint tendon. Obturator externus originates from the lateral surface of the obturator membrane and the ischiopubic ramus, and inserts just proximal to Quadratus femoris in the intertrochanteric fossa. Quadratus femoris originates just lateral to the ischial tuberosity and inserts on the trochanteric crest as it runs posteriorly(11).

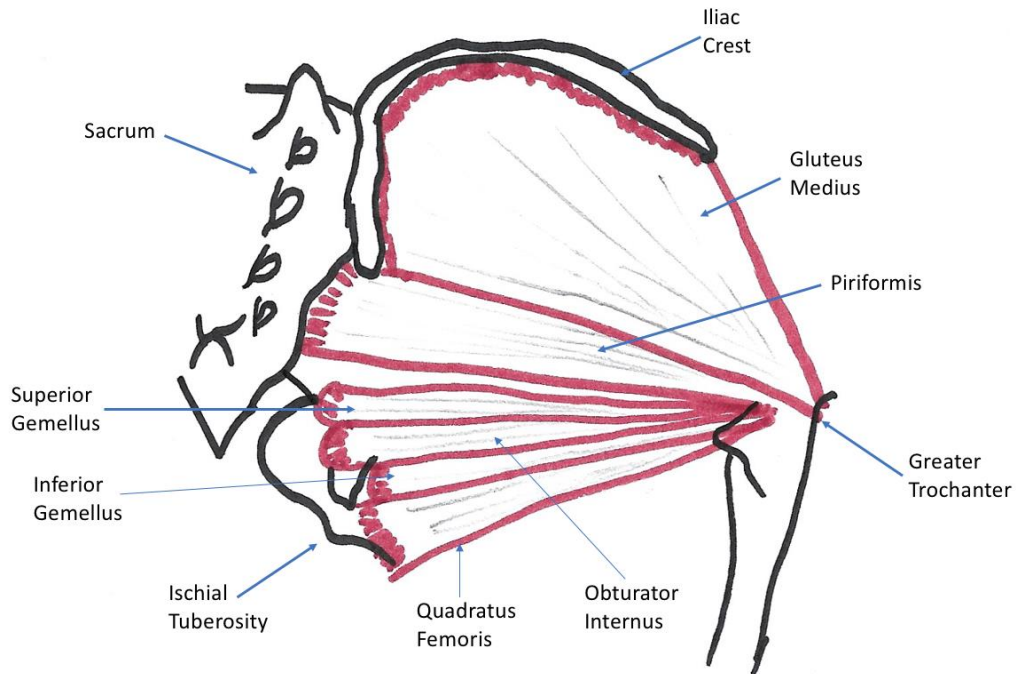


Figure 1.5 Posterior hip musculature (PA view)

1.1.3. Capsulo-labral Anatomy

The hip capsule is a strong static stabilizer of the hip joint. It comprises a thick sheet of connective tissue that circumferentially surrounds the articulation of the femoral head with the acetabulum, and extends distally to the end of the femoral neck area. It can be anatomically separated into 3 distinct ligamentous areas – pubofemoral, iliofemoral and ischiofemoral (Figure 1.6) (18). It has an intimate anatomical relationship with the hip labrum, with labrum sitting just inside the hip capsule and following the rim of the acetabulum (Figure 1.7) and separated from the capsule by the perilabral recess. The labrum deepens the hip joint by approximately 20% and also acts as a “suction-seal” for the joint. It is not circumferential, it stops on either side of the acetabular notch, and the two pillars at the notch are connected by the transverse acetabular ligament (11). It is comprised chiefly of fibrocartilage, and plays an important role in stabilizing the hip joint.

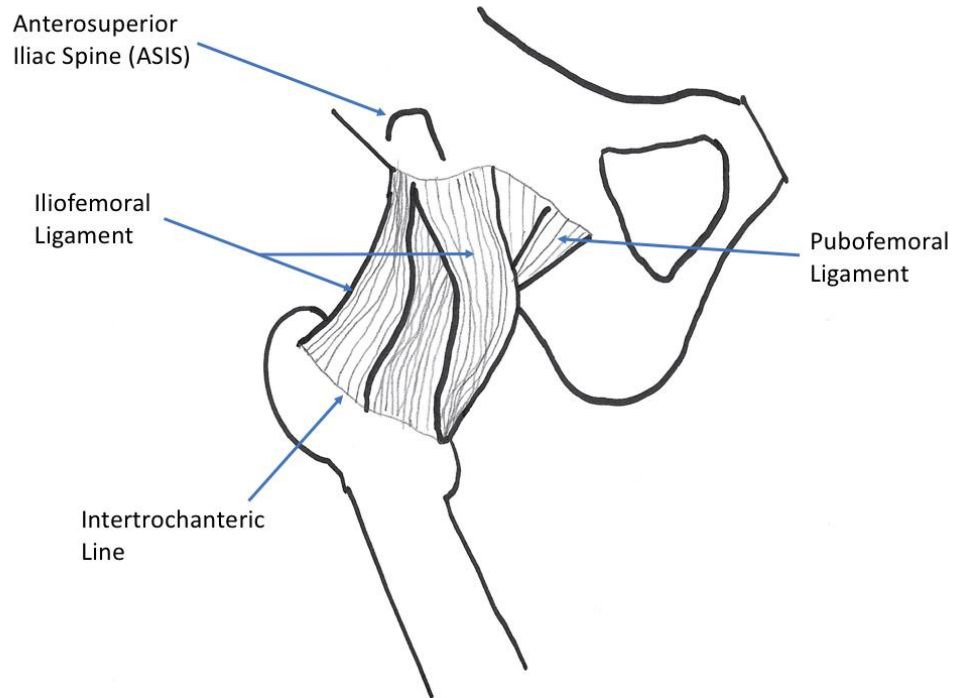


Figure 1.6 Anterior Capsular anatomy of the hip joint (AP view)(ischiofemoral ligament not viewed due to being posterior structure)

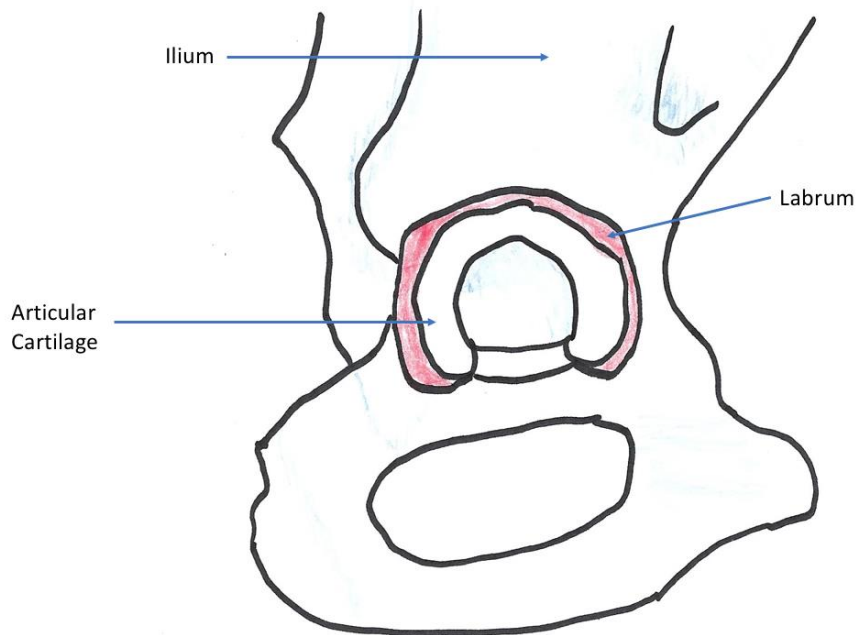


Figure 1.7 Labral anatomy and hip joint articular cartilage (Sagittal view)

1.2 Hip Arthritis

1.2.1. Etiology of Hip Arthritis

Arthritis of the hip is one of the most common musculoskeletal complaints in modern healthcare(19). With a current prevalence of 85 sufferers in every 1,000 patients(20) and this number set to rise in the next 20 years, it demands a significant amount of healthcare resources. It often causes debilitating pain, stiffness and weakness all of which contribute to a marked decrease in quality of life and functional capacity. With the current high demand for treatment of hip arthritis and disease burden set to worsen in the near future, healthcare professionals involved in the care of arthritis patients need to develop cost-effective strategies to maximize quality of life and functional ability whilst limiting expenditure and resources as best they can.

Table 1.1 Risk factors for hip arthritis

<i>Non-Modifiable</i>	<i>Modifiable</i>
Age	Obesity
Sex	Joint Trauma
Genetics	Muscle Weakness
Race	Sedentary Lifestyle
Increased Bone Density	

Hip arthritis describes a degenerative process whereby the hyaline cartilage lining the hip joint breaks down and the joint articulation in the absence of the cartilage results in subchondral bone contacting the subchondral bone on the other side of the joint. A complex inflammatory process follows, the bone attempts to remodel, and the patient begins to experience gradually worsening symptoms. There are numerous potential causes of this phenomenon. Although a number of risk factors have been identified to predispose a patient to arthritis (Table 1.1), often there is no single identifiable cause for

it. This is commonly referred to as primary, or idiopathic, osteoarthritis(21).

The aforementioned risk factors include advanced age, sex (F>M), genetics, race and acquired hip deformities such as developmental dysplastic hip (DDH). These are considered non-modifiable risk factors(22,23), whereas obesity, sedentary lifestyle, muscle weakness and trauma are all considered to be modifiable risk factors(22).

Table 1.2 Hip Arthritis Aetiologies

Mechanical	Developmental Hip Dysplasia (DDH)
	Slipped Capitofemoral Epiphysis (SCFE)
	Trauma
	Femoroacetabular Impingement (FAI)
Biological	Perthes Disease
	Chondrolysis
	Avascular Necrosis (AVN)
Inflammatory	Rheumatoid Arthritis (RA)
	Ankylosing Spondylitis
	Systemic Lupus Erythematosus (SLE)
Infectious	Septic Arthritis

Other causes of arthritis (Table 1.2) include avascular necrosis (AVN) of the femoral head, which can be due to trauma, but has a number of other causes including steroid medications, alcohol abuse, radiation therapy and bisphosphonate therapy(24). It is also associated with a number of pre-existing conditions including diabetes, sickle cell anaemia and Gauchers disease. Once the blood supply to the femoral head is disrupted

irreversibly, the structural integrity of both the cartilage and the subchondral bone is compromised, and arthritic change in the joint is an inevitability.

Systemic inflammatory conditions can also lead to severe hip arthritis – rheumatoid arthritis (RA), Ankylosing Spondylitis (AS) and Systemic Lupus Erythematosus (SLE) are all common conditions where hip arthritis develops due to the autoimmune-mediated inflammatory process that occurs in the hip concurrently with other parts of the body(25). These conditions also typically affect bone density and, along with other skeletal manifestations, make patients with these conditions unique in the context of joint reconstruction surgery. Due to their complexity, these cases are often challenging to manage.

Finally, destruction of articular cartilage, or chondrolysis, can occur quite aggressively in the presence of an intra-articular infection. This condition is known as Septic Arthritis. If not treated with a formal surgical articular lavage procedure soon after a prompt diagnosis, can not only cause dramatic destruction of joint architecture, but potentially result in systemic sepsis and potentially lead to life-threatening situations(26).

In order to appropriately manage patients presenting with hip arthritis, it is important to first understand the cause wherever possible. This enables the clinician to make appropriate decisions regarding the best treatment for each patient individually and maximizes the probability of successful outcomes.

1.2.2. Clinical Presentation of hip arthritis

The most common complaint of hip arthritis patients is pain. Classic hip arthritis pain is felt in the groin area, usually worsens with physical activity and can also be associated with stiffness, especially after long periods of immobility (e.g. first thing in the morning getting out of bed). It is essential for the assessing healthcare professional to take a detailed and thorough pain history(27). There are a number of important alternative diagnoses that will present with an almost identical picture to hip arthritis. Discerning the differing pathologies that present in the same way is subtle and seldom easy, but good history taking and examination will reveal small clues that may lead one to abandon the

hip as the cause of the patients' pain in favor of alternative diagnoses. Sciatica, athletic pubalgia, inguinal hernia, iliopsoas tendinitis and femoroacetabular impingement are all potential considerations when constructing a differential diagnosis(28). One must also be mindful of how this pain is affecting the patient, as a diminished ability to perform activities of daily living is important clinically.

A comprehensive physical examination of the hip should always be performed. Examination of the patients' gait is important as an antalgic or Trendelenburg gait is a sign of potential underlying arthritis. Inspection of the hip should be performed and note made of any scars, muscular atrophy, asymmetry or leg length discrepancy. Palpation of the joint is often of limited value due to the deep nature of the joint, but can reveal associated pathology such as Greater Trochanteric Bursitis. Examination of hip range of motion is important – severe arthritis often results in obligate external rotation with flexion, and attempted passive internal rotation in flexion is often painful(29). Establishing the neurovascular status of the limb is essential, and comprehensive examinations should also include the joint above and below.

1.2.3. Non-Surgical Management of hip arthritis

The general principles of treatment in a hip arthritis patient dictate that the healthcare professional begin with the least invasive treatments available, and move through more invasive options until satisfactory therapeutic benefit has been achieved. Numerous non-surgical options exist in the treatment of hip arthritis, many of which improve patient quality of life for years before their benefit is exhausted and surgical intervention becomes necessary. They include lifestyle modification, weight loss, gait aids, non-steroidal anti inflammatory medications (NSAIDS), non-narcotic analgesics and intra-articular injections(30).

As we mentioned obesity as being a modifiable risk factor in arthritis development, many patients that are able to lose significant amounts of weight actually find that their pain decreases to such an extent that it becomes eminently manageable, if at all problematic(31). There is obvious inherent challenge in losing weight with a painful joint, as this often discourages the patient from staying active, since this exacerbates their hip

pain. Low impact aerobic exercise such as swimming or aqua aerobics is often a good alternative in these situations. Dietary modifications are often necessary, and referral to a dietician may be of benefit to some patients. There is a growing body of evidence surrounding gastric band surgery prior to elective joint replacement in the morbidly obese patient population(32), however there is no evidence to suggest that this reduces the risk of requiring THA.

Gait aids such as canes, walkers and even crutches alleviate symptoms by offloading the affected hip and relieving the pain associated with weight bearing. They do not affect the natural history of the disease process itself, but rather alter the patients gait pattern to help them cope with the symptoms and maintain functional ability through it.

Several medications have been shown to help relieve arthritis pain, the most popular of which being NSAIDs and Acetaminophen. Taken in combination, they provide periodic pain relief via different mechanisms of action. Caution should be exercised when prescribing or recommending these medications – Acetaminophen in excess is hepatotoxic and should be avoided in patients with liver pathology. NSAIDs have numerous side effects and should be avoided in patients with uncontrolled hypertension, renal disease or gastric ulcers. In severe flare-ups, narcotic analgesics have been shown to be effective, but chronic use has been linked with dependence.

Intra-articular injections into the hip joint, unlike the knee joint, necessitate image-guidance with ultrasound or fluoroscopy and so are most commonly performed by interventional radiologists in an imaging department. Injections of corticosteroid are often effective at relieving pain on a temporary basis, but should not be performed within 6 months of any planned surgical intervention due to the increased risk of infection this confers to the patient(33). Injection of synthetic hyaluronic acid and/or platelet-rich plasma into a hip joint is controversial and has no strong evidence base to support its efficacy(34).

1.2.4. Surgical Management of hip arthritis

When all non-surgical options for treatment of hip arthritis have been exhausted (or when the arthritis is so severe that non-surgical options have an unacceptably low probability of being effective), the patient should be offered surgical intervention. Total Hip Arthroplasty is the most appropriate surgical option in the vast majority of patients. With recent advances in implant design improving the durability and longevity of THA components, even younger arthritis patients are increasingly considered candidates for Total Hip Arthroplasty

The goal of Total Hip Arthroplasty is to achieve a functional, pain-free hip joint with well-preserved range of motion. There is ample literature to support the success of Total Hip Arthroplasty in both the short and long term (35,36). Indeed, it has become so synonymous with success, that it is frequently the gold-standard to which other elective orthopaedic procedures are held accountable to(37).

There are numerous technical considerations the surgeon must consider when planning a THA. Selection of an appropriate surgical approach is important, and we will discuss this in detail later in this section. Implant selection is also important, and this decision is affected by the need to restore the patients' native offset and leg length, whilst sizing the components appropriately to the patients' native anatomy. Standard THA components consist of an acetabular component, usually made of metal, with an inner liner that locks into it (Figure 1.7). The liner is usually made of highly cross-linked polyethylene – a special type of plastic designed to be highly resistant to wear. Ceramic and metal options do exist but are used far less commonly in Canada(38). There is also a femoral component and a femoral head component. Both of these are usually metal (though ceramic femoral heads do exist, again, they are less common in Canada) and the femoral component can either be cementless (with special features such as porous coating or hydroxyapatite coating) relying on the surrounding bones' natural ability to grow into or onto it to fix it in place, or cemented which relies on a material known as polymethylmethacrylate (colloquially known as bone cement) acting as a grout-type material, interdigitating through the bony trabeculae at a microscopic level and binding

to the stem to secure it in place(39). The femoral head is usually affixed to the femoral stem via a Morse taper, and it then articulates with the inner liner of the acetabular component. This bearing surface has been the subject of much study, and while options include ceramic-on-ceramic, metal-on-metal and ceramic-on-poly, the most commonly used bearing surface in modern day Canadian hospitals is metal-on-poly(38).

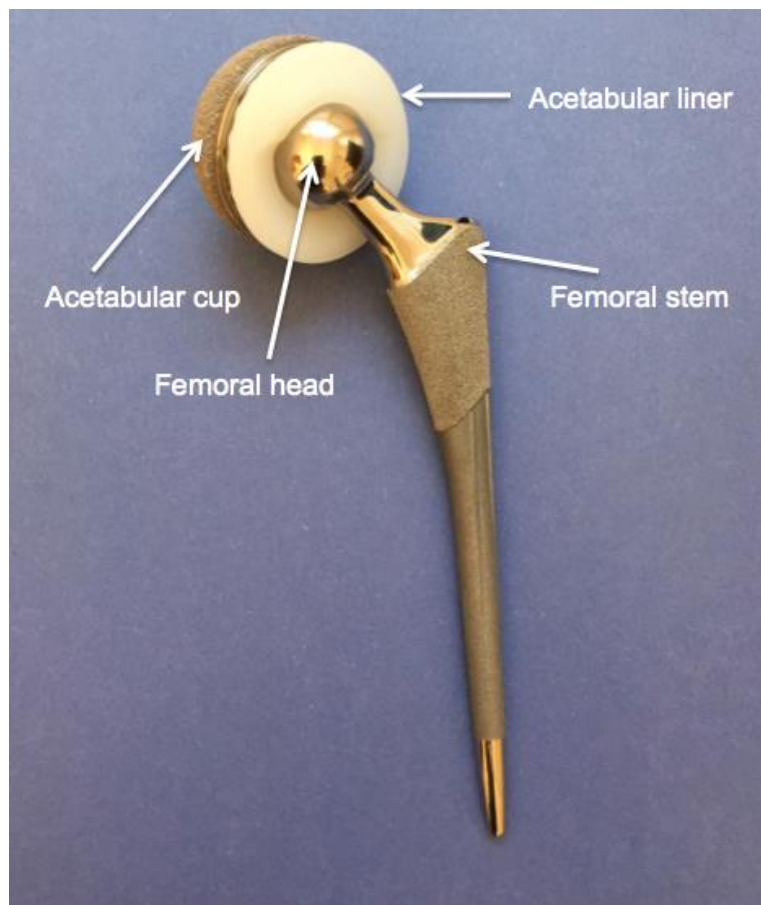


Figure 1.8 Total Hip Arthroplasty components

1.3 Surgical Approaches

1.3.1. Anterior approach to the hip

Although this surgical approach was first described in the late 19th century, it has gained popularity recently due to its purported benefits of allowing enhanced earlier recovery

within the first 3 post-operative months(7,8,9). It is performed with the patient in the supine position and can be performed on a normal operating table that can be tilted or have the foot of the bed move independently of the head of the bed, or on a specialized traction table that can apply manual traction to each limb independently as well as manoeuvre each leg independently. In this section, we will describe the surgical technique used to perform a THA using the latter variant of table.

With the patient positioned supine on the table, a perineal post is secured in place and the patient is brought down to it such that their perineum is up against said post. Each foot is then padded appropriately and placed in a traction boot, and a small amount of traction is applied symmetrically to ensure the patients perineum is fully in contact with the post(40). Care is taken to position male patients' genitalia toward the non-operative side to prevent injury.

The patients' skin is then prepped and they are draped surgically. The anterior superior iliac spine is used as a skin landmark, and a longitudinal incision directed distally and slightly laterally is then made approximately 8-10cm long. Dissection is performed down to Sartorius fascia and the fascia is then incised in line with the skin incision. The lateral femoral cutaneous nerve is protected throughout the surgery, and is retracted medially. Blunt dissection is used to develop the surgical interval between Sartorius and Tensor Fascia Lata, and then Gluteus Medius and Rectus Femoris in the deeper layer. Once this exposure is performed, the ascending branch of the lateral femoral circumflex artery is identified and ligated or cauterized to maintain haemostasis. Once the reflected head of the Rectus Femoris is retracted medially, a capsular arthrotomy is made, developing anterior and posterior leaflets of capsule which are tagged and controlled with a stay suture. The limb is placed in neutral rotation with a small amount of traction applied, and the femoral neck cut is then made and the cut femoral head is retrieved(40).

Once the acetabular labrum has been excised, acetabular retractors are then placed and acetabular preparation and component insertion can be performed using fluoroscopy to assist in the process.

When this is complete, femoral exposure is then undertaken. This is often the most challenging part of the case. A special curved retractor attached to a hydraulic side-arm can be used to anteriorize the proximal femur into the surgical field and the leg must be positioned in maximal extension, adduction and external rotation. Exposure can be further improved by dissecting the posterior capsular leaflet off the short external rotators and, if necessary, a series of soft tissue releases including Piriformis, Conjoint Tendon and, in extreme cases, a capsulectomy of the posterior leaflet. Occasionally, a small portion of Tensor Fascia Lata needs to be released off the anterior portion of the iliac wing.

When exposure is adequate, femoral preparation can commence. Even with good exposure, this step is technically demanding and the learning curve is steep. Every effort to avoid femoral complications such as intra-operative fracture or inappropriate component position or size should be made, and fluoroscopy can be used to accurately assess changes in leg length and offset.

Advantages – as previously mentioned, this approach is considered muscle-sparing, and there is much published literature that supports the purported benefit of enhanced early recovery within the first 3 months as well as diminished pain. The location of the approach also allows for a cosmetic bikini-line incision should the patient wish to have this. It is also known for having a very low dislocation rate(41).

Disadvantages – the proximity of the lateral femoral cutaneous nerve to the surgical field means the rates of injury to this nerve have been described as high as 33%(42). There is also quite a steep learning curve to the technically challenging aspects of this technique(43), with some papers describing a higher rate of femoral revisions for reasons including intraoperative fracture, femoral component undersizing leading to subsidence and aseptic loosening.

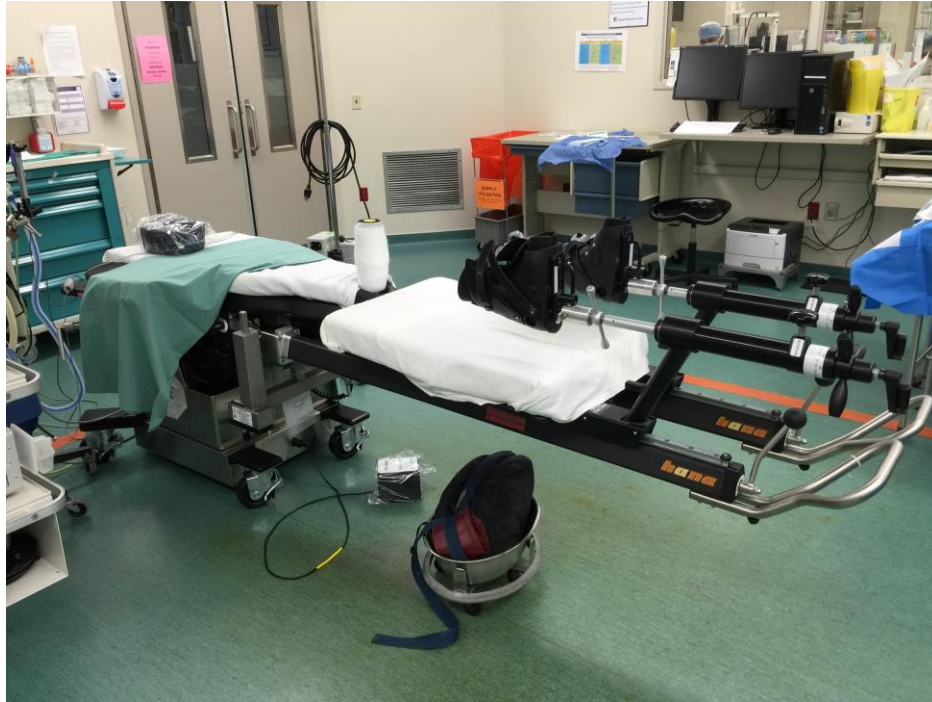

Figure 1.9 Traction table setup for anterior approach THA (Hana™ fracture table, Mizuho OSI, Union City, CA).

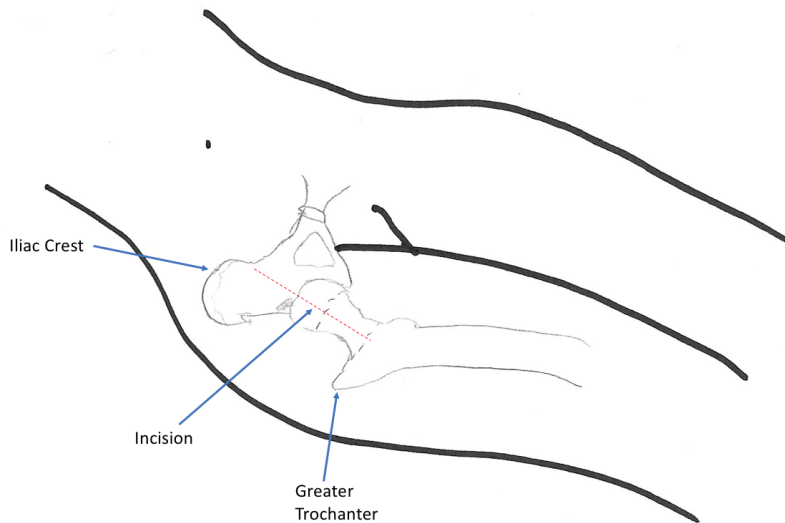


Figure 1.10 Anterior hip approach (Oblique view)

1.3.2. Lateral approach to the hip

Known more colloquially as the “Hardinge” approach to the hip after the surgeon who first described it(44), this approach provides excellent exposure of both the acetabulum and proximal femur and is suited to both primary and revision hip arthroplasty. For this reason, it is the most commonly used surgical approach for THA in Canada. It does not require a special table, though a patient positioning device (e.g. Stuhlberg frame) is required to hold the pelvis stable with the patient in the lateral decubitus position.

Using the Greater Trochanter as the skin landmark, an incision in line with the axis of the femur is made extending just proximally beyond the tip of the Greater Trochanter, and a slightly longer length distally to it. Dissection is then performed down to the level of the Tensor Fascia Lata which is then incised along the axis of the femur. Once the incision is completed, a Charnley retractor is placed to maintain exposure of the Gluteus Medius. A split is then made in the muscle fibres of the Medius muscle at approximately the midpoint of the muscle belly, and it is then dissected along with its tendon off the its insertion on the femur, and the dissection is continued across the anterior femur to its medial side. A split is also then made in the Gluteus Minimus and capsule (usually dissected as one layer together) along the axis of the neck of the femur, and this too is dissected off the anterior femur and retracted medially. Once adequate exposure of the hip joint and proximal femur is obtained, the hip can then be dislocated by manoeuvring the leg into extension, adduction and external rotation.

Once the femoral head is retrieved, acetabular retractors can be placed, labrectomy performed and preparation of the bone and insertion of the acetabular component completed. The cut end of the femur is then easily accessed by adducting, extending and externally rotating the leg once more, and femoral preparation and component insertion can be completed.

Advantages – this exposure provides an en-face view of the acetabulum, allowing for easier positioning of the acetabular component and keeping it within the safe zone. It also stays away from most major nerves and blood vessels, reducing the likelihood of

injury and allowing for a potentially more extensile exposure of the hip joint and its surrounding anatomy where necessary. It is also known for low dislocation rates(45).

Disadvantages – violating the abductor musculature can result in a limping or lurching gait post-operatively that can persist even at long-term follow-up(46). Patients with large abductor muscle mass can bias the femoral component into anteversion.

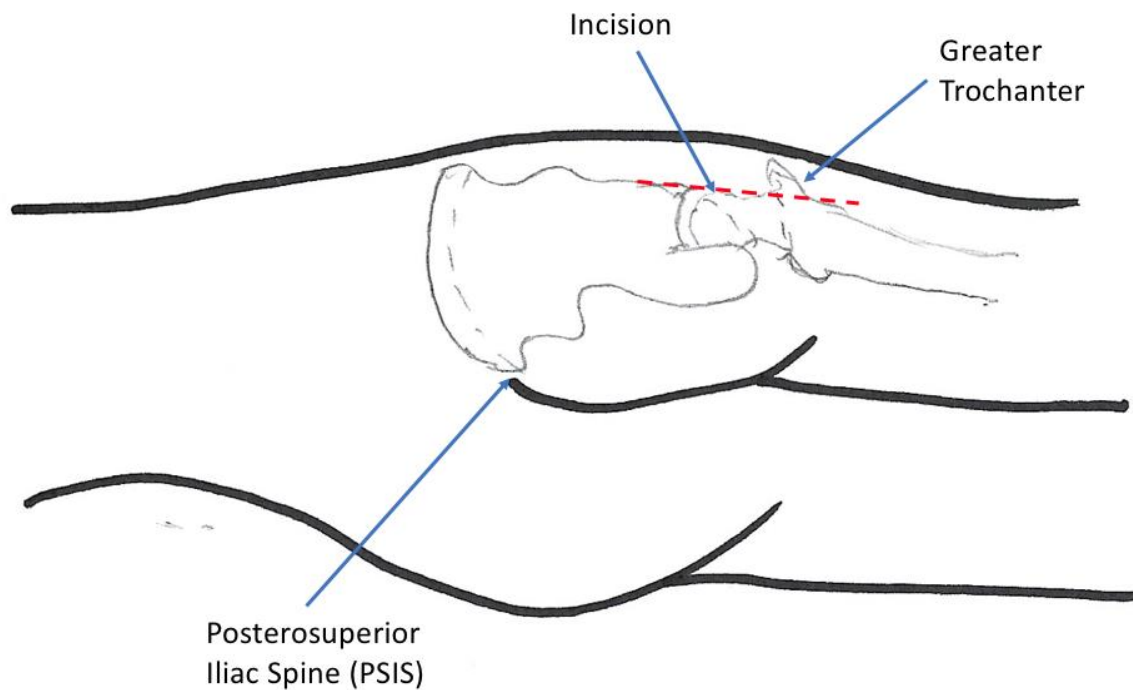


Fig 1.11 Lateral Hip Approach (PA view)

1.3.3. Posterior approach to the hip

First described by Austin Moore in 1957(13), this approach is the most commonly performed approach for THA globally. It provides good acetabular and femoral exposure(47) and can be extended significantly, making it a good choice in complex revision arthroplasty.

This approach is performed with the patient in the same position as for the lateral approach to the hip – the lateral decubitus. Indeed, patient positioning and set-up for the

cases should be virtually identical to the lateral approach. The skin incision however is lined up over the posterior one-third of the Greater Trochanter. Distally it follows parallel to the axis of the femur, more proximally it can be curved towards the posterior superior iliac spine. Dissection to gluteal fascia is performed and an incision of the fascia is made along the line of its fibres. These are then split bluntly to reveal the short external rotators and the sciatic nerve which should be identified and protected. The short external rotators are then released from their insertions, usually being tagged with stay sutures after this is performed and the hip capsule is exposed. An arthrotomy is performed and the hip can be dislocated by flexing, internally rotating and adducting the leg. The femoral neck cut can now be made, the femoral head retrieved, and in much the same way as the lateral approach, retractors placed for acetabular and femoral preparation and component placement.

Advantages – Avoids the nerve injury rates of the anterior approach and the post-operative limp of the lateral approach. Excellent extensile approach possible for both acetabulum and femur.

Disadvantages – traditionally associated with a higher dislocation rate. Can bias the acetabular component into retroversion, especially if offset reamer handles are not available.

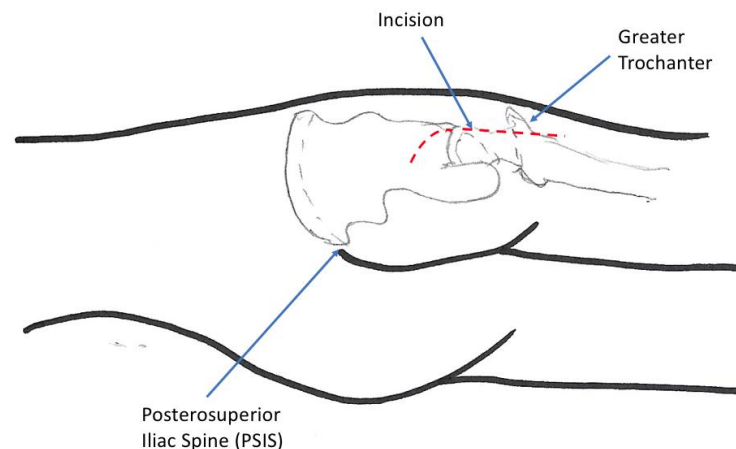


Fig 1.12 Posterior Hip Approach (PA view)

1.4 References

1. Nho SJ, Kymes SM, Callaghan JJ, Felson DT The burden of hip osteoarthritis in the United States: epidemiologic and economic considerations. *J Am Acad Orthop Surg.* 2013;21 Suppl 1:S1-6
2. Learmonth ID, Young C, Rorabeck C. The operation of the century: total hip replacement. *Lancet.* 2007;370(9597):1508-19.
3. Sochart DH Relationship of acetabular wear to osteolysis and loosening in total hip arthroplasty. *Clin Orthop Relat Res.* 1999 Jun;(363):135-150
4. D'Antonio JA, Capello WN, Ramakrishnan R Second-generation annealed highly cross-linked polyethylene exhibits low wear. *Clin Orthop Relat Res.* 2012 Jun;470(6):1696-1704
5. Kumar A, Bloch BV, Esler C Trends in total hip arthroplasty in young patients – results from a regional register. *Hip Int.* 2017 Sep 19;27(5):443-448
6. Petis S, Howard JL, Lanting BL, Vasarhelyi EM Surgical approach in primary total hip arthroplasty: anatomy, technique and clinical outcomes. *Can J Surg.* 2015 Apr;58(2):128-139
7. Parvizi J, Restrepo C, Mattenfort MG Total Hip Arthroplasty Performed Through Direct Anterior Approach Provides Superior Early Outcome: Results of a Randomized, Prospective Study. *Orthop Clin North Am.* 2016 Jul;47(3):497-504
8. Zhao HY, Kang PD, Xia YY, Shi XJ, Nie Y, Pei FX Comparison of Early Functional Recovery After Total Hip Arthroplasty Using a Direct Anterior or Posterolateral Approach: A Randomized Controlled Trial *J Arthroplasty* 2017 Nov;32(11):3421-3428
9. Meermans G, Konan S, Das R, Volpin A, Haddad FS The direct anterior approach in total hip arthroplasty: a systematic review of the literature *Bone Joint J.* 2017 Jun;99-B(6):732-740
10. Post ZD, Orozco F, Diaz-Ledezma C, Hozack WJ, Ong A Direct anterior approach for total hip arthroplasty: indications, technique and results *J Am Acad Orthop Surg.* 2014 Sep;22(9):595-603

11. Drake RL, Vogl W, Mitchell AWM Gray's Anatomy for Students Toronto, Canada: Elsevier Churchill Livingstone; 2005.
12. Brown T QC, Mihalko W, Saleh K. The Hip. 1st ed. Philadelphia, PA: Saunders Elsevier; 2009.
13. Hoppenfeld S DP, Buckley R. Surgical exposures in orthopaedics: The anatomic approach. 4th ed. Philadelphia, PA: Lippincott Williams and Wilkins; 2009.
14. Yoshioka Y, Siu D, Cooke TD. The anatomy and functional axes of the femur. J Bone Joint Surg Am. 1987;69(6):873-80.
15. Falliner A, Muhle C, Brossmann J. Acetabular inclination and anteversion in infants using 3D MR imaging. Acta Radiol. 2002;43(2):221-4.
16. Beverland D. The transverse acetabular ligament: optimizing version. Orthopedics. 2010;33(9):631.
17. Fowkes LA, Petridou E, Zagorski C, Karuppiah A, Toms AP. Defining a reference range of acetabular inclination and center-edge angle of the hip in asymptomatic individuals. Skeletal Radiol. 2011;40(11):1427-34.
18. Wagner FV, Negrao JR, Campos J, Ward SR, Haghighi P, Trudell DJ, Resnick D. Capsular ligaments of the hip: anatomic, histologic and positional study in cadaveric specimens with MR arthrography. Radiology. 2012 Apr;263(1):189-198
19. Ackerman IN, Osborne RH. Obesity and increased burden of hip and knee joint disease in Australia: results from a national survey BMC Musculoskelet Disord. 2012 Dec 20;13:254
20. Plotnikoff R, Karunamuni N, Lytvyak E, Penfold C, Schopflocher D, Imayama I, Johnson ST, Raine K. Osteoarthritis prevalence and modifiable factors: a population study BMC Public Health. 2015 Nov 30;15:1195
21. Summers MN, Haley WE, Reveille JD, Alarcon GS. Radiographic assessment and psychologic variables as predictors of pain and functional impairment in osteoarthritis of the knee or hip. Arthritis Rheum. 1988;31(2):204-9.

22. Felson DT, Lawrence RC, Dieppe PA, Hirsch R, Helmick CG, Jordan JM, et al. Osteoarthritis: new insights. Part 1: the disease and its risk factors. *Ann Intern Med.* 2000;133(8):635-46
23. Silverwood V, Blagojevic-Bucknall M, Jinks C, Jordan JL, Protheroe J, Jordan KP. Current evidence on risk factors for knee osteoarthritis in older adults: a systematic review and meta-analysis. *Osteoarthritis Cartilage.*
24. Mont MA, Hungerford DS. Non-traumatic avascular necrosis of the femoral head. *J Bone Joint Surg Am.* 1995;77(3):459-74
25. Ranawat CS. Surgical management of the rheumatoid hip. *Rheum Dis Clin North Am.* 1998;24(1):129-41
26. Manzotti A, Rovetta L, Pullen C, Catagni MA. Treatment of the late sequelae of septic arthritis of the hip. *Clin Orthop Relat Res.* 2003(410):203-12
27. Canale S BJ. *Campbell's Operative Orthopaedics.* 12th ed. Philadelphia, PA: Mosby; 2012
28. Khan AM, McLoughlin E, Giannakas K, Hutchinson C, Andrew JG. Hip osteoarthritis: where is the pain? *Ann R Coll Surg Engl.* 2004;86(2):119-21.
29. Maslowski E, Sullivan W, Forster Harwood J, Gonzalez P, Kaufman M, Vidal A, et al. The diagnostic validity of hip provocation maneuvers to detect intra-articular hip pathology. *PM R.* 2010;2(3):174-81
30. Sinusas K. Osteoarthritis: diagnosis and treatment. *Am Fam Physician.* 2012;85(1):49-56
31. Christensen R, Bartels EM, Astrup A, Bliddal H. Effect of weight reduction in obese patients diagnosed with knee osteoarthritis: a systematic review and meta-analysis. *Ann Rheum Dis.* 2007;66(4):433-9
32. Kulkarni A, Jameson SS, James P, Woodcock S, Muller S, Reed MR. Does bariatric surgery prior to lower limb joint replacement reduce complications? *Surgeon.* 2011 Feb;9(1):18-21
33. Holland C, Jaeger L, Smentkowski U, Weber B, Otto C. Septic and aseptic complications of corticosteroid injections: an assessment of 278 cases reviewed

- by expert commissions and mediation boards from 2005 to 2009. *Dtsch Arztebl Int.* 2012;109(24):425-30
34. van den Bekerom MP, Lamme B, Sermon A, Mulier M. What is the evidence for viscosupplementation in the treatment of patients with hip osteoarthritis? Systematic review of the literature. *Arch Orthop Trauma Surg.* 2008;128(8):815-23
 35. Haase E KC, Beyer F, Lützner J, Kirschner S, Hartmann A, Schmitt J, Günther KP. Patient-reported outcomes and outcome predictors after primary total hip arthroplasty: results from the Dresden Hip Surgery Registry. *Hip Int* 2016 Feb;26(1):73-81
 36. Kasper DS, Kim GK, Restrepo C, Parvizi J, Rothman RH Primary total hip arthroplasty with an uncemented femoral component five- to nine-year results *J Arthroplasty.* 2011 Sep;26(6):838-841
 37. Lim JB, Chou AC, Yeo W, Lo NN, Chia SL, Chin PL, et al. Comparison of patient quality of life scores and satisfaction after common orthopedic surgical interventions. *Eur J Orthop Surg Traumatol.* 2015;25(6):1007-12
 38. Nikolau VS, Edwards MR, Bogoch E, Schemitsch EH, Waddell JP A prospective randomized controlled trial comparing three alternative bearing surfaces in primary total hip replacement *J Bone Joint Surg Br.* 2012 Apr;94(4):459-465
 39. Askew MJ, Steege JW, Lewis JL, Ranieri JR, Wixson RL. Effect of cement pressure and bone strength on polymethylmethacrylate fixation. *J Orthop Res.* 1984;1(4):412-20
 40. Horne PH, Olson SA. Direct anterior approach for total hip arthroplasty using the fracture table. *Curr Rev Musculoskelet Med.* 2011;4(3):139-45
 41. Siguier T, Siguier M, Brumpt B. Mini-incision anterior approach does not increase dislocation rate: a study of 1037 total hip replacements. *Clin Orthop Relat Res.* 2004(426):164-73
 42. Homma Y, Baba T, Sano K, Ochi H, Matsumoto M, Kobayashi H, Yuasa T, Maruyama Y, Kaneko K Lateral femoral cutaneous nerve injury with the direct anterior approach for total hip arthroplasty. *Int Orthop.* 2016 Aug;40(8):1587-1593

43. De Steiger RN, Lorimer M, Solomon M What is the learning curve for the anterior approach for total hip arthroplasty? Clin Orthop Relat Res. 2015 Dec;473(12):3860-3866
44. Hardinge K The direct lateral approach to the hip. J Bone Joint Surg Br. 1982;64(1):17-9
45. Masonis JL, Bourne RB Surgical approach, abductor function, and total hip arthroplasty dislocation Clin Orthop Relat Res. 2002(405):46-53
46. Odak S, Ivory J Management of abductor mechanism deficiency following total hip replacement. Bone Joint J. 2013 Mar;95-B(3):343-347
47. Higgins BT, Barlow DR, Heagerty NE, Lin TJ. Anterior vs. posterior approach for total hip arthroplasty, a systematic review and meta-analysis. J Arthroplasty. 2015;30(3):419-34

Chapter 2

2. Radiostereometric Analysis (RSA)

The purpose of this chapter is to provide an overview of the development of radiographic analysis techniques used to assess movement of Total Hip Arthroplasty components within the bone into which they have been implanted and discuss the clinical importance of modern computer-assisted techniques such as Radiostereometric Analysis (RSA).

For decades, surgeons have observed that components implanted during arthroplasty surgery have the potential to move within the bone from their original implanted position(1). This phenomenon is referred to as migration, and the direction and extent to which the component moves is dependent upon the direction and size of the force vector acting upon the component. In Total Hip Arthroplasty both the acetabular and femoral components have the potential to migrate, and studies have shown that cemented acetabular components do have significant migration potential(2). However, the majority of acetabular components used in primary arthroplasty today have a cementless, press-fit design and these components migrate notably less than their cemented counterparts(3). On the femoral side however, the converse is true – cementless femoral components have been shown to migrate up to three times more than cemented femoral components within the first 6 post-operative months(4).

Measuring the extent of component migration has presented a unique challenge to surgeons over many years, with techniques to accurately quantify the phenomenon becoming more refined with advancements in technology. Ever since the advent of plain film radiographs, surgeons have been able to compare 2 radiographs from different follow-up visits and measure the distance between a fixed point on the component and a fixed point on the bone. After accounting for magnification error, one can then estimate based on the change in the measurement, the extent of component migration. The accuracy of this technique was limited when using hard copy plain film radiographs, although with the widespread adoption of computer-based radiographic imaging

software, the ability of the software to standardize the magnification in its display did afford this technique an increased level of accuracy.

Different measurements can be used to describe different patterns of migration. Figure 2.1 Indicates the most commonly used measurements to assess femoral component migration. The distance from the tip of the greater trochanter to the shoulder of the component (A) is used to measure how far the femoral component subsides down into the femur over time. The distance from the component to the inner surface of the medial(C) and lateral(D) cortices respectively and the angle portended between the lateral surface of the component and the inner surface of the lateral cortex of the femur(B) are all used to measure changes in the alignment of the component within the sagittal plane i.e. shift of the component into varus or valgus.

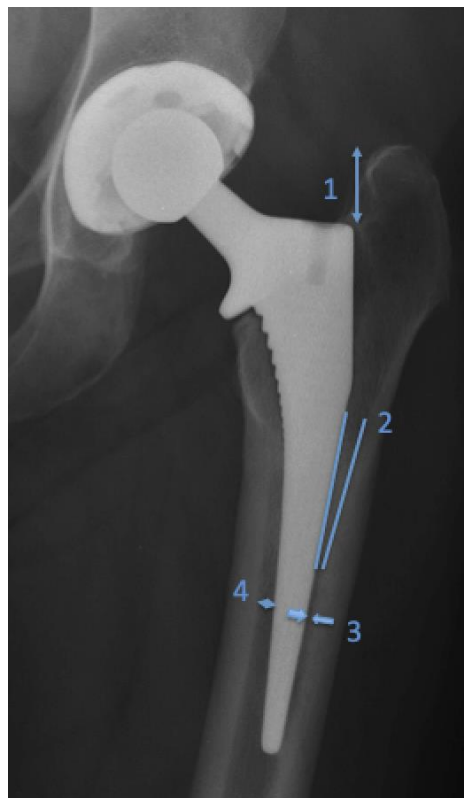


Figure 2.1 – Radiographic Analysis parameters

There are still significant limitations to this technique – the radiographic measurements, particularly ones measuring movement in the sagittal plane, are susceptible to

variations in rotation of the operative leg when obtaining the radiograph. This may create artificial differences in the measurements, and ultimately misleading data. It is also limited in its accuracy to measure small amounts of migration, with research suggesting that a minimum of 5mm of movement is necessary to prove migration when utilizing this method(5).

The underlying principles of the Radiostereometric Analysis (RSA) technique were first described in 1898 by a UK radiologist who investigated a method(6) of determining the exact position of an object in space by placing 2 X-ray tubes at different points on a horizontal beam, then taking a radiograph of the same object from 2 different angles (commonly referred to as the “stereo” method). He then placed the radiographic film underneath the X-ray tubes and used pieces of string to indicate beam trajectories for the 2 different angled films and used the intersection of the string as the true position in space of the object (Figure 2.2).

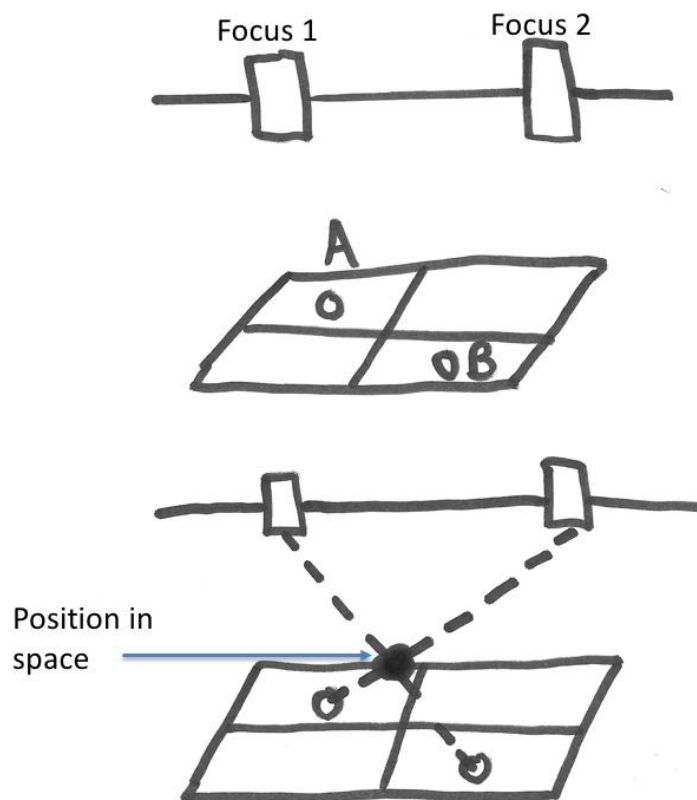


Figure 2.2 Calculating position in space based on 2 image and fixed focus points

The same basic principles of this method apply to modern RSA methods, however instead of using a “localizer” (an apparatus using known focus and film position), modern techniques use a cage with fiducial and control markers to generate a 3-dimensional co-ordinate system.

Modern RSA techniques have become invaluable to surgeons in that they produce an accurate and reliable estimate of the amount of migration an arthroplasty component undergoes over time in vivo. It does, however, operate under a number of assumptions. The first is that the rigid body model theory applies to our components and environment. This is a mathematical model using simple geometry to describe movement of one rigid body relative to another. A rigid body is defined as any 3 pairs of non-co-linear points within a body matrix where the distance between each pair of points is consistent. If the distances between these points are variable, the body is referred to as deformable.

In RSA, if the distances between paired points of two rigid bodies all change, this is referred to as translation. Rotation is defined as the points along the rotation axis not changing but all other paired points within the matrix of the rigid body changing. The overall movement of a rigid body is the sum of translation of all points within its matrix and rotation about an axis through a point in the matrix or in space.

The rigid body we are interested in measuring the movement of is the component itself. The second rigid body that we use as a reference point is the bone. However, identification of accurately and easily reproducible landmarks in the bone is almost impossible. Therefore, as a surrogate measurement, we use small tantalum beads that we implant into the bone at the time of surgery. The position of these beads remains constant within the bone, and can therefore be used as a proxy for the bone as they are easily visible on radiographs and do not change in position over time. The beads are highly biocompatible and resistant to corrosion, making them ideal choices for this process. The beads are available in 0.6mm, 0.8mm and 1mm diameter. Although using smaller beads increases the accuracy of the measurements, they are more difficult to visualize in radiographs, particularly when there is a large amount of soft tissue

coverage. For this reason, the most common bead diameter in hip or knee arthroplasty is 1mm.

Although only 3 marker beads are theoretically necessary to calculate, usually between 5 and 9 are implanted around each component to compensate for invisible or loose beads. The distribution should be random as the goal is to create a large rigid body(7) - the more the orientation of the beads resembles a straight line, the higher the condition number (an inverse measurement of accuracy) and the less accurate the technique will be. Most studies will exclude patients with condition numbers greater than 300(8). It is also important to be aware how much (if any) movement of the beads occurs – this is commonly measured via computer algorithms and is represented as a value referred to as the mean error. Values for the mean error greater than 250 μ m are usually excluded. Extra-osseous beads reduce the usable bead pattern, and decrease the accuracy of the technique also – fortunately these are rare and usually lone single beads, with prevalence around the femur reported as 2% and around the pelvis as 6%(9)

The same process is followed at most modern RSA labs (Figure 2.3) – 2 different radiographs are obtained at a known difference of angle from the perpendicular to the patient (the difference itself varying between machines from anywhere between 20 and 40 degrees). The radiographs are taken with the aforementioned cage (Figure 2.4) either behind or in front of the patient so that the markers essentially frame the joint being radiographed. The 2 radiographs are then obtained and digitally uploaded into the RSA software program. An RSA technician can then manually include or exclude marker beads wherever necessary before the software generates a digital projection of the prosthesis relative to the marker beads implanted in the bone around the prosthesis (Figure 2.5).

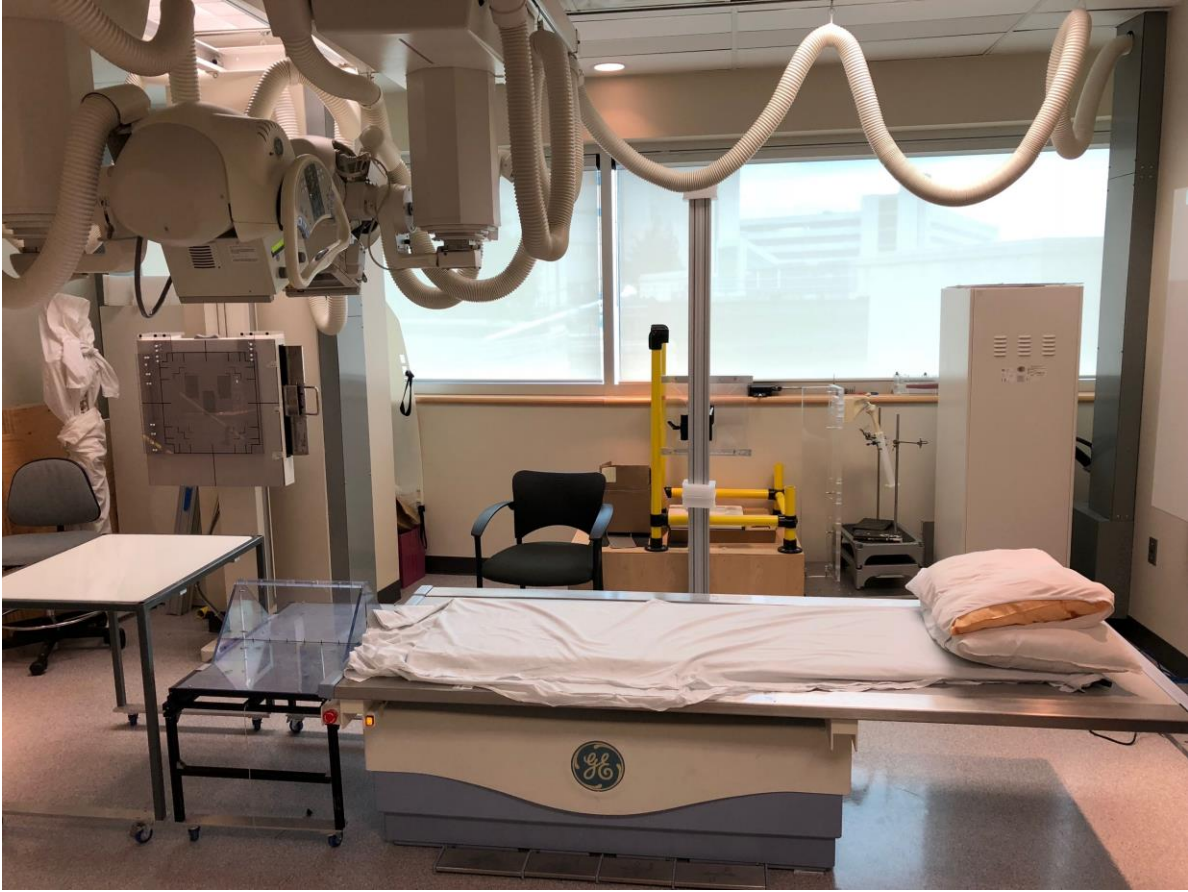

Figure 2.3 RSA Lab setup (Robarts Research Institute, London, ON, Canada)



Figure 2.4 Fiducial bead marker cage

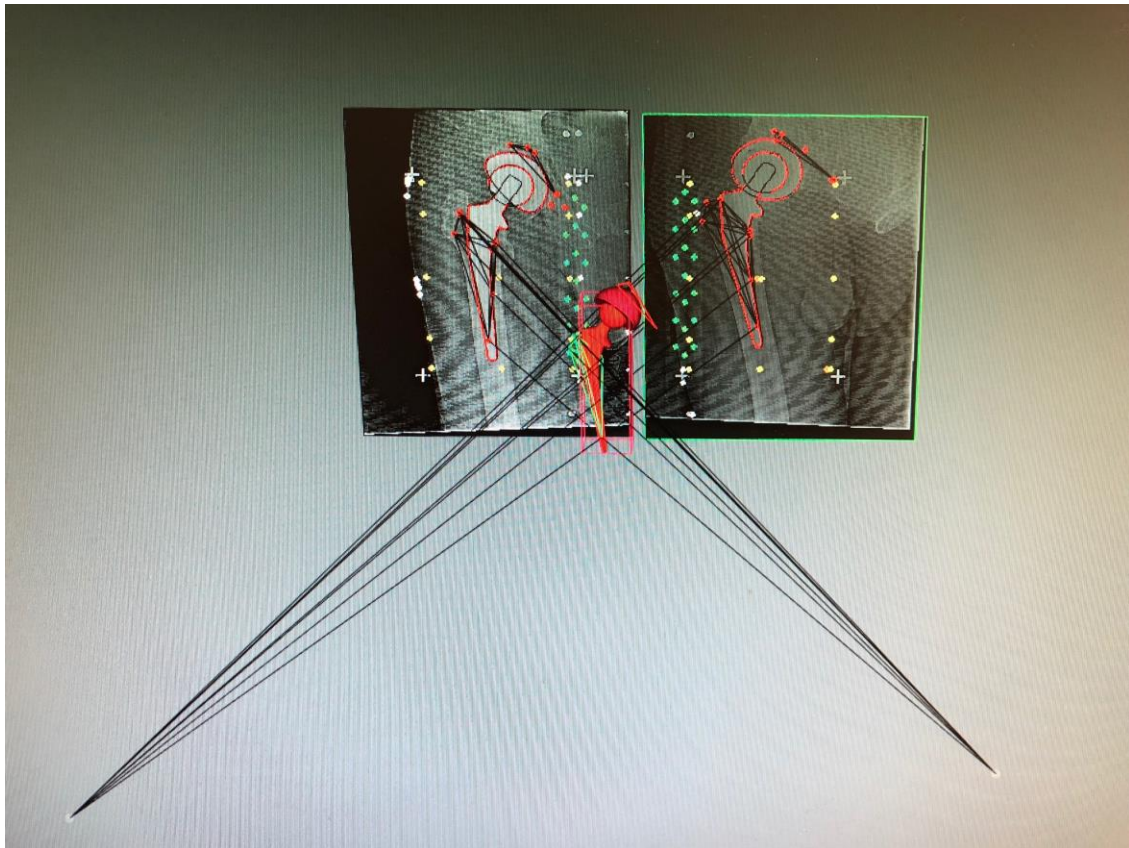


Figure 2.5 RSA Software digitally projecting prosthesis position based on RSA radiographs

With multiple RSA radiographs taken over time at regular follow-up intervals, we can generate multiple digital projections of the position of the prosthesis relative to the marker beads, and therefore we can calculate the amount of movement from the original position of the component relative to the fixed point marker beads.

The reported accuracy of RSA techniques in most studies approaches approximately 0.2mm(4) in clinical studies, with increased accuracy of 0.047 to 0.121mm described from in vitro studies(10). With this increased accuracy as compared to more basic radiographic analysis techniques, it has been suggested that RSA is arguably the gold-standard technique for evaluating new implants as failure can be predicted with fewer patients and shorter follow-up time(11). Karrholm et al.(12) suggested that $>0.33\text{mm}$ of subsidence and $>0.85\text{mm}$ of maximum total point migration before 6 months are factors highly predictive of the need for future revision surgery, with Teeter et al.(13) studying

survivorship of different cemented stems using $>0.23\text{mm}$ or $>1.2\text{mm}$ after 2 years as migration thresholds predictive of failure. These studies were conducted on cemented stems however and, as we have previously discussed in this chapter, cementless components can migrate up to 3 times more than their cemented counterparts without the risk for long term failure increasing(4). Although this does mean that it is more difficult to make long-term predictions from short-term RSA data when analyzing cementless stems, previous randomized controlled studies have shown improved fixation of hydroxyapatite coated stems when compared to beaded(14) and grit-blasted porous implant surfaces(15).

Refining RSA techniques over many years has developed a reliable, reproducible tool for assessing component migration in arthroplasty surgery with a high degree of accuracy provided tantalum marker bead placement and radiograph film quality are both optimized(16). As a result, many renowned surgical journals now require 2-year follow-up RSA data when articles investigating implant performance and survivorship are being submitted. RSA has also shown significant utility in accurately quantifying polyethylene wear, particularly when tantalum beads are incorporated into the polyethylene liner itself(17,18)

In 2005, standardized guidelines for RSA technique were published in order to facilitate reliable comparisons between research groups(19). Audit study of published RSA literature since this date however, reveals that no study has fully adhered to all guidelines, with around half of published studies partially adhering to 10 of the 13 guidelines published(20). The study did demonstrate improved methodological quality of studies published after the guidelines when compared to RSA studies published prior to their introduction in 2005.

As advances in implant technology are made, we will continue to rely on RSA techniques to provide us with important data surrounding continued implant migration long before clinical signs of failure are evident. This data is key to improving implant selection and design, and ultimately improving patient outcomes in the ever-growing arthroplasty patient population.

2.1 References

1. Mjoberg B. *Loosening of the cemented hip prosthesis. The importance of heat injury* Acta Orthop Scand Suppl. 1986; 221():1-40
2. Rorabeck CH, Bourne RB, Mulliken BD, Nayak N, Laupacis A, Tugwell P, Feeney D *The Nicholas Andry Award: comparative results of cemented and cementless total hip arthroplasty* Clin Orthop Relat Res 1996 Apr; (325):330-344
3. Thanner J *The acetabular component in total hip arthroplasty. Evaluation of different fixation principles* Acta Orthop Scand Suppl. 1999 Aug; 286():1-41
4. Soballe K, Toksvig-Larsen S, Gelinek J, Fruensgaard S, Hansen ES, Ryd L, Lucht U, Bunker C *Migration of Hydroxyapatite coated femoral prostheses. A Roentgen Stereophotogrammetric study* J Boint Joint Surg Br. 1993 Sep; 75(5):681-687
5. Sutherland CJ, Wilde AH, Borden LS, Marks KE *A ten-year follow-up of one hundred consecutive Muller curved-stem total hip-replacement arthroplasties* J Bone Joint Surg Am 1982 Sept; 64(7):970-982
6. Davidson JM *Roentgen Rays and Localisation: An Apparatus for Exact Measurement and Localisation by means of Roentgen Rays* Br Med J 1898 Jan 1; 1(1931):10-13
7. Ryd L, Yuan X, Lofgren H *Methods for determining the accuracy of radiostereometric analysis (RSA)* Acta Orthop Scand. 2000 Aug; 71(4):403-408
8. Bottner F, Su E, Nestor B, Azzis B, Sculco TP, Bostrom M *Radiostereometric Analysis: The Hip* HSS J. 2005 Sep; 1(1):94-99
9. Lawrie DF, Downing MR, Ashcroft GP, Gibson PH. *Insertion of tantalum beads in RSA of the hip: variations in incidence of extra-osseous beads with insertion site.* Acta Orthop Scand. 2003 Aug;74(4):404-407
10. Onsten I, Berzins A, Shott S, Sumner DR *Accuracy and precision of radiostereometric analysis in the measurement of THR femoral component translations: human and canine in vitro models* J Orthop Res. 2001 Nov; 19(6):1162-1167

11. Ryd L *Roentgen Stereophotogrammetric analysis of prosthetic fixation in the hip and knee joint* Clin Orthop Relat Res. 1992 Mar; (276):56-65
12. Karrholm J, Borssen B, Lowenhielm G, Snorasson F *Does early micromotion of femoral stem prostheses matter? 4-7-year radiostereographic follow-up of 84 cemented prostheses* J Bone Joint Surg Br. 1994 Nov; 76(6):912-917
13. Teeter MG, McCalden RW, Yuan X, MacDonald SJ, Naudie DD Predictive accuracy of RSA migration thresholds for cemented total hip arthroplasty stem designs. Hip Int. 2018 May 1:1120700018762179
14. Karrholm J, Malchau H, Snorasson F, Herberts P *Micromotion of femoral stems in total hip arthroplasty. A randomized study of cemented, hydroxyapatite-coated, and porous-coated stems with roentgen stereophotogrammetric analysis* J Bone Joint Surg Am. 1994 Nov; 76(11):1692-1705
15. Hamadouche M, Witvoet J, Porcher R, Meunier A, Sedel L, Nizard R *Hydroxyapatite-coated versus grit-blasted femoral stems. A prospective randomized study using EBRA-FCA* J Bone Joint Surg Br. 2001 Sep; 83(7):979-987
16. De Vries LM, van der Weegen W, Pilot P, Stolarczyk PA, Sijbesma T, Hoffman EL The predictive value of Radiostereometric analysis for stem survival in total hip arthroplasty. A systematic review. Hip Int. 2014 May-Jun;24(3):215-222
17. Dahl J, Figved W, Snorrason F, Nordsetten L, Rohrl SM Center index method-an alternative for wear measurements with radiostereometry (RSA). J Orthop Res. 2013 Mar;31(3):480-484
18. Nebergall AK, Rader K, Palm H, Malchau H, Greene ME Precision of Radiostereometric analysis (RSA) of acetabular cup stability and polyethylene wear improved by adding tantalum beads to the liner. Acta Orthop. 2015;86(5):563-568
19. Valstar ER, Gill R, Ryd L, Flivik G, Borlin N, Karrholm J. Guidelines for standardization of radiostereometry (RSA) of implants. Acta Orthop. 2005 Aug;76(4):563-572

20. Madanat R, Makinen TJ, Aro HT, Bragdon C, Malchau H Adherence of hip and knee arthroplasty studies to RSA standardization guidelines. A systematic review Acta Orthop. 2014 Sep;85(5):447-455

Chapter 3

3. Objectives

The objectives of this thesis include:

- 1) Demonstrating the extent and nature of component subsidence after Total Hip Arthroplasty in patients who receive a collared femoral prosthesis through both anterior and lateral surgical hip approaches measured via a retrospective analysis of serial post-operative plain radiographs, and how this correlates with revision rate between the two approaches.
- 2) Using RadioStereometric Analysis (RSA), demonstrating the extent and nature of component subsidence after Total Hip Arthroplasty in patients who are prospectively randomized to either receive a collared or collarless femoral component of an otherwise identical design femoral prosthesis, and how this correlates with early implant migration patterns between direct anterior and direct lateral approach surgery.
- 3) Discussing, and making direct comparisons where appropriate, the retrospectively analyzed plain radiograph data and the prospectively collected RSA data and conclusions that can be drawn from this study, including the implications for component design selection in both anterior-approach Total Hip Arthroplasty, and Total Hip Arthroplasty patients in general.

Chapter 4

4. Collared stems in Direct Anterior and Direct Lateral Primary Total Hip Arthroplasty: A Retrospective Cohort study

4.1 Introduction

Total Hip Arthroplasty (THA) is one of the most reliable and reproducible procedures in orthopedic surgery today, with recent published outcomes achieving as high as 97% success(1). One of the key requirements in accurately measuring this success is regular follow-up, consisting of serial clinical examinations, plain-film radiographs and validated patient-reported outcome measures (PROMs). The follow-up clinic visit is a unique opportunity to collect important data regarding patient outcomes that can be analyzed and form the basis of well-designed clinical studies which, in turn, can be compared to other studies of similar design to produce high-level evidence supporting the high success rates of THA(2,3). Types of obtainable data can be broadly classified into either patient-reported or physician-reported. Both have important roles – patients must report satisfaction in order for a procedure to be considered successful, but true success is only achieved when both the patient and the physician report favorably.

One of the important assessments an arthroplasty surgeon must make when assessing a patient post-operatively is the patients' post-operative radiograph. Although surgeon preference for post-THA plain film radiograph frequency varies significantly(4), most surgeons agree that serial radiographs must be taken during the first post-operative year to have sufficient information to be able to be confident of the long-term success of the arthroplasty. Numerous important pieces of information can be obtained from serial radiographic examination, including accuracy of appropriate component sizing, component orientation, any change in component position and signs of component subsidence as well as presence or absence of radiolucent lines. The latter plays a particularly important role in determining long term success, as numerous published studies have shown that the greater the degree of component subsidence, the greater the risk of requiring revision surgery(5,6).

Subsidence tends to occur more on the femoral side of the joint due to the direction of the force vectors that occur around the hip during normal mobilization. Using an inappropriately small femoral component is a risk factor for subsidence. Subsidence can cause adverse symptoms such as thigh pain, difficulty mobilizing and can result in symptomatic leg-length discrepancies and even, in more extreme cases, periprosthetic fracture(7). However, it is important to note that implant migration and subsidence does still occur in appropriately sized femoral components, albeit to much lesser degree. It is essential that the surgeon monitor for signs of gross component subsidence when examining post-operative plain film radiographs.

The purpose of this chapter is to describe a retrospective study examining serial post-operative radiographs in THA patients from the database of our academic centre who received a fully hydroxyapatite-coated collared femoral component (Corail, Depuy Synthes, Raynham, MA, USA) and describing changes in component position and quantify any migration or subsidence that may occur.

We will also assess revision rates between patients who received THA via a direct anterior or a direct lateral approach and compare the cohorts, examining reasons for revision specifically and identifying any discrepancy between the surgical approach groups.

4.2 Materials & Methods

After obtaining Research Ethics Board approval, the database of our tertiary care academic centre was searched, and anonymized data on all patients who had received a fully hydroxyapatite-coated collared femoral stem as part of primary THA surgery between January 2012 and September 2017 was extracted. The index arthroplasty surgery was performed by one of three consultant surgeons from our institution (BL, JH and EV). The data was formatted into an Excel spreadsheet (Microsoft, 2016) and each patient had three post-operative radiographs examined – the immediate post-operative radiograph taken on the day of surgery, the 1 year follow-up radiograph and the 2 year

follow-up radiograph. These radiographs were retrieved and viewed using our institutions' Centricity PACS system (General Electric Healthcare, 2018). Analysis of each radiograph included the following specific measurements:

- 1) The distance from the tip of the greater trochanter to the shoulder of the femoral component
- 2) The angle formed between the lateral border of the component and the lateral cortex
- 3) The distance from the mid-point of the femoral component to the lateral cortex
- 4) The distance from the mid-point of the femoral component to the medial cortex

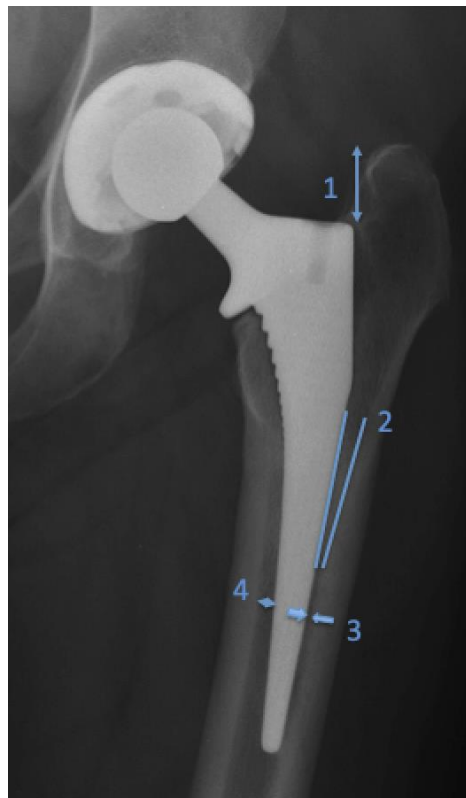


Figure 4.1 Radiographic analysis parameters

The dataset was analyzed between two reviewers (SH and MP) who analyzed the first 100 patients in the database together, comparing agreement between their values using a Pearson Correlation Coefficient. Each reviewer was then assigned half of the remaining data each to analyze independently using the same technique.

The above values were obtained for all patients in the extracted data, and these were then recorded in a separate spreadsheet to enable calculation of means/medians and standard deviations for each separate value.

Once all radiographs had been analyzed, the data was then examined for any patients who had received revision surgery, and the values for these patients were compared directly to the means/medians and standard deviations of the cohort as a whole to determine whether these patients were deemed to be outliers. The reason for the revision surgery was also recorded.

We used an unpaired t-test for statistical comparisons between mean values where appropriate (e.g. comparing the mean age and BMI of the direct anterior and direct lateral cohorts respectively). We used a chi-squared test for statistical comparisons between event rates where appropriate (e.g. revision rates between the cohorts). Statistical significance was considered to be present where the p-value < 0.05.

4.3 Results

For the aforementioned 100 patient cohort analyzed in tandem, the Pearson Correlation coefficient value for measurement A = 0.97, B = 0.75, C = 0.81 and D = 0.92, indicating good agreement between reviewers values.

Table 4.1 indicates the patient demographics from the entire retrieved cohort and their distribution across key factors such as gender, BMI, age and indication for surgery. Table 4.2 illustrates a demographic comparison between the two surgical approach cohorts respectively, along with p-values to indicate any statistically significant differences between the cohorts in each category.

Table 4.1 – Patient demographics & information

Number of patients (number of hips)	695 (778)
Mean age at time of surgery +/- SD (range)	70 +/- 12 (21-95)
Mean BMI +/- SD (range)	30 +/- 6.9 (15-74)
Sex	
Male	337
Female	358
Side	
Left	359
Right	419
Surgical Approach	
Direct Anterior	281
Direct Lateral	497
Indication (%)	
Osteoarthritis	677
Osteonecrosis/AVN	21
Post-traumatic	20
Fracture	5
Hip Dysplasia	3

Inflammatory Arthritis	3
Tumour	2
Perthes	2
Osteopetrosis	1

Table 4.2 – Demographic comparison between cohorts & statistical significance

	<i>Direct Anterior</i>	<i>Direct Lateral</i>	
Age	69.1 (+/- 11.4 SD)	70.6 (+/- 14.5SD)	$p = 0.152$
BMI	28.1 (+/- 15.7 SD)	30.3 (+/- 8.0 SD)	$p = 0.0447$
Sex	M = 123, F = 151	M = 222, F = 265	$p = 0.984$
Side	L = 139, R = 134	L = 221, R = 267	$p = 0.132$

A total of 809 hips in 734 patients received a full-hydroxyapatite coated femoral stem were retrieved from the institutional database search. We excluded 48 patients who had reported surgical approaches other than an anterior or lateral approach, leaving 761 patients for analysis. Of this cohort, 96% (n = 734) had retrievable radiographs both post-operatively and at the 1-year follow-up. Thirty-four percent (n = 275) had post-operative, 1 year and 2 year radiographs available for analysis (Figure 4.2).

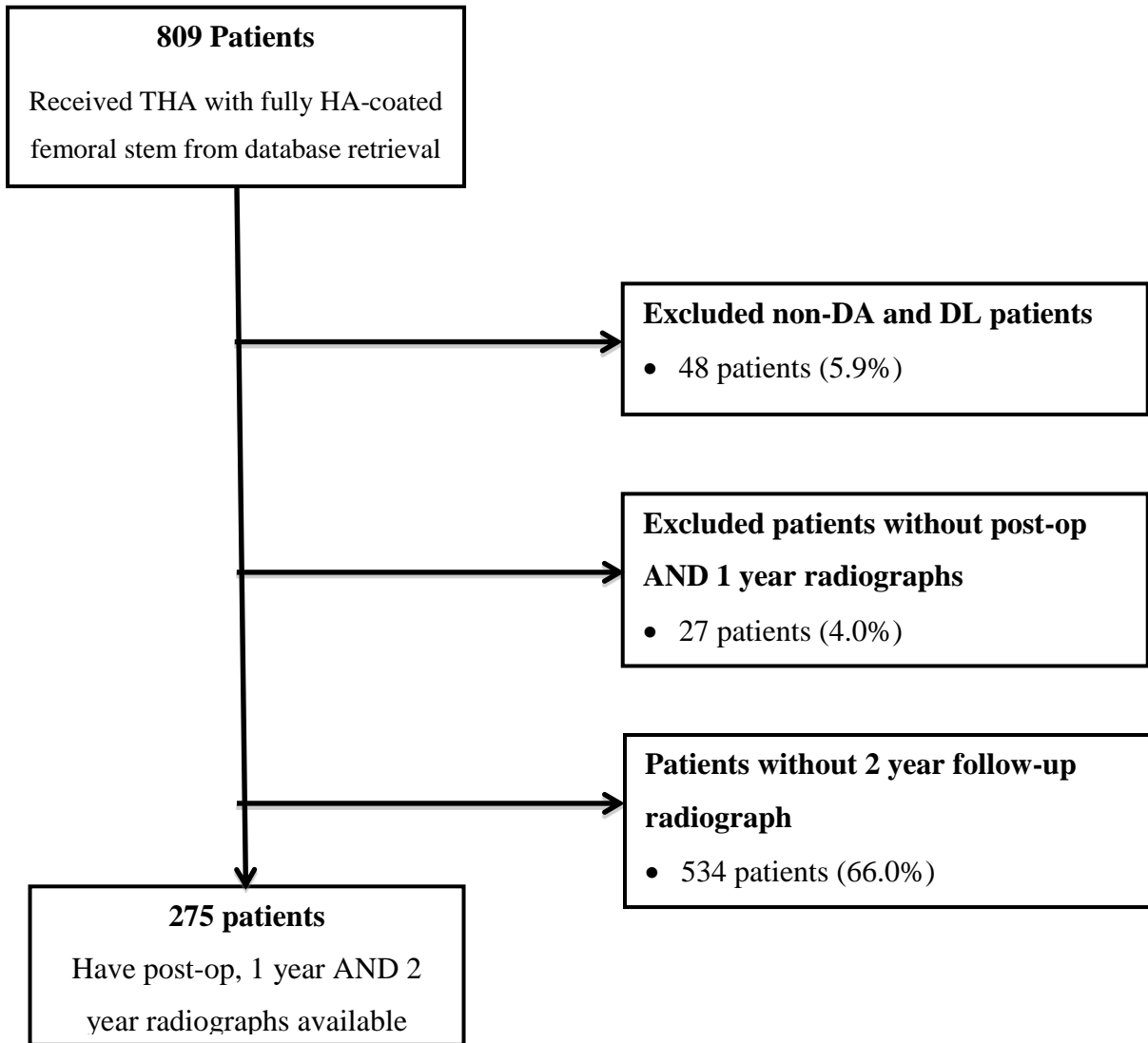


Figure 4.2 – Patient follow-up Flow Diagram

This loss to follow-up at the 2-year mark is likely due to either patient non-attendance at scheduled 2-year clinic follow-up appointment or physician judgement that the patient did not require a 2-year follow-up appointment during their 1-year assessment and therefore scheduling a follow-up at the 3-year post-surgery point instead.

Between the post-operative radiograph and the 1-year follow-up radiograph, the mean stem subsidence (as indicated by the distance measured from the tip of the greater trochanter to the shoulder of the femoral component) was 1.24mm (+/- 12.1mm SD) with the median value being 0.98mm (0 – 34.8mm Range). At the 2-year follow-up

radiograph, the mean stem subsidence from the initial post-operative radiograph was 2.09mm (+/- 8.3mm SD) with the median value being 1.88mm (0 – 26.34mm Range), indicating that on average, the stem subsided approximately a further 1mm between the first and second post-operative year.

For the angle portended between the lateral cortex of the femur and lateral surface of the femoral component, the mean difference between the post-operative and 1-year follow-up radiograph was 0.2 degrees (+/- 0.14 degrees SD) with the median value being 0.1 (0 – 7.9 degrees Range), indicating a very minor varus change of the overall component alignment. Comparing the 2-year follow-up radiograph to the initial post-operative radiograph results in a mean difference of 0.36 degrees (+/- 0.11 degrees SD) and a median value of 0.4 degrees (0 – 4.3 degrees Range), indicating that approximately a further 0.2 degrees of varus shift occurs between the first and second year post-operatively.

These alignment findings are further confirmed by the results of the analysis of the distance of the component stem at its' midpoint from the medial and lateral cortices. Between the post-operative and 1-year follow-up radiograph, the distance from the medial cortex increase by a mean of 0.12mm (+/- 0.17mm SD) and a median of 0.17mm (0 – 5.74mm Range) and further increased at the 2-year radiograph by a mean of 0.18mm (+/- 0.13mm SD) and a median of 0.14 (0 – 4.9mm Range). The lateral cortex distance decreased at the 1-year radiograph by a mean of 0.45mm (+/- 0.2mm SD) and a median of 0.1mm (0 – 1.8mm Range) and maintained this change at the 2-year radiograph with a mean of 0.44mm (+/- 0.27mm SD) and a median of 0.28 (0 – 3.75mm Range).

Table 4.3 – Radiographic Analysis by Surgical Approach

	Measurement 1	Measurement 2	Measurement 3	Measurement 4
Direct Anterior	1.88 (+/- 18.5)	0.176 (+/- 0.45)	-0.463 (+/- 2.79)	0.116 (+/- 2.12)
Direct Lateral	0.47 (+/- 7.03)	0.418 (+/- 0.16)	-0.435 (+/- 1.44)	0.027 (+/- 1.48)
<i>Unpaired t-test</i>	$p = 0.31$	$p = 0.89$	$p = 0.69$	$p = 0.29$

Examining our radiographic analysis data when broken down by surgical approach allows us to compare the migration of the femoral component implanted via both direct anterior and direct lateral approaches respectively. The mean changes in each value between the post-operative radiograph and the 2-year radiograph are indicated in Table 3. The anterior approach cohort stems subsided 1.88mm on average, compared to 0.47mm in the lateral cohort. Varus tilt occurred in both groups, with the lateral group experiencing slightly greater tilt of 0.418 degrees compared to the anterior groups' 0.176 degrees. The distance measurements from each cortex exhibited minimal difference between cohorts. No statistically significant differences exist between the cohorts for any of the measurements described.

Table 4.4 – Indications for Revision Surgery

	Direct Anterior	Direct Lateral	Chi-squared
Aseptic Loosening	1.42% (n=4)	0.4% (n=2)	$p = 0.118$
Periprosthetic Infection	0.7% (n=2)	1% (n=5)	$p = 0.676$
Periprosthetic Fracture	0.4% (n=1)	0.6% (n=3)	$p = 0.643$

Instability	0% (n=0)	0.4% (n=2)	$p = 0.916$
-------------	----------	------------	-------------

Our overall revision rate was found to be 2.5%, with 19 patients in the analyzed cohort receiving revision surgery to date. There was no statistically significant difference between the revision rate for the two surgical approaches with the revision rate in the anterior approach cohort being 2.4% and the revision rate in the lateral approach cohort being 2.5% ($p=0.95$).

The most common reason for revision across both approach cohorts was periprosthetic infection, with 36.8% ($n=7$) of patients who underwent revision surgery doing so for this diagnosis. Second most common was revision for aseptic loosening – 31.6% ($n=6$) of patients were revised for this indication. Periprosthetic fracture necessitating revision surgery was third most common with 21.1% ($n=4$). 2 patients were revised for recurrent instability

4.4 Discussion

The outcome of our radiographic analysis broadly confirms our expected results – there is subsidence of the implant over the first 2 post-operative years and a small amount of shift in alignment toward the varus direction is observed over this time also. This has been theorized to occur in collared femoral components like the one investigated in our study due to the weight bearing force vectors acting on the femoral component, with the collar contacting the calcar bone and subsequently acting as a fulcrum around which the component can tilt into varus. This theory, however, is predicated on several prerequisites:

- 1) The femoral component is undersized sufficiently to allow some varus alignment within the femoral canal.
- 2) The femoral component is not already in significant varus at the time of surgery
- 3) The femoral component subsidence that occurs during the post-operative period does not prevent this varus shift from happening

Further examination of our results reveal that, compared to research examining the extent of subsidence of a fully-hydroxyapatite collarless coated stem post-operatively, our mean value is significantly lower than values recorded(8) – supporting the

hypothesis that having a collared femoral implant reduces overall subsidence. This finding, however, is mitigated by the standard deviation values for our subsidence measurements at 1 and 2 years post-operatively being 12.1mm and 8.3mm respectively. This indicates a broad range of values for subsidence that are more in keeping with existing published literature on this topic.

When we examine our data with a view to directly comparing the two approaches, we are able to make several observations. The only statistically significant difference when comparing the demographics of patients in each cohort was in BMI, where patients who had a direct lateral approach have a mean BMI 2 points higher than those who had surgery via direct anterior approach. No other statistically significant differences were observed.

Despite recently published literature suggesting that the anterior approach carries a higher risk of femoral fracture as compared to other approaches(9), this has not been observed in our cohort. Although there appears to be a trend toward a higher infection rate in the lateral approach (n=5, 1%) when compared to the anterior approach (n=2, 0.7%) a chi-squared test reveals a p-value of 0.676 indicating no statistically significant difference. The aseptic loosening rate appears higher in the anterior approach cohort (n = 4, 1.42%) as opposed to the lateral approach cohort (n = 2, 0.4%). A chi-squared test, however, reveals a p-value of 0.118, indicating the difference is not statistically significant.

Examining the radiographic measurement data for each cohort respectively, we see large standard deviation values for each measurement indicating the limited accuracy of this technique. What we are able to observe, however, is that no statistically significant differences exist between anterior and lateral approaches for any of the measurements. We can infer from this finding that surgical approach does not significantly influence migration of the femoral stem post-operatively.

The limitations of our radiographic analysis technique must also be acknowledged. Although our analysis technique has been previously described in the literature(8), the chief limitation in using this technique to assess change in component position over time

is that measurements (particularly our angle and cortex distance measurements) are highly susceptible to error when the radiographs are taken with the limb in differing degrees of rotation. We must also recognize our limitations with respect to patient numbers within the study – despite having a significant size cohort for analysis, we remain underpowered to detect statistically significant differences for infrequent events. Although having 3 different surgeons perform the procedures introduces heterogeneity and bias into our study, this factor does have positive implications in terms of generalizability of results and eliminating a single-surgeon bias element.

With recent advances in computer-based radiographic assessment tools and radiostereometric analysis (RSA) techniques(10), these are now considered the gold-standard for examining component position changes over time. However, use of these tools requires a prospective study design and availability of an RSA lab to investigators. Conversely, when a study is retrospective or investigators do not have access to an RSA lab, the radiographic analysis technique we have described is the only way to quantify changes in component position over time.

Our revision rates, both overall and in our approach-specific cohorts, are comparable to those reported in the literature when using a fully-hydroxyapatite coated femoral stem(11), and when using other femoral stem systems(12,13). Our data indicates no statistically significant difference in early revision rates between direct anterior and direct lateral surgical approaches when using this stem. This is in contrast to recent literature findings that suggest the direct anterior approach is a risk factor for higher early revision rates(14). When examining the indications for revision, we are able to demonstrate that the majority of revision surgeries are performed for indications that are unrelated to component position or subsidence. Where patients have undergone revision surgery for indications that may be related to these factors, we have determined that they are not considered outliers within our cohort, and femoral component position change is unlikely to have contributed to their indication for revision surgery.

Our results have significant implications from a health economic perspective – new research is emerging to suggest patients who receive THA via direct anterior approach present a significantly lower cost to the hospital when compared to those who receive THA via alternate approaches(15). This study suggests that this cost-saving is not subsequently offset by higher early revision rates in the anterior approach cohort, although further cost-efficacy analysis study is required to support these hypotheses.

4.5 Conclusion

In our patient population who received collared fully hydroxyapatite-coated femoral stems as part of a Total Hip Arthroplasty, we have observed a mean femoral stem subsidence of approximately 2mm during the first 2 post-operative years. The stems also appear to shift in the varus direction by 0.4 degrees during this time. Surgical approach does not appear to affect femoral stem migration patterns significantly. Further study with radiostereometric analysis in a prospective randomized trial will produce more accurate values for femoral component position changes.

Our revision rates for patients in both the direct anterior and direct lateral cohort are comparable to prior studies and do not indicate a higher early revision rate in the anterior approach cohort as has been suggested in recent publications.

4.6 References

1. Kasper DS, Kim GK, Restrepo C, Parvizi J, Rothman RH Primary total hip arthroplasty with an uncemented femoral component five- to nine-year results J Arthroplasty. 2011 Sep;26(6):838-841
2. Haase E KC, Beyer F, Lützner J, Kirschner S, Hartmann A, Schmitt J, Günther KP. Patient-reported outcomes and outcome predictors after primary total hip arthroplasty: results from the Dresden Hip Surgery Registry. Hip Int 2016 Feb;26(1):73-81
3. Berstock JR, Blom AW, Beswick AD. A systematic review and meta-analysis of complications following the posterior and lateral surgical approaches to total hip arthroplasty. Ann R Coll Surg Engl. 2015 Jan;97(1):11-16
4. Bolz KM, Crawford RW, Donnelly B, Whitehouse SL, Graves N. The cost-effectiveness of routine follow-up after primary total hip arthroplasty. J Arthroplasty. 2010 Feb;25(2):191-196
5. Ryd L *Roentgen Stereophotogrammetric analysis of prosthetic fixation in the hip and knee joint* Clin Orthop Relat Res. 1992 Mar; (276):56-65
6. Karrholm J, Borssen B, Lowenhielm G, Snorasson F *Does early micromotion of femoral stem prostheses matter? 4-7-year radiostereographic follow-up of 84 cemented prostheses* J Bone Joint Surg Br. 1994 Nov; 76(6):912-917
7. Louboutin L, Viste A, Desmarchelier R, Fessy MH. Long-term survivorship of the Corail standard stem. Orthop Traumatol Surg Res. (2017)
8. Selvaratnam V, Shetty V, Sahni V. Subsidence in Collarless Corail Hip Replacement. The Open Orthop J. 2015;9:194-197
9. De Geest T, Vansintjan P, De Loore G. Direct anterior total hip arthroplasty: complications and early outcome in a series of 300 cases. Acta Orthop Belg. 2013 Apr;79(2):166-173
10. Onsten I, Berzins A, Shott S, Sumner DR *Accuracy and precision of radiostereometric analysis in the measurement of THR femoral component translations: human and canine in vitro models* J Orthop Res. 2001 Nov; 19(6):1162-1167

11. Vidalain, JP. Twenty-year results of the cementless Corail stem. *International Orthopaedics (SICOT)*. 2011;35:189-194
12. Pennington M, Grieve R, Black N, van der Meulen JH. Functional outcome, revision rates and mortality after primary total hip replacement—a national comparison of nine prosthesis brands in England. *PLoS One*. 2013 Sep 4;8(9):e73228
13. Danesh-Clough T, Bourne RB, Rorabeck CH, McCalden R. The mid-term results of a dual offset uncemented stem for total hip arthroplasty. *J Arthroplasty*. 2007 Feb;22(2):195-203
14. Panichkul P, Parks NL, Ho H, Hopper RH Jr, Hamilton WG. New Approach and Stem Increased Femoral Revision Rate in Total Hip Arthroplasty. *Orthopedics*. 2016 Jan-Feb;39(1):e86-92
15. Petis SM, Howard JL, Lanting BA, Marsh JD, Vasarhelyi EM. In-Hospital Cost Analysis of Total Hip Arthroplasty: Does Surgical Approach Matter? *J Arthroplasty*. 2016 Jan;31(1):53-58

Chapter 5

5. Collared vs. Collarless stems in Direct Anterior and Direct Lateral Primary Total Hip Arthroplasty: A Prospective Randomized Cohort study

5.1 Introduction

With a globally aging population, the burden of age-related hip pathology on healthcare systems is set to grow in line with recently observed trends(1). While this results in an increasing demand for Total Hip Arthroplasty worldwide(2), advances in component technology and evolving surgical techniques are expanding the indications for THA to include increasingly younger patients with symptomatic hip pathology. This paradigm shift in the field of hip arthroplasty is driving surgeons to devise and refine techniques that meet the increasing demands of the modern hip arthroplasty patient – decreased pain, shorter hospital stays and shorter times to return to work or other physical activity. Although Anterior hip arthroplasty has been well-described in the literature as meeting each of these requirements respectively (3,4,5) there is research to suggest that, in doing so, it also carries a higher risk of early revision when compared to alternative, more traditional surgical approaches(6). While the learning curve of the Direct Anterior approach has been documented in detail(7) and is often considered to be a factor when determining risk of early revision, another important question is raised – is our implant technology meeting the same demands that our surgical techniques are striving toward?

The majority of early failures in Anterior hip arthroplasty occur on the femoral side(8), and recent literature has demonstrated that fully hydroxyapatite-coated bone impaction stems outperform flat-tapered stems in the early post-operative period(8). However, although there has been cadaveric study suggesting collared stems are able to withstand greater forces before failure(9), clinical research directly comparing collared and collarless stems (Figure 5.1) has revealed no major differences in survivorship at 5

years, with only increased radiographic pedestal formation observed in the collarless group(10).

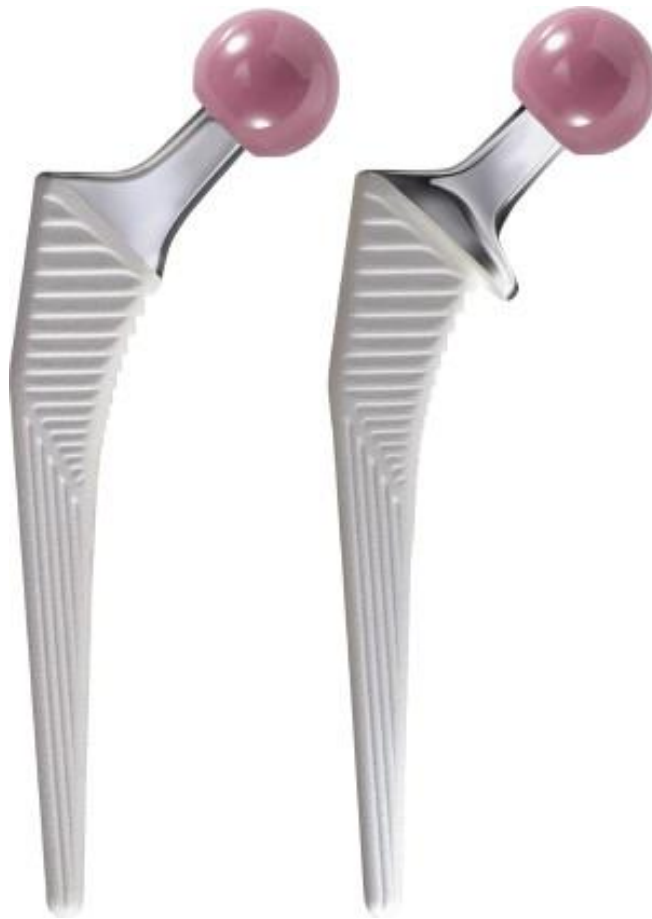

Figure 5.1 – Collarless and Collared Femoral Implants

The purpose of our study is to investigate the differences between a collared and collarless femoral component of a fully hydroxyapatite-coated bone impaction design with respect to their early survivorship as well as their migration patterns using Radiostereometric analysis (RSA) techniques.

5.2 Materials and Methods

We obtained Research Ethics Board (REB) approval at our institution for our study protocol which includes recruiting and prospectively randomizing patients seen at our institution by one of two senior surgeons (BL and EV). The patients who were

approached by study personnel for recruitment were assessed and planned for primary Total Hip Arthroplasty on an elective basis. Recruitment occurred either in the outpatient clinic at the time of assessment, or in the pre-operative assessment clinic where patients are counselled and prepared for their surgery by a team including a nurse practitioner, Anaesthesiologist and Internal Medicine specialist.

After obtaining informed consent to be included in the study, patients were then randomized using a sealed envelope technique to receive either a collared or collarless femoral prosthesis as part of their THA. The patient is blinded to their cohort, although surgeon cannot be for obvious reasons. The patient is identified as a study patient on the day of their surgery, and as part of their procedure they receive tantalum beads impacted into the bone surrounding the hip joint in a standard distribution protocol. They also receive whichever femoral component design they have been randomized to. The patients follow standard post-operative THA care pathways and are discharged from hospital accordingly.

Patients receive a baseline RSA radiograph within 24 hours after the operation. The patients then follow-up on an outpatient basis at 2, 4 and 6 weeks, and thereafter at 3 months, 6 months, 1 year and 2 years. During these outpatient visits, patient-reported outcome measures (WOMAC, HHS, SF-12, UCLA Activity score) are recorded and, as well as having standard follow-up radiographs taken, they are also taken to the RSA lab where they have special RSA radiographs taken as per standard RSA protocol.

Any revision surgery performed on any study patient within the first 2 years is recorded and the reasons for revision are also documented. RSA measurements are used to calculate implant migration at each follow-up time point, and total implant migration is also calculated based on these values. PROMs are also recorded and analyzed as per standard follow-up protocol.

5.3 Results

At the time of thesis submission, the prospective randomized trial is ongoing. 21 patients have undergone THA (10 Collared, 11 Collarless) and have both RSA and

PROM data available at 6 weeks post-operatively, 17 of these patients have RSA data available for the 3-month follow-up visit, 15 have 3-month PROM data available. These patients have undergone THA either through anterior or lateral approaches – since the study has not yet reached full recruitment for each cohort, we will report preliminary results across all approaches.

There have been no patients who have undergone revision surgery for any reason at the time of submission.

Table 5.1 – Mean UCLA Activity Score Improvement

	<i>2 weeks</i>	<i>4 weeks</i>	<i>6 weeks</i>	<i>3 months</i>
<i>Collared</i>	-2.6 (+/- 2.06 SD)	-0.8 (+/- 1.33 SD)	0.4 (+/- 1.43 SD)	1 (+/- 1.41 SD)
<i>Collarless</i>	-1.75 (+/- 2.17 SD)	-0.58 (+/- 2.22 SD)	0 (+/- 2.55 SD)	1.63 (+/- 2.74 SD)

Our PROM data indicates that during the first 4 post-operative weeks, patients describe a decline in activity. At the 6 week mark, patients begin to report equivalent or greater activity level as compared to pre-op scores, and this increase continues at 3 months post-surgery. Unpaired t-test calculated at each time interval reveals no statistically significant difference between collared and collarless groups at 2 weeks ($p = 0.37$), 4 weeks ($p = 0.7887$), 6 weeks ($p = 0.6671$) and 3 months ($p = 0.5223$).

Table 5.2 – Mean RSA Maximum Total Point Motion

	<i>2 weeks</i>	<i>4 weeks</i>	<i>6 weeks</i>	<i>3 months</i>
<i>Collared</i>	2.6 (+/- 2.06 SD)	3.05 (+/- 1.79 SD)	3.61 (+/- 2.48 SD)	4.26 (+/- 2.72 SD)
<i>Collarless</i>	6.43 (+/- 4.31 SD)	6.93 (+/- 4.83 SD)	6.76 (+/- 5.2 SD)	7.86 (+/- 5.64 SD)

Our RSA data reveals statistically significant differences between the collared and collarless cohort even at early time intervals – Table 5.2 shows mean values for the Maximum Total Point Motion at each time interval, indicating significantly more motion in the collarless group than in the collared group. Unpaired t-testing reveals statistical significance to this difference at 2 weeks ($p = 0.0194$) and 4 weeks ($p = 0.0273$) while the values at 6 weeks ($p = 0.0978$) and 3 months ($p = 0.0828$) approach significance but do not meet the threshold.

Table 5.3 – Mean RSA Total Migration

	<i>2 weeks</i>	<i>4 weeks</i>	<i>6 weeks</i>	<i>3 months</i>
<i>Collared</i>	1.3 (+/- 1.31 SD)	1.78 (+/- 1.66 SD)	2.23 (+/- 2.56 SD)	2.73 (+/- 2.60 SD)
<i>Collarless</i>	3.92 (+/- 3.03 SD)	4.42 (+/- 3.25 SD)	4.33 (+/- 3.21 SD)	4.51 (+/- 3.67 SD)

The values in Table 5.3 illustrates the mean Total Migration for both groups. As per the Maximum Total Point Motion data, we observe notably less Total Migration in the collared group at each time point than in the collarless group. Statistical significance of this difference is achieved at 2 weeks ($p = 0.0207$) and 4 weeks ($p = 0.0325$) with the values for 6 weeks ($p = 0.1162$) and 3 months ($p = 0.2194$) not achieving statistical significance.

5.4 Discussion

Although interim analysis of the limited data available at the time of thesis submission makes drawing meaningful conclusion difficult, we are able to see a trend emerging even at this early stage of the study. With such small numbers in each cohort so far, and with follow-up data having only reached the 3-month mark, it is not surprising that no revisions have occurred given that the revision rate we have observed from our previous retrospective data is around 1-2%. Similarly, early PROM data has followed an expected pattern of initially decreased scores as compared to pre-operatively in the

weeks following the surgery while recovery occurs with the trend towards improvement in these scores beginning at around the 6-week post-operative visit. The presence of a collar does not appear to influence this process given no statistically significant differences between groups in the data we have thus far.

However, our early RSA data tells a different story – even from the 2 week radiographs we have observed a statistically significant difference in the biomechanical behaviour of the collarless stems when compared to the collared stems. Greater values for Maximum Total Point Migration and Total Migration overall indicate the collarless stems are migrating more than the collared stems early on. Loss of statistical significance of this difference at the 6 week and 3 month marks may be due to increases in the standard deviations in both groups, and therefore a purely statistical phenomenon that will be eliminated when the study reaches its recruitment goal of 50 patients in each cohort. It remains possible, however, that this may be due to a true biomechanical phenomenon where stem subsidence occurs this early on in both groups, and is merely greater in the collarless group due to the limiting factor of the collar in the collared group. If this were the case, it would be more likely that no statistically significant differences between the cohorts will reveal themselves for the remainder of the follow-up visits, indicating that both stem designs have reached biomechanical stability at an early stage in the patients' recovery.

The key question that cannot be answered adequately by our data in its current limited state is: do collarless stems migrate more to a clinically significant extent? We may indeed see significant differences between Total Migration of the groups at the completion of the study, but if early revision rates remain equal, the clinical implications of using a collared stem as compared to a collarless stem may be less important than initially hypothesized.

5.5 Conclusion

Although our early and incomplete data set shows collarless stems migrating significantly more than collared stems in the immediate post-operative time period, longer follow-up and a greater number of patients in the study are needed to fully

understand whether this is a true biomechanical phenomenon and not just a misleading statistical anomaly, and whether these findings translate to significant clinical differences between these two patient cohorts.

5.6 References

1. Nho SJ, Kymes SM, Callaghan JJ, Felson DT The burden of hip osteoarthritis in the United States: epidemiologic and economic considerations. *J Am Acad Orthop Surg.* 2013;21 Suppl 1:S1-6
2. Learmonth ID, Young C, Rorabeck C. The operation of the century: total hip replacement. *Lancet.* 2007;370(9597):1508-19.
3. Parvizi J, Restrepo C, Mattenfort MG Total Hip Arthroplasty Performed Through Direct Anterior Approach Provides Superior Early Outcome: Results of a Randomized, Prospective Study. *Orthop Clin North Am.* 2016 Jul;47(3):497-504
4. Zhao HY, Kang PD, Xia YY, Shi XJ, Nie Y, Pei FX Comparison of Early Functional Recovery After Total Hip Arthroplasty Using a Direct Anterior or Posterolateral Approach: A Randomized Controlled Trial *J Arthroplasty* 2017 Nov;32(11):3421-3428
5. Meermans G, Konan S, Das R, Volpin A, Haddad FS The direct anterior approach in total hip arthroplasty: a systematic review of the literature *Bone Joint J.* 2017 Jun;99-B(6):732-740
6. De Geest T, Vansintjan P, De Loore G. Direct anterior total hip arthroplasty: complications and early outcome in a series of 300 cases. *Acta Orthop Belg.* 2013 Apr;79(2):166-173
7. Goytia RN, Jones LC, Hungerford MW Learning curve the anterior approach total hip arthroplasty. *J Surg Orthop Adv.* 2012 Summer;21(2):78-83.
8. Cidambi KR, Barnett SL, Mallette PR, Patel JJ, Nassif NA, Gorab RS Impact of Femoral Stem Design on Failure After Anterior Approach Total Hip Arthroplasty. *J Arthroplasty.* 2018 Mar;33(3):800-804
9. Demey G, Fary C, Lustig S, Neyret P, si Selmi T. Does a collar improve the immediate stability of uncemented femoral hip stems in total hip arthroplasty? A bilateral comparative cadaver study. *J Arthroplasty.* 2011 Dec;26(2):1549-1555

10. Meding JB, Ritter MA, Keating EM, Faris PM. Comparison of collared and collarless femoral components in primary uncemented total hip arthroplasty. *J Arthroplasty*. 1997 Apr;12(3):273-280

Chapter 6

6. Conclusions

Based on the research described in this thesis, we are able to draw the following conclusions:

1. Despite existing published literature suggesting a higher early revision rate in Direct Anterior Total Hip Arthroplasty, our experience at our institution is that revision rates for DA THA patients are comparable to those for patients who receive THA through a more traditional lateral approach.
2. Radiographic analysis of post-operative radiographs, while limited in its accuracy, can provide useful information regarding femoral component migration in the setting of a retrospective study design. Using this technique, we have observed no statistically significant difference in femoral stem migration between surgical approaches.
3. Early prospectively collected data suggests the presence or absence of a collar on the femoral component does not influence patient-reported outcome measures at very short-term follow-up
4. Although early RSA data suggests that collarless femoral components migrate more than collared femoral components to a statistically significant extent, the clinical implications of this information are not yet clear. Further study and data are necessary to determine how this affects survivorship.

Appendix A: The UCLA Score

UCLA Activity Score	Hip ID:
	Study Hip: <input type="checkbox"/> Left <input type="checkbox"/> Right
	Examination Date (MM/DD/YY): / /
	Subject Initials:
	Medical Record Number:

Interval: _____

<p>Check one box that best describes current activity level.</p> <p><input type="checkbox"/> 1: Wholly Inactive, dependent on others, and can not leave residence</p> <p><input type="checkbox"/> 2: Mostly Inactive or restricted to minimum activities of daily living</p> <p><input type="checkbox"/> 3: Sometimes participates in mild activities, such as walking, limited housework and limited shopping</p> <p><input type="checkbox"/> 4: Regularly Participates in mild activities</p> <p><input type="checkbox"/> 5: Sometimes participates in moderate activities such as swimming or could do unlimited housework or shopping</p> <p><input type="checkbox"/> 6: Regularly participates in moderate activities</p> <p><input type="checkbox"/> 7: Regularly participates in active events such as bicycling</p> <p><input type="checkbox"/> 8: Regularly participates in active events, such as golf or bowling</p> <p><input type="checkbox"/> 9: Sometimes participates in impact sports such as jogging, tennis, skiing, acrobatics, ballet, heavy labor or backpacking</p> <p><input type="checkbox"/> 10: Regularly participates in impact sports</p>

Appendix B: WOMAC

Your Full Name: _____
 _____/_____/_____

Today's Date:

Month Day Year

WOMAC OSTEOARTHRITIS INDEX

1. The following questions concern the amount of pain you are currently experiencing in your knees. For each situation, please enter the amount of pain you have experienced in the past 48 hours.

	None	mild	moderate	severe	extreme
A. Walking on a flat surface	A. <input type="checkbox"/>	<input type="checkbox"/>	<input type="checkbox"/>	<input type="checkbox"/>	<input type="checkbox"/>
B. Going up or down stairs	B. <input type="checkbox"/>	<input type="checkbox"/>	<input type="checkbox"/>	<input type="checkbox"/>	<input type="checkbox"/>
C. At night while in bed	C. <input type="checkbox"/>	<input type="checkbox"/>	<input type="checkbox"/>	<input type="checkbox"/>	<input type="checkbox"/>
D. Sitting or lying	D. <input type="checkbox"/>	<input type="checkbox"/>	<input type="checkbox"/>	<input type="checkbox"/>	<input type="checkbox"/>
E. Standing upright	E. <input type="checkbox"/>	<input type="checkbox"/>	<input type="checkbox"/>	<input type="checkbox"/>	<input type="checkbox"/>

2. Please describe the level of pain you have experienced in the past 48 hours for each one of your knees.

	None	mild	moderate	severe	extreme
A. Right knee	A. <input type="checkbox"/>	<input type="checkbox"/>	<input type="checkbox"/>	<input type="checkbox"/>	<input type="checkbox"/>
B. Left knee	B. <input type="checkbox"/>	<input type="checkbox"/>	<input type="checkbox"/>	<input type="checkbox"/>	<input type="checkbox"/>

3. How severe is your stiffness after first awakening in the morning?

None	mild	moderate	severe	extreme
<input type="checkbox"/>	<input type="checkbox"/>	<input type="checkbox"/>	<input type="checkbox"/>	<input type="checkbox"/>

4. How severe is your stiffness after sitting, lying, or resting later in the day?

None	mild	moderate	severe	extreme
<input type="checkbox"/>	<input type="checkbox"/>	<input type="checkbox"/>	<input type="checkbox"/>	<input type="checkbox"/>

5. The following questions concern your physical function. By this we mean your ability to move around and to look after yourself. For each of the following activities, please indicate the degree of difficulty you have experienced in the last 48 hours, in your knees.

What degree of difficulty do you have with:

	None	mild	moderate	severe	extreme
A. Descending (going down) stairs	A. <input type="checkbox"/>	<input type="checkbox"/>	<input type="checkbox"/>	<input type="checkbox"/>	<input type="checkbox"/>
B. Ascending (going up) stairs	B. <input type="checkbox"/>	<input type="checkbox"/>	<input type="checkbox"/>	<input type="checkbox"/>	<input type="checkbox"/>
C. Rising from sitting	C. <input type="checkbox"/>	<input type="checkbox"/>	<input type="checkbox"/>	<input type="checkbox"/>	<input type="checkbox"/>
D. Standing	D. <input type="checkbox"/>	<input type="checkbox"/>	<input type="checkbox"/>	<input type="checkbox"/>	<input type="checkbox"/>
E. Bending to floor	E. <input type="checkbox"/>	<input type="checkbox"/>	<input type="checkbox"/>	<input type="checkbox"/>	<input type="checkbox"/>
F. Walking on a flat surface	F. <input type="checkbox"/>	<input type="checkbox"/>	<input type="checkbox"/>	<input type="checkbox"/>	<input type="checkbox"/>
G. Getting in/out of car	G. <input type="checkbox"/>	<input type="checkbox"/>	<input type="checkbox"/>	<input type="checkbox"/>	<input type="checkbox"/>
H. Going shopping	H. <input type="checkbox"/>	<input type="checkbox"/>	<input type="checkbox"/>	<input type="checkbox"/>	<input type="checkbox"/>
I. Putting on socks/stockings	I. <input type="checkbox"/>	<input type="checkbox"/>	<input type="checkbox"/>	<input type="checkbox"/>	<input type="checkbox"/>
J. Rising from bed	J. <input type="checkbox"/>	<input type="checkbox"/>	<input type="checkbox"/>	<input type="checkbox"/>	<input type="checkbox"/>
K. Taking off socks/stockings	K. <input type="checkbox"/>	<input type="checkbox"/>	<input type="checkbox"/>	<input type="checkbox"/>	<input type="checkbox"/>
L. Lying in bed	L. <input type="checkbox"/>	<input type="checkbox"/>	<input type="checkbox"/>	<input type="checkbox"/>	<input type="checkbox"/>
M. Getting in/out of bath	M. <input type="checkbox"/>	<input type="checkbox"/>	<input type="checkbox"/>	<input type="checkbox"/>	<input type="checkbox"/>
N. Sitting	N. <input type="checkbox"/>	<input type="checkbox"/>	<input type="checkbox"/>	<input type="checkbox"/>	<input type="checkbox"/>
O. Getting on/off toilet	O. <input type="checkbox"/>	<input type="checkbox"/>	<input type="checkbox"/>	<input type="checkbox"/>	<input type="checkbox"/>
P. Heavy domestic duties (mowing the lawn, lifting heavy grocery bags)	P. <input type="checkbox"/>	<input type="checkbox"/>	<input type="checkbox"/>	<input type="checkbox"/>	<input type="checkbox"/>
Q. Light domestic duties (such as tidying a room, dusting, cooking)	Q. <input type="checkbox"/>	<input type="checkbox"/>	<input type="checkbox"/>	<input type="checkbox"/>	<input type="checkbox"/>

APPENDIX C: SF-12 Survey

SF-12 Health Survey

This survey asks for your views about your health. This information will help keep track of how you feel and how well you are able to do your usual activities. **Answer each question by choosing just one answer.** If you are unsure how to answer a question, please give the best answer you can.

1. In general, would you say your health is:

₁ Excellent ₂ Very good ₃ Good ₄ Fair ₅ Poor

The following questions are about activities you might do during a typical day. Does **your health now limit you** in these activities? If so, how much?

	YES, limited a lot	YES, limited a little	NO, not limited at all
2. Moderate activities such as moving a table, pushing a vacuum cleaner, bowling, or playing golf.	<input type="checkbox"/> ₁	<input type="checkbox"/> ₂	<input type="checkbox"/> ₃
3. Climbing several flights of stairs.	<input type="checkbox"/> ₁	<input type="checkbox"/> ₂	<input type="checkbox"/> ₃

During the **past 4 weeks**, have you had any of the following problems with your work or other regular daily activities **as a result of your physical health**?

	YES	NO
4. Accomplished less than you would like.	<input type="checkbox"/> ₁	<input type="checkbox"/> ₂
5. Were limited in the kind of work or other activities.	<input type="checkbox"/> ₁	<input type="checkbox"/> ₂

During the **past 4 weeks**, have you had any of the following problems with your work or other regular daily activities **as a result of any emotional problems** (such as feeling depressed or anxious)?

	YES	NO
6. Accomplished less than you would like.	<input type="checkbox"/> ₁	<input type="checkbox"/> ₂
7. Did work or activities less carefully than usual .	<input type="checkbox"/> ₁	<input type="checkbox"/> ₂

8. During the **past 4 weeks**, how much **did pain interfere** with your normal work (including work outside the home and housework)?

₁ Not at all ₂ A little bit ₃ Moderately ₄ Quite a bit ₅ Extremely

These questions are about how you have been feeling during the **past 4 weeks**.

For each question, please give the one answer that comes closest to the way you have been feeling.

How much of the time during the **past 4 weeks**...

		All of the time	Most of the time	A good bit of the time	Some of the time	A little of the time	None of the time
9. Have you felt calm & peaceful?	<input type="checkbox"/> ₁	<input type="checkbox"/> ₂	<input type="checkbox"/> ₃	<input type="checkbox"/> ₄	<input type="checkbox"/> ₅	<input type="checkbox"/> ₆	
10. Did you have a lot of energy?	<input type="checkbox"/> ₁	<input type="checkbox"/> ₂	<input type="checkbox"/> ₃	<input type="checkbox"/> ₄	<input type="checkbox"/> ₅	<input type="checkbox"/> ₆	
11. Have you felt down-hearted and blue?	<input type="checkbox"/> ₁	<input type="checkbox"/> ₂	<input type="checkbox"/> ₃	<input type="checkbox"/> ₄	<input type="checkbox"/> ₅	<input type="checkbox"/> ₆	

12. During the **past 4 weeks**, how much of the time has your **physical health or emotional problems** interfered with your social activities (like visiting friends, relatives, etc.)?

₁ All of the time ₂ Most of the time ₃ Some of the time ₄ A little of the time ₅ None of the time

Patient name:	Date:	PCS:	MCS:
Visit type (circle one)			
Preop	6 week	3 month	6 month 12 month 24 month Other: _____

Appendix D: List of abbreviations

THA	-	Total Hip Arthroplasty
DDH	-	Developmental Dysplasia of the Hip
AVN	-	Avascular Necrosis
SCFE	-	Slipped Capitofemoral Epiphysis
FAI	-	Femoroacetabular Impingement
RA	-	Rheumatoid Arthritis
SLE	-	Systemic Lupus Erythematosus
NSAID	-	Non-Steroidal Anti-Inflammatory Drug
ASIS	-	Antero-Superior Iliac Spine
PSIS	-	Postero-Superior Iliac Spine
RSA	-	Radiostereometric Analysis
PROM	-	Patient-Reported Outcome Measure
BL	-	Brent Lanting
JH	-	James Howard
EV	-	Edward Vasarhelyi
SH	-	Sebastian Heaven
MP	-	Maxwell Perelgut
PACS	-	Picture Archive and Communication System
BMI	-	Body Mass Index

SD	-	Standard Deviation
HA	-	Hydroxyapatite
DA	-	Direct Anterior
DL	-	Direct Lateral
REB	-	Research Ethics Board
HHS	-	Harris Hip Score
WOMAC	-	Western Ontario & McMaster Universities Osteoarthritis Index
UCLA	-	University of California, Los Angeles
SF-12	-	12-item Short Form survey

Curriculum Vitae

Dr. Sebastian Heaven, MBBCh, FRCSC

Education

- 2017 – present **Western University**
Adult Lower Extremity Reconstruction Clinical Fellow
Currently enrolled in the Masters in Surgery MSc Program to be completed in Fall 2018
- 2012-2017 **McMaster University**
Orthopaedic Surgery Resident
Rotations completed: Internal Medicine, Diagnostic Radiology, Emergency Medicine, Physical Medicine & Rehabilitation, Plastic Surgery, General Surgery, Anaesthesia, ICU/Critical Care, Orthopaedic Surgery (including Trauma, Spine, Arthroplasty, Sports, Oncology & Paediatrics)

Electives completed:
- Massachusetts General Hospital/Newton Wellesley Hospital, USA
 Lower Extremity Reconstruction
- University of Western Ontario, London, ON, Canada
 Lower Extremity Reconstruction
- 2006 – 2012 **Cardiff University**
MBBCh (Medicine)
Modules included: General Surgery & Orthopaedics, Cardiology, Respiratory Medicine, Gastroenterology, Community Medicine, Neurology, Paediatrics, Psychiatry, Obstetrics & Gynaecology, ENT, Ophthalmology, Dermatology, Infectious Diseases, Haematology and Internal Medicine
- 1999 – 2006 **King Edward's School, Birmingham**
4 A levels: Biology (B) Chemistry (A) Spanish (A) Gen Studies (A)
10 GCSE's: French (A*) English (A*) Maths (A*) Biology (A) Physics (A*) Chemistry (A) Religious Studies (A*) Music (A*) English Literature (A*) Spanish (A*)

Medical Licensures

2012 – 2017	College of Physicians and Surgeons of Ontario Postgraduate License
2018 – present	College of Physicians and Surgeons of Ontario Independent License (ACTIVE)

Publications

Journal Articles

1. **Heaven S**, de SA D, Simunovic N, Williams D, Naudie D, Ayeni OR *Hip Arthroscopy in the setting of Hip Arthroplasty* Knee Surg Sports Traumatol 2014 Nov 20 (PUBLISHED)
2. Horner NS, de SA D, **Heaven S**, Simunovic N, Bedi A, Athwal GS, Ayeni OR *Indications and outcomes of shoulder arthroscopy after shoulder arthroplasty* J Shoulder Elbow Surg 2015 (PUBLISHED)
3. **Heaven S**, de SA D, Simunovic N, Bedair H, Naudie D, Ayeni OR *Knee Arthroscopy in the setting of Knee Arthroplasty* J Knee Surg 2015 (PUBLISHED)
4. **Heaven S**, de SA D, Duong A, Simunovic N, Ayeni OR *Safety and Efficacy of Shoulder Arthroscopy in the setting of Shoulder Arthroplasty* Curr Rev Musculoskelet Med 2015 (PUBLISHED)
5. De SA D, Holmich P, Philips M, **Heaven S**, Simunovic N, Philippon MJ, Ayeni OR *Athletic Groin Pain: A Systematic Review of Surgical Diagnoses, Investigations and Treatment* Br J Sports Med 2015 (PUBLISHED)
6. Bedair H, Antioch V, **Heaven S** *Line-to-line Reaming of Highly Porous Acetabular Components Improves Position and Reduces Variability of Component Placement* J Hip Surg 2017 (PUBLISHED)

Textbook Chapters

1. Dugani S, Alfonsi J *Shoulder, Elbow, Hand and Wrist – Clinical Anatomy Cases: An Integrated Approach with Physical Examination and Medical Imaging*, Lippincott Williams 2016

Presentations

- 2011 - 1st All-Wales Student Research Symposium – “Outcomes of Oxford Unicondylar Knee Arthroplasty in a District General Hospital” (POSTER)
- 2012 – 3rd International Student Medical Congress Kosice – “Outcomes of Oxford Unicondylar Knee Arthroplasty in a District General Hospital” (PODIUM)
AWARDED 1st PLACE IN SURGERY CATEGORY
- 2014 – Canadian Association of Sports and Exercise Medicine Annual Meeting – “Hip Arthroscopy in the setting of Hip Arthroplasty” (POSTER)
- 2015 – Canadian Orthopaedic Association Annual Meeting – “Hip Arthroscopy in the setting of Hip Arthroplasty” (POSTER)

- 2015 – Canadian Orthopaedic Association Annual Meeting – “A Survey of Canadian Orthopaedic Surgeon use of Tranexamic Acid in Arthroplasty and Hip Fracture Surgery” (POSTER)
- 2015 – International Society for Hip Arthroscopy “Athletic Groin Pain: A Systematic Review of Surgical Diagnoses, Investigations and Treatment” (POSTER)
- 2016 – American Academy of Orthopaedic Surgeons Annual Meeting – “Line to Line Reaming of Porous Cups Improves Position and Reduces Variability in Acetabular Component Placement” (POSTER)

Courses/Conferences Attended

2013 – OTA Comprehensive Fracture Course for Residents 2.0
 2013 – AAHKS Resident Arthroplasty Course/Annual Meeting
 2014 – OTA Advanced Fracture Course
 2015 – ATLS Instructor Course
 2016 – CORR Trauma
 2016 – CORR Paeds
 2016 – CORR Recon
 2016 – SPORC St. Justine Review Course, Montreal

Educational Responsibilities

2009	Tutor to high school students during “MedWales” career experience event.
2010	Clinical tutor to high school students for Cardiff University “Medical Roadshow”. Interview panel member for prospective medical student admissions interview
2011	Team member in development of the Clinical Skills Video project that won the 2010 International Journal of Clinical Skills award. Volunteer for Peer-Assisted Learning programme at Cardiff university.
2012	Clinical Tutor to McMaster University medical students in core knowledge “MF2” modules and clinical skills sessions including suturing, casting & splinting workshops
2013	Elected Orthopaedic Surgery co-ordinator and Vice President of McMaster University Surgical Foundations Committee

Other Qualifications

01.04.2012	-	ACLS Certified
15.02.2015	-	ATLS Instructor Qualified