

Medical and Biological Sciences, 2012, 26/4, 103-110

Maciej Nowacki¹, Wiesław Nowacki², Edward Szymkowiak²

THE USE OF PERIOPERATIVE PHYSIOTHERAPY METHODS IN SURGICAL TREATMENT OF IDIOPATHIC SCOLIOSIS – AN ANALYSIS OF THE LATEST REPORTS AND SCIENTIFIC LITERATURE

ZASTOSOWANIE METOD FIZJOTERAPII OKOŁOOPERACYJNEJ W CHIRURGICZNYM LECZENIU SKOLIOZ IDIOPATYCZNYCH – ANALIZA NAJNOWSZYCH DONIESIEŃ I PIŚMIENNICTWA

¹Tissue Engineering Department at the Nicolaus Copernicus University in Toruń, Ludwik Rydygier's Collegium Medicum in Bydgoszcz

Head: dr hab. n. med. Tomasz Drewna (Prof.UMK) FEBU, NCU

²Department of Orthopaedics and Musculoskeletal Traumatology at the Nicolaus Copernicus University in Toruń, Ludwik Rydygier's Collegium Medicum in Bydgoszcz

Head: dr n. med. Edward Szymkowiak

Summary

Introduction. The term of idiopathic scoliosis refers to a change (deformity) of uncertain etiology related to improper setting of the spine, of a lateral curvature greater than 10 degrees by Cobb classification, with a characteristic image of abnormalities of the spine-chest axis and the topographic-anatomical axis. Some of such changes, particularly those characterized by a significant degree of progression or specific indication are referred for a surgical correction. The perioperative use of physiotherapy methods is now one of the most important factors of a complex surgical treatment.

The aim of this study was to present the applicability of the methods in the field of physical therapy in the perioperative surgical treatment of idiopathic scoliosis.

Material and methods. The paper presents an analysis of the literature from the years 2000-2012 in the field of spinal surgery in terms of correction of idiopathic scoliosis. Materials were selected according to information

about the use of perioperative physiotherapy methods in preparing the patient for surgery, and postoperative rehabilitation.

Results. There are many physical therapy preoperative methods used in spinal surgery to support the process of idiopathic scoliosis correction. In all of the analyzed scientific materials and available guidelines, it is demonstrated a significant positive effect of the different methods used in the perioperative physiotherapy Intra-correction and the possibility of long-term results obtained after surgery.

Conclusions. The use of modern methods of perioperative physiotherapy in surgical treatment of idiopathic scoliosis should be an important element of a comprehensive procedure. Methods of physiotherapy should be performed at a specified time prior to surgery and after surgery to ensure adequate, positive clinical results.

Streszczenie

Wstęp. Termin skolioza idiopatyczna odnosi się do zmian o nieokreślonej etiologii dotyczących nieprawidłowego ustawienia kręgosłupa, o charakterze skrzywienia bocznego powyżej 10 stopni wg Cobba z charakterystycznym obrazem zaburzeń osi symetrii kręgosłup- klatka

piersiowa, względem osi topograficzno-anatomicznych. Niektóre tego typu zmiany, szczególnie te cechujące się istotnym stopniem progresji i powyżej odnośnikowych punktów referencyjnych wg. poszczególnych skal oceny, stanowią istotne wskazanie do korekcji chirurgicznej.

Wprowadzanie rehabilitacji okołoperacyjnej stanowi obecnie jeden z ważniejszych czynników kompleksowego leczenia zabiegowego.

Celem pracy było przedstawienie możliwości stosowania metod z zakresu fizjoterapii okołoperacyjnej w chirurgicznym leczeniu skolioz idiopatycznych.

Materiał i metody. W pracy dokonano analizy piśmiennictwa z lat 2000-2012 z zakresu chirurgii kręgosłupa w aspekcie korekcji skolioz idiopatycznych. Materiał dobierano pod kątem informacji z zakresu wykorzystania metod fizjoterapii okołoperacyjnej w przygotowaniu pacjenta do zabiegu i rehabilitacji pooperacyjnej.

Wyniki. Istnieje obecnie wiele technik z zakresu fizjoterapii okołoperacyjnej, wspomagających zabiegową korekcję zmian klinicznych o charakterze skoliozy

idiopatycznej. We wszystkich analizowanych przykładach przedstawiono dostępne wytyczne i wykazano istotny wpływ stosowana poszczególnych metod fizjoterapii okołoperacyjnej na śród zabiegową możliwość korekcji i uzyskiwane wyniki odległe po zabiegu.

Wnioski. Stosowanie nowoczesnych metod fizjoterapii okołoperacyjnej w chirurgicznym leczeniu skolioz idiopatycznych powinno być podstawowym elementem kompleksowego postępowania. Metody fizjoterapeutyczne powinny być wprowadzane w ściśle określonym czasie przed zabiegiem i po zabiegu dla uzyskania odpowiednich, pozytywnych wyników klinicznych.

Key words: idiopathic scoliosis, spine surgery, perioperative physiotherapy methods

Słowa kluczowe: skolioza idiopatyczna, chirurgia kręgosłupa, fizjoterapia okołoperacyjna

INTRODUCTION

The term of idiopathic scoliosis defined a heterogeneous syndrome of uncertain etiology, of the changes relating to incorrect, three-dimensional setting of a spinal curvature. The complexity of the clinical problem and the large value of early treatment in selected cases, including surgical intervention, especially in the case of progressive scoliosis, have been known for a long time. Already in the scientific work of Lovett, published in 1913 in the *Journal of Bone & Joint Surgery*, the author describes the history and development of diagnostic and research methods according to different types of scoliosis with information about the complexity of the clinical and pathological features, found in many descriptions of individual case reports of patients [1,2]. Proper identification and monitoring, supported by imaging studies, including an assessment of the angle of curvature of the spine usually with Cobb classification, allows avoiding the possibility of error in the form of Pre-treatment system selection and prediction of progression [3,4]

Currently, according to the latest guidelines of international orthopedic societies and scientific organizations such as Society on Scoliosis Orthopaedic and Rehabilitation Treatment (SOSORT) and Scoliosis Research Society (SRS), and also according to the latest literature publications, the term of idiopathic scoliosis, shall be strictly called as a structural nature change (deformity) of unknown origin in the wrong setting of the spine, affecting as a side curvature. Mostly right-sided by more than 10 degrees in a Cobb classification, this was determined on the basis of X-ray images in the Anterior / Posterior projection.

Idiopathic scoliosis, is clinically characterized by disturbances in the axis of symmetry between the spine and chest, and also in another different topographic-anatomical axis. Those disorders occur frequently in the asymmetry and structural change of the shape of the elements directly affecting the spatial arrangement of the spine, including the shape of individual vertebrae and intervertebral discs, or asymmetry of the ligament, muscle and fascia anatomical parts of the back. The complexity of the problems of scoliosis also shows a large heterogeneous number of possible combinations of disorders of the spine axis and its spatial arrangement. According to the Lenke, Betz et al. there are six main types of idiopathic scoliosis with the possible three subtypes, depending on the modification of the lateral curvature. The most common type of idiopathic scoliosis is a one side main thoracic curvature of the spine [5,6,7,8,9].

The clinical assessment of each patient with scoliosis, regardless of diagnosis age, is important to establish the size of lesions and their possible degree of progression. This affects the taken action and perioperative treatment directly. Physical activity, based on the principles of modern methods of physiotherapy, including exercises undertaken by an individual or in rehabilitation group, usually are nowadays described as a therapeutic element, used mostly in patients with low grade changes, without significant progression. Another kind of standard use of various physical activities not considered with perioperative procedures is rehabilitation in combination with the apparatus used in the treatment

or orthopedic corset by scoliosis in patients with intermediate-level changes [10, 11].

However, the important point in the development of physiotherapy seems to be the implementation of kinesiology methods and other forms and methods of field exercises and physical activity as a part of a comprehensive, systemic perioperative procedure. By this type of methods, called perioperative, properly prepared implementation of staggered activation of the motoric system, placed before the surgery to activation of muscular-ligamentous support for the best possible, surgical correction is understood. This type of systemic treatment is also very important in the early period after surgery, to shorten the period of hospitalization and more rapid mobilization.

According to the Society on Scoliosis Orthopaedic and Rehabilitation Treatment (SOSORT) an essential factor for the introduction of implementation of such methods of physiotherapy in the treatment of systemic and comprehensive surgery, is knowledge of the characteristics of problematic patients scheduled for surgical correction of scoliosis, including basic eligibility criteria.

OBJECTIVE

The objective of this study was to present the possibility, various methods and techniques in the field of perioperative physiotherapy as a factor supporting, through a comprehensive surgical treatment of idiopathic scoliosis, along with a discussion of the characteristics of patients eligible for surgery.

MATERIAL AND METHODS

The paper presents an analysis of the literature from the years 2000-2012 with a range of topics related to spinal surgery and physiotherapy in terms of correction of idiopathic scoliosis. Materials were selected for information according to the use of perioperative physiotherapy methods in preparing the patient for surgery and postoperative rehabilitation conduct. Material selection was performed using bibliographic databases such as PubMed, Springer, Willey, ProQuest, Google Scholar and used in analysis consensus guidelines, descriptions of research and teaching materials in the form of recommendations of clinical and scientific societies and organizations from an interest group of study of scoliosis and spinal surgery, orthopedics and rehabilitation medicine. We

have analyzed scientific and public material, published by: Society on Scoliosis Orthopaedic and Rehabilitation Treatment (SOSORT), Scoliosis Research Society (SRS), the British Scoliosis Research Foundation (BSRF), North America Spine Society (NASS), The American Academy of Orthopaedic Surgeons (AAOS), British Association of Spine Surgeons (BASS), The Spine Society of Europe (Eurospin), The International Society of Physical and Rehabilitation Medicine (ISPRM), The American Academy of Physical Medicine and Rehabilitation (AAPM & R).

I. Treatment criteria

Currently, there are several well-known and well-defined indications for an operational correction of scoliosis surgery. Indications are based on many published meta-analysis and analysis, which clearly define the moment in which the physician should consider the decision to execute the procedure in the individual case study. The criteria for treatment are determined on the basis of three main types of classification of individual patients. This classification include: 1) classification according to Cobb angle (often includes an evaluation of the relative rate of progression of time estimation), 2) Risser classification 3), evaluation of clinical indications and complications. Less frequently used scales are used only in certain cases, for example, the fusion performance considerations include the method of King and Lenke or others [12,13,14].

1. Indications according to the Cobb classification

The patient is classified in this case on the basis of measurements, respectively, based on the principles of the Cobb technique [Figure 1.]. The measurements are almost always of full format of spine x-ray, performed in a standing position. In recent years, some scientific work on the possibilities of computer measurement techniques under X-ray and computed tomography were created, but the authors advise against the use of assessment techniques such as standard; they only recommend it as part of the introduction of additional preoperative diagnosis, or Intra in innovative navigation techniques, aimed at evaluation of vertebral rotation, axis disorders and scoliosis angle in different planes. However, in this type of innovative techniques it is important to properly assess the behavior of the

geometric differences in the standing and supine patient, to waive any errors in the evaluation [15,16,17]. Nowadays, accepted and suggested criteria for the indication of the surgical treatment of scoliosis cases are above 40 degrees Cobb angle (Criteria of the Pediatric Orthopaedic Society of North America (POSN), the most widely used reference mean angular values between 45 ° and 50 ° and upwards. An important factor in this type of classification is also assessing the progression of scoliosis in relation to time of evaluation and monitoring of the patient [13, 14, 18].

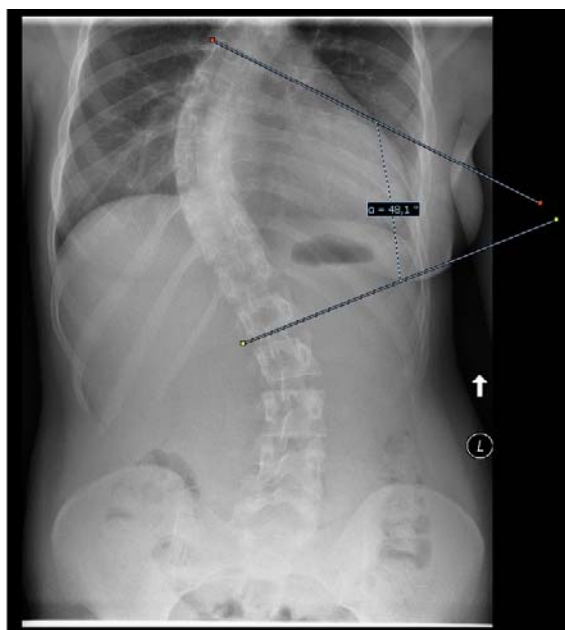


Fig. 1. X-ray of 19 year's old patient with idiopathic scoliosis before surgery (48.1° of cobb angle)

Fig. 2. RTG 19-letniej pacjentki, z skoliozą idiopatyczną przed zabiegiem operacyjnym. Z kątem skrzywienia mierzonym za pomocą klasyfikacji Cobba (48.1°).

2. Indications according to the Risser classification

Rissera classification is based on the analysis of skeletal maturity with a special evaluation of the pelvis and spine; the clinical significance of this test is especially important for the evaluation of idiopathic scoliosis occurring in children. Assessments are made on the basis of the X-ray images. Performing surgery is possible in case of grade IV and V by Risser. This ratio is often given with important calculation of scoliosis progression in the time estimation formula of Lonstein and Carlson [13, 19, 20].

3. Other clinical indications

Other clinical indications group include: all of the spinal geometry deformations, which can significantly affect the functioning of the circulatory and respiratory system (confirmed by appropriate diagnostic procedures), and also induce pathological neurological symptoms, the scoliosis of large values of the Cobb angle (60 ° -100 °). The surgical correction is possible as an indication of eligible patients with Cobb angle values lower than 40 °, in the hypokyphosis or lordosis coexistence in the thoracic spine or treatments performed from cosmetic reasons in case of major disturbances of chest-torso-spine symmetry [21, 22, 23, 24].

II. An outline of surgical techniques

Surgical techniques used in the correction of idiopathic scoliosis appeared already in the early twentieth - century through pioneering treatments of F H. Wilkins of Kansas who first applied the operational stability of the spine. For the treatment he used a wire covered with carbolic acid, with which he fixed the individual vertebral pediculus arches. This technique took over and was continued by Hadr from Galveston in Texas. However, these treatments were not fully schematizing void. The authors, who first described the technique of correction effectively, were Hibbs (1911) and Albee (1913). But the largest contribution to the development and elaboration of relevant procedures and guidelines for treatment, including the appropriate instruments (developed according to his idea), was brought Dr. Paul Harrington of the Rehabilitation Hospital in Houston in 1960 [25,26].

Currently, there are many methods and types of surgical procedures, instruments and implants used in surgical correction of idiopathic scoliosis. The most important criteria that should be taken into consideration during the individual techniques is to determine the surgical access, which could be on the back and front, or in some cases combined. This is also crucial to take action in the field of perioperative physiotherapy in both situations, before and after the surgery. The most commonly used methods include the use of modified techniques by Harrington, the CD method, the method of Dero, LFC and other implants, Vepr, fusion techniques, modifications of surgical techniques according to the MoE and Wisconsin (WSSI) techniques using Luque'a rod, and the

introduction of ephiphysiodesis, Vats, Th -plasty and many other techniques [Figure .2] [27,28].

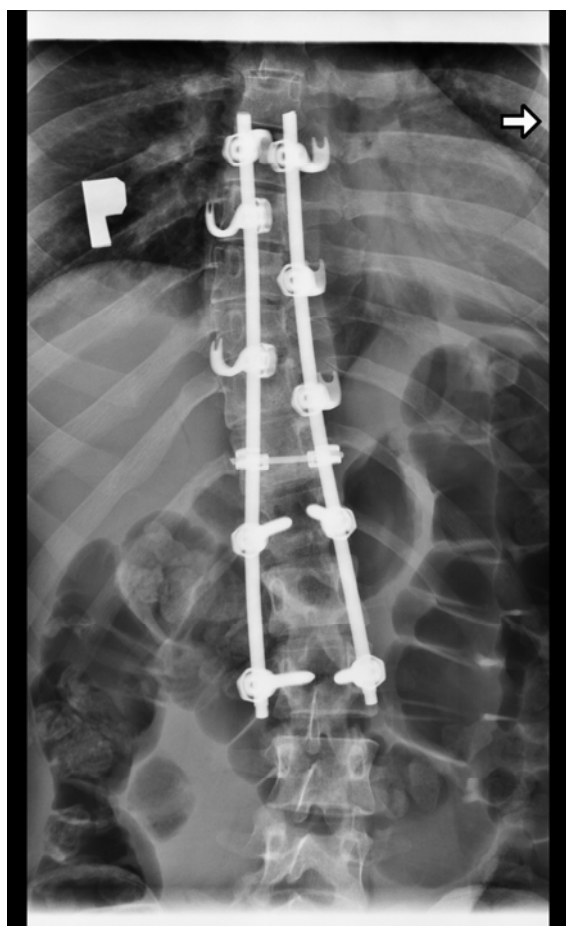


Fig. 2. X-ray of the same patient (from Fig. 1) after surgical correction of scoliosis using the LFC implant
Ryc. 2. RTG pacjentki (z ryc. 1) po chirurgicznej korekcie skoliozy za pomoc q implantu LFC

III. Preoperative physiotherapy methods.

The physiotherapy methods used in the perioperative period fall strictly within the composition of perioperative care techniques. Those techniques are now widely used increasingly in many disciplines to improve the treatment of the patient and are targeted on better elimination of long surgical procedures and for reducing the problems associated with the proper anesthesia. It is a rule is to ensure a general systemic efficiency in the most points of cardiovascular and respiratory systems in this type of procedure. It was also noted that a properly conducted, strictly physiotherapy care before the significantly affects the shortening of hospital stay and postoperative mobilization of the patient.

For the patients operated for idiopathic scoliosis, these actions are magnified by the tactics of proper preparation of muscular-ligament, fascia, and most importantly, of the spine and its individual components in the correction procedures. In the long-term assessments and studies were shown that the use of multi-compounded physiotherapy perioperative methods may be an significant, important factor in some cases affecting onto the possibility of greater intraoperative correction of idiopathic scoliosis patients with various degrees by a particular classification. The authors suggested that those methods should be entered in both groups of patients with idiopathic scoliosis, that's mean: children and adults.

An important factor is to know the team leading preoperative therapy based on the methods of physiotherapy, should know clinical and surgical indications (according to the 3 main criteria) and to know the planed surgical technique, chosen taking into account the appropriate access. Perioperative therapy should generally be conducted in the same facility where the patient will be operated, including the indications of leading surgeon.

The primarily physiotherapy group of methods used in preoperative management of patients with idiopathic scoliosis include: 1) breathing exercises and inspiratory muscle training, 2) kinesiology methods (with relaxation and stretching methods), 3) traction method, 4) preoperative bracing methods.

1. Breathing Exercises and inspiratory muscle training

Breathing exercises as a physical work on the correct pressing track operations and breathing are among the most important supporting techniques, used in a wide variety of surgeries. Mainly this type of activity is supported by the majority of surgical societies including the bringing together organizations and societies recommend the use of spinal surgery and therapy, breathing exercises and the muscles, responsible for proper functioning of the breathing apparatus. In the case of scoliosis surgery is it still an important meaning, namely by supporting the anterior operation procedures, and positive impact on the faster postoperative mobilization.

2. Kinesiology methods

There are several well-defined groups of exercises and opportunities for therapy with the use of appropriate systems, traffic patterns and conducting exercises and physical activity. We have find the

specify methods, which can be used as a preoperative treatment physiotherapy methods. We have selected the: Schrot method, DoBoMED (Dobosiewicz method), the use and movement patterns of PNF method and standard kinesis exercises, with modification for children.

The method called Schrot comes from Kahtarina Schrot, which has developed three main assumptions of this method (3 –dimensional method). Although the method is known for a long time, now for the perioperative and standard use are developed specific modifications and guidelines, but the underlying assumptions do not remain unchanged. Synonymic names of this method are postural correction, correction of breathing patterns and correction of postural perception (Weiss 2011).

DoBoMED method was developed by Mrs. Prof. K. Dobosiewicz in Katowice Poland as a standard treatment method for patients with small angle progressive scoliosis in their clinic. Durmala, Kotwicki and Detko suggest in their work titled *Physiotherapy for idiopathic scoliosis according to DoBoMED* (2011) that this method could help to increase the curve flexibility in the immediate preoperative stage.

PNF method - This method is one of the most popular methods used in general rehabilitation. Very useful in perioperative period of surgery is a proprioceptive neuromuscular facilitation stretching (PNF-stretching), which allows patients to fully mobilize of the muscles. As well as extending support activities based on the exact patterns of movement based on the proper conduct of the kinetic chain in accordance with the principles of biomechanics during all preoperative exercises.

Kinesiology methods used as a perioperative physical exercises, regularly based on standard physiotherapeutic kinesis techniques used in small angle non-progressive scoliosis. However, significant difference is placed from the introduction till end of preoperative kinesis program. The high attention is targeted onto execution of the movements mainly in the sagittal plane with the exception of lateral movement, in order to obtain the positive effect in the short term on patients preparing for the treatment. Those methods must also be strictly and specifically modified when they are applying into patients with more than one arch in the axis of spine flexion, as well as when planed method are applying for children. For work with children there are many exercise used as a “playing or game exercises” with the use of appliances

and utensils. It is also important to be careful in working individually or in groups with children or teenagers, to do not lead to a push in a short time before the surgery.

3. Traction Method

Nowadays the mostly used traction method is a Halo-Gravity method, which could be used separately or in two another kinds of individual methods, as a Halo femoral and halo tibial traction (Qui, Liu et all. 2007). The Halo-Gravity method allows the reduction of the risk of neurologic compromise by the rapid curve correction, especially if there is significant kyphosis. This method is positively assessed by Scoliosis Research Society (SRS), North America Spine Society (NASS) and The American Academy of Orthopaedic Surgeons (AAOS). Rinella, Lenke and Whitaker (2003) informed that Halo Gravity method could be an important factor for faster patient socialization and mobilization after surgery.

4. Preoperative bracing methods

The procedure for the use of tailored corsets and braces in individual patient case as a method for the preoperative treatment of idiopathic scoliosis is particularly recommended by the Scoliosis Research Society (SRS) and the British Scoliosis Research Foundation (BSRF). A research group led by Wang (2009) stated that the use of properly designed and individually tailored brace does not adversely affect onto the operational procedure, and can be used as a preoperative factor.

IV. Early Postoperative Rehabilitation

Postoperative rehabilitation management includes early stage rehabilitation, in a short time after surgery, the rehabilitation methods used during hospitalization, and not included in this study remote method of rehabilitation and improvement. Early postoperative management is very important for the future rehabilitation process. In the first moments after surgery rehabilitation focuses on breathing exercises and ensures the correct alignment. Often this stage is supported by pharmacological investigation of an analgesic treatment. On consecutive days it is an important element of early mobilization of patients, including sitting, walking and implementation of the

free socializing methods seamless. In the early rehabilitation proceedings shall be used the method of general systemic, securing performance, including passive exercises, active and passive steps upper and lower limbs or along the rim of muscle activation [29,30].

V. Analysis of results and conclusions

In this paper, we have presented main information's, as a review of literature, according to perioperative physiotherapy methods and necessary short form of basic knowledge, about characteristics and clinical classification of patients with idiopathic scoliosis. We analyzed publicly available database of the literature and some guidelines for leading organizations and associations dealing with the treatment of idiopathic scoliosis. The use of modern methods of perioperative physiotherapy in surgical treatment of idiopathic scoliosis should be an important element of a comprehensive procedure. Methods of physiotherapy should be placed at a specified date prior and after the surgery to ensure adequate, positive clinical results. It is important to breakdown the elements of therapy before surgical, early after a treatment, and not included in the proceedings improving perioperative distant. Currently, there are several important methods successfully applied and implemented in the system's treatment of scoliosis. The problem of this type of deformity of the spine is very complex and therefore should require a close study of each case. Individual approach to each patient, together with the use of showed in this publication methods, according to the general analyzed literature. This data could have a potential affect in the improvement of treatment, as well as heavily on the patient's rapid return to daily duties and full efficiency. Perioperative procedures can be significant factors supporting the perioperative patient endurance, especially in cases of large lesions.

REFERENCES

- Guille JT, D'Andrea LP, Betz RR: Fusionless treatment of scoliosis. *Orthop Clin North Am.* 2007 Oct;38(4):541-5
- R.W. Lovett: The History of Scoliosis. *The Journal of Bone & Joint Surgery* 1913; s2-11:54-62
- Rigo MD, Villagrasa M, Gallo D: A specific scoliosis classification correlating with brace treatment: description and reliability. *Scoliosis.* 2010 Jan 27;5(1):1.
- Zhang J, Lou E, Shi X, Wang Y, Hill DL, Raso JV, Le LH, Lv L.A computer-aided Cobb angle measurement method and its reliability. *J Spinal Disord Tech.* 2010 Aug;23(6):383-7
- T. Kotwicki, J. Durmała, D. Czaprowski, M. Głowacki, M. Kołban, S. Snela,
- Śliwiński, I. M. Kowalski: Zasady leczenia nieoperacyjnego skolioz idiopatycznych – wskazówki oparte o zalecenia SOSORT 2006 (Society on Scoliosis Orthopaedic and Rehabilitation Treatment) *Ortopediia Traumatologia Rehabilitacja;* 2009; 5(6); Vol. 11, 379-39
- Growth Negrini S, Aulisa AG, Aulisa L, Circo AB, de Mauroy JC, Durmala J, Grivas TB, Knott P et al.: 2011 SOSORT Guidelines: Orthopaedic and Rehabilitation Treatment of Idiopathic Scoliosis. *Scoliosis* 2012, 7:3
- S. Gutknecht, J. Lonstein, T. Novacheck: Adolescent Idiopathic Scoliosis: Screening, Treatment and Referral A Pediatric Perspective 2009, Vol 14(4) 1-4
- Guidelines on "Standards of management of idiopathic scoliosis with corrective braces in everyday clinics and in clinical research": SOSORT Consensus 2008. *Scoliosis.* 2009 Jan 16;4:2.
- S Mohanty, N Kumar: Patterns of presentation of congenital scoliosis. *Journal of Orthopaedic Surgery* 2000, 8(2): 33–37
- Weiss HR, Negrini S, Hawes MC, Rigo M, Kotwicki T, Grivas TB, Maruyama T; Physical exercises in the treatment of idiopathic scoliosis at risk of brace treatment -- SOSORT consensus paper 2005. *Scoliosis.* 2006 May 11;1:6.
- Bürger W, Dietsche S, Morfeld M, Koch U: Ambulante und stationäre orthopädische Rehabilitation - Ergebnisse einer Studie zum Vergleich der Behandlungsergebnisse und Kosten. *Rehabilitation* 2002; 41: 92-102.
- Lenke LG, Betz RR, Harms J, Bridwell KH, Clements DH, Lowe TG, Blanke K: Adolescent idiopathic scoliosis: a new classification to determine extent of spinal arthrodesis. *J Bone Joint Surg Am.* 2001 Aug;83-A(8):1169-81.
- T. Maruyama, K. Takeshita: Surgical treatment of scoliosis: a review of techniques currently applied. *Scoliosis.* 2008 Apr 18;3:6
- Weiss HR, Negrini S, Rigo M, Kotwicki T, Hawes MC, Grivas TB, Maruyama T, Landauer F: Indications for conservative management of scoliosis (guidelines). *Scoliosis.* 2006 May 8;1:5
- Quante M, Richter A, Thomsen B, Köszegvary M, Halm H. Surgical management of adult scoliosis. The challenge of osteoporosis and adjacent level degeneration. *Orthopade.* 2009 Feb;38(2):159-69.
- Adam CJ, Izatt MT, Harvey JR, Askin GN: Variability in Cobb angle measurements using reformatted computerized tomography scans. *Spine (Phila Pa 1976).* 2005 Jul 15;30(14):1664-9.
- Cui G, Wang Y, Kao TH, Zhang Y, Liu Z, Liu B, Li J, Zhang X, Zhu S, Lu N, Mao K, Wang Z, Zhang X, Yuan X, Dong T, Xiao S: Application of Intraoperative Computed Tomography with or without Navigation

- System in Surgical Correction of Spinal Deformity- A Preliminary Result of 59 Consecutive Human Cases. *Spine (Phila Pa 1976)*. 2011 Oct 21.
18. Monticelli G, Corigliano A, Illiano S, Costanzo G. Indications for early surgery in cases of lumbar and dorsolumbar scoliosis: the role of vertebral rotation. *Ital J Orthop Traumatol*. 1990 Sep;16(3):347-53.
 19. Negrini S, Aulisa AG, Aulisa L, Circo AB, de Mauroy JC, Durmala J, Grivas TB, Knott P, Kotwicki T, Maruyama T, Minozzi S, O'Brien JP, Padopoulos D, Rigo M, Rivard CH, Romano M, Wynne JH, Villagrana M, Weiss HR, Zaina F. 2011 SOSORT Guidelines: Orthopaedic and Rehabilitation Treatment of Idiopathic Scoliosis During Growth. *Scoliosis*. 2012 Jan 20;7(1):3
 20. Lonstein JE, Carlson JM: The prediction of curve progression in untreated idiopathic scoliosis during growth. *Journal of Bone and Joint Surgery* 1984, 66-A:1061-1071.
 21. Greiner KA. Adolescent idiopathic scoliosis: radiologic decision-making. *Am Fam Physician*. 2002 May 1;65(9):1817-22.
 22. Lonner BS, Auerbach JD, Sponseller P, Rajadhyaksha AD, Newton PO. Variations in pelvic and other sagittal spinal parameters as a function of race in adolescent idiopathic scoliosis. *Spine (Phila Pa 1976)*. 2010 May 1;35, 374-7
 23. Weiss HR. Adolescent idiopathic scoliosis (AIS) - an indication for surgery? A systematic review of the literature. *Disabil Rehabil*. 2008;30(10):799-807.
 24. Aebi M. The adult scoliosis. *Eur Spine J*. 2005 Dec;14(10):925-48
 25. Winter RB: Innovation in surgical technique. The story of spine surgery. *Clin Orthop Relat Res*. 2000 Sep;378:9-14.
 26. A. Smoczyński, M. Smoczyński, P. Łuczkiwicz, R. Pankowski, K. Poblócki: Operacyjne leczenie boczno-idiopatycznego skrzywienia kręgosłupa zmodyfikowanym sposobem Harringtona podłukowymi pętlami drutu. *Ann. Acad. Med. Gedan.*, 2007, 37, 103-110
 27. I. Madejska, A. Doroszewska-Szczepanik: Pre- and postoperative rehabilitation of elderly patient. *Borgis - Postępy Nauk Medycznych* 12/2008, s. 804-810
 28. Takaso M, Nakazawa T, Imura T, Okada T, Fukushima K, Ueno M, Takahira N, Takahashi K, Yamazaki M, Ohtori S, Okamoto H, Okutomi T, Okamoto M, Masaki T, Uchinuma E, Sakagami H. Surgical management of severe scoliosis with high risk pulmonary dysfunction in Duchenne muscular dystrophy: patient function, quality of life and satisfaction. *Int Orthop*. 2010 Jun;34(5):695-702.
 29. Wang C, Zhao Y, He S, Zhu X, Zhao Y, Chen Z, Gu S, Xie Y, Li M. Effect of preoperative brace treatment on quality of life in adolescents with idiopathic scoliosis following corrective surgery. *Orthopedics*. 2009 Aug;32(8).
 30. Green BN, Johnson C, Moreau W. Is physical activity contraindicated for individuals with scoliosis? A systematic literature review. *J Chiropr Med*. 2009 Mar;8(1):25-37

Address for correspondence:

1. Tissue Engineering Department, ul. Karłowicza 24, 85-092 Bydgoszcz

2. Department of Orthopaedics and Musculoskeletal Traumatology, Szpital Uniwersytecki nr 1 im. dr. A. Jurasza w Bydgoszczy, ul. Skłodowskiej-Curie 9, 85-094 Bydgoszcz

Corresponding author: Maciej Nowacki –
maciej.s.nowacki@gmail.com

Phone: 692-412-444

Department of Orthopaedics and Traumatology:
52 585-47-21

Received: 10.01.2012

Accepted for publication: 6.03.2012