

Rowan University

Rowan Digital Works

Faculty Scholarship for the College of Science & Mathematics

College of Science & Mathematics

2005

Early oral-motor interventions for pediatric feeding problems: What, when and how

C. J. Manno

C. Fox

P. S. Eicher

Mary Louise Kerwin

Rowan University, kerwin@rowan.edu

Follow this and additional works at: https://rdw.rowan.edu/csm_facpub

 Part of the [Child Psychology Commons](#), and the [Pediatrics Commons](#)

Let us know how access to this document benefits you -
share your thoughts on our [feedback form](#).

Recommended Citation

Manno, C. J.; Fox, C.; Eicher, P. S.; and Kerwin, Mary Louise, "Early oral-motor interventions for pediatric feeding problems: What, when and how" (2005). *Faculty Scholarship for the College of Science & Mathematics*. 93.

https://rdw.rowan.edu/csm_facpub/93

This Article is brought to you for free and open access by the College of Science & Mathematics at Rowan Digital Works. It has been accepted for inclusion in Faculty Scholarship for the College of Science & Mathematics by an authorized administrator of Rowan Digital Works. For more information, please contact rdw@rowan.edu.

Early Oral-Motor Interventions for Pediatric Feeding Problems: What, When and How

Cecilia J. Manno, Catherine Fox, Peggy S. Eicher and MaryLouise E. Kerwin

Abstract

Children with developmental delays often have feeding difficulties resulting from oral-motor problems. Based on both clinical experience and a review of published studies, oral-motor interventions have been shown to be effective in improving the oral function of preterm infants and children with neuromotor disorders, such as cerebral palsy. However, oral-motor problems may be under identified in other populations of children with developmental difficulties. The purpose of this paper is to provide a conceptual framework for understanding oral-motor skill development and problems that can occur in any infant and young child and to review oral-motor treatment techniques and their empirical support.

Keywords: dysphagia, feeding behavior, oral stimulation, oral-motor, behavioral intervention.

Oral-motor problems in children are easy to recognize when the child coughs and chokes while eating. However, the majority of feeding problems present initially in more subtle ways, such as difficulty introducing spoon feedings or advancing texture, or limited variety of foods accepted (Kerwin, 1999). For some children, these more common feeding problems may reflect a specific oral-motor problem, such as uncoordinated tongue movement during lateralization or dysfunctional oral transport of the food bolus to the back of the mouth to initiate the swallowing reflex. Children with neurological disorders, or those born prematurely often exhibit oral-motor problems (Gisel, Alphonse, & Ramsay, 2000; Lau & Hurst, 1999; Sullivan, Lambert, Ford-Adams, Griffiths, & Johnson, 2000). Increasing evidence suggests that oral-motor problems are under-recognized in children with problems other than cerebral palsy (Ramsay, Gisel, McCusker, Bellavance, & Platt, 2002; Reilly, Skuse, Wolke, & Stevenson, 1999), including children with autism disorders (Amato & Slavin, 1998).

Oral motor skills develop within a system that changes rapidly both in structural growth and neurological control during the first three years of life (Arvedson & Lefton-Greif, 1996; Bosma, 1986). During this period, children engage in a great variety of oral motor experiences as they satisfy their basic needs for food and comfort and begin to explore their world. Developmentally, a feeding problem exists when a child is “stuck” in their feeding pattern and cannot progress (Eicher, 2002; Kerwin, 2003; Palmer & Horn, 1977). Because oral motor skills represent a sequential progression of increasingly complex movement patterns, any disruption in practice can interfere with or limit positive oral motor practice, resulting in the loss of advancement in skill development and the learned behaviors that ensue (Illingworth & Lister, 1964). The challenge of treating children with feeding problems comes in identifying the specific areas that interfere with skill advancement for the individual child (Rudolph & Link, 2002; Stevenson & Allaire, 1991). Understanding each of the active factors interfering with skill advancement and the interaction of those factors enables the treating team to: 1) identify the specific factors contributing to the feeding problem; and then 2) ameliorate them to allow the child successful practice leading to positive learning, skill advancement and mastery (Kerwin & Eicher, 2004).

The following case history will serve as an example of some of the common, but more subtle, oral motor problems in children that require early, intensive intervention: bottle dependence, difficulty advancing texture, food refusal and food selectivity. Joey is a 4-year-old boy with hypotonia (i.e., low muscle tone), mild cognitive and motor delays, severe speech delay, poor social relatedness, and a

tendency to perseverate. He will eat only yogurt, Dutch apple dessert and pureed banana baby foods, and will drink only apple juice from a sippy cup. Joey's mother reports that Joey always loved bottle-feeding, but preferred to drink lying down rather than while being held. He gagged and vomited every time spoon-feeding was attempted. At 15 months, his parents were able to introduce cream soups with a tablespoon while semi-reclined in a bouncy seat. Through the efforts of weekly feeding therapy, yogurt and the two fruit baby foods were successfully introduced. He has recently become interested in the green colored small fish crackers, but he only shaves the tails down with his front teeth. At age 2, the pediatrician advised getting rid of the bottle. When his parents stopped offering the bottle, Joey no longer accepted milk. Desperate to get fluids into him, his parents resorted to apple juice via dropper. He now accepts only apple juice and only through a sippy cup while lying down.

Joey's feeding patterns demonstrate components of food refusal, food selectivity, failure to advance texture, and bottle dependence. Despite being four years old and having only mild motor and cognitive delays, Joey is stuck in a very abnormal feeding pattern with high risk of serious short- and long-term health and developmental consequences. The purpose of this paper is to elucidate the contributing factors to oral-motor skill development and practice, review the existing literature for empirical evidence regarding these interventions, and elaborate on possible intervention strategies that could be used to treat these feeding difficulties.

Development of Oral-Motor Skills

Oral-motor ontogeny follows a stepwise progression building on the suckle reflex to acquire the more complex oral-motor milestones suck, munch, and chew (Bosma, 1986; Ogg, 1975). Just as with gross motor skill development, milestone acquisition is not driven by maturation alone. Rather, the emergence of each oral-motor milestone is also dependent upon successful practice (Eicher, 2002; Illingworth & Lister, 1964; Pinnington & Hegarty, 2000). Infants are born with a biologically driven suckle reflex which fades around four months of age (Ingram, 1962). When the infant uses the reflex successfully with breast or bottle feedings, they master suckling and its coordination with breathing (Herbst, 1983). In addition, this practice occurs contemporaneously with neuronal growth and development that together enable the infant to acquire volitional control over the suckle response (Arvedson & Lefton-Greif, 1996; Bosma, 1986; Miller, 1993). If an infant does not experience successful practice with the suckle reflex before the reflex fades at four months of age, the suckle pattern may not be mastered (Illingworth & Lister, 1964). As a result, the infants may not be able to successfully initiate nutritive sucking (i.e., nipple feeding) without the propelling effect of the suckle reflex even if the child practiced non-nutritive sucking. This reciprocal, dynamic influence between the child's practice during feeding and oral-motor skill development continues until the child has accomplished the most advanced skill, rotary chewing (Smith, Weber, Newton, & Denny, 1991).

Oral-motor skill development is integrally linked with increasingly complex tongue movements (Gisel et al., 2000; Morris & Klein, 2000). In the typical pattern of development, the tongue first moves liquids through a nipple in an anterior/posterior (in/out) pattern (i.e., suckling); and then liquids and pureed foods with a superior/inferior (up/down) pattern (i.e., sucking; Ayano, Tamuro, Ohtsuka, & Mukai, 2000; Tamura, Matsushita, Shinoda, & Yoshida, 1998). The tongue moves chewable foods with a lateral (side to side) pattern over to the molar surface and back to the center, splitting and separating the food until it is ground down enough and recollected to swallow (Ayano et al., 2000). As the child's oral motor function advances, s/he learns to stabilize the jaw, working the tongue off this stable base first centrally with sucking and then laterally with munching (Meyer, 2000; Morris & Klein, 2000). Range of movement increases to allow sweeping anteriorly, posteriorly, laterally, and with tongue tip elevation.

In summary, the child's feeding experience and practice directly influence oral-motor pattern and oral-motor pattern directly influences feeding response (Bosma, 1986). If the utensils or food taste and

texture do not change, the child does not learn to accept new foods and does not practice the new patterns necessary to manipulate the new food and transport it through the pharynx safely and efficiently (Gisel et al., 2000). Lack of appropriate and successful practice may result in the loss of previously acquired oral-motor skills and/or failure to acquire more advanced skills.

Factors Influencing Oral-Motor Skills

In addition to appropriate and successful practice, other factors can also negatively influence oral-motor skill development. Feeding and swallowing movements and behaviors are very complex and clearly involve much more than just activities in the mouth, throat, and stomach (Gisel, Birnbaum, & Schwartz, 1998). The sensory motor systems provide both the structural foundation and the sensory information that enable a child to practice and master oral-motor skills (Morris & Klein, 2000). Because the dynamic feeding process involves internal activities such as breathing, digestion, and elimination; structural alignment, control and sensory input are important from top to bottom.

Structural Alignment

In the clinical feeding lore, there is an old adage, “If you want the lips, you must first get the hips,” meaning that support for function in the mouth comes from structures below (Morris & Klein, 2000). Biomechanical alignment means that structures of the body are aligned to allow the most efficient muscular interaction. For example, when the pelvis is in a neutral position, the structures of the spine line up biomechanically. A neutral position of the pelvis not only makes sitting up straight much easier, but also provides the spinal alignment and base of support for the rib cage, shoulder girdle, and head position. Figure 1 depicts a typical head-forward position resulting from loss of the biomechanical alignment of the spine that in turn results in poor head-shoulder-trunk alignment. In the head-forward position, the tongue and jaw muscles are helping to stabilize the child’s neck. As a result, the jaw is depressed and food and liquid are often lost during meals because the tongue and jaw are not able to move as freely for oral-motor function compared to a head in a neutral position (Patrick & Gisel, 1990). Several studies have demonstrated that proper biomechanical alignment is associated with improved swallowing, feeding and speech functioning (Gisel, Schwartz, Petryk, Clarke, & Haberfellner, 2000; Hulme, Gallacher, Walsh, Niesen, & Waldron, 1987; Kumin & Bahr, 1999; Larnert & Ekberg, 1995).




Figure 1. Typical head-forward position that results from poor head-shoulder-trunk alignment

Biomechanical alignment becomes even more important when we consider that many muscle groups cross multiple joints and can work together or in competition with one another to adapt and complete a desired task (Howle, 2002). For example, muscles of the neck can function in several ways: 1) as respiratory muscles to assist with breathing, 2) as swallowing muscles, and 3) as postural muscles to help maintain head and neck alignment. These muscle groups learn to work together to maintain all of these functions (McFarland, Lund, & Gagner, 1994; Palmer & Hiemae, 2003). However, when life-sustaining activities, such as breathing, become more difficult, muscles will be recruited from other functions to complete the desired task. For example, when breathing is challenged, muscles of the neck are automatically recruited to help, impacting head alignment and swallowing control. In this situation, less efficient or “compensatory” motor patterns develop. If these compensatory motor patterns persist, skill refinement will be difficult and lack of mastery will result in persistent immature oral-motor patterns (Macie & Arvedson, 1993; Pinder & Faherty, 1999).

Sensory Motor Input

The motor and sensory systems work together in an exchange that creates proactive and reactive responses to sensory input from the environment (e.g., tactile, kinesthesia and proprioceptive cues) and internal sensory information from the body (e.g., arousal, hunger, satiety, pain, fatigue, “lump in the throat”, or the need to stool). When used in combination, the child is able to generate an appropriate response for the desired task, resulting in positive practice. Integrated sensory information is essential for developing motor planning skills that incorporate both motor control and motor learning (Roley, Blanche, & Schaaf, 2001). All of these factors must work in a coordinated process for the child to receive positive feedback from safe oral motor and swallowing skill development. This positive feedback provides information to help the child develop the internal desire that will enable the child to develop self-generating progress towards mastery of feeding and swallowing skills.

Muscle Tone & Oral-Motor Patterns

Low muscle tone in the facial muscle can result in an open mouth posture. Because stability of the jaw allows the tongue to dissociate movement patterns within the mouth, this open lax jaw precludes dissociation resulting in an immature anterior/posterior pattern in which the tongue and jaw move together. Moreover, wide jaw excursions decrease the ability to manipulate food within the oral cavity increasing the possibility of food falling out of the mouth or failure to chew smaller pieces of food due to the inability to grade movement. Because their tongue moves in and out, as opposed to side to side, these children are not exhibiting the oral-motor pattern that would enable them to adequately chew foods. The lips and cheeks work together providing enough tension within the mouth to contain the food and with the lips provide negative pressure to begin the swallowing process. If the lip and cheek muscles become shortened through compensatory motor movements and/or lack of practice, they will not be able to attain full muscle length required for lip closure. Therefore, tonal and muscle imbalance of these structures can leave the lips in an open position. This can result in losing food anteriorly or the inability to contain the food while manipulating it (Alper, & Manno, 1996; Ernsperger, & Hanson, 2004). The resulting pattern appears as though the child is pushing food out the front of the mouth, such as the oral-motor pattern that is typical of many children with Down Syndrome (Kumin & Bahr, 1999).

Medical Influence on Oral-Motor Patterns

Although any medical illness, if severe enough, can interrupt successful practice with feeding and contribute to development of a feeding problem, the two most common medical issues that interfere with feeding are respiratory and gastrointestinal (Eicher, 2002). Sensory inputs from the respiratory and gastrointestinal tracts directly influence oral motor patterns through the swallowing center in the brainstem (Miller, 1986). Because the upper respiratory tracts use the same structures as the upper

digestive tracts (i.e., back of the mouth, and throat), breathing is neurologically programmed to supercede feeding (Daniels, Devlieger, Minami, Eggermont & Casaer, 1990). Any respiratory illness that makes breathing more difficult will negatively impact feeding and swallowing. For example, a child with asthma whose rate of breathing is increased may drool and refuse to swallow because the increased respiratory rate does not allow enough time for swallowing between breaths (Timms, DeFiore, Marin, & Miller, 1993).

Recent research is beginning to document the impact of respiratory problems on the feeding and growth of preterm children (Lau, Smith, & Schanler, 2003). Although full-term and preterm infants did not demonstrate significant differences in feeding difficulties at their first oral feeding, by the time solid foods were introduced, preterm children were more likely to demonstrate feeding difficulties (Burklow, McGrath, Valerius, & Rudolph, 2002). Regression analysis indicated that medical factors, especially breathing assistance, accounted for more of the variance in feeding difficulties than preterm status alone. However, pacing the bottle feedings in a sample of preterm infants with respiratory diagnoses resulted in the development of more efficient sucking patterns, increased weight gain, decreased incidence of bradycardia during feeding and shorter hospital stays compared to infants bottle-fed traditionally (Law-Morstatt, Judd, Snyder, Baier, & Dhanireddy, 2003).

In addition to respiratory issues, gastrointestinal issues can also influence oral-motor functioning (Henderson, Woolf, & Marryatt, 1976; Hyman, 1993; Sivit, Curtis, Crain, Cruess, & Winters, 1988). Frequent nausea, fullness from constipation, delayed emptying, or discomfort from gastroesophageal reflux or other irritants reduce the child's interest in eating as well as impacting the timing and degree of contraction of the muscle pattern required to complete the swallowing process (Mendell & Logemann, 2002; Waring, Feiler, Hunter, Smith, & Gold, 2002). As a result, the child becomes more protective of the airway and mouth; s/he may pull the tongue up or back to minimize entry into the mouth, and tongue movement is restricted (Mendell & Logemann, 2002). These changes may result in the use of more immature tongue movement patterns, less efficient tongue transport, and increased residual after the swallow (Mendell & Logemann, 2002). This can lead to preference for purees and foods that do not require increased tongue manipulation.

Case Illustration

When a child presents with a feeding problem, a comprehensive assessment needs to evaluate what oral motor pattern the child is using, and also what factors (medical, motor or learned patterns of behavior) are contributing to maintain the child's use of that pattern. Let's return to the example of Joey. Joey's first symptoms of a feeding problem occurred with the introduction of spoon feedings. Gagging and vomiting prevented him from successful practice with a spoon. At that point, gastrointestinal issues should have been considered as interfering with feeding development. However, his history of wanting to drink the bottle lying down suggests the possibility of sensorimotor issues also playing a role. Perhaps his low tone increased his difficulty with head control when upright, his perception of alignment or orientation in space, or impacted his respiratory efficiency. Each or all could have been contributing factors to his difficulty practicing spoon-feeding. Any child who is unable to initiate spoon-feeding after 3-4 months of practice should be evaluated. Because Joey vomited when the spoon touched his tongue, caretakers changed the food on the spoon to enable him to practice without putting the spoon in his mouth. With liquid soups, they could pour the "food" in without touching his tongue. Sensorimotor issues were not addressed, as he remained reclined in a bouncy seat. With practice he was able to transition to a couple of smooth baby foods. However, his pattern was not changing since he never really accepted the spoon into his mouth and on top of his tongue. Thus he continues to use an immature nipple pattern for spoon feedings because that is all he has practiced.

At this point, the oral-motor pattern Joey has practiced dictates what foods he will accept; they all have to be able to be transported like a liquid. Foods that do not flow like a liquid are refused resulting in his food refusal. He can't advance texture because he doesn't let pieces of food into his mouth, and doesn't have the tongue pattern necessary to manipulate them resulting in failure to advance texture. In addition, he has no experience eating in an upright position, which influences appropriate alignment and the muscle groups necessary to eat and swallow. Thus Joey now has multiple feeding problems resulting from medical and sensorimotor issues that initially prevented normal spoon practice. His lack of practice with normal patterns and increased experience with abnormal compensatory patterns in turn resulted in his food selectivity, failure to advance texture and ultimately food refusal.

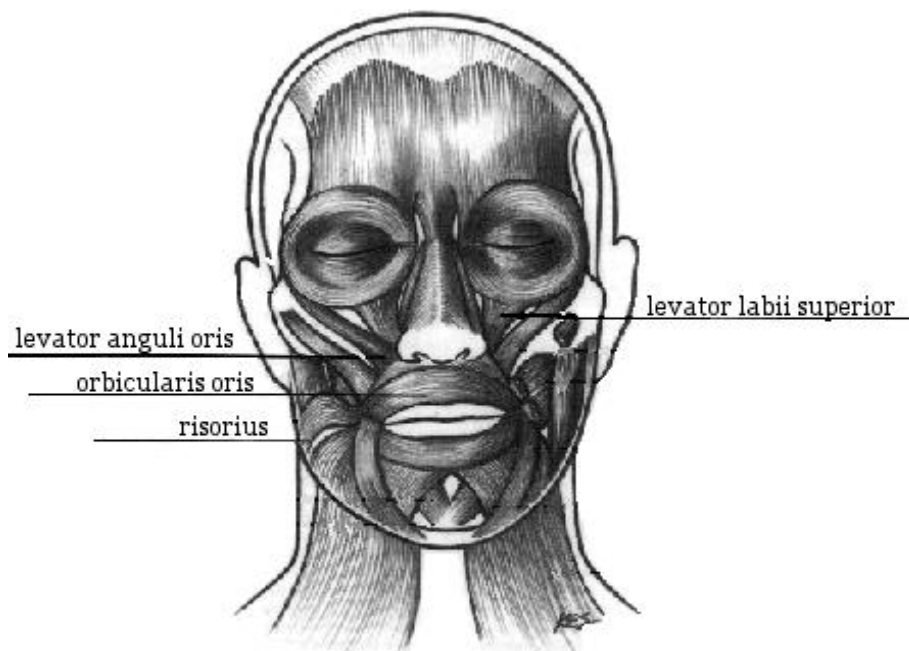
Treatment

Treatment is most successful when the history of the child's feeding progression is understood and a thorough assessment of the contributing factors has been done. Oral motor treatment should not start until medical issues are identified and controlled or stabilized, and issues of postural alignment and support have been addressed. To be most successful in providing oral motor stimulation, any medical issues need to be stable. This will help the child be more amenable to accepting any stimulation in the oral cavity and practice the oral-motor patterns that are needed. Since oral movements are refined motor movements, and they are distal to the pelvis and trunk, trunk alignment must be obtained to gain the best practice. Improving neck elongation and jaw stability will set the other oral structures in the correct alignment for active acceptance, manipulation and transport of food through the pharynx.

Oral stimulation should be viewed as preparation for eating; therefore, oral-motor practice with food should follow oral stimulation so that the movements facilitated during oral stimulation can be coordinated to practice food manipulation, transport and swallow. In other words, oral stimulation is a means to an end, and should not typically be done in isolation. Oral stimulation is typically begun periorally (i.e., outside the oral cavity) then transitioned to intraoral facilitation (e.g., Rendón-Macías, et al., 1999). More detailed descriptions and illustrations are contained in Alper and Manno (1996), DeGangi (1994), Gisel et al. (1998), Palmer and Heyman (1993) and Morris and Klein (2000).

Specific Oral-Motor Techniques

Facial/Oral Muscle Tone. If there are facial muscle tone issues, the use of tapping, pressure, vibration and speed of input can change tone (Morris & Klein, 2000). Figure 2 depicts a diagram of the facial muscles. Fast tapping, light touch, vibration and a fast pace alerts the system and can increase tone while slow tapping, deep pressure, vibration and a slowed pace tends to decrease tone. When the facial muscles are shortened or inactive, such as in children who are defensive about foods and utensils entering the mouth, stretching these muscles will improve the muscle length to enable a more mature movement patterns. For example, many children who refuse food will hold the upper lip in retraction showing their top teeth. The lips are in extension and there is tension throughout the face. In this position the child will not be able to use the upper lip actively to remove food from a spoon, drink from a cup without spillage, or place the tongue behind the teeth to receive the food. When the labial elevator muscles (i.e., levator labii superior, levator anguli oris and risorius) are stretched downward throughout the entire muscle, the upper lip can become more active.



Muscles of Facial Expression

Palmer, J. (1993) *Anatomy for Speech and Hearing*. (4th ed.),
Williams & Wilkins: Baltimore, MD.

Figure 2. Diagram of facial muscles

Stimulation of the orbicularis oris muscle improves flexion of the lips for mouth closure and puckering. Active use of this muscle assists in food containment, straw drinking and closure to provide the negative pressure necessary for transporting food through the oral cavity and swallowing. Active closure of the lips is needed to attain a single bolus swallow as opposed to a sequential swallow (i.e., multiple swallows in a row on a single bolus). Sequential swallowing is typical in children who are not transitioning to higher textured foods or who transport their food to the back of the mouth to swallow. This existing oral-motor pattern may be functional (i.e., the child successfully gets the food into the esophagus); however, prolonged practice with this type of pattern limits the child's ability to advance to more mature oral-motor patterns.

Tongue & Transport. Stimulation to the tongue can be effective to change the movement of the tongue. Initially, implements (e.g., NUK, Ark probe) can be utilized to facilitate these movements. Then, modifying the method used to present the spoon with food and/or presenting small amounts of meltable foods (e.g., cheerio, cheese puffs) should be introduced to all the children to practice the new tongue movements with food.

When a child presents with a midline pattern (i.e., the tongue moves in and out with little side to side motion), s/he will not be able to efficiently chew and swallow a variety of foods. He may not be able to move the food laterally to the molars to grind down the food in preparation for swallowing. This will lead to the child learning to swallow foods whole or partially chewed. If the tongue movements are not altered, the child will continue to practice this less efficient movement and will not be able to advance to higher textured foods. The use of pressure on the middle of the tongue or the lateral sides of the tongue can facilitate the intrinsic and extrinsic lingual muscles to widen, thin out, narrow, elongate and flatten. Pressure on the lateral borders of the tongue can thin out the muscle and the tongue will move to that side. Stimulation to the anterior part of the tongue will facilitate a tongue tip. This serves to facilitate movement, increase acceptance of tactile sensation and acceptance of implements in the mouth.

Doing oral stimulation techniques alone provides sensation and movement but typically does not translate into accepting foods. Once the movement is active, food must be presented to use the pattern. For children who don't accept foods other than purees, the lateral movement pattern can be practiced by placing purees over the molar surface so that the tongue will shift to either side of the mouth to accept the food, and then to transport the food to the back of the mouth in preparation for a swallow. Foods such as lollipops or lifesavers on a string can be presented to the child to practice moving the tongue from midline, to side and across midline so that the tongue practices moving food within the oral cavity. The meltable foods, such as cereals, can be placed over the molar surface for the tongue to get and then move over to the other molar for several sequences before softening, chewing and swallowing. As the child becomes more facile with this technique, foods are added into meals to practice these patterns for entire meals or for therapeutic meals.

Swallowing. Shifting from a sequential swallowing pattern to a single bolus swallow in spoon-feeding can be practiced using the spoon. Many therapists are taught to use Nuk brushes and other similar implements to present tastes and foods to children that refuse foods. Since we use a spoon to eat with, practicing the oral-motor pattern needed with the appropriate utensil will lead to more efficient learning.

To facilitate a single bolus swallow, the entire bowl of a dry spoon can be placed on the tongue applying downward pressure to encourage the tongue to make a bowl then move back to initiate a swallow. If the child does not close his lips around the spoon, he is asked to and/or his lips are closed around the spoon to learn the correct sequence (Chigira, Omoto, Mukai, & Kaneko, 1994). All presentations of the spoon should be done with the child's head in a neutral position and with him facing forward. Since there is no food on the spoon and no threat of aspiration, he is learning the correct sequence of movement for a single bolus swallow in a safe manner using the utensil that is used for feeding. As he becomes more proficient with this pattern, a small amount of food is placed on the spoon. The amount of food on the spoon is increased gradually until he can accept a level spoonful of food while always ensuring that he is continuing to exhibit the appropriate oral-motor pattern.

Grading Jaw Movement. Some children have difficulty grading the amount of mouth opening and closing needed for a variety of foods. When a child demonstrates wide jaw excursions, he will have difficulty using his tongue to manage the food. Providing jaw stability by placing your hand under the jaw will help the child to take bites and to keep the mouth closed while the tongue does the work of manipulating the food. As the child practices, thinner foods can be placed between the molars to chew using minimal jaw excursions.

Empirical Support for Oral Stimulation and Oral-Motor Therapy

Oral-Motor Therapy

While the majority of published studies report on the efficacy of oral-motor therapy for high-risk infants born prematurely or children with neuromotor difficulties, a few case studies suggest the promising use of oral-motor treatment techniques for children with low muscle tone (Kumin, Von Hagel, & Bahr, 2001) and retardation/autism (Larrington, 1987).

High-Risk Infants. Sensorimotor interventions (e.g., proper positioning and external support of the cheeks and mandible during bottle feeding) improve oral feeding of preterm infants (Case-Smith, 1988; Einarsson-Backes, Deitz, Price, Glass, & Hays, 1994). Using a two-group design, Gaebler and Hanzlik (1996) compared 5 minutes of pre-feeding stroking to 5 minutes of pre-feeding stroking and introral prefeeding stimulation in a sample of 18 premature infants. Assessments occurred on days 1, 3 and 5; the group that received oral stimulation fed significantly better than the control group on day 3 only. A more recent study has demonstrated that those preterm infants who received daily 15-minute oral

stimulation program consisting of stroking the peri- and intraoral structures for 10 days before the start of oral feedings, achieved full oral feedings seven days sooner than the infants in the control group (Fucile, Gisel, & Lau, 2005). In addition, infants in the experimental group demonstrated greater overall intake, rate of milk transfer, and amplitude of the expression component of sucking. In contrast, there were no differences between experimental and control infants on sucking stage maturation, sucking frequency, amplitude of the suction component of sucking or endurance of sucking.

Children with Neuromotor Disorders. An elegant series of studies investigating sensorimotor intervention on eating skills of children with cerebral palsy (average age ~ 5 years) has been conducted by Gisel and colleagues (Gisel, 1994; Gisel, Applegate-Ferrante, Benson, & Bosma, 1995, 1996). Oral-motor therapy, which was designed to increase tongue lateralization, lip control, and vigor of chewing, was delivered before the lunch meal for 5-7 minutes/day, 5 days/week for 10-20 weeks. Using a between subject experimental design, children's spoon feeding, biting, and chewing improved with oral-motor therapy (Gisel, 1994). Using a within-subject design, spoon feeding, chewing, and swallowing improved after oral-motor therapy (Gisel et al., 1996). In addition, more children advanced food texture with oral-motor therapy (Gisel et al., 1995). One interesting finding was the discovery that eating efficiency (i.e., meal duration) was not a good outcome measure but rather is a diagnostic indicator of the severity of the feeding impairment.

A relatively new type of intervention for oral-motor difficulties in children with neuromotor impairments is an intraoral appliance, Innsbruck Sensorimotor Activator and Regulator (ISMAR; Gisel, Schwartz, & Haberfellner, 1999). The ISMAR was designed to achieve two goals: 1) jaw stabilization, and 2) activation/mobilization of the oral and pharyngeal structures. Although there were some difficulties in achieving tolerance and compliance with ISMAR (see Johnson et al., 2004), children with neuromotor disorders demonstrate significant improvements in spoon-feeding, biting, chewing, cup drinking, swallowing, and drooling after one year of ISMAR (Haberfellner, Schwartz, & Gisel, 2001; Johnson et al., 2004). These functional changes in feeding skills appear to be a function of jaw stabilization. Furthermore, these improvements in feeding were maintained for one year after ISMAR therapy was stopped (Gisel, Haberfellner, & Schwartz, 2001). Finally, use of ISMAR was associated with significant improvements in sitting and ambulation providing preliminary evidence for the dynamic interplay among oral-motor, postural, and ambulatory functions (Gisel et al., 2000).

Behavioral Interventions Targeting Oral-Motor Problems

Within the field of applied behavior analysis, several researchers have designed interventions using behavioral principles to improve specific oral-motor problems, such as swallowing dysfunction (Hagopian, Farrell, & Amari, 1996; Hoch, Babbitt, Coe, Duncan, & Trusty, 1995; Lamm & Greer, 1988), cup drinking (Patel, Piazza, Kelly, Ochsner, & Santana, 2001), and failure to advance texture (Luiselli & Gleason, 1987; Shore, Babbitt, Williams, Coe, & Snyder, 1998). The hallmark of all these interventions is 1) analyzing the "task" into small, discrete steps, 2) manipulating the antecedent condition by presenting food or liquid in a way that allows the child to complete the behavior expected successfully, and 3) clear consequences for completing or not completing the task. For example, in the swallowing induction procedures, swallowing was broken down into its component steps from food entering the mouth to the initiation of the swallowing reflex at the faucal arches. The researchers used forward or backward chaining with prompts (verbal and physical prompts on the tongue) to initiate swallowing. Although the data suggest that the intervention is promising (Kerwin, 1999), the technique assumes competent oral-motor tongue and jaw movements. Although the children had increased swallow frequency, increased food acceptance and increased quantity of food consumed orally, it is unclear from the study results if the oral-motor pattern acquired indirectly would allow the child to continue advancing oral-motor skills with other food textures. The current research literature suggests that a more expedient intervention might be direct targeting of the oral-motor movements.

Combined Use of Oral-Motor Therapy and Behavioral Techniques

Successful eating requires effective oral-motor patterns. The behavior analyst can be instrumental in assisting members of other disciplines in teaching children these skills. Because behavior analysts are skilled in task analyses, they can also help members of the other disciplines task analyze their interventions and learn to look for and document specific responses that they expect from each procedure (see Kumin et al., 2001 for example of task analysis of oral-motor treatment). Perhaps an ideal avenue for future investigation is combining the best of both approaches together to maximize the child's benefit from systematic, gradual steps with clear instruction and consequences in the context of meaningful oral-motor facilitation and therapy (Bailey & Angell, 2005). Peterson and Ottenbacher (1986) demonstrated this combined approach in teaching lip closure to three children with mental retardation.

Conclusion

Children requiring early, intensive intervention often have complex feeding and swallowing issues that requires a team approach in order to fully evaluate and treat the underlying issues. Low tone, abnormal sensory processing, altered postural alignment and movement patterns are often present in these populations. These issues place them at risk for having abnormal postural alignment of the pelvis, trunk, shoulder girdle, which leads to a forward head posture. This alters the biomechanics of breathing and swallowing and the corresponding sensory input. With altered sensory perception the child may have difficulty motor planning postural alignment and control for acquisition and mastery of feeding and swallowing behaviors. Once medical stability and postural alignment have been obtained, oral stimulation can be an effective adjunct to feeding treatment. Oral stimulation should provide the child with the necessary sensory and movement input to adequately prepare the child for controlled practice with food. The use of varying foods in multiple therapeutic practice situations a day is the key to increasing the frequency of positive practice and thus increasing the acceptance of variety and volume of foods consumed in children exhibiting oral-motor difficulties.

References

- Alper, B. S., & Manno, C. J. (1996). Dysphagia in infants and children with oral-motor deficits: Assessment and management. *Seminars in Speech and Language, 17*, 283-310.
- Amato, J., & Slavin, D. (1998). A preliminary investigation of oromotor function in young verbal and nonverbal children with autism. *Infant Toddler Investigation: The Transdisciplinary Journal, 8*, 175-184.
- Arvedson, J. C., & Lefton-Greif, M. A. (1996). Anatomy, physiology and development of feeding. *Seminars in Speech and Language, 17*, 261-268.
- Ayano, R., Tamura, F., Ohtsuka, Y., & Mukai, Y. (2000). The development of normal feeding and swallowing: Showa University study of feeding function. *International Journal of Orofacial Myology, 26*, 24-32.
- Bailey, R. L., & Angell, M. E. (2005). Improving feeding skills and mealtime behaviors in children with disabilities. *Education and Training in Developmental Disabilities, 40*, 80-96.
- Bosma, J. F. (1986). Development of feeding. *Clinical Nutrition, 5*, 210-218.

- Burklow, K. A., McGrath, A. M., Valerius, K. S., & Rudolph, C. (2002). Relationship between feeding difficulties, medical complexity, and gestational age. *Nutrition in Clinical Practice, 17*, 373-378.
- Case-Smith, J. (1988). An efficacy study of occupational therapy with high-risk neonates. *The American Journal of Occupational Therapy, 42*, 499-506.
- Chigira, A., Omoo, K., Mukai, Y., & Kaneko, Y. (1994). Lip closing pressure in disabled children: A comparison with normal children. *Dysphagia, 9*, 193-198.
- Daniels, H., Devlieger, H., Minami, T., Eggermont, E., & Casaer, P. (1990). Infant feeding and cardiorespiratory maturation. *Neuropediatrics, 21*, 9-10.
- DeGangi, G. A. (1994). Examining the efficacy of short-term NDT intervention using a case study design: Part 2. *Physical and Occupational Therapy in Pediatrics, 14*, 21-61.
- Eicher, P.S. (2002). Feeding. In M.L. Batshaw (Ed.), *Children with disabilities* (pp. 549-566). Baltimore: Paul H. Brookes Publishing Co.
- Einarsson-Backes, L. M., Deitz, J., Price, R., Glass, R., & Hays, R. (1994). The effect of oral support on sucking efficiency in preterm infants. *American Journal of Occupational Therapy, 48*, 490-498.
- Ernsperger, L., & Hanson, T. (2004). *Motor-Based Eating Problems vs. Sensory-Based Eating Problems in Just Take a Bite*. Arlington, TX: Future Horizons Inc.
- Fucile, S., Gisel, E. G., & Lau, C. (2005). Effect of an oral stimulation program on sucking skill maturation of preterm infants. *Developmental Medicine and Child Neurology, 47*, 158-162.
- Gaebler, C. P., & Hanzlik, J. R. (1996). The effects of a prefeeding stimulation program on preterm infants. *American Journal of Occupational Therapy, 50*, 184-192.
- Gisel, E. G. (1994). Oral-motor skills following sensorimotor intervention in the moderately eating-impaired child with cerebral palsy. *Dysphagia, 9*, 180-192.
- Gisel, E. G., Alphonse, E., & Ramsay, M. (2000). Assessment of ingestive and oral praxis skills: Children with cerebral palsy vs. controls. *Dysphagia, 15*, 236-244.
- Gisel, E. G., Applegate-Ferrante, T., Benson, J. E., & Bosma, J. F. (1995). Effect of oral sensorimotor treatment on measures of growth, eating efficiency, and aspiration in the dysphagic child with cerebral palsy. *Developmental Medicine and Child Neurology, 37*, 528-543.
- Gisel, E. G., Applegate-Ferrante, T., Benson, J. E., & Bosma, J. F. (1996). Oral-motor skills following sensorimotor therapy in two groups of moderately dysphagic children with cerebral palsy: Aspiration vs. nonaspiration. *Dysphagia, 11*, 59-71.
- Gisel, E. G., Birnbaum, R., & Schwartz, S. (1998). Feeding impairments in children: Diagnosis and effective intervention. *The International Journal of Orofacial Myology, 24*, 27-33.
- Gisel, E. G., Haberfellner, H., & Schwartz, S. (1999). The Innsbruck Sensorimotor Activator and Regulator (ISMAR): Construction of an intraoral appliance to facilitate ingestive function. *Journal of Dentistry for Children, 66*, 180-187.

- Gisel, E. G., Haberfellner, H., & Schwartz, S. (2001). Impact of oral appliance therapy: Are oral skills and growth maintained one year after termination of therapy? *Dysphagia*, *16*, 296-307.
- Gisel, E. G., Schwartz, S., Petryk, A., Clarke, D., & Haberfellner, H. (2000). "Whole body" mobility after one year of intraoral appliance therapy in children with cerebral palsy and moderate eating impairment. *Dysphagia*, *15*, 226-235.
- Haberfellner, H., Schwartz, S., & Gisel, E. G. (2001). Feeding skills and growth after one year of intraoral appliance therapy in moderately dysphagic children with cerebral palsy. *Dysphagia*, *16*, 1-14.
- Hagopian, L. P., Farrell, D. A., & Amari, A. (1996). Treating total liquid refusal with backward chaining and fading. *Journal of Applied Behavior Analysis*, *29*, 573-575.
- Henderson, R. D., Woolf, C., & Marryatt, G. (1976). Pharyngoesophageal dysphagia and gastroesophageal reflux. *Laryngoscope*, *86*, 1531-1539.
- Herbst, J. J. (1983). Development of suck and swallow. *Journal of Pediatric Gastroenterology & Nutrition*, *2 Supplement 1*, S131-S135.
- Hoch, T. A., Babbitt, R. A., Coe, D. A., Ducan, A., & Trusty, E. M. (1995). A swallow induction avoidance procedure to establish eating. *Journal of Behavior Therapy and Experimental Psychiatry*, *26*, 41-50.
- Howle, J.M. (2003). *Neuro-Developmental Treatment Approach: Theoretical Foundations and Principles of Clinical Practice*. Neurodevelopmental Treatment Association, Laguna Beach: California, Canada.
- Hulme, J. B., Gallacher, K., Walsh, J., Niesen, S., & Waldron, D. (1987). Behavioral and postural changes observed with use of adaptive seating by clients with multiple handicaps. *Physical Therapy*, *67*, 1060-1067.
- Hyman, P. (1993). Gastroesophageal reflux: One reason why baby won't eat. *The Journal of Pediatrics*, *125*, S103-S109.
- Illingworth, R. S. & Lister, J. (1964). The critical or sensitive period, with special reference to certain feeding problems in infants and children. *Journal of Pediatrics*, *65*, 839-848.
- Ingram, T. T. (1962). Clinical significance of the infantile feeding reflexes. *Developmental Medicine and Child Neurology*, *4*, 159-169.
- Johnson, H. M., Reid, S. M., Hazard, C. J., Lucas, J. O., Desai, M., & Reddihough, D. S. (2004). Effectiveness of Innsbruck Sensorimotor Activator and Regulator in improving saliva control in children with cerebral palsy. *Developmental Medicine and Child Neurology*, *46*, 39-45.
- Kerwin, M. L. (1999). Empirically supported treatments in pediatric psychology: Severe feeding problems. *Journal of Pediatric Psychology*, *24*, 193-214.
- Kerwin, M.L.E. (2003). Pediatric Feeding Disorders. *The Behavior Analyst Today*, *4*, 160-174. Retrieved from <http://www.behavior-analyst-online.org/NEWBAT/Frameless%20BAT/BAT-4.2-7-23-03-C.PDF>.

- Kerwin, M. L. E., & Eicher, P. S. (2004). Behavioral interventions and prevention of feeding difficulties in infants and children. *Journal of Early Intensive Behavioral Intervention, 1*, 129-140.
- Kumin, L., & Bahr, D. C. (1999). Patterns of feeding, eating, and drinking in young children with Down Syndrome with oral motor concerns. *Down Syndrome Quarterly, 4*, 1-8.
- Kumin, L., Von Hagel, K. C., & Bahr, D. C. (2000). An effective oral motor intervention protocol for infants and toddlers with low muscle tone. *Infant-Toddler Intervention, 11*, 181-200.
- Lamm, N., & Greer, R. D. (1988). Induction and maintenance of swallowing responses in infants with dysphagia. *Journal of Applied Behavior Analysis, 21*, 143-156.
- Lanert, G., & Ekberg, O. (1995). Positioning improves the oral and pharyngeal swallowing function in children with cerebral palsy. *Acta Paediatrica, 84*, 689-692.
- Larrington, G. G. (1987). A sensory integration based program with a severely retarded/autistic teenager: An occupational therapy case report. *Sensory Integrative Approaches in Occupational Therapy, 4*, 101-117.
- Lau, C., & Hurst, N. (1999). Oral feeding in infants. *Current Problems in Pediatrics, 29*, 105-124.
- Lau, C., Smith, E. O., & Schanler, R. J. (2003). Coordination of suck-swallow and swallow respiration in preterm infants. *Acta Paediatrica, 92*, 721-727.
- Law-Morstatt, L., Judd, D. M., Snyder, P., Baier, J. J., & Dhanireddy, R. (2003). Pacing as a treatment technique for transitional sucking patterns. *Journal of Perinatology, 23*, 483-488.
- Luiselli, J. K., & Gleason, D. J. (1987). Combining sensory reinforcement and texture fading procedures to overcome chronic food refusal. *Journal of Behavior Therapy and Experimental Psychiatry, 18*, 149-155.
- Macie, D., & Arvedson, J.C. (1993). Tone and positioning. In J. C. Arvedson & L. Brodsky (Eds.), *Pediatric Swallowing and Feeding: Assessment & Management* (pp. 209-247). San Diego, CA: Singular Publishing Group, Inc.
- McFarland, D. H., Lund, J. P., & Gagner, M. (1994). Effects of posture on the coordination of respiration and swallowing. *Journal of Neurophysiology, 74*, 2431-2437.
- Mendell, D. A., & Logemann, J. A. (2002). A retrospective analysis of the pharyngeal swallow in patients with a clinical diagnosis of GERD compared with normal controls: A pilot study. *Dysphagia, 17*, 220-226.
- Meyer, P. G. (2000). Tongue lip and jaw differentiation and its relationship to orofacial myofunctional treatment. *International Journal of Orofacial Myology, 26*, 44-52.
- Miller, A. J. (1986). Neurophysiological basis of swallowing. *Dysphagia, 1*, 90-100.
- Miller, A. J. (1993). The search for the central swallowing pathway: The quest for clarity. *Dysphagia, 8*, 185-194.

- Morris, S. E., & Klein, M. D. (2000). *Pre-Feeding Skills: A comprehensive resource for mealtime development* (2nd ed.). Tucson, Arizona: Therapy Skill Builders.
- Ogg, H. L. (1975). Oral-pharyngeal development and evaluation. *Physical Therapy, 55*, 235-241.
- Palmer, M. M., & Heyman, M. B. (1993). Assessment and treatment of sensory- versus motor-based feeding problems in very young children. *Infants and Young Children, 6*, 67-73.
- Palmer, J. B., & Hiimae, K. M. (2003). Eating and breathing: Interactions between respiration and feeding on solid food. *Dysphagia, 18*, 169-178.
- Palmer, S., & Horn, S. (1977). Feeding problems in children. In S. Palmer & S. Ekvall (Eds.), *Pediatric Nutrition in Developmental Disorders*. Springfield, IL: Charles C. Thomas.
- Patel, M. R., Piazza, C. C., Kelly, M. L., Ochsner, C. A., & Santana, C. M. (2001). Using a fading procedure to increase fluid consumption in a child with feeding problems. *Journal of Applied Behavior Analysis, 34*, 357-360.
- Patrick, J., & Gisel, E. G. (1990). Nutrition for feeding impaired child. *Journal of Neurologic Rehabilitation, 4*, 115-119.
- Petersen, P., & Ottenbacher, K. (1986). Use of applied behavioral techniques and an adaptive device to teach lip closure to severely handicapped children. *American Journal of Mental Deficiency, 90*, 535-539.
- Pinder, G. L., & Faherty, A. S. (1999). Issues in pediatric feeding and swallowing. In A. Caruso & E. A. Strand (Eds.), *Clinical Management of Motor Speech Disorders in Children* (pp. 281-318). New York, NY: Thieme Medical Publishers.
- Pinnington, L., & Hegarty, J. (2000). Effects of consistent food presentation on oral-motor skill acquisition in children with severe neurological impairment. *Dysphagia, 15*, 213-223.
- Ramsay, M., Gisel, E. G., McCusker, J., Bellavance, F., & Platt, R. (2002). Infant sucking ability, non-organic failure to thrive, maternal characteristics, and feeding practices: A prospective cohort study. *Developmental Medicine and Child Neurology, 44*, 405-414.
- Reilly, S. M., Skuse, D. H., Wolke, D., & Stevenson, J. (1999). Oral-motor dysfunction in children who fail to thrive: Organic or non-organic? *Developmental Medicine and Child Neurology, 41*, 115-122.
- Rendón-Macías, M. E., Cruz-Perez, L. A., Mosco-Peralta, M. R., Saraiba-Russell, M. M., Levi-Tajfeld, S., & Morales-López, M. G. (1999). Assessment of sensorial oral stimulation in infants with suck feeding disabilities. *Indian Journal of Pediatrics, 66*, 319-329.
- Roley, S.S., Blanche, E.I., & Schaaf, R.C. (2001). *Sensory Integration with Diverse Populations*. Tucson, Arizona: Therapy Skill Builders.
- Rudolph, C., & Link, D. T. (2002). Feeding disorders in infants and children. *Pediatric Clinics of North America: Pediatric Gastroenterology and Nutrition, 49*, 97-112.

- Shore, B. A., Babbitt, R. L., Williams, K. E., Coe, D. A., & Snyder, A. (1998). Use of texture fading in the treatment of food selectivity. *Journal of Applied Behavior Analysis, 31*, 621-633.
- Sivit, C. J., Curtis, D. J., Crain, M., Cruess, D. F., & Winters, C. (1988). Pharyngeal swallow in gastroesophageal reflux disease. *Dysphagia, 2*, 151-155.
- Smith, A., Weber, C. M., Newton, J., & Denny, M. (1991). Developmental and age-related changes in reflexes of the human jaw-closing system. *Electroencephalography and Clinical Neurophysiology, 81*, 118-128.
- Stevenson, R. D., & Allaire, J. H. (1991). The development of normal feeding and swallowing. *Pediatric Clinics of North America, 38*, 1439-1453.
- Sullivan, P. B., Lambert, B., Ford-Adams, M., Griffiths, P., & Johnson, A. (2000). Prevalence and severity of feeding and nutritional problems in children with neurological impairments: Oxford Feeding Study. *Developmental Medicine and Child Neurology, 42*, 674-680.
- Tamura, Y., Matsushita, S., Shinoda, K., & Yoshida, S. (1998). Development of perioral muscle activity during suckling in infants: A cross-sectional and follow-up study. *Developmental Medicine and Child Neurology, 40*, 344-348.
- Timms, B.J., DeFiore, J.M., Martin, R.J., & Miller, M. J. (1993). Increased respiratory drive as an inhibitor of oral feeding of preterm infants. *Journal of Pediatrics, 123*, 127-131.
- Waring, J.P., Feiler, M.J., Hunter, J.G., Smith, C.D., Gold, B.D. (2002). Childhood gastroesophageal reflux symptoms in adult patients. *Journal of Pediatric Gastroenterology and Nutrition, 35*, 334-338.

Authors' Note

Below are the affiliations of all authors on this article:

Cecilia J. Manno, *Speech-Language Pathology, Private Practice, Newtown, PA*

Catherine Fox, *Pediatric Occupational Therapy, Private Practice, Frederick, MD*

Peggy S. Eicher, *Center for Pediatric Feeding and Swallowing Disorders, St. Joseph's Hospital and Medical Center*

MaryLouise E. Kerwin, *Department of Psychology, Rowan University*

Correspondence concerning this article should be addressed to:

MaryLouise Kerwin
Department of Psychology
Rowan University
201 Mullica Hill Road
Glassboro, New Jersey 08028
E-mail: kerwin@rowan.edu