

2004

Histological Evaluation of the Cryo-Destruction of the Zona Glomerulosa (Outermost Layer) of the Adrenal Cortex

Huda Ahmed

Minnesota State University, Mankato

Jonida Pone

Minnesota State University, Mankato

Follow this and additional works at: <http://cornerstone.lib.mnsu.edu/jur>

 Part of the [Endocrine System Diseases Commons](#), and the [Medical Biochemistry Commons](#)

Recommended Citation

Ahmed, Huda and Pone, Jonida (2004) "Histological Evaluation of the Cryo-Destruction of the Zona Glomerulosa (Outermost Layer) of the Adrenal Cortex," *Journal of Undergraduate Research at Minnesota State University, Mankato*: Vol. 4, Article 1.

Available at: <http://cornerstone.lib.mnsu.edu/jur/vol4/iss1/1>

This Article is brought to you for free and open access by the Undergraduate Research Center at Cornerstone: A Collection of Scholarly and Creative Works for Minnesota State University, Mankato. It has been accepted for inclusion in Journal of Undergraduate Research at Minnesota State University, Mankato by an authorized administrator of Cornerstone: A Collection of Scholarly and Creative Works for Minnesota State University, Mankato.

Student Agreement:

I am submitting my research article to be published in the JUR (The Journal of Undergraduate Research at Minnesota State University, Mankato), an electronic journal of the Minnesota State University Undergraduate Research Center.

I/We certify have followed the accepted standards of scientific, creative, and academic honesty and ethics.

I understand that my article submission will be blind-reviewed by faculty reviewers who will recommend acceptance for publication; acceptance with revisions; or reject for publication.

I understand that as author, I retain the right to present any part of the research in any form in other publications.

The JUR has the right to reproduce and reprint published submissions for instructional or promotional purposes.

For complete details, see [*Journal of Undergraduate Research at Minnesota State University, Mankato policies page*](#).

Mentor Agreement:

I have reviewed the submission, and I support its inclusion in the JUR (The Journal of Undergraduate Research at Minnesota State University, Mankato). I understand that I will be acknowledged as the faculty mentor for the student author(s). To the best of my knowledge, the student has followed the accepted standards of scientific, creative, and academic honesty and ethics.

HISTOLOGICAL EVALUATION OF THE CRYO-DESTRUCTION OF THE ZONA GLOMERULOSA (OUTERMOST LAYER) OF THE ADRENAL CORTEX

Huda Ahmed (Biological Sciences)

Jonida Pone (Biological Sciences)

Penny Knoblich, Faculty Mentor (Biological Sciences)

ABSTRACT:

The outer portion, or cortex, of the adrenal gland produces three hormones, two of which are highly critical to normal function of the body. The cortex itself is divided into three layers, each responsible for a certain hormone synthesis. The outermost layer (zona glomerulosa) produces aldosterone, a hormone involved in the regulation of body sodium, blood volume, and blood pressure. The middle layer produces corticosterone, a hormone that is active in a variety of biological functions, and necessary for life. Due to its effects on blood volume, aldosterone has been implicated in the development of hypertension, or high blood pressure. Aldosterone has been studied through the use of receptor blocking agents, which are associated with undesirable side effects, and complete adrenalectomy (removal of both adrenal glands), which eliminates both aldosterone and corticosterone. The overall objective of the current study is to produce a surgically induced low aldosterone rat model, with functioning lower adrenal layers, by cryo-destruction of only the zona glomerulosa. The purpose of the present study was to perfect histological techniques for fixation, sectioning and staining of the adrenal glands, and to evaluate the success of the cryo-destruction. Adrenal glands were removed from rats 2, 4, and 8 weeks after cryo-destruction of the left adrenal zona glomerulosa. Glands were fixed in paraffin, sectioned, stained, and viewed under a microscope. Percent destruction of the outer layer of the adrenal cortex was estimated. Results: Techniques for fixing, sectioning, and staining of the adrenals glands was perfected by trial and error. The percent of the zona glomerulosa successfully destroyed by the cryo-treatment was highly variable between rats.

INTRODUCTION:

The adrenal gland, located above the kidneys, has an outer layer that secretes three hormones. This outer layer is called the adrenal cortex. The adrenal cortex it self has three layers; each layer is responsible for the production of one hormone. The outermost layer of the cortex, the zona glomerulosa, produces the hormone aldosterone. Aldosterone increases blood volume which in turn increases blood pressure. Because of these effects, aldosterone is thought to be responsible for hypertension also known as high blood pressure.

There had been many attempts made to study aldosterone and thus find out for sure whether or not it was responsible for the development of high blood pressure. These attempts, however, had shortcomings.

The main objective of this particular experiment was to destroy the outer layer of the cortex without destroying the other two layers. Our part in this experiment was to perfect a fixing, sectioning and staining technique that shows whether or not the destruction of the zona glomerulosa was successful .

METHODS:

Adrenals that were removed surgically from the rat were processed in 3 steps:

- 1- Paraffin Embedding
- 2-Tissue Sectioning
- 3-Staining

The paraffin embedding step prepares the tissue for cutting into sections so that it can be examined under a microscope.

Paraffin Embedding:

The adrenals were fixed in formalin for 2-3 days to preserve the cells and prevent post-mortem changes. The glands were then put through the following steps:

Repetition	Concentration (%)	Chemical	Time
1		Formalin	Overnight
2	0.10M	PO4	Wash
1	50	EtOH	15min
1	70	EtOH	15min
1	80	EtOH	15min
1	90	EtOH	15min
2	95	EtOH	15min
2	100	EtOH	15min
1	50/50	EtOH/Xylene	15min
2	100	Xylene	15min
1	50/50	Xylene/Paraffin	15min
1	100	Paraffin	30min
1	100	Paraffin	1hour

Paraffin Embedding (continued)

However, the above method did not result in complete paraffin infiltration of the tissues. After more trial and error, the following protocol was found to be most effective:

Repetitions	Concentrations%	Chemical	Time	Notes
1		Formalin	Overnight	
2	0.10M	PO4	Wash	
1	50	EtOH	15 min	
1	70	EtOH	1 hour	May stop overnight
1	80	EtOH	15 min	
1	90	EtOH	15 min	
2	95	EtOH	15 min	
2	100	EtOH	15 min	
1	50/50	EtOH/Xylene	15 min	
2	100	Xylene	15 min	Place in warmer
1	50/50	Xylene/Paraffin	1 hour	
1	100	Paraffin	1 hour	
1	100	Paraffin	2 hours	Can stop

Tissue Sectioning & Staining:

- 1-The water bath container was filled to 80% of its height, with double distilled H₂O (ddH₂O), and warmed to 45 – 50°C.
- 2-A microtome (Leica, Model RM2155) was set, by placing the blade in the blade holder and the sections thickness was set to 10 (µm). The wax block was then mounted onto the chuck holder. The wax block was trimmed above and below the embedded tissue.
- 3-The block was adjusted so that the surface of the wax block was parallel to the blade edge.
- 4-The blade base was adjusted by using the control handles on both sides of the blade.
- 5-The block/blade alignment was checked by slowly cutting the sections.
- 6-Sections were cut until the tissue plane was reached.
- 7-A sheet of Kimwipes was soaked in 100% ethanol, to clean the wax surface to facilitate sectioning.
- 8-Sections were cut with a steady and smooth movement.
- 9-Wax ribbons were then cut and carefully transferred to the surface of the water bath.
- 10-The sections were allowed to float on the water until they were fully extended, thus minimizing wrinkles in the sections.
- 11-SuperFrost/Plus (Fisher, Cat # 12-550-15) slides were used to pick up the floating sections from the water bath.
- 12-The slides were placed onto a baked slide rack, and were dried at least 2 hours.

After the slides were completely dry, the staining procedure was performed.

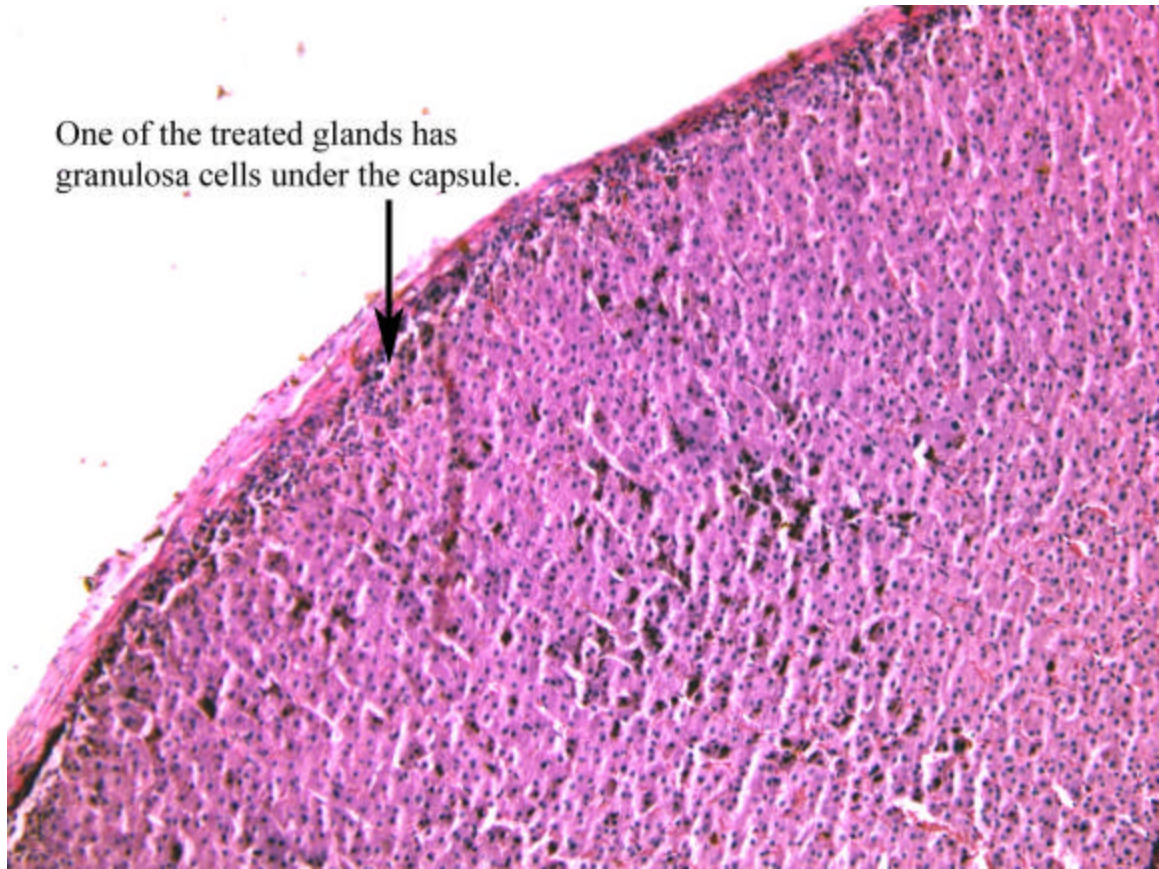
Tissue Staining:

It involved several steps. The boat containing the slides was placed in different solutions for various times (8sec - 10min):

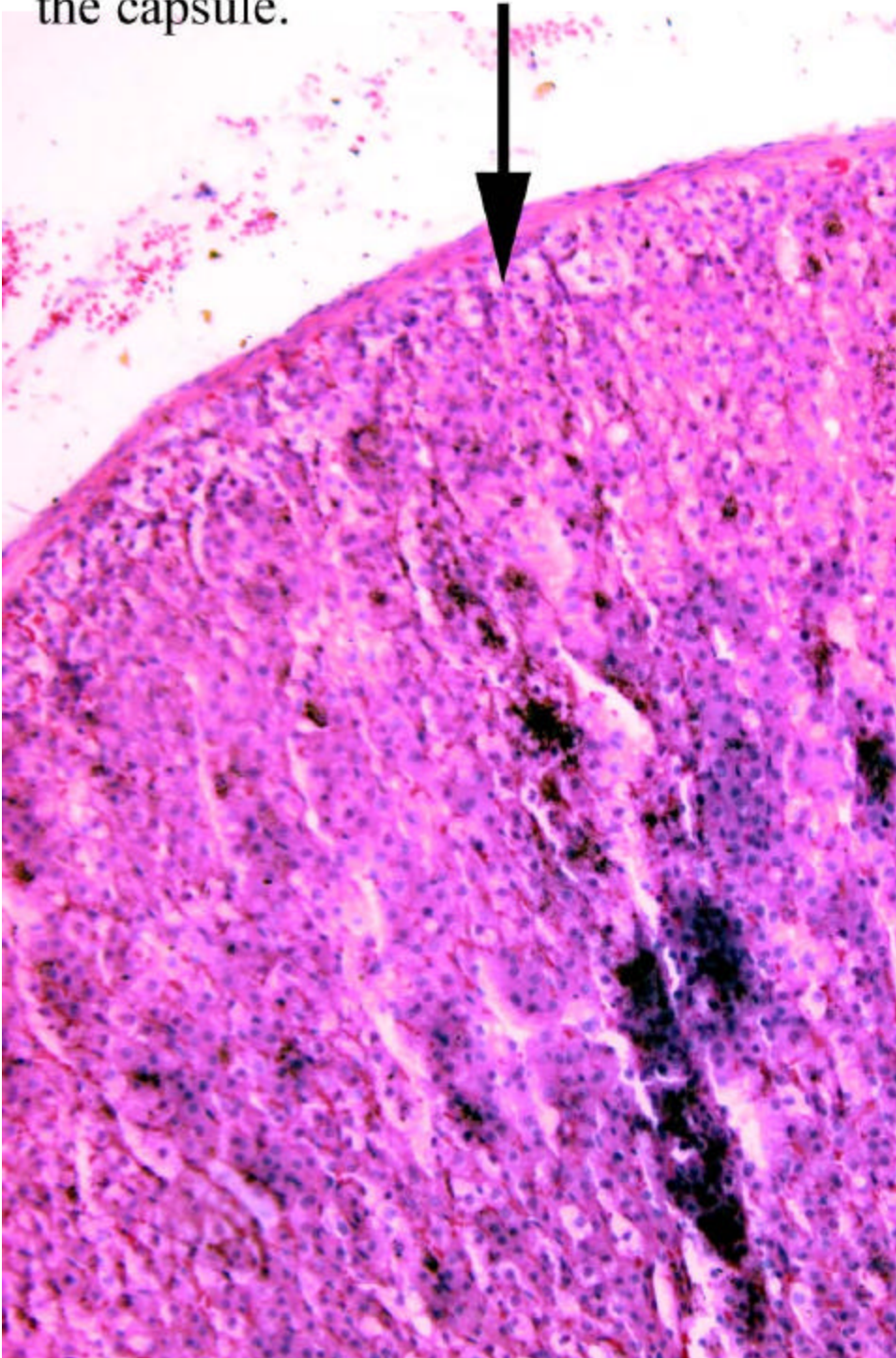
Solution	Time
Xylene	10 minutes
100% EtOH	10 minutes
95% EtOH	8 minutes
80% EtOH	4 minutes
Tap Water	4 minutes
Mordant (FeCl ₃)	5 minutes
Tap Water	5 minutes
Hematoxylin	5 minutes
Acidic Alcohol Solution	8 seconds
Tap Water	4 minutes
80% EtOH	4 minutes
Eosin Solution	20 seconds
95% EtOH	30 seconds
100% EtOH	2 minutes
Xylene	10 minutes

The slides were air dried in a hood overnight.

The following day, the slides were observed under a microscope and an estimation of the percent destruction of the zona glomerulosa layer was made.



The properly treated gland has
no layer of granulosa cells under
the capsule.



RESULTS:

Fixing, Staining and Sectioning of the adrenal glands were perfected by trial and error. The perfected technique revealed that the zona glomerulosa destruction ranged from 0-100% and was variable between glands.

CONCLUSION:

The freezing technique must be more carefully performed to result in a more consistent destruction of the zona glomerulosa.

Authors' Biography:

Jonida Pone is a student at MSU, Mankato double majoring in Biology and Chemistry. Huda Ahmed is a student at MSU, Mankato majoring in Biology.

Faculty Mentor Biography:

Penny Knoblich is a faculty mentor. She had a DVM and a Ph.D in physiology and teaches at MSU, Mankato.