

2017

## Single-stage osseointegrated reconstruction and rehabilitation of lower limb amputees: the Osseointegration Group of Australia Accelerated Protocol-2 (OGAAP-2) for a prospective cohort study

Munjed Al Muderis

*The University of Notre Dame Australia*, [munjed.al.muderis@nd.edu.au](mailto:munjed.al.muderis@nd.edu.au)

William Lu

Kevin Tetsworth

Belinda Bosley

Jiao Jiao Li

Follow this and additional works at: [https://researchonline.nd.edu.au/med\\_article](https://researchonline.nd.edu.au/med_article)



This other contribution to a refereed journal was originally published as:

Al Muderis, M., Lu, W., Tetsworth, K., Bosley, B., & Li, J. J. (2017). Single-stage osseointegrated reconstruction and rehabilitation of lower limb amputees: the Osseointegration Group of Australia Accelerated Protocol-2 (OGAAP-2) for a prospective cohort study. *BMJ Open*, 7 (3).

Original other contribution to a refereed journal available here:

<https://dx.doi.org/10.1136/bmjopen-2016-013508>

This other contribution to a refereed journal is posted on ResearchOnline@ND at [https://researchonline.nd.edu.au/med\\_article/874](https://researchonline.nd.edu.au/med_article/874). For more information, please contact [researchonline@nd.edu.au](mailto:researchonline@nd.edu.au).



This is an Open Access article distributed in accordance with the Creative Commons Attribution-Non Commercial (CC BY-NC 4.0) license, which permits others to distribute, remix, adapt, build upon this work non-commercially, and license their derivative works on different terms provided the original work is properly cited and the use is non-commercial.

See: <https://creativecommons.org/licenses/by-nc/4.0/>

This article originally published in *BMJ Open* available at:

<https://dx.doi.org/10.1136/bmjopen-2016-013508>

No changes have been made to this article.

Al Muderis, M., Lu, W., Tetsworth, K., Bosley, B., and Li, J.J. (2017) Single-stage osseointegrated reconstruction and rehabilitation of lower limb amputees: the Osseointegration Group of Australia Accelerated Protocol-2 (OGAAP-2) for a prospective cohort study. *BMJ Open*,7(3). doi: 10.1136/bmjopen-2016-013508

# BMJ Open Single-stage osseointegrated reconstruction and rehabilitation of lower limb amputees: the Osseointegration Group of Australia Accelerated Protocol-2 (OGAAP-2) for a prospective cohort study

Munjed Al Muderis,<sup>1,2,3</sup> William Lu,<sup>4</sup> Kevin Tetsworth,<sup>5,6</sup> Belinda Bosley,<sup>3</sup> Jiao Jiao Li<sup>4</sup>

**To cite:** Al Muderis M, Lu W, Tetsworth K, *et al.* Single-stage osseointegrated reconstruction and rehabilitation of lower limb amputees: the Osseointegration Group of Australia Accelerated Protocol-2 (OGAAP-2) for a prospective cohort study. *BMJ Open* 2017;**7**:e013508. doi:10.1136/bmjopen-2016-013508

► Prepublication history for this paper is available online. To view these files please visit the journal online (<http://dx.doi.org/10.1136/bmjopen-2016-013508>).

Received 17 July 2016  
Revised 17 February 2017  
Accepted 20 February 2017



CrossMark

For numbered affiliations see end of article.

## Correspondence to

Dr Jiao Jiao Li;  
[jiaojiao.li@sydney.edu.au](mailto:jiaojiao.li@sydney.edu.au)

## ABSTRACT

**Introduction:** Lower limb amputations have detrimental influences on the quality of life, function and body image of the affected patients. Following amputation, prolonged rehabilitation is required for patients to be fitted with traditional socket prostheses, and many patients experience symptomatic socket-residuum interface problems which lead to reduced prosthetic use and quality of life. Osseointegration has recently emerged as a novel approach for the reconstruction of amputated limbs, which overcomes many of the socket-related problems by directly attaching the prosthesis to the skeletal residuum. To date, the vast majority of osseointegration procedures worldwide have been performed in 2 stages, which require at least 4 months and up to 18 months for the completion of reconstruction and rehabilitation from the time of the initial surgery. The current prospective cohort study evaluates the safety and efficacy of a single-stage osseointegration procedure performed under the Osseointegration Group of Australia Accelerated Protocol-2 (OGAAP-2), which dramatically reduces the time of recovery to ~3–6 weeks.

**Methods and analysis:** The inclusion criteria for osseointegrated reconstruction under the OGAAP-2 procedure are age over 18 years, unilateral transfemoral amputation and experiencing problems or difficulties in using socket prostheses. All patients receive osseointegrated implants which are press-fitted into the residual bone. Functional and quality-of-life outcome measures are recorded preoperatively and at defined postoperative follow-up intervals up to 2 years. Postoperative adverse events are also recorded. The preoperative and postoperative values are compared for each outcome measure, and the benefits and harms of the single-stage OGAAP-2 procedure will be compared with the results obtained using a previously employed 2-stage procedure.

**Ethics and dissemination:** This study has received ethics approval from the University of Notre Dame, Sydney, Australia (014153S). The study outcomes will

## Strengths and limitations of this study

- This study is the first study to describe, as well as report on the safety and efficacy of, a single-stage procedure for the osseointegrated reconstruction of amputated limbs. This study may therefore have significant influence on the standard of treatment for patients with lower limb amputations undergoing osseointegration surgery, and reverse the concept that a two-stage procedure is required.
- This study has a relatively large sample size of 105 patients, which resembles one of the largest patient cohorts among studies published to date reporting on the outcomes of osseointegrated reconstruction of amputated limbs.
- This study does not directly compare the outcomes of using osseointegrated prostheses to the outcomes of using socket prostheses as the traditional method of treating patients with lower limb amputations.
- This study has a relatively short follow-up period of 2 years, which does not allow the examination of longer term outcomes and risk of adverse events.

be disseminated by publications in peer-reviewed academic journals and presentations at relevant clinical and orthopaedic conferences.

## INTRODUCTION

Lower limb amputations almost inevitably result in major changes to the quality of life, function and body image of the affected patients,<sup>1–4</sup> and are still associated with considerable morbidity and mortality.<sup>5</sup> For patients with bilateral above-knee amputations,



over 90% are eventually confined to a wheelchair due to the difficulty of mobilising with prostheses attached to both lower limbs.<sup>6</sup> The effect of amputation is greater in younger and more active patients who must adapt to a drastic reduction in mobility and the associated psychological consequences,<sup>4</sup> which also often restricts their ability to seek or continue employment.<sup>7</sup> The return-to-work rate for lower limb amputees is between 22% and 67%, with many having to change their occupation or work only part-time.<sup>8</sup> Data pooled from study populations in the UK, Europe, USA and parts of the Asia-Pacific indicate that the global incidence of all forms of lower extremity amputation ranges from 5.8 to 31 per 10<sup>5</sup> in the total population.<sup>9</sup>

Following amputation, prolonged rehabilitation is often required for patients to be fitted with traditional suspended socket prostheses. The fitting generally becomes more difficult with amputation at higher levels, and often results in characteristic symptoms of local pain, skin ulceration and discomfort.<sup>2 10 11</sup> In addition, patients with a short stump, skin grafts, scarring or heterotopic bone formation may be entirely unable to use socket prostheses, or choose not to use them due to the problems associated with socket fitting. A survey of 97 patients with transfemoral amputation in Sweden reported a very high prevalence of problems related to the use of socket prostheses, including: 72% with symptomatic heat and sweating of the stump, 62% with sores or skin irritation from the socket, 61% with interference to mobility and 51% with pain in the stump when standing or walking.<sup>2</sup> In addition, these patients consistently reported a significantly diminished quality of life when compared with able-bodied participants. The typical socket prosthesis used for transfemoral amputations has also been shown to hinder the range of motion of the involved hip, which contributes further to difficulties in ambulation.<sup>12</sup> The problems associated with socket prostheses have remained largely unsolved, despite extensive and continuing research into socket design and manufacturing.<sup>13</sup> Consequently, at least one-third of all amputees still experience symptomatic socket-residuum interface problems, leading to reduced prosthetic use and markedly reduced quality of life.<sup>10 14</sup>

Osseointegration has emerged over the past two decades as a dramatically different approach for the reconstruction of limb loss due to amputation, which can overcome many of the issues associated with traditional socket prostheses.<sup>15-17</sup> The surgical procedure involves direct attachment of the prosthesis to the skeletal residuum, in a process analogous to that used in uncemented hip arthroplasty. A titanium intramedullary implant is press-fitted into the residual bone of the amputated limb, which becomes rapidly incorporated into the bone over the few months following surgery. This implant is continuous with an abutment that penetrates the skin through a small permanent opening, which is used for attachment of the prosthetic limb. Osseointegrated prostheses can therefore completely

eliminate the problematic socket-residuum interface due to the intimate structural and functional connection between the intramedullary implant and host bone.

The Food and Drug Administration (FDA) recently approved osseointegration surgery for amputees in the USA, although for humanitarian indications only.<sup>18</sup> Nevertheless, this technology has been employed internationally for over 20 years and increasingly in Europe, the UK and Australia over the past decade. Osseointegration surgery for the reconstruction of amputated limbs has mainly been performed using two types of implants. Cannulated screw-fixation implants, originally developed in Sweden, achieve skeletal integration as a result of bone on-growth. Treatment requires two operations, where an initial procedure is performed to insert the intramedullary implant, and a second procedure is performed 6-9 months later to create the percutaneous skin opening for allowing abutment attachment and prosthesis fitting.<sup>19</sup> Alternatively, press-fit macroporous surface structure implants allow skeletal integration by bone penetration and ingrowth, which also require a two-stage operation with a 6-8-week interval between stages.<sup>20</sup> Several prospective case series describing these two techniques have been published, which reported on the major clinical benefits of the osseointegration approach, including improvements in the patients' quality of life,<sup>21</sup> prosthetic use,<sup>21 22</sup> body image,<sup>22</sup> hip range of motion,<sup>23</sup> sitting comfort,<sup>12</sup> donning and doffing,<sup>21</sup> osseoperception<sup>24</sup> and walking ability,<sup>16 25</sup> as well as very acceptable levels of risk with respect to implant stability<sup>26</sup> and infection rates.<sup>17 27</sup> Recently, a comprehensive surgical and rehabilitation protocol (OGAAP-1) has been developed for procedures involving osseointegrated implants which are currently used in Australia and the Netherlands, with press-fit designs that encourage bone ingrowth.<sup>28</sup> This protocol emphasises an integrated approach for the management of patients with lower limb amputations, and revolves around two-stage osseointegration surgery with a 4-6-week interval between stages. Preliminary results have demonstrated significant improvements in quality of life and functional outcome measures,<sup>28</sup> while maintaining very reasonable complication rates.<sup>29</sup>

Until very recently, the vast majority of osseointegration procedures worldwide have been performed in two stages. From the time of the initial surgery, these procedures require up to 12-18 months for the completion of reconstruction and rehabilitation with screw-fixation implants, and at least 4-5 months even under the accelerated OGAAP-1 protocol.<sup>28</sup> Since April 2014, however, a single-stage osseointegration procedure has been routinely performed by the Osseointegration Group of Australia (OGA) under the Osseointegration Group of Australia Accelerated Protocol-2 (OGAAP-2). This protocol reduces the overall time required for the definitive osseointegrated reconstruction and rehabilitation of lower limb amputees to ~3-6 weeks, which is substantially shorter compared with any currently available two-stage

procedure. This study aims to assess the safety and efficacy of the single-stage OGAAP-2 procedure in a sufficiently large group of patients. The main hypothesis is that the single-stage OGAAP-2 procedure will result in more rapid progression to unrestricted full weight-bearing with an osseointegrated reconstruction, within an even shorter time frame compared with the two-stage OGAAP-1 procedure, without an increased risk of associated adverse events.

### Study objectives

The overall objective of this study is to assess the safety and efficacy of the single-stage OGAAP-2 procedure for the osseointegrated reconstruction of lower limb amputations, and compare the benefits and harms with the outcomes obtained using the OGAAP-1 procedure within 2 years of follow-up. Specifically, this involves:

1. Assessing the objective functional outcomes after osseointegrated reconstruction of amputated limbs using the single-stage OGAAP-2 procedure, with the 6 Minute Walk Test (6MWT), Timed Up and Go (TUG) and K-levels, compared with preoperative data and also data obtained using the previously employed two-stage OGAAP-1 procedure.
2. Assessing the subjective patient-reported quality-of-life outcomes after osseointegrated reconstruction of amputated limbs using the single-stage OGAAP-2 procedure, with the Questionnaire for persons with a Trans-Femoral Amputation (Q-TFA) and the Short Form Health Survey 36 (SF-36), compared with preoperative data and also data obtained using the previously employed two-stage OGAAP-1 procedure.
3. Examining the prevalence of adverse events after osseointegrated reconstruction of amputated limbs using the single-stage OGAAP-2 procedure, including infection, revision surgery, fractures and implant failures, compared with data obtained using the previously employed two-stage OGAAP-1 procedure.

## METHODS AND ANALYSIS

### Overview of study design

The current prospective cohort study is designed to assess the safety and efficacy of the single-stage OGAAP-2 procedure for the osseointegrated reconstruction of lower limb amputations within 2 years of follow-up. The OGAAP-2 procedure is a comprehensive programme for the management of patients with lower limb amputation using single-stage osseointegration surgery (figure 1). This procedure is exclusively performed by the OGA in Australia, and has been routinely performed on eligible patients since March 2014. Patients are evaluated by validated outcome measures preoperatively and postoperatively. Preliminary data have been obtained from an initial pilot study with 10 patients, which have been used to provide the sample size estimate for the current study. The outcomes of this study will be compared with those obtained using the

previously employed OGAAP-1 procedure at the same follow-up time points.

### Patient selection

#### Eligibility criteria

The inclusion criteria are age over 18 years, unilateral transfemoral amputation and experiencing socket-related problems or difficulties in using socket prostheses (including patients who are ambulatory with assistive devices or non-ambulatory with short stumps and non-reconstructable limb pathology). The exclusion criteria are smoking, psychological instability, pregnancy, limb exposure to radiation, ongoing chemotherapy, immunosuppression, diabetes, peripheral vascular disease and non-compliance during preoperative screening and evaluation.

#### Patient screening and recruitment

Prospective patients are referred by rehabilitation physicians, specialists, general practitioners (GPs) or prosthetists, or arise from direct enquiries. All prospective patients are asked to complete a secure online enquiry form found on the OGA website. If the patient has consented to communication, team contact occurs in the form of a phone call to confirm the patient's medical and social demographic history, prosthetic history, general expectations and compliance, as well as to discuss the exclusion criteria. Pain and psychological questionnaires are then provided to the patient, and used as tools for assessing the patient's psychological well-being and identifying any chronic pain issues. Patients who satisfy the inclusion criteria are invited to attend a specialised osseointegration clinic, during which preoperative clinical, radiological and psychological examinations are performed, and baseline values of outcome measures are recorded. The clinic also gives an opportunity for prospective patients to receive specialist team counselling, as well as to engage in peer-to-peer interaction regarding the surgical procedure and recovery. After an individual consultation with the specialist team, suitable patients are enrolled for osseointegration surgery using the OGAAP-2 procedure, and informed consent for data collection is obtained.

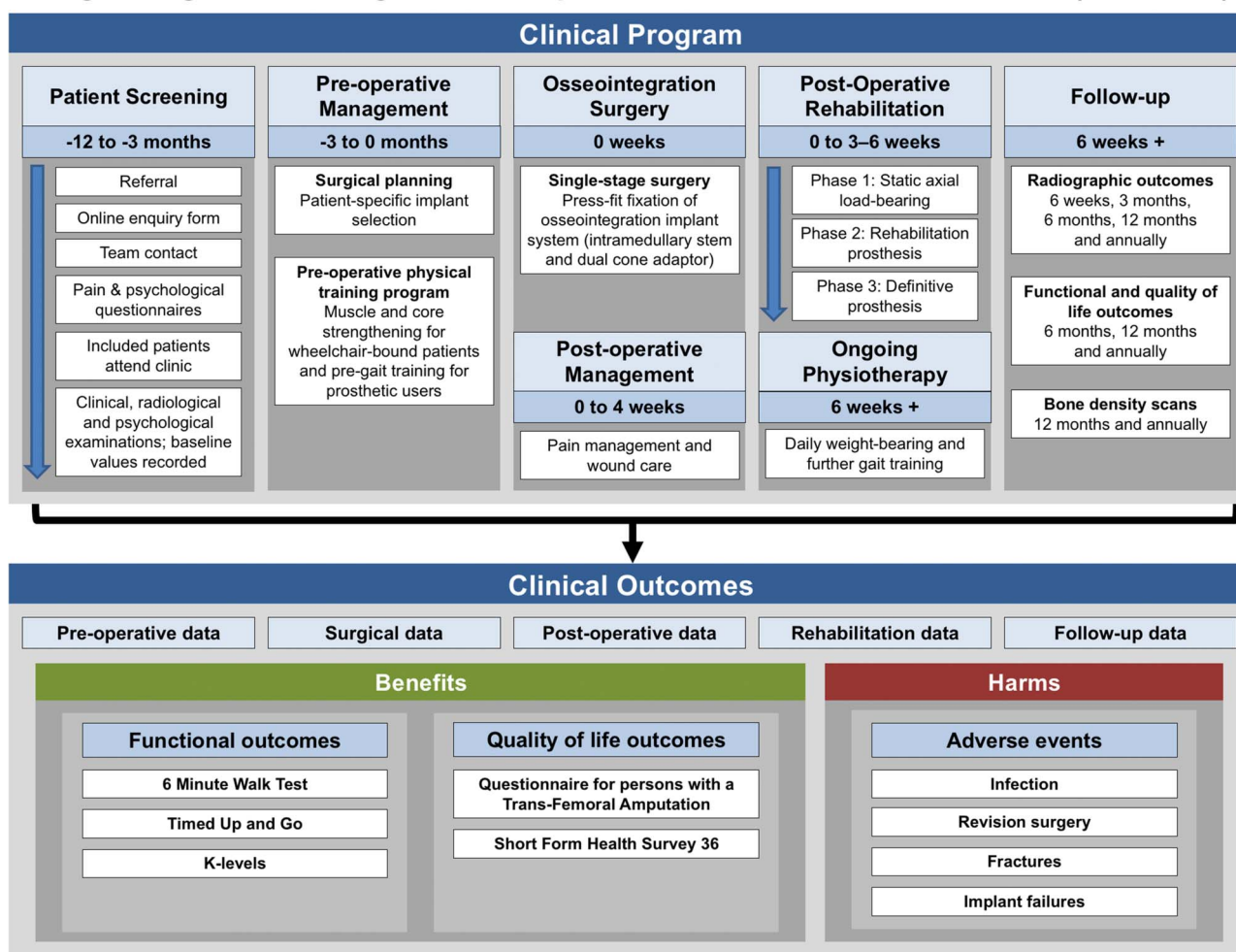
The first definitive patient undergoing osseointegrated reconstruction using the OGAAP-2 procedure was enrolled on 9 April 2014. Enrolment is ongoing at the time of publication and is expected to be complete by December 2016.

### Study intervention

#### Preoperative management

Surgical planning is conducted by using the patient's radiographs, CT scans and dual-energy X-ray absorptiometry (DXA) scans to determine the anatomy of the skeletal residuum, as well as to allow patient-specific selection of the implant type and size, and external prosthetic components. A preoperative physical training programme is recommended for all patients. This consists

## Single-Stage Osseointegration Group of Australia Accelerated Protocol (OGAAP-2)



**Figure 1** Overview of the single-stage Osseointegration Group of Australia Accelerated Protocol-2 clinical programme and outcomes evaluation for the osseointegrated reconstruction of lower limb amputations.

of muscle strengthening and visualisation, and core strengthening exercises (including abdominals and upper body) for wheelchair-bound patients, and pre-gait training aimed at increasing the range of movement (with particular emphasis on the residuum hip flexors and adductors) for prosthetic users.

### Osseointegration surgery

The surgical procedure involves permanent insertion of the Osseointegrated Prosthetic Limb (OPL; Permedica s. p.a; Milan, Italy) (figure 2). This osseointegration implant system is specifically designed for press-fit fixation and consists of two components. The intramedullary stem component has proximal splines to facilitate initial rotational stability, and a distal flare to provide initial axial stability. It also has a macroporous surface structure resembling cancellous bone to facilitate bone penetration. These design features provide rigid initial stability, as well as permanent implant anchorage as a result of bone ingrowth. The dual-cone adaptor component connects the intramedullary stem to the external prosthesis and has a highly polished surface coated with

titanium-niobium dioxide to minimise soft tissue friction and adhesions. The proximal aspect of the dual-cone adaptor that connects to the intramedullary stem is provided with a safety pin, which fails under excessive torsional forces to prevent periprosthetic fracture or implant breakage.

The procedure is performed in a single stage under the OGAAP-2 protocol (figure 3). Prophylactic intravenous antibiotics using 2 g of cephazolin is administered prior to the procedure, in accordance with standard arthroplasty antibiotic prophylaxis protocols.<sup>30</sup> The first part of the operation involves soft tissue preparation and implantation of the intramedullary stem, which comprises a major portion of the surgery. This includes guillotine amputation of the stump without shortening of the bony residuum, and reorganisation of the residual muscle groups around the bone end using absorbable purse string sutures. Haemostasis is achieved, and neuromas are identified and terminalised by shortening the nerve endings and embedding them into the surrounding fatty tissue to avoid adhesions or tethering to muscles. Additional soft tissue optimisation is then



**Figure 2** The Osseointegrated Prosthetic Limb implant system (Permedica s.p.a; Milan, Italy) used for the osseointegrated reconstruction of trans-femoral amputations under the Osseointegration Group of Australia Accelerated Protocol-2 procedure. The implant consists of an intramedullary stem component and a dual-cone adaptor component.

performed with refashioning of the stump and excision of excess subcutaneous fat to achieve a minimised soft tissue envelope. The final stage of soft tissue preparation involves identifying the area of soft tissue opposing the distal end of the bony residuum, and removing the fat beneath a circular portion of skin in this area. The dermis is then sutured around the periosteum, and the wound is closed using metal staples with minimal internal sutures. Under fluoroscopy, a k-wire is inserted through the de-fatted skin at the tip of the bony residuum, followed by application of a circular skin corer to create a percutaneous opening.

After haemostasis is achieved, the medullary canal is prepared under fluoroscopic guidance using sequential flexible reamers followed by implant-specific broaches. Broaching is undertaken to the same size as the planned implant size. However, in the presence of osteoporosis as indicated by examination of the DXA scan, broaching is undertaken to one size under that of the planned implant size. The distal portion of the femur is prepared

using specific rasps to match the distal flange of the implant. The intramedullary stem is then inserted into the medullary canal of the residual femur by impacting with a mallet to achieve a mechanically stable press-fit fixation.

The second part of the operation involves attachment of the transcuteaneous dual-cone adaptor to the intramedullary stem. The appropriate size is selected by inserting the adaptor sizing guide through the skin opening. The selected dual-cone adaptor is placed into the Morse taper sleeve on the distal end of the intramedullary stem and locked by impaction, then further secured with an internal locking screw. The distal taper sleeve, bushing and distal abutment screw are then attached to the distal aspect of the dual-cone adaptor. The bushing contains a two-pin external fail-safe mechanism, which limits the risk of periprosthetic fracture. Once completed, local anaesthetic is infiltrated proximal to the terminalised nerves, as well as surrounding the stoma and incision site.

### Postoperative management

Pain management involves the administration of intravenous and epidural pain medications for the first 3 days following surgery, and oral analgesics thereafter. Wound care involves daily dressing changes with dry ribbon gauze and application of antiseptic solution for 10 days postoperation. Patients are then advised to wash the implant–skin interface two times per day with warm tap water and soap, and to pat dry the skin opening with disposable paper towels. Patients are generally discharged 5–7 days after surgery. Staples are typically removed after 3–4 weeks.

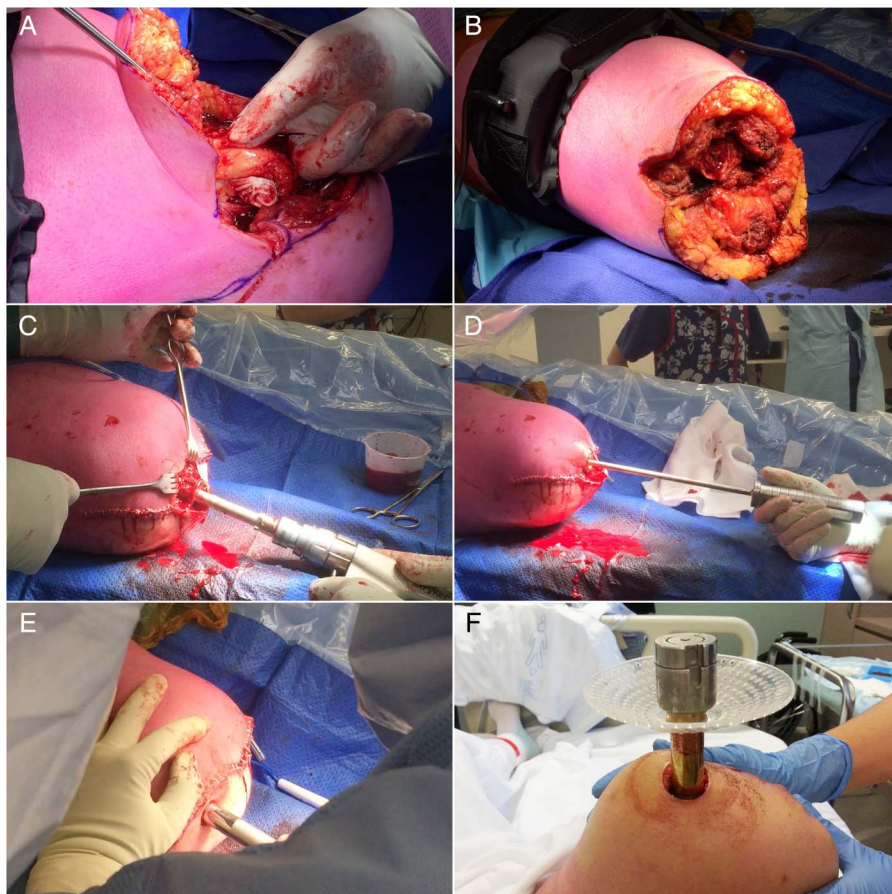### Rehabilitation

Postoperative rehabilitation proceeds in three phases. Phase I is initiated 3 days after surgery and consists of the patient applying a static axial load of 20 kg for 20 min two times per day. The load is increased by 5 kg/day until either 50 kg or 50% of the patient's body weight is reached. Phase II is initiated when the patient has reached the recommended axial loading level. The patient is fitted with a rehabilitation prosthesis, which includes a light leg with a stable locked knee. The patient continues to perform core strengthening and balance exercises, and gait exercises aided by parallel bars. Phase III is initiated when the patient is safely mobilising using the rehabilitation prosthesis. The patient is then fitted with the definitive prosthesis and proceeds to daily weight-bearing. Postoperative rehabilitation should be concluded within 3–6 weeks following osseointegration surgery.

### Ongoing physiotherapy

After rehabilitation, the patient performs daily weight-bearing using the definitive prosthesis, first on two crutches for 6 weeks, then on a single crutch in the opposite hand for another 6 weeks and unaided

**Figure 3** Steps involved in single-stage osseointegration surgery under the Osseointegration Group of Australia Accelerated Protocol-2. (A) Identification and terminalisation of neuromas during soft tissue preparation. (B) Completed guillotine amputation of the stump. (C) Reaming of the medullary canal and preparation of the distal femur to accommodate the flange of the intramedullary stem component of the osseointegration implant. (D) Insertion of the intramedullary stem by impacting with a mallet. (E) Creation of the stoma site and insertion of the dual-cone adaptor component of the osseointegration implant. (F) Stoma site postoperation, showing the inserted dual-cone adaptor and remaining parts of the abutment.



thereafter. Meanwhile, further gait training is recommended that focuses on fall prevention and management, balance, walking and ascending and descending slopes.

### Study outcomes and follow-up

#### Study outcomes

The outcome measures of this study include: (1) objective functional outcomes measured using the 6MWT, TUG and K-levels, (2) subjective patient-reported quality-of-life outcomes measured using the Q-TFA and SF-36 and (3) prevalence of adverse events including infection, revision surgery, fractures and implant failures after osseointegrated reconstruction of amputated limbs using the single-stage OGAAP-2 procedure. A description of each of these validated outcome measures is provided below. In addition, perioperative parameters including total surgical time (hours), intraoperative bleeding (significant (>300 cc) or not significant), postoperative pain (numerical rating scale), total time in hospital (days), time to definitive prosthetic fitting (days) and time to full weight-bearing (days) will be recorded and compared with results obtained using the previously employed OGAAP-1 procedure.

The 6MWT involves documenting, in metres, the maximum distance covered by the patient in 6 min by continuously walking along a 25 m long level enclosed corridor.<sup>31</sup> The TUG involves documenting the time, in

seconds, required for the patient to rise from a standard armchair, walk to a line on the floor 3 m away, turn, walk back to the chair and sit down again.<sup>32</sup> K-levels are defined by the US Medicare system to categorise the ability of lower limb amputees to ambulate and navigate the environment, and uses a five-level functional classification system (K0–K4, where K0 is defined as inability to ambulate and a prosthesis does not enhance quality of life or mobility, and K4 is defined as ability for prosthetic ambulation that exceeds basic ambulation skills as exemplified by a child, active adult or athlete).<sup>33</sup> The results of these functional outcome measures obtained after osseointegrated reconstruction using the OGAAP-2 procedure will be compared with preoperative baseline values, as well as with the results obtained using the previously employed OGAAP-1 procedure at the same follow-up time points.

The Q-TFA is a self-report measure developed for transfemoral amputees using a socket or osseointegrated prosthesis to reflect prosthetic use, prosthetic mobility, problems and global health, each in a separate score (0–100).<sup>34</sup> The SF-36 is a short-form health survey designed for use in clinical practice and research, and includes one multi item scale that assesses the eight health concepts of physical functioning, social functioning, role limitations due to physical problems, bodily pain, general mental health, role limitations due to emotional problems, vitality and general health



perceptions.<sup>35</sup> The results of these quality-of-life outcome measures obtained after osseointegrated reconstruction using the OGAAP-2 procedure will be compared with preoperative baseline values, as well as with the results obtained using the previously employed OGAAP-1 procedure at the same follow-up time points.

The monitoring and recording of adverse events involves identifying infections related to the osseointegrated implant on the basis of clinical and radiographic findings, and grading them into five levels of severity: 0, no infection; 1, low-grade soft tissue infection; 2, high-grade soft tissue infection; 3, deep bone infection or 4, septic implant failure.<sup>29</sup> Management of infections is recorded as (A) oral antibiotics, (B) parenteral antibiotics, or (C) surgical debridement and/or explantation.<sup>29</sup> Other adverse events are recorded and categorised into: stoma hypergranulation, redundant soft tissue, proximal femoral fracture, inadequate osseointegration with replacement of implant, breakage of intramedullary component and breakage of dual-cone component safety pin.<sup>29</sup> The prevalence of adverse events after osseointegrated reconstruction using the OGAAP-2 procedure will be compared with the results obtained using the previously employed OGAAP-1 procedure at the same follow-up time points.

### Study follow-up

All patients are followed for a minimum period of 2 years, with routine clinical monitoring conducted and outcomes assessed at set intervals of 6 weeks, 3, 6 and 12 months after surgery and annually thereafter. Radiographic outcomes are assessed at all follow-up intervals scheduled. 6MWT, TUG, Q-TFA and SF-36 outcomes are assessed at 6 and 12 months, and annually thereafter. DXA scans are performed at the 12-month follow-up, and annually thereafter. All adverse events are managed when identified as appropriate for the clinical conditions encountered, and recorded at the time of occurrence. Mechanisms of reporting adverse events include entries in the patient's diary booklet, reports from the patient's GP and any contact made directly to the clinical team.

The minimum follow-up period of 2 years is chosen as our previous experience indicates that peak gains in function and quality of life as a result of osseointegrated reconstruction of amputated limbs are obtained within 12 months postoperation,<sup>28</sup> and changes in related outcomes can be expected to plateau thereafter. Our previous experience also shows that 2 years of follow-up will provide sufficient time for the monitoring of any major adverse events (such as infection) following surgery.<sup>29</sup> Given the short time period required for definitive osseointegrated reconstruction and rehabilitation under the OGAAP-2 procedure, the most significant changes in measures of benefits and harms are expected to be observed within 6 months of follow-up.

### Protecting against sources of bias

Owing to the nature of this study with one treatment group (patients undergoing single-stage

osseointegration surgery under the OGAAP-2) and no simultaneous control group (previously obtained data from patients undergoing osseointegration surgery under the OGAAP-1 will be used for comparison at the same follow-up time points), the assessors of outcome measures cannot be blinded. However, bias will be unlikely for the functional and quality-of-life outcome measures since these do not require the assessor's subjective judgement. The results of functional outcome measures (6MWT, TUG, K-levels) depend completely on the patients' physical performance, while the results of quality-of-life outcome measures (Q-TFA, SF-36) are derived completely from surveys of patient responses. To avoid bias, the assessors collecting these results will not be involved in the data analysis aspect of the study.

For the reporting of adverse events, patients are advised to see their GP for suspected infection, and cases of infection are typically managed by the GP unless surgical intervention is required. The GPs are not part of the core clinical and research team conducting this study, and will therefore provide an unbiased diagnosis of any infection cases related to osseointegration surgery. Information on cases of infection is relayed back to the OGA team, and an infection grading is assigned only after the case has been resolved. The level of severity of the infection (0–4) is determined by a group of surgeons and infection specialists to minimise bias, while the method of management (A–C) is assigned depending on the type of intervention and does not require assessor judgement. Adverse events other than infection are reported as the number of cases occurring and are not subjected to bias.

Bias relating to surgeon expertise and protocol adherence is eliminated since all operations will be performed by a single surgeon, who is the developer of the OGAAP-2 protocol and initiator of this study.

### Statistical plan and data analysis

#### Sample size estimate

Owing to the absence of previous literature on osseointegrated reconstruction using the OGAAP-2 procedure, data from an initial pilot study with 10 patients have been used to provide the most accurate sample size estimate possible. An a priori sample size calculation for analysis of variance (ANOVA) has been performed to determine the number of cases required to demonstrate a statistically significant ( $p=0.05$ ) difference between preoperative and postoperative data for the functional and quality-of-life outcome measures. The sample size was calculated using the difference between the means for four of the main validated outcome measures (6MWT, TUG, Q-TFA and SF-36) based on the pilot study data (table 1), assuming that  $\alpha=0.5$  and  $\beta=0.10$  with a power of 0.90 ( $1-\beta$ ). Based on these parameters, the sample size calculations indicate that a minimum of 84 participants is necessary to provide a statistical power of 90%. To account for dropouts related to death and

**Table 1** Sample size calculations comparing preoperative and postoperative pilot study data for the functional and quality-of-life outcome measures, obtained for osseointegrated reconstruction under the Osseointegration Group of Australia Accelerated Protocol-2 procedure

Pilot study outcome measures	Preoperative mean	Postoperative mean	SD	Estimated N
6MWT	165	392	178	13
TUG	10.5	6.2	8.6	84
Q-TFA (global score)	45.0	71.3	21.6	15
SF-36 (physical component score)	39.3	46.4	12.4	64

loss to follow-up (conservative estimate of 25%), a total of 105 patients will be recruited for the current study.

### Data analysis

Continuous outcome variables will be summarised by calculating the mean and SE, and a Kolmogorov-Smirnov test will be used to determine the normality of the data. Categorical outcome variables will be presented as frequencies and percentages. ANOVA will be used to determine differences between preoperative and postoperative values for each continuous outcome measure. Fisher's exact test will be used to examine the significance of the contingency of preoperative and postoperative K-levels. The Bonferroni corrections will be performed to adjust for multiple comparisons. Multiple two-way contingency tables will be created, and a two-tailed Pearson  $\chi^2$  test with Yates corrections will be used for comparisons as indicated. All statistical analyses will be performed using Systat SPSS V.22.0 (IBM Corp., Armonk, New York, USA), where  $p < 0.05$  will be considered significant for all comparisons.

## DISSEMINATION

### Ethical considerations

All patients included in this study will sign a consent form that provides sufficient information about the study for patients to make an informed decision about their participation. All patient data and personal information will be deidentified and maintained on a password-enabled secure laptop computer.

### Dissemination

Outcomes of the current study will be disseminated by publications in peer-reviewed academic journals and presentations at relevant clinical and orthopaedic conferences. To minimise delay, the preparation of study findings for dissemination will start as soon as data collection for the 2-year follow-up is complete for all enrolled patients. A manuscript containing the major findings of this study will be submitted for publication regardless of the presence or absence of significant outcomes.

## DISCUSSION

The findings of this study will make an important contribution to the small body of literature that is currently

available regarding the reconstruction and rehabilitation of lower limb amputees using osseointegrated prostheses. The single-stage OGAAP-2 procedure enables the patient to achieve rapid progression to definitive osseointegrated reconstruction and full weight-bearing after surgery, within a substantially shorter period of time compared with any other currently available two-stage procedure. By allowing single-stage surgery, the new implant design used under the OGAAP-2 procedure eliminates the minimum 6-week delay between surgical stages that is required for two-stage procedures, and also facilitates an accelerated postoperative rehabilitation programme that results in fast progression to unrestricted and unassisted full weight-bearing. The OGAAP-2 procedure therefore dramatically reduces the overall treatment time to 3–6 weeks, which is comparable to that of uncemented total hip arthroplasty procedures.<sup>36</sup>

The concept of osseointegrated reconstruction originated in the dental implant field. Osseointegrated dental implants were introduced in the 1960s and were initially performed in two stages, where a 3–6-month interval between stages allowed uneventful wound healing prior to further intervention.<sup>37</sup> Nevertheless, the immediate loading of dental implants is now routinely permitted, with multiple studies demonstrating the feasibility and predictability of the single-stage approach.<sup>38–40</sup> A major research question answered by the current study is whether the same concept of single-stage operation for dental implants can be applied to the osseointegrated reconstruction of amputated lower limbs.

If this study demonstrates that the single-stage OGAAP-2 procedure leads to significant improvements in postoperative functional and quality-of-life outcomes compared with preoperative levels without an increased prevalence of adverse events, it will potentially reverse the concept that a two-stage procedure is necessary to achieve the safe and effective osseointegrated reconstruction of amputated limbs. This may have a substantial impact in shaping a new standard of treatment for patients with lower limb amputations, which allows for rapid recovery and the earliest possible return to daily activities.

A limitation of this study is that direct comparisons cannot be made with the outcomes of using socket prostheses, as the cohort of patients who are considered for osseointegration surgery are either experiencing problems with their socket prosthesis or are wheelchair-bound.

Nevertheless, the current study compares preoperative and postoperative values of functional and quality-of-life outcome measures in patients undergoing osseointegrated reconstruction under the OGAAP-2 procedure, which gives an indication of the benefits of osseointegrated prostheses as a solution for patients who have previously been excluded from other types of prosthetic reconstruction. Another limitation is the relatively short follow-up period of 2 years. Although this time frame is considered sufficient for assessing the important benefits and harms of the OGAAP-2 procedure, it does preclude the examination of long-term outcomes and the long-term risk of adverse events. Larger prospective studies with longer follow-up times will be necessary to fully evaluate the long-term safety and efficacy of osseointegrated reconstruction of lower limb amputations under the OGAAP-2 procedure. The OGA team will continue to collect routine clinical data from the patients of this study after the 2-year follow-up, such that long-term retrospective analyses can be performed at a later date.

#### Author affiliations

<sup>1</sup>The Australian School of Advanced Medicine, Macquarie University, North Ryde, New South Wales, Australia

<sup>2</sup>School of Medicine, University of Notre Dame, Auburn, New South Wales, Australia

<sup>3</sup>Norwest Private Hospital, Bella Vista, New South Wales, Australia

<sup>4</sup>Biomaterials and Tissue Engineering Research Unit, School of AMME, University of Sydney, Sydney, New South Wales, Australia

<sup>5</sup>Royal Brisbane Hospital, Herston, Queensland, Australia

<sup>6</sup>School of Medicine, University of Queensland, Brisbane, Queensland, Australia

**Contributors** MAM is responsible for study design, patient care and surgical procedure, and manuscript preparation. WL is responsible for data collection and manuscript revision. KT is responsible for study design, statistical planning and manuscript revision. BB is responsible for patient care, data collection and manuscript revision. JLL is responsible for data collection and manuscript preparation and revision.

**Funding** This research received no specific grant from any funding agency in the public, commercial or not-for-profit sectors.

**Competing interests** MAM receives royalties for design contributions for the Osseointegrated Prosthetic Limb (OPL; Permedica s.p.a; Milan, Italy) implant system.

**Ethics approval** University of Notre Dame, Sydney, Australia.

**Provenance and peer review** Not commissioned; externally peer reviewed.

**Open Access** This is an Open Access article distributed in accordance with the Creative Commons Attribution Non Commercial (CC BY-NC 4.0) license, which permits others to distribute, remix, adapt, build upon this work non-commercially, and license their derivative works on different terms, provided the original work is properly cited and the use is non-commercial. See: <http://creativecommons.org/licenses/by-nc/4.0/>

#### REFERENCES

- Ephraim PL, MacKenzie EJ, Wegener ST, *et al.* Environmental barriers experienced by amputees: the craig hospital inventory of environmental factors-short form. *Arch Phys Med Rehabil* 2006;87:328–33.
- Hagberg K, Brånemark R. Consequences of non-vascular trans-femoral amputation: a survey of quality of life, prosthetic use and problems. *Prosthet Orthot Int* 2001;25:186–94.
- Livingston DH, Keenan D, Kim D, *et al.* Extent of disability following traumatic extremity amputation. *J Trauma Acute Care Surg* 1994;37:495–9.
- Senra H, Oliveira RA, Leal I, *et al.* Beyond the body image: a qualitative study on how adults experience lower limb amputation. *Clin Rehabil* 2012;26:180–91.
- Ploeg AJ, Lardenoye JW, Vrancken Peeters MPFM, *et al.* Contemporary series of morbidity and mortality after lower limb amputation. *Eur J Vasc Endovasc Surg* 2005;29:633–7.
- Ziegler-Graham K, MacKenzie EJ, Ephraim PL, *et al.* Estimating the prevalence of limb loss in the United States: 2005 to 2050. *Arch Phys Med Rehabil* 2008;89:422–9.
- Burger H, Marinček C. The life style of young persons after lower limb amputation caused by injury. *Prosthet Orthot Int* 1997;21:35–9.
- Burger H, Marinček C. Return to work after lower limb amputation. *Disabil Rehabil* 2007;29:1323–9.
- Moxey PW, Gogalniceanu P, Hinchliffe RJ, *et al.* Lower extremity amputations—a review of global variability in incidence. *Diabet Med* 2011;28:1144–53.
- Dillingham TR, Pezzin LE, MacKenzie EJ, *et al.* Use and satisfaction with prosthetic devices among persons with trauma-related amputations: a long-term outcome study. *Am J Phys Med Rehabil* 2001;30:563–71.
- Meulenbelt HEJ, Geertzen JHB, Jonkman MF, *et al.* Skin problems of the stump in lower limb amputees: 1. A clinical study. *Acta Derm Venereol* 2011;91:173–7.
- Hagberg K, Häggström E, Uden M, *et al.* Socket versus bone-anchored trans-femoral prostheses: hip range of motion and sitting comfort. *Prosthet Orthot Int* 2005;29:153–63.
- Collins DM, Karmarkar A, Relich R, *et al.* Review of research on prosthetic devices for lower extremity amputation. *Crit Rev Biomed Eng* 2006;34:379–438.
- Lyon CC, Kulkarni J, Zimerson E, *et al.* Skin disorders in amputees. *J Am Acad Dermatol* 2000;42:501–7.
- Brånemark R, Brånemark P, Rydevik B, *et al.* Osseointegration in skeletal reconstruction and rehabilitation: a review. *J Rehabil Res Dev* 2001;38:175.
- Van de Meent H, Hopman MT, Frölke JP. Walking ability and quality of life in subjects with transfemoral amputation: a comparison of osseointegration with socket prostheses. *Arch Phys Med Rehabil* 2013;94:2174–8.
- Brånemark R, Berlin Ö, Hagberg K, *et al.* A novel osseointegrated percutaneous prosthetic system for the treatment of patients with transfemoral amputation: a prospective study of 51 patients. *Bone Joint J* 2014;96-B:106–13.
- U.S. Food and Drug Administration. FDA authorizes use of prosthesis for rehabilitation of above-the-knee amputations. <http://www.fda.gov/NewsEvents/Newsroom/PressAnnouncements/UCM455103> 16 July 2015.
- Hagberg K, Brånemark R. One hundred patients treated with osseointegrated transfemoral amputation prostheses—rehabilitation perspective. *J Rehabil Res Dev* 2009;46:331–44.
- Aschoff HH, Kennon RE, Keggi JM, *et al.* Transcutaneous, distal femoral, intramedullary attachment for above-the-knee prostheses: an endo-exo device. *J Bone Joint Surg Am* 2010;92(Suppl 2):180–6.
- Hagberg K, Brånemark R, Gunterberg B, *et al.* Osseointegrated trans-femoral amputation prostheses: prospective results of general and condition-specific quality of life in 18 patients at 2-year follow-up. *Prosthet Orthot Int* 2008;32:29–41.
- Lundberg M, Hagberg K, Bullington J. My prosthesis as a part of me: a qualitative analysis of living with an osseointegrated prosthetic limb. *Prosthet Orthot Int* 2011;35:207–14.
- Tranberg R, Zügner R, Kärrholm J. Improvements in hip- and pelvic motion for patients with osseointegrated trans-femoral prostheses. *Gait Posture* 2011;33:165–8.
- Hagberg K, Häggström E, Jönsson S, *et al.* Osseoperception and osseointegrated prosthetic limbs. In: Gallagher Desmond D, MacLachlan M, eds. *Psychoprosthetics*. London: Springer London, 2008:131–40.
- Frossard L, Hagberg K, Häggström E, *et al.* Functional outcome of transfemoral amputees fitted with an osseointegrated fixation: temporal gait characteristics. *J Prosthet Orthot* 2010;22:11–20.
- Nebergall A, Bragdon C, Antonellis A, *et al.* Stable fixation of an osseointegrated implant system for above-the-knee amputees. *Acta Orthop* 2012;83:121–8.
- Tillander J, Hagberg K, Hagberg L, *et al.* Osseointegrated titanium implants for limb prostheses attachments: infectious complications. *Clin Orthop Relat Res* 2010;468:2781–8.
- Muderis MA, Tetsworth K, Khemka A, *et al.* The Osseointegration Group of Australia Accelerated Protocol (OGAAP-1) for two-stage osseointegrated reconstruction of amputated limbs. *Bone Joint J* 2016;98-B:952–60.
- Al Muderis M, Khemka A, Lord SJ, *et al.* Safety of osseointegrated implants for transfemoral amputees: a two-center prospective cohort study. *J Bone Joint Surg Am* 2016;98:900–9.



30. Meehan J, Jamali AA, Nguyen H. Prophylactic antibiotics in hip and knee arthroplasty. *J Bone Joint Surg Am* 2009;91:2480–90.
31. Lipkin DP, Scriven AJ, Crake T, *et al*. Six minute walking test for assessing exercise capacity in chronic heart failure. *Br Med J (Clin Res Ed)* 1986;292:653–5.
32. Schoppen T, Boonstra A, Groothoff JW, *et al*. The timed 'up and go' test: reliability and validity in persons with unilateral lower limb amputation. *Arch Phys Med Rehabil* 1999;80:825–8.
33. Health Care Financing Administration (HCFA). *Common Procedure Coding System HCPCS 2001*. Washington, DC, USA: US Government Printing Office, 2001.
34. Hagberg K, Rickard B, Hägg O. Questionnaire for persons with a transfemoral amputation (Q-TFA): initial validity and reliability of a new outcome measure. *J Rehabil Res Dev* 2004;41:695–706.
35. Ware JE, Sherbourne CD. The MOS 36-Item Short-Form Health Survey (SF-36): I. Conceptual framework and item selection. *Med Care* 1992;30:473–83.
36. Bitar AA, Kaplan RJ, Stitik TP, *et al*. Rehabilitation of orthopedic and rheumatologic disorders. 3. Total hip arthroplasty rehabilitation. *Arch Phys Med Rehabil* 2005;86(Suppl 1):56–60.
37. Adell R, Lekholm U, Rockler B, *et al*. A 15-year study of osseointegrated implants in the treatment of the edentulous jaw. *Int J Oral Surg* 1981;10:387–416.
38. Brånemark P-I, Engstrand P, Öhrnell L-O, *et al*. Brånemark Novum®: a new treatment concept for rehabilitation of the edentulous mandible. Preliminary results from a prospective clinical follow-up study. *Clin Implant Dent Relat Res* 1999;1:2–16.
39. Gatti C, Haefliger W, Chiapasco M. Implant-retained mandibular overdentures with immediate loading: a prospective study of ITI implants. *Int J Oral Maxillofac Implants* 2000;15:383–8.
40. Spiekermann H, Jansen VK, Richter E-J. A 10-year follow-up study of IMZ and TPS implants in the edentulous mandible using bar-retained overdentures. *Int J Oral Maxillofac Implants* 1995;10:231–43.

**BMJ Open**

# Single-stage osseointegrated reconstruction and rehabilitation of lower limb amputees: the Osseointegration Group of Australia Accelerated Protocol-2 (OGAAP-2) for a prospective cohort study

Munjed Al Muderis, William Lu, Kevin Tetsworth, Belinda Bosley and Jiao Jiao Li

*BMJ Open* 2017 7:

doi: 10.1136/bmjopen-2016-013508

---

Updated information and services can be found at:

<http://bmjopen.bmj.com/content/7/3/e013508>

---

*These include:*

## References

This article cites 37 articles, 4 of which you can access for free at: <http://bmjopen.bmj.com/content/7/3/e013508#ref-list-1>

## Open Access

This is an Open Access article distributed in accordance with the Creative Commons Attribution Non Commercial (CC BY-NC 4.0) license, which permits others to distribute, remix, adapt, build upon this work non-commercially, and license their derivative works on different terms, provided the original work is properly cited and the use is non-commercial. See: <http://creativecommons.org/licenses/by-nc/4.0/>

## Email alerting service

Receive free email alerts when new articles cite this article. Sign up in the box at the top right corner of the online article.

---

## Topic Collections

Articles on similar topics can be found in the following collections

[Rehabilitation medicine](#) (345)  
[Surgery](#) (447)

---

## Notes

---

To request permissions go to:

<http://group.bmj.com/group/rights-licensing/permissions>

To order reprints go to:

<http://journals.bmj.com/cgi/reprintform>

To subscribe to BMJ go to:

<http://group.bmj.com/subscribe/>