

3-2019

# Diagnosis of B-cell lymphoproliferative disorder through concomitant management of medication-related osteonecrosis of the jaw: A case report

Robert Diecidue

Allen F. Champion


Ruifeng Zhou

James G. Buckley

## Let us know how access to this document benefits you

Follow this and additional works at: <https://jdc.jefferson.edu/omsfp> Part of the [Oral and Maxillofacial Surgery Commons](#)

This Article is brought to you for free and open access by the Jefferson Digital Commons. The Jefferson Digital Commons is a service of Thomas Jefferson University's [Center for Teaching and Learning \(CTL\)](#). The Commons is a showcase for Jefferson books and journals, peer-reviewed scholarly publications, unique historical collections from the University archives, and teaching tools. The Jefferson Digital Commons allows researchers and interested readers anywhere in the world to learn about and keep up to date with Jefferson scholarship. This article has been accepted for inclusion in Department of Oral and Maxillofacial Surgery Faculty Papers by an authorized administrator of the Jefferson Digital Commons. For more information, please contact: [JeffersonDigitalCommons@jefferson.edu](mailto:JeffersonDigitalCommons@jefferson.edu).



## Diagnosis of B-cell lymphoproliferative disorder through concomitant management of medication-related osteonecrosis of the jaw: A case report



Robert Diecidue<sup>a</sup>, Allen F. Champion<sup>a</sup>, Ruifeng Zhou<sup>b</sup>, James G. Buckley<sup>a,\*</sup>

<sup>a</sup> Thomas Jefferson University Hospital, Department of Oral and Maxillofacial Surgery, Philadelphia, PA, USA

<sup>b</sup> Thomas Jefferson University Hospital, Department of Hematology and Oncology, Philadelphia, PA, USA

### 1. Introduction

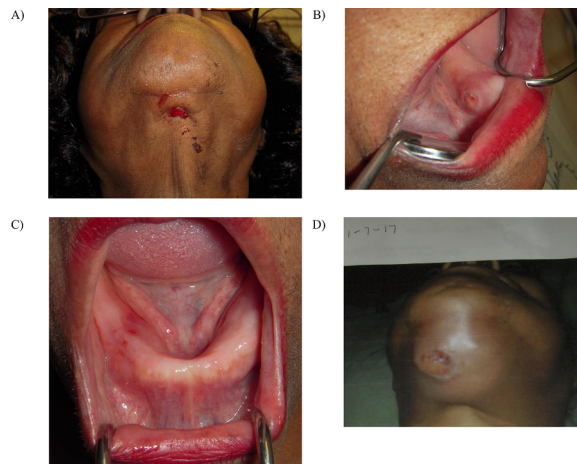
The first description of medication-related osteonecrosis of the jaw (MRONJ) associated with bisphosphonates was published by Marx in 2003 [1]. MRONJ is defined as bone exposed to the oral cavity for at least eight weeks in the maxillofacial region for at least 8 weeks in patients at-risk due to prior or current medication therapy. Over the years, additional medications have been implicated MRONJ beyond bisphosphonates and interdisciplinary strategies for screening and management have shown a reduction in the rate of MRONJ [2]. Despite the increased attention and research, the pathophysiology of MRONJ remains poorly understood. Most cases and reviews published thus far have occurred in patients previously diagnosed with malignant and metastatic disease as bisphosphonate use in these patients reduces the risk of adverse skeletal events such as fractures [3]. We present a case where treatment of MRONJ based on clinical parameters resulted in a subsequent diagnosis of occult B-cell lymphoproliferative disorder.

### 2. Case report

A 79-year-old female presented to the Department of Oral & Maxillofacial Surgery for evaluation of a lesion of the anterior mandible. The patient reported history of non-insulin dependent diabetes mellitus, hypertension, hyperlipidemia, and osteoporosis. Her osteoporosis was treated by her primary care physician with alendronate 70mg weekly for a total duration of five years. Her diabetes was well controlled and she denied history of tobacco use or smoking. She reported dental extractions two years prior to facilitate the fabrication of a complete mandibular denture. Seven months prior to her presentation to our clinic, she developed a large submandibular swelling which resulted in spontaneous submental drainage. She reported she was only treated with antibiotics and the swelling resolved with persistent drainage at a submental site. For the seven months since her infection and initial drainage, she reported persistent drainage of fluid from underneath her chin for which she would use gauze dressings as needed. She denied recent fever, chills, nausea, vomiting, difficulty breathing, or dysphagia.

On clinical exam, she was normocephalic with no appreciable facial asymmetry. In the submental region, she had a slight non-tender swelling with a noted depression associated with granulation tissue (Fig. 1a). The granulation tissue was associated with a chronic fistula which had minimal seropurulent drainage. Intraorally, she was completely edentulous on the maxilla and mandible. She had no swelling of the floor of mouth or posteriorly towards the oropharynx. On the lingual aspect of the left mandible, there was an

\* Corresponding author. 909 Walnut Street 3rd Floor, Philadelphia, PA 19107, USA.  
E-mail address: [james.buckley@jefferson.edu](mailto:james.buckley@jefferson.edu) (J.G. Buckley).



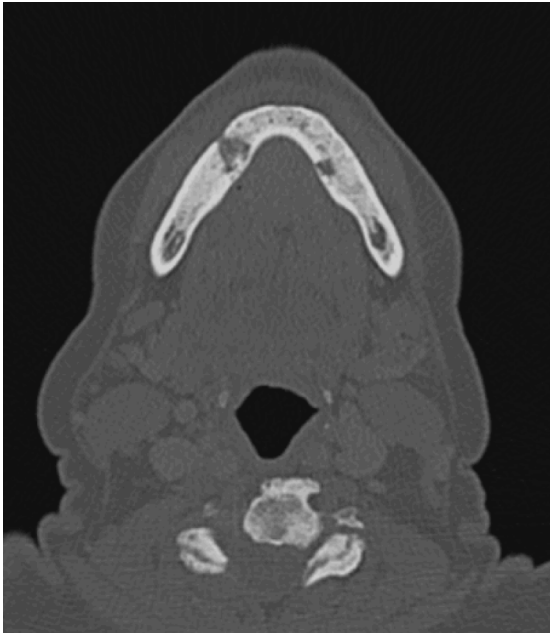
**Fig. 1.** Preoperative Photos A) Worms-eye view of orocutaneous fistula. B) Intraoral view of exposed bone on left mandible C) Intraoral view of orocutaneous fistula D) Patient provided photo of previous swelling months prior to presentation.

area of exposed bone 1cm by 1cm in dimension (Fig. 1b). On the right mandible, there were punctate fistula with seropurulent drainage (Fig. 1c). At that time, cultures were taken of the drainage intraorally and extraorally. A CT Maxillofacial was performed which demonstrated multiple areas of bone erosion involving both sides of the mandible. The erosion of the left mandible was greater than right and there was associated cortical destruction with surrounding sclerosis of the adjacent bone without periosteal reaction. Additionally, there was a linear sequestration along the medial aspect of the left body of mandible (Fig. 2). Based on her history and clinical presentation, she was given a diagnosis of Stage III MRONJ. The patient was started on amoxicillin/clavulanic acid therapy and scheduled for surgical intervention. The cultures returned from the extraoral and intraoral sites were both polymicrobial in nature representing skin and oral flora respectively. Ultimately, the patient was taken to the operating room where she had segmental resection of the involved portion of the anterior mandible with placement of custom designed patient specific plate for mandibular reconstruction (Fig. 3). Given the chronicity of the infection and the fistula, the decision was made not to attempt reconstruction of the area with bone graft at the same time as resection. She was admitted for inpatient management post-operatively. She was evaluated by the Department of Infectious Disease and a peripherally inserted central catheter was placed in anticipation of an extended duration of intravenous antibiotics. The cultures from surgery grew *Enterobacter cloacae*. She tolerated the procedure and was discharged to home two days after the procedure with intravenous ertapenem therapy for a planned 6-week duration. Histopathologic analysis performed on the resection specimen revealed viable and non-viable bone with an unanticipated finding of chronic plasmacytic infiltration. The specimen showed a predominantly plasmacytic inflammatory infiltrate arranged in “sheets” in some areas (Fig. 4). The increased number of plasma cells and their growth pattern was concerning for a plasma cell dyscrasia. In situ hybridization for kappa and lambda light chain was noncontributory due to prior decalcification of the specimen. The findings prompted referral to the Department of Hematology/Oncology for further workup. A full skeletal series and long bone survey was performed which revealed no lytic lesions. A complete blood count with differential was within normal limits. The beta-2 microglobulin was negative. SPEP demonstrated faint bands in IgG and lambda. The free light chain ratio was elevated in both the serum and urine analyses. The serum kappa/lambda ratio was high at 3.19 and the urine kappa/lambda ratio was 82.27. Ultimately, a bone marrow biopsy was performed. The core biopsy showed mild increase in small mature B-cells. Immunohistochemistry for CD20 and PAX-5 shows a predominance of B cells involving 5–10% of marrow (Fig. 5). Concurrent flow cytometry detected an CD5+/CD23 + clonal B-cell population with kappa light chain restriction. This phenotype was consistent with chronic lymphocytic leukemia/small lymphocytic lymphoma (CLL/SLL). A concurrent FISH study identified a deletion of RB1 and concurrent karyotype demonstrated no abnormalities (Fig. 6). The patient was ultimately diagnosed with CD5<sup>+</sup> B cell lymphoproliferative disorder. She continued active surveillance with oncology for transformation or change of disease. From a surgical standpoint, the patient healed without issue and demonstrated resolution of chronic infection and draining fistula post operatively (Figs. 7 and 8).

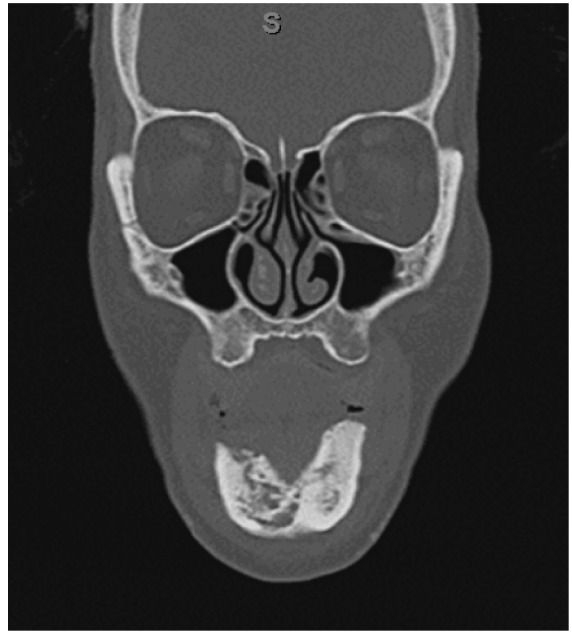### 3. Discussion

Although MRONJ is related to antiresorptive therapy for many different diseases including blood dyscrasias, it is infrequently found concomitant with the disease process. There have been a few case reports of concurrent metastatic disease, including multiple myeloma and breast cancer, in resection specimens for MRONJ [4–6]. Carlson et al. [7] performed a large retrospective study to identify patients treated for MRONJ with resection on IV bisphosphonate therapy for cancer with metastatic disease found in the resection specimens. The prevalence of cancer detected in the MRONJ specimens of this group was 5.3%, with multiple myeloma as the predominant associated metastasis [7]. In the setting of cancer with metastases to bone and lytic lesions of multiple myeloma, IV bisphosphonate therapy is supported in various guidelines to reduce the rate of pathologic fractures and morbidity from interventions

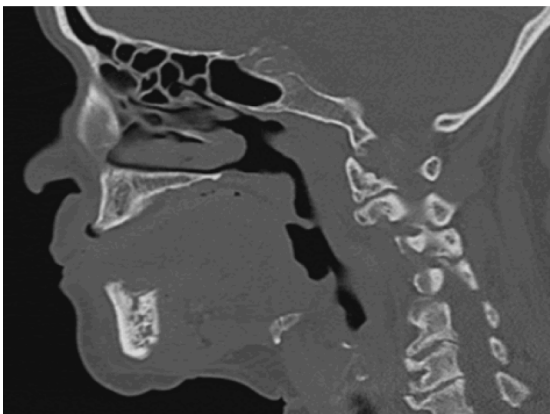
A)



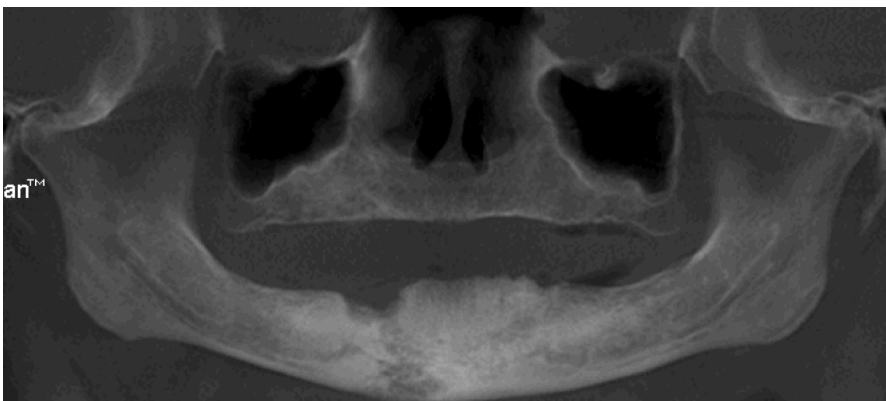
B)



C)

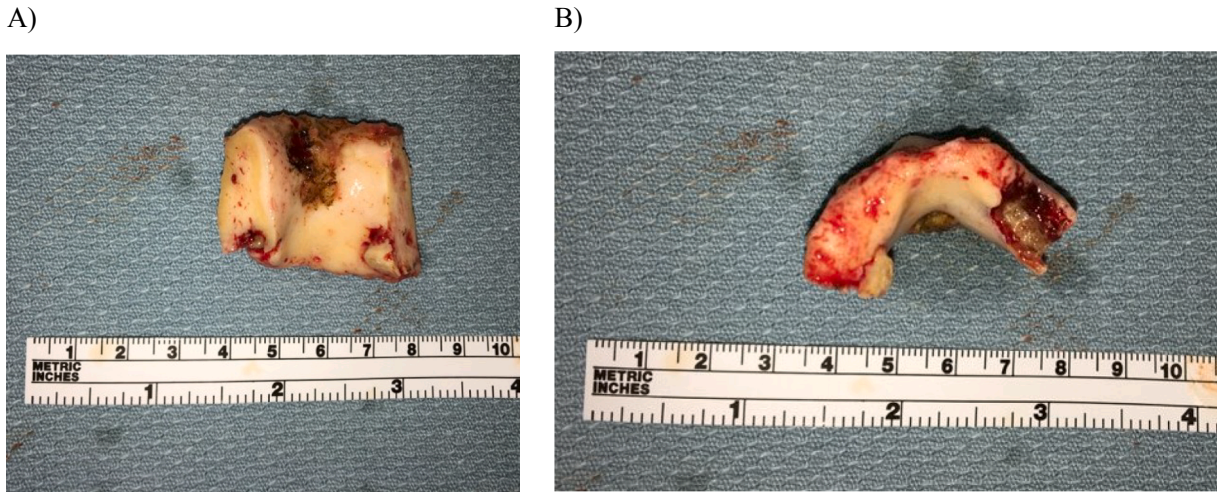


D)

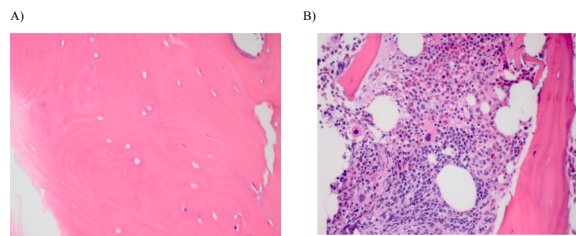


(caption on next page)

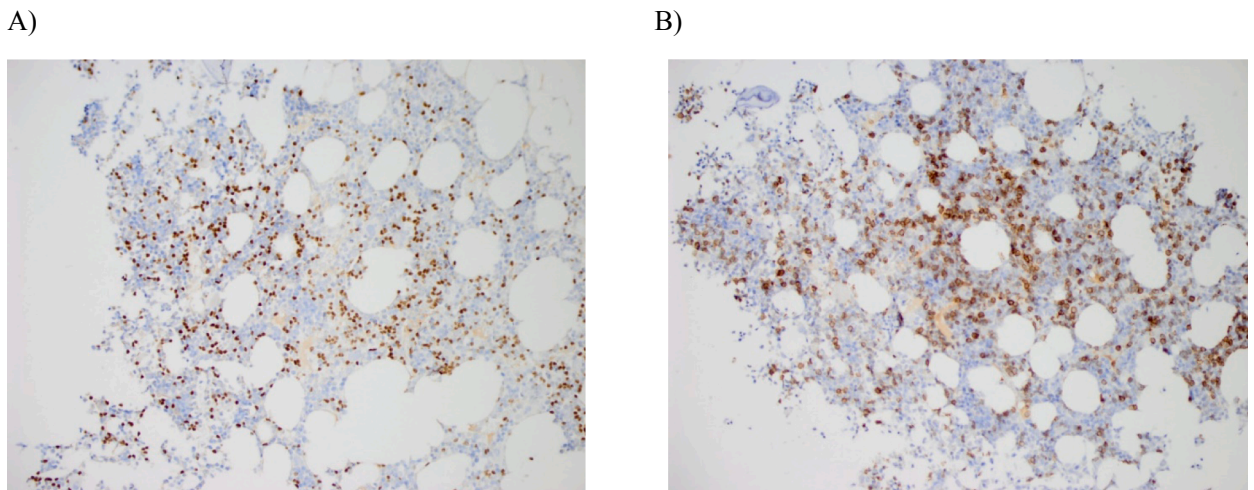
**Fig. 2.** Pre-operative radiographs. A CT maxillofacial bony window with representative axial (A), coronal (B), and sagittal cuts. D) Panoramic radiograph.



**Fig. 3.** Intraoperative photos of resected specimen from posterior (A) and superior (B) views.



**Fig. 4.** Histopathological evaluation with hematoxylin and eosin stains. A) Biopsy specimen showing necrotic bony trabeculae, with empty lacunae in the top of the frame compared with viable osteocytes in the lower right corner. B) Bone marrow core biopsy showing a lymphoid aggregate comprised of monomorphic population of small mature lymphocytes. Note trilineage hematopoiesism in background (H&E, original magnification 400 $\times$ ).



**Fig. 5.** Immunohistochemical evaluation of bone marrow biopsy specimens. A) Pax-5 stain highlights B-cells in the interstitium and loose aggregates in bone marrow core biopsy B) CD5 stain in the bone marrow core biopsy shows similar distribution to B-cells (original magnification 400 $\times$ ).

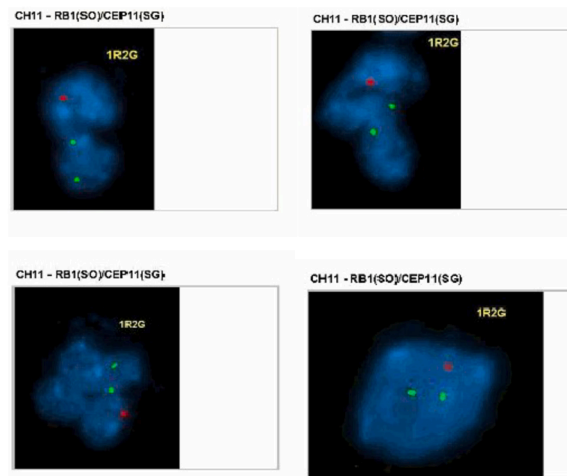


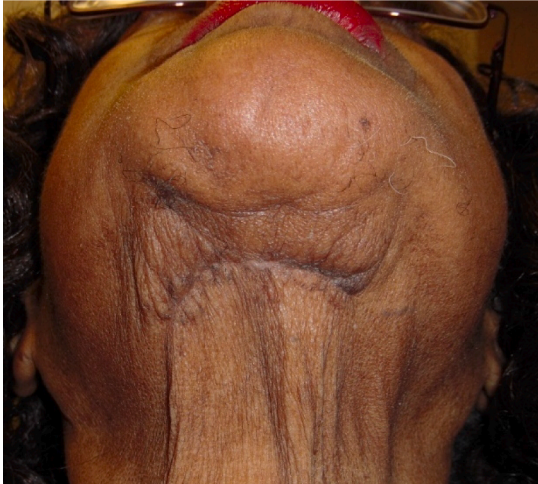Fig. 6. Fluorescence In-Situ Hybridization of bone marrow biopsy demonstrating positive deletion of RB1.

for bone pain [3,8]. The current American Association of Oral and Maxillofacial Surgeons (AAOMS) position paper on MRONJ considers the role of anti-angiogenic medications in disease progression in addition to anti-resorptive medications such as bisphosphonates [2]. Since the position paper update, there have been a few case reports of MRONJ from disease modifying antirheumatic drugs (DMARDs) and immunosuppressive medications used after organ transplant [9,10]. A recent case series demonstrates a case of MRONJ in the setting of treatment of chronic lymphocytic leukemia with antiresorptive agents and targeted therapy with tyrosine kinase inhibitors [11]. Aghaloo and Tetradis [12] reported a case series of six patients with MRONJ without antiangiogenic or antiresorptive medications, rather the use of various anti-rheumatic agents with Stage II and III MRONJ.

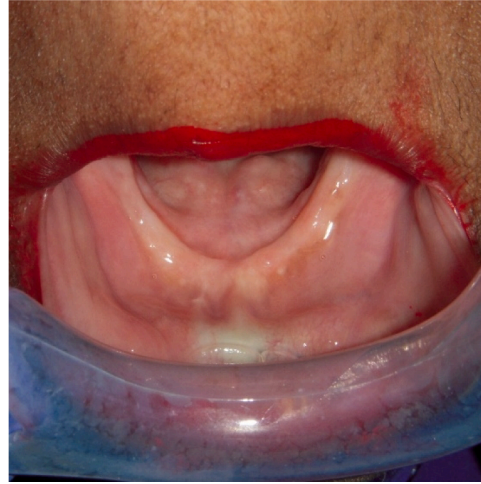Interestingly, methotrexate and rituximab are associated with iatrogenic lymphoproliferative disorders [13,14]. Our patient was ultimately diagnosed with a CD5<sup>+</sup> B cell lymphoproliferative disorder as she did not meet the diagnostic criteria for chronic lymphocytic leukemia and she demonstrated deletion of RB1, a frequent chromosomal abnormality found in B-cell lymphoproliferative disorders [15]. Her presentation was similar to monoclonal B-cell lymphocytosis; however, she did not meet the diagnostic criteria due to the presence of chronic infection [16]. Monoclonal B-cell lymphocytosis is considered a precursor condition to chronic lymphocytic leukemia similar to monoclonal gammopathy of undetermined significance (MGUS) is a precursor condition to multiple myeloma [17, 18]. Evidence suggests that precursor conditions such as MGUS which were initially thought to not have clinical implications are associated with increased rates of adverse skeletal events [19].

Our patient had a clear history of bisphosphonate-use and met the established criteria for MRONJ. However, her bisphosphonate use was limited to the oral bisphosphonate agent alendronate. Nitrogen-containing bisphosphonates such as alendronate, have been shown to trigger the release of pro-inflammatory mediators such as IL-6 and TNF $\alpha$  from osteoclasts. An in vivo study demonstrated bisphosphonate-treated osteoclasts survive longer than untreated osteoclasts as they are not subject to the cytotoxic effects of natural killer cells. The longer survival time may contribute to chronic inflammation in areas of bone turnover [20]. A large retrospective study of patients with chronic oral bisphosphonate therapy identified a low prevalence of MRONJ at 0.10% [21]. Other factors identified to increase the risk of MRONJ with oral bisphosphonate-use includes dental extraction, smoking, poorly-controlled diabetes, atherosclerosis, and steroid-use [22]. The additional risk factors for our patient only included history of dental extractions. Given the low prevalence of MRONJ with oral bisphosphonates and case reports that have implicated medications associated with iatrogenic lymphoproliferative disorders in MRONJ, is it unclear how our patient's undiagnosed lymphoproliferative disorder may have contributed to her development of stage III MRONJ. Of note, the plasmocytic infiltration was seen outside of the area of necrotic bone and was included in the specimen due to segmental resection. In a review of margin analysis for MRONJ, Qaisi and Montague [23] discuss the need for representative samples of the resected bone to evaluate for underlying pathology contributing to bone destruction. In addition, there is difficulty in establishing a clear margin or additional pathologic processes with pathology specimens from conservative debridements [23]. It is possible in our case the association of the clonal population in the MRONJ resection specimen was serendipitous and unrelated to her MRONJ progression. If so, the treatment allowed her to obtain a diagnosis before the manifestation of symptoms and enter active surveillance to monitor for transformation. However, there is evidence in the form of case series and case reports reviewed to suggest that lymphoproliferative disorders may play a yet undermined role in some forms of MRONJ. MRONJ in the setting immunosuppressant agents could represent an intramedullary manifestation of iatrogenic immunodeficiency-associated lymphoproliferative disorders. In much the same way that intravenous and oral bisphosphonate regimens have different risk profiles for the development of MRONJ, it could be that different forms of lymphoproliferative disorders factor differently into the MRONJ scenario [2,24]. Additional research is needed to elucidate possible interplay between lymphoproliferative disorders and osteonecrosis of the jaw.

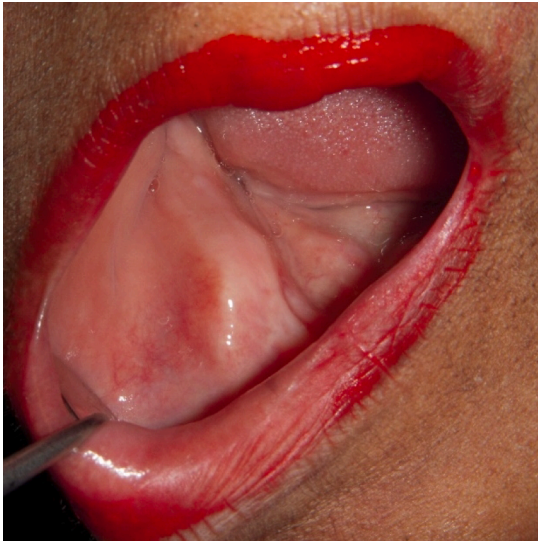A)



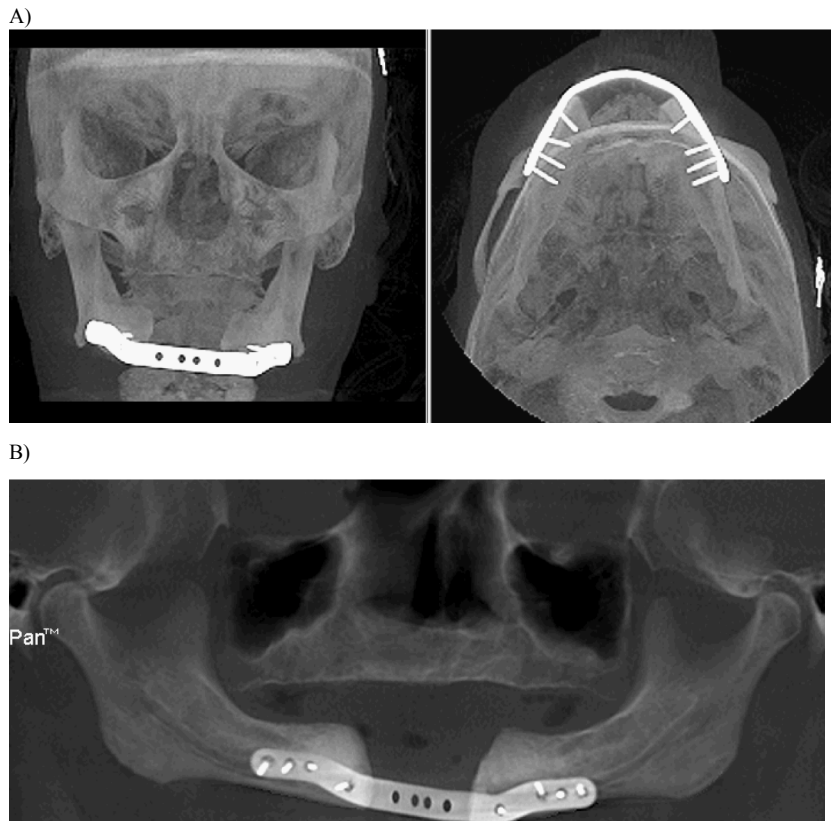B)



C)



**Fig. 7.** Post-Operative Photos A) Worms-eye view of extraoral scar from mandibular resection B) Intraoral view of mandibular resection site C) Intraoral view of healed orocutaneous fistula site.



**Fig. 8.** Post-operative radiographs. A CBCT maxillofacial A) 3-D rendering of bony window B) Panoramic radiograph after 4 months.

## References

- [1] Marx RE. Pamidronate (Aredia) and zoledronate (Zometa) induced avascular necrosis of the jaws: a growing epidemic. *J Oral Maxillofac Surg* 2003;61(9): 1115–7.
- [2] Ruggiero Salvatore L, Dodson Thomas B, Fantasia J, Goodday Reginald, Aghaloo Tara, Mehrotra B, et al. American association of oral and maxillofacial Surgeons position paper on medication-related osteonecrosis of the jaw—2014 update. *J Oral Maxillofac Surg* 2014;72(10):1938–56.
- [3] Anderson Kenneth, Ismaila Nofisat, Flynn Patrick J, Halabi Susan, Jagannath Sundar, Ogaily Mohammed S, et al. Role of bone-modifying agents in multiple myeloma: American society of clinical oncology clinical practice guideline update. *J Clin Oncol : Off J Am Soc Clin Oncol* 2018 Mar 10;36(8):812–8.
- [4] DeSesa CR, Appugounder Suganya, Haberland Christel, Johnson MP. Osteonecrosis of the jaw in association with chemotherapy in the setting of cutaneous T-cell lymphoma. *J Oral Maxillofac Surg* 2016;74(2):292–301.
- [5] Gander Thomas, Obwegeser Joachim A, Zemmann Wolfgang, Grätz Klaus-Wilhelm, Jacobsen Christine. Malignancy mimicking bisphosphonate-associated osteonecrosis of the jaw: a case series and literature review. *Oral Surg Oral Med Oral Pathol Oral Radiol* 2014;117(1):32–6.
- [6] Otto S, Schreyer C, Hafner S, Mast G, Ehrenfeld M, Stürzenbaum S, et al. Bisphosphonate-related osteonecrosis of the jaws – characteristics, risk factors, clinical features, localization and impact on oncological treatment. *J Cranio-Maxillo-Fac Surg* 2011;40(4):303–9.
- [7] Carlson Eric R, Fleisher KE, Ruggiero Salvatore L. Metastatic cancer identified in osteonecrosis specimens of the jaws in patients receiving intravenous bisphosphonate medications. *J Oral Maxillofac Surg* 2013;71(12):2077–86.
- [8] Carlson R, et al. Breast cancer. *J Natl Compr Canc Netw* 2009 February;7(2):122–92.
- [9] Allegra A, Oteri G, Alonci A, Bacci F, Penna G, Minardi V, et al. Association of osteonecrosis of the jaws and POEMS syndrome in a patient assuming rituximab. *J Cranio-Maxillo-Fac Surg* 2013;42(4):279–82.
- [10] Henien M, Carey B, Hullah E, Sproat C, Patel V. Methotrexate-associated osteonecrosis of the jaw: a report of two cases. *Oral Surg Oral Med Oral Pathol Oral Radiol* 2017 Dec;124(6):e287.
- [11] Abel Mahedi Mohamed H, Nielsen CEN, Schiodt M. Medication related osteonecrosis of the jaws associated with targeted therapy as monotherapy and in combination with antiresorptives. A report of 7 cases from the Copenhagen Cohort. *Oral Surg Oral Med Oral Pathol Oral Radiol* February 2018;125(2):157–63.
- [12] Aghaloo Tara L, Tetradis Sotirios. Osteonecrosis of the jaw in the absence of antiresorptive or antiangiogenic exposure: a series of 6 cases. *J Oral Maxillofac Surg* 2016;75(1):129–42.
- [13] Keribin P, Guerrot D, Jardin F, Moizan H. Osteonecrosis of the jaw in a patient presenting with post-transplantation lymphoproliferative disorder treated with rituximab: a case report. *J Oral Maxillofac Surg : Off J Am Assoc Oral Max Surg* December 2017;75(12):2599–605.
- [14] Yoshida Y, Takahashi Y, Yamashita H, Kano T, Kaneko H, Mimori A. Clinical characteristics and incidence of methotrexate-related lymphoproliferative disorders of patients with rheumatoid arthritis. *Mod Rheumatol* 2014 Sep;24(5):763–5.
- [15] Struski S, Helias C, Gervais C, Audhuy B, Zamfir A, Herbrecht R, et al. 13q deletions in B-cell lymphoproliferative disorders: frequent association with translocation. *Cancer Genet Cytogenet* 2007;174(2):151–60.
- [16] Marti GE, Rawstron AC, Ghia P, Hillmen P, Houlston RS, Kay N, et al. Diagnostic criteria for monoclonal B-cell lymphocytosis. *Br J Haematol* 2005 Aug;130(3): 325–32.
- [17] Strati P, Shanafelt TD. Monoclonal B-cell lymphocytosis and early-stage chronic lymphocytic leukemia: diagnosis, natural history, and risk stratification. *Blood* 2015 Jul 23;126(4):454–62.
- [18] Wadhera RK, Rajkumar SV. Prevalence of monoclonal gammopathy of undetermined significance: a systematic review. *Mayo Clin Proc* 2010;85(10):933–42.



- [19] Drake MT. Unveiling skeletal fragility in patients diagnosed with MGUS: No longer a condition of undetermined significance? *J Bone Miner Res* 2014 Dec;29(12):2529–33.
- [20] Tseng H, Kanayama K, Kaur K, Park S, Park S, Kozłowska A, et al. Bisphosphonate-induced differential modulation of immune cell function in gingiva and bone marrow in vivo: role in osteoclast-mediated NK cell activation. *Oncotarget* 2015 Aug 21;6(24):20002–25.
- [21] Lo JC, O’Ryan FS, Gordon NP, Yang J, Hui Rita L, Martin D, et al. Prevalence of osteonecrosis of the jaw in patients with oral bisphosphonate exposure. *J Oral Maxillofac Surg* 2010;68(2):243–53.
- [22] Assael LA. Oral bisphosphonates as a cause of bisphosphonate-related osteonecrosis of the jaws: clinical findings, assessment of risks, and preventive strategies. *J Oral Maxillofac Surg* 2009;67(5):35–43.
- [23] Qaisi M, Montague L. Bone margin analysis for osteonecrosis and osteomyelitis of the jaws. *Oral Maxillofac Surg Clin* 2017 Sep 10:921.
- [24] Swerdlow SH, Campo E, Pileri SA, Harris NL, Stein H, Siebert R, et al. The 2016 revision of the World Health Organization classification of lymphoid neoplasms. *Blood* 2016 May 19;127(20):2375–90.