



Thomas Jefferson University
Jefferson Digital Commons

Department of Obstetrics and Gynecology Faculty
Papers

Department of Obstetrics and Gynecology

7-1-2018

Pregnancies complicated by maternal osteogenesis imperfecta type III: a case report and review of literature.

Tetsuya Kawakita
MedStar Washington Hospital Center

Melissa Fries
MedStar Washington Hospital Center

Jasbir Singh
Austin Maternal Fetal Medicine

Huda B. Al-Kouatly
Thomas Jefferson University, huda.al-kouatly@jefferson.edu

[Let us know how access to this document benefits you](#)

Follow this and additional works at: <https://jdc.jefferson.edu/obgynfp>

 Part of the [Obstetrics and Gynecology Commons](#)

Recommended Citation

Kawakita, Tetsuya; Fries, Melissa; Singh, Jasbir; and Al-Kouatly, Huda B., "Pregnancies complicated by maternal osteogenesis imperfecta type III: a case report and review of literature." (2018).


Department of Obstetrics and Gynecology Faculty Papers. Paper 47.

<https://jdc.jefferson.edu/obgynfp/47>

This Article is brought to you for free and open access by the Jefferson Digital Commons. The Jefferson Digital Commons is a service of Thomas Jefferson University's [Center for Teaching and Learning \(CTL\)](#). The Commons is a showcase for Jefferson books and journals, peer-reviewed scholarly publications, unique historical collections from the University archives, and teaching tools. The Jefferson Digital Commons allows researchers and interested readers anywhere in the world to learn about and keep up to date with Jefferson scholarship. This article has been accepted for inclusion in Department of Obstetrics and Gynecology Faculty Papers by an authorized administrator of the Jefferson Digital Commons. For more information, please contact: JeffersonDigitalCommons@jefferson.edu.

CASE REPORT

Pregnancies complicated by maternal osteogenesis imperfecta type III: a case report and review of literature

Tetsuya Kawakita¹ , Melissa Fries¹, Jasbir Singh² & Huda B. Al-Kouatly^{1,3}

¹Obstetrics and Gynecology, MedStar Washington Hospital Center, Washington, District of Columbia

²Obstetrics and Gynecology, Austin Maternal Fetal Medicine, Austin, Texas

³Obstetrics and Gynecology, Sidney Kimmel Medical College, Thomas Jefferson University, Philadelphia, Pennsylvania

Correspondence

Tetsuya Kawakita, Obstetrics and Gynecology, MedStar Washington Hospital Center, 110 Irving Street, NW, Suite 5B-45, Washington, DC 20010. Tel: +1-202-877-8035; Fax: +1-202-877-5435; E-mail: tetsuya.x.kawakita@gmail.com

Funding Information

No sources of funding were declared for this study.

Received: 5 February 2018; Revised: 22 March 2018; Accepted: 3 April 2018

Clinical Case Reports 2018; **6(7)**: 1252–1257

doi: 10.1002/ccr3.1549

Introduction

Osteogenesis imperfecta (OI) is a rare inherited connective tissue disease. We present two pregnancies of a patient with OI Type III, with severe scoliosis, and restrictive lung disease whose pregnancies were complicated by frequent admissions for pneumonia and respiratory distress, resulting in iatrogenic preterm delivery.

Osteogenesis imperfecta (OI) is a rare inherited disease of connective tissue that primarily involves the abnormal synthesis of collagen, consisting of bone and many other connective tissues [1]. OI is known as “Brittle bone disease,” which occurs when collagen is made of insufficient quality or quantity. The clinical phenotype is broad and ranges from a mild type (moderate increase in fracture frequency) to a severe type (lethal in the perinatal period).

Several cases of OI in pregnancy have been emphasizing the importance of the skeletal abnormalities in the pregnant female. Complications reported in the literature include pelvic contractures that lead to cesarean delivery,

Key Clinical Message

The restrictive lung disease can be exacerbated by growing fundus in women with osteogenesis imperfecta type III. Regional anesthesia can be performed in these women. Mode of delivery for women with osteogenesis imperfecta type III is generally cesarean delivery. Neonatal outcomes are complicated due to indicated preterm deliveries.

Keywords

Osteogenesis imperfecta, preterm delivery, restrictive lung disease, skeletal deformity.

an increased basal metabolic rate leading to hyperthermia, and uterine rupture in labor [2–5].

Case History/Examination

Maternal medical history

We present two consecutive pregnancies of a patient who had the common manifestation of type III OI, kyphoscoliosis, leading to respiratory complications. Maternal DNA sequence analysis for type 1 collagen genes (COL1A1 and COL1A2), revealed a single nucleotide substitution in one allele of the COL1A1 gene (c.2596G>A) consistent with OI type III (Fig. 1) [6]. Her medical history was significant for skeletal deformities secondary to multiple long bone fractures. She was wheelchair bound, had blue sclera, contracted hips and pelvis, severe scoliosis with distortion of the chest (right breast rotated anteriorly to mid-chest), lordosis limiting abdominal expansion, and marked anterior bowing of the tibiae (Fig. 2). The patient also suffered from

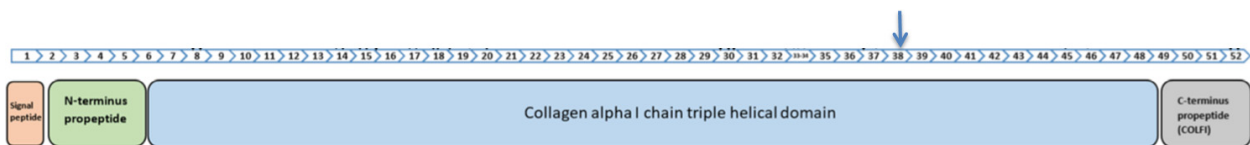

Figure 1. Diagram of the COL1A1 exons. The blue arrow points to the mutation our patient had in one allele of the COL1A1 gene (c.2596G>A) at exon 38.

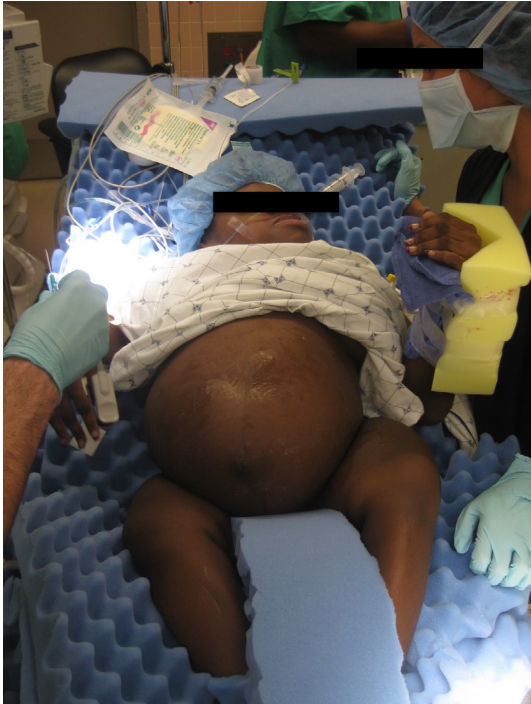

Figure 2. Severe anterior bowing of tibiae.

restrictive lung disease due to severe kyphoscoliosis (Fig. 3) with associated chest wall deformities and severe asthma. She has had multiple admissions during her lifetime for recurrent pneumonia. Her longtime steroid use (Prednisone 10 mg daily) for lung disease caused her to suffer from steroid induced diabetes mellitus. Maternal-fetal medicine physicians followed both of her pregnancies.

Pregnancy No. 1

She initially presented at 8 weeks' gestation for prenatal care when she was 23 years old. Her height, weight, and body mass index (BMI kg/m²) were 96 cm, 25 kg, and 27.1 kg/m², respectively (Fig. 4). She had a mediport placed the year prior due to a prolonged hospital course secondary to pneumonia and difficulty swallowing tablets. On physical examination, she was noted to be very short stature. She measured 17 cm from her iliac crest to her

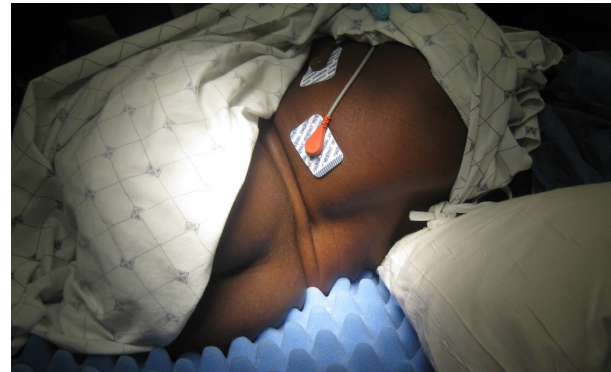

Figure 3. Severe kyphoscoliosis.

C-7 prominence. Auscultation of her lungs was unremarkable and oxygen saturation was 97% on room air. A previous chest radiograph was available for review, showing severe scoliosis (Fig. 5).

Her first trimester screening with nuchal translucency (Down syndrome 1 in 999 [background risk], <1 in 10,000 [screening risk]; Trisomy 18 1 in 1956 [background risk], <1 in 10,000 [screening risk]), infection screening (hepatitis, human immunodeficiency virus, and syphilis), hematologic and coagulation studies were within normal limits. Chorionic villus sampling performed at 14 weeks' gestation revealed a fetus unaffected by OI. A maternal echocardiogram was within normal limits. Detailed anatomy scan was performed at 22 weeks' gestation by maternal-fetal medicine physician at our tertiary care center, showing normal anatomy. At our institution, ultrasound scans are performed according to ISUOG (International Society of Ultrasound in Obstetrics and Gynecology) guidelines.

As the patient's pregnancy progressed, continuing fetal growth further restricted her pulmonary capacity. She progressively had positional dyspnea and inability to sleep in the supine position. Bilevel positive airway pressure (BPAP) at night and O₂ via nasal cannula during the day were started but only provided temporary relief. At 27 weeks' gestation, the patient presented again to the emergency room extremely agitated by her progressive dyspnea. Tachypnea was noted on presentation with a respiratory rate of 30–40 breaths per

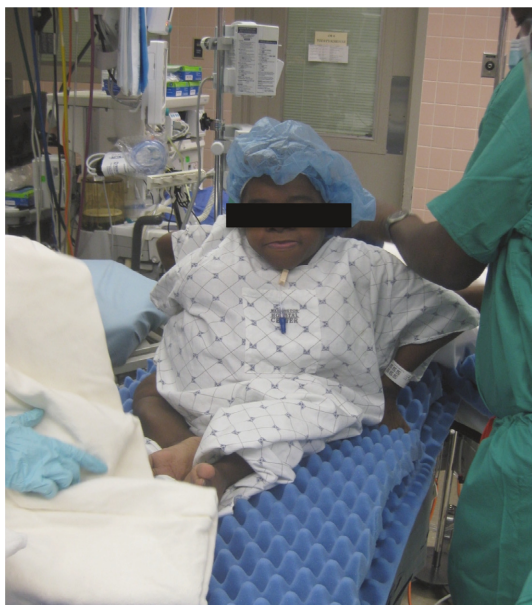

Figure 4. The external appearance of the patient with type III osteogenesis imperfecta.

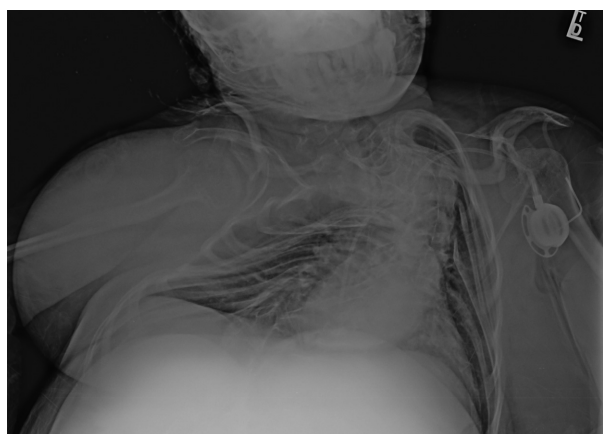


Figure 5. Chest radiograph. Chest radiograph showing severe scoliosis.

minute. An arterial blood gas revealed a pH of 7.41, $p\text{CO}_2$ of 32 mm of Hg, $p\text{O}_2$ of 179 mm of Hg, and bicarbonate of 20 mmol/L. In consultation with pulmonary medicine, no evidence was present to suggest an acute infectious process. Her symptoms were due to her worsening restrictive lung disease secondary to the gravid uterus.

A panel of pulmonary medicine, neonatology, anesthesia, maternal-fetal medicine, and ethics providers met to discuss the challenges of ongoing pregnancy in this complicated patient and any potential delivery complications. Risks associated with preterm delivery such as respiratory

distress syndrome, retinopathy, bronchopulmonary dysplasia, sepsis, necrotizing enterocolitis, intraventricular hemorrhage, hypoglycemia, hyperbilirubinemia, impaired cognitive skills, cerebral palsy, and sensory impairment including vision and hearing losses were discussed with the patient. The consensus was that delivery was indicated based on a concern over potential respiratory collapse with the recommendation for cesarean delivery at 28 weeks' gestation after administration of a course of betamethasone 12 mg. A regional anesthetic was recommended, via fluoroscopy if needed, in order to avoid any of the numerous complications anticipated with a general anesthetic. Concern was raised for securing an airway in a patient with a reduced range of motion of cervical spine movement, poor dentition, and who was prone to fractures and malignant hyperthermia.

The patient underwent cesarean section at 28 weeks' gestation under epidural anesthesia. Before regional anesthesia was attempted, direct laryngoscopy under topical anesthesia of the oral pharynx was performed to assess ease of intubation should a regional block fail or ascend too high as to cause respiratory insufficiency. The anesthesia provider was able to successfully place a regional anesthetic using bupivacaine without the use of fluoroscopy. Foam padding was required to ensure neutral positioning of her limbs and support the angulation of her pelvis (Fig. 6). Once positioned, it was apparent that her lower abdomen was not well exposed. A classical cesarean section was performed through a transverse infra-umbilical skin incision (Fig. 7) with the delivery of an infant female that weighed 970 g with APGAR score of 4 and 7 after 1 and 5 min, respectively. The umbilical artery blood gas showed pH 7.30, bicarbonate 24.6 mmol/L, and base excess 0.0 mEq. The neonate stayed in the neonatal intensive care unit for 71 days. She did have respiratory distress syndrome and bronchopulmonary dysplasia but did not have complications of retinopathy, sepsis, necrotizing enterocolitis, or intraventricular hemorrhage. She was discharged home. The patient experienced a blood loss of 750 mL. Considering her short stature, this was interpreted as a significant percentage of her total blood volume. She received one unit of packed red blood cells intraoperatively. Patient-controlled analgesia (PCA) with hydromorphone was used for pain control until postoperative day 1. In the immediate postoperative period, the patient reported a marked improvement in her comfort and respiratory status. She no longer required any supplemental oxygen. The patient had the appropriate return of bowel and bladder function and was discharged home on postoperative day five. Prior to discharge, a subcutaneous progesterone implant was placed in her arm for contraception.

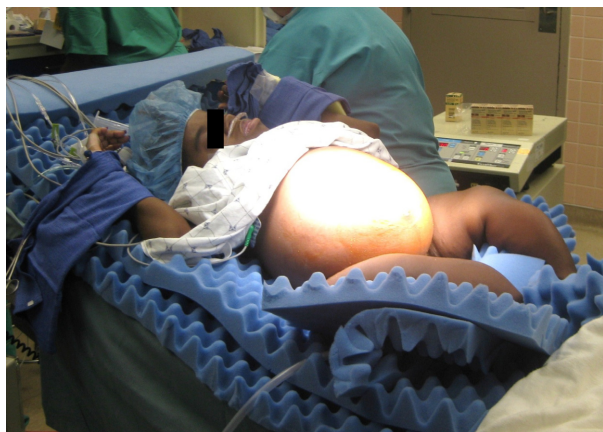

Figure 6. Patient positioning and padding at time of cesarean delivery.

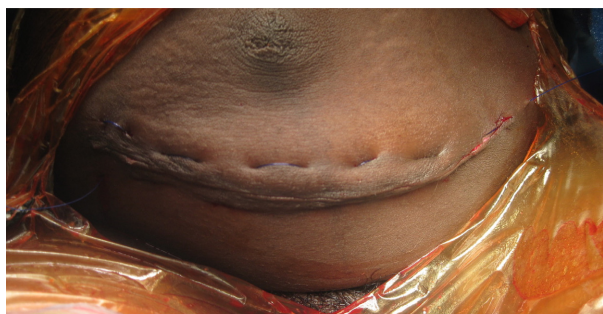

Figure 7. Infra-umbilical skin incision.

Pregnancy No. 2

Three years later, she presented at 8 weeks' gestation for prenatal care. Her height, weight, and BMI were 81 cm, 27.2 kg, and 41.5 kg/m², respectively. Her restrictive lung disease was worse, requiring home BPAP. She had anti-Kell antibody (1:8), which she did not have in the previous pregnancy. Paternal genetic testing was declined. Middle cerebral artery Doppler was performed and was within normal limits until delivery. Her prenatal labs included normal first trimester screening with nuchal translucency (Down syndrome 1 in 905 [background risk], <1 in 10,000 [screening risk]; Trisomy 18 1 in 1,633 [background risk], <1 in 10,000 [screening risk]). Amniocentesis was performed which showed 46,XX and no COL1A1 mutation. A maternal echocardiogram was within normal limit.

Her first trimester was complicated by hyperemesis gravidarum requiring two hospital admissions and urinary tract infection (UTI). Since 19 weeks' gestation, she started to feel shortness of breath, which was much earlier than previous pregnancy. Her worsening respiratory

distress was thought to be growing the uterine size and limited pulmonary capacity because of her worsening severe scoliosis. She was 15 cm shorter with the second pregnancy. Detailed anatomy scan was performed at 21 weeks' gestation by maternal-fetal medicine physician at our tertiary care center, showing normal anatomy. At 22 weeks' gestation, she presented with worsening shortness of breath and frequent contractions. She was diagnosed with pneumonia. She declined admission and was discharged with ceftriaxone 1 g IV daily through her mediport.

At 24 weeks' gestation, she presented with respiratory distress. Her respiratory rate was 50 and oxygen saturation was 85%. Respiratory therapist and pulmonologist were consulted. She was treated with oxygen by nasal cannula, nebulizer therapy every 6 h, and corticosteroid inhaler in addition to BPAP. Chest X-ray did not show evidence of pneumonia. She also started to have frequent painful uterine contractions. The digital cervical exam was performed, showing no cervical dilation. However, due to her pelvic anatomy displacement, her cervix was difficult to access. Due to her worsening respiratory distress, early delivery was thought to be imminent. She received a course of betamethasone 12 mg.

At 25 weeks' gestation, she became progressively fatigued from her work of breathing. Early delivery at 27 weeks' gestation after the second course of betamethasone was planned. As her previous pregnancy, the discussion was made with pulmonologists, anesthesiologists, neonatologists, and ethics providers. Risks of prematurity were discussed with her as the previous pregnancy. Regional anesthesia was recommended. Because of possible difficult anesthesia, respiratory complications, and risk of bleeding, the patient made an advance directive.

On the day of cesarean delivery, she received magnesium for neuroprophylaxis (6-gram bolus followed by 2 g per hour). Epidural placement was tried twice without success. Spinal anesthesia with bupivacaine was successful. The high classical uterine incision was made. A 730 g baby girl with APGAR score of 3, 5, and 6 after 1, 5, and 10 min, respectively, was delivered. The umbilical artery blood gas showed pH 7.20, bicarbonate 11.6 mmol/L, and base excess 0.0 mEq. The neonate did not have sepsis or necrotizing enterocolitis. She had respiratory distress syndrome and bronchopulmonary dysplasia. In addition, she had grade 3 right intraventricular hemorrhage and grade 4 left intraventricular hemorrhage. She stayed in the neonatal intensive care unit for 99 days. During her stay, she did not have seizures or shunt procedure. However, she was transferred to another institution for further neurological work-up.

Cesarean section was completed with a blood loss of 700 mL, which required one unit of red blood cell. She underwent bilateral tubal ligation as she wished. Again,

PCA with hydromorphone was used for pain control until postoperative day 1. Her respiratory status dramatically improved postoperatively. She was discharged on postoperative day nine.

Discussion

The most common cause of OI is gene mutations encoding alpha-1 and alpha-2 chains of type 1 collagen or proteins modifying type 1 collagen. Type 1 collagen is an important structure for bone, tendon, ligament, skin, and sclera. A common presentation of OI includes brittle bones, short stature, scoliosis, hearing loss, and blue sclera.

Sillence *et al.* [7] proposed four types of clinical classification. Type I is the most common and mildest form with a variable fracture rate. Patients with type I OI usually have minimal deformity and normal stature, and often have a hearing impairment. Type II OI is lethal in uterus or shortly after birth. Typical causes of death include severe fractures and pulmonary failure. Type III, which this patient suffered from, is most severe form and patients have marked deformity of the limbs and marked kyphoscoliosis, thorax deformity, and significant short stature. Type III OI is a rare disease with an incidence of 1/70,000 and there are few case reports of maternal type III OI [4, 5, 7]. Distortion of spine and thorax can lead to restrictive lung disease and sleep apnea syndrome. Pulmonary insufficiency is a leading cause of death in patients with type III OI. Patient with type IV OI have mild to moderate bone fragility.

Fertility is preserved in patients with OI and there are several case reports on maternal OI in pregnancy. Several complications are reported, including respiratory insufficiency, difficult anesthesia management, pelvic pain, increased risk of cesarean section and uterine rupture [2–5].

Pulmonary insufficiency is the most common cause of demise in Type II OI and affects a number of individuals with the more severe Type III OI. This process may progress to pulmonary hypertension and subsequent cor pulmonale, requiring oxygen support. Our case highlights the respiratory complications of OI and how the growing fundus exacerbated the restrictive lung disease. In this patient, worsening respiratory condition was ultimately the factor that led to her preterm delivery at 28 weeks' gestation and 27 weeks' gestation. Perhaps the occurrence of respiratory complications at an earlier gestational age was due to the worsening skeletal abnormalities and scoliosis over 3 years. The patient did lose 15 cm in height during this time period.

Anesthesia for patients with OI presents challenges, such as airway control, hemostasis, difficult insertion of

regional anesthesia, increased risk of perioperative hyperthermia, and respiratory insufficiency from the deformed thoracic cavity. Airway management in patients with OI can be challenging in terms of the difficult airway, increased risk for odonto-axial dislocation, brittle teeth and weak cervical and mandibular bones [4]. Higher risk of perioperative hyperthermia has been reported [5]. This case illustrates the successful use of regional anesthesia. Successful use of regional anesthesia has been described in patients with OI. Using regional anesthesia, we were able to avoid tracheal intubation and its inherent risks of aspiration and mandibular injury. General anesthesia should be avoided whenever possible due to the potential risk for malignant hyperthermia. In the event that the regional block failed, precautionary measures were taken to assess the ease of intubation should it be required. Regional anesthesia may be challenging due to severe scoliosis, inability to tolerate the supine position awake, and a preexisting coagulopathy.

Mode of delivery for patients with type III OI is generally cesarean delivery because of old maternal fractures causing crippling skeletal deformities, cephalopelvic disproportion, and increased incidence of abnormal presentation [4, 5]. Other milder types of OI can be delivered vaginally. However, in a retrospective study using diagnostic codes, women with OI (all types) had 6-fold increased risk of cesarean delivery compared with women without OI [8].

Conclusion

Management of maternal type III OI needs a multidisciplinary approach. Underlying restrictive lung disease worsens as pregnancy progresses, which may mandate early delivery. Mode of delivery is controversial, but many patients with type III OI undergo cesarean delivery due to skeletal deformities and malpresentation. Anesthesia can be challenging, but successful regional anesthesia is reported. Neonatal outcomes are complicated due to indicated preterm deliveries.

Authorship

TK: conceived the idea for the study, wrote the article, and is the corresponding author of the study. MF: critically revised drafts of the article for important intellectual content and gave final approval of the version to be published. JS: critically revised drafts of the article for important intellectual content and gave final approval of the version to be published. HA: conceived the idea for the study, critically revised drafts of the article for important intellectual content, and gave final approval of the version to be published.

Conflict of Interest

There is no financial support, funding source, acknowledgment, or conflict of interest to disclose.

References

1. Byers, P. H. 1993. Osteogenesis imperfecta. Pp. 317–350 in P. M. Royce and B. Steinmann, eds. *Connective tissue and its heritable disorders. Molecular, genetic and medical aspects*. Wiley-Liss, New York, NY.
2. Cropp, G. J. A., and D. N. Myers. 1972. Physiological evidence of hypermetabolism in osteogenesis imperfecta. *Pediatrics* 49:375–391.
3. Ryan, C. A., A. S. Al-Ghamdi, M. Gayle, and N. N. Finer. 1989. Osteogenesis imperfecta and hyperthermia. *Anesth. Analg.* 68:811–814.
4. Maya, D., B. Nayyar, and P. Patra. 2006. Anesthetic management of a case of osteogenesis imperfect with associated bronchial asthma for repair of corneal perforation. *Indian J. Anaesth.* 50:223–225.
5. Porsborg, P., G. Astrup, D. Bendixen, A. M. Lund, and H. Ording. 1996. Osteogenesis imperfecta and malignant hyperthermia: is there a relationship? *Anesthesia* 51:863–865.
6. Ho Duy, B, Zhytnik, L, Maasalu, K, Kändla, I, Prans, E, Reimann, E, Märtson, A, Kõks, S. Mutation analysis of the COL1A1 and COL1A2 genes in Vietnamese patients with osteogenesis imperfecta. *Hum Genomics.* 2016 Aug 12;10(1):27.
7. Sillence, D., A. Senn, and D. M. Danks. 1979. Genetic heterogeneity in osteogenesis imperfecta. *J. Med. Genet.* 16:101–116.
8. Ruitter-Ligeti, J., N. Czuzoj-Shulman, A. R. Spence, T. Tulandi, and H. A. Abenheim. 2016. Pregnancy outcomes in women with osteogenesis imperfecta: a retrospective cohort study. *J. Perinatol.* 36:828–831.