



## MRI visualization of optic nerve avulsion due to ocular perforation from BB gun projectile

Luke Barnard, Radwan Ajlan\*

University of Kansas School of Medicine, 3901 Rainbow Blvd, Kansas City, KS, USA



### ARTICLE INFO

#### Keywords:

Optic nerve avulsion  
MRI  
BB  
Air-soft gun  
Perforating injury

### ABSTRACT

To report a case of optic nerve avulsion after a perforating injury by an air-soft/BB gun that was successfully captured with magnetic resonance imaging.

### 1. Case report

An 18-year-old male presented with vision loss after being struck in the left eye with a metallic ball-bearing (BB) that had ricocheted off of the target after being shot from the BB gun. On presentation, the right eye had a 20/20 visual acuity with unremarkable exam. The left eye had visual acuity of no light perception vision (NLP), reversed relative afferent pupillary defect, upper lid margin defect nasally (measuring 2 mm), corneal edema, total hyphema, and sclera laceration at the junction between zones 1 and 2 (from 9 to 10 o'clock positions) with visible prolapsed uveal and vitreous tissues. CT imaging showed a ruptured left globe with the BB projectile present in the globe (Fig. 1). Emergent globe rupture repair, pars plana vitrectomy, lensectomy, and foreign body removal were performed. Extensive vitreous hemorrhage and sub-retinal hemorrhage surrounding optic nerve head (ONH) region caused obstructed view of the ONH. Silicon oil was infused as part of retinal detachment repair caused by projectile scleral entry wound, and to decrease the chances of retinal re-detachment.

On postoperative follow up, vision remained NLP. At 1-week visit, B-scan did not show the left optic nerve to reach the optic disc, with an area of hypolucency seen just posterior to the optic nerve head position (Fig. 2). Non-urgent MRI was performed after 1-month, showing hypointensities in the posterior left globe consistent with optic nerve avulsion (ONA) (Fig. 3 and 4).

### 2. Discussion

Optic nerve avulsion is defined as the separation of the nerve from the globe of the eye usually at the weaker fibers of the lamina cribrosa.

ONA has been attributed to forced rotation of the globe in relation to the nerve, rapid elevation of intraocular pressures, or anterior/posterior displacement of the globe/nerve, respectively.<sup>1,2</sup> ONA has been reported as a result of many forms of trauma including motor vehicle accidents, sports injuries, falls, and eye gouges.<sup>1,2</sup> While BB projectiles usually cause vision loss through penetrating injuries to the cornea and

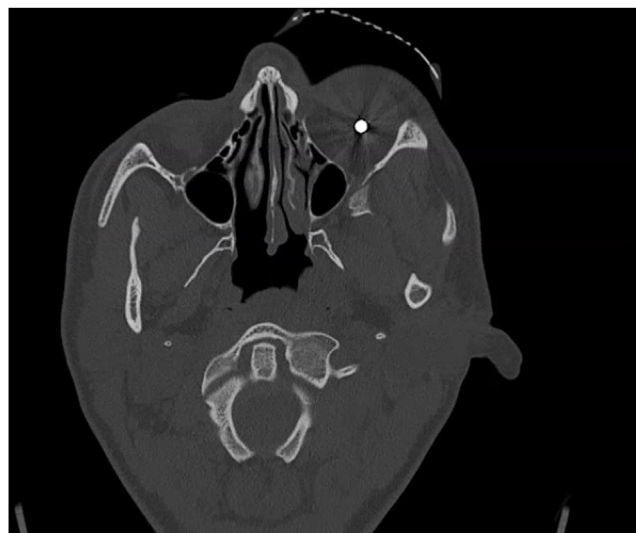

Fig. 1. Axial CT showing BB projectile within the left globe.

\* Corresponding author. Department of Ophthalmology, University of Kansas School of Medicine, 7400 State Line Road, Prairie Village, KS 66208, USA.  
E-mail address: [rajlan@kumc.edu](mailto:rajlan@kumc.edu) (R. Ajlan).

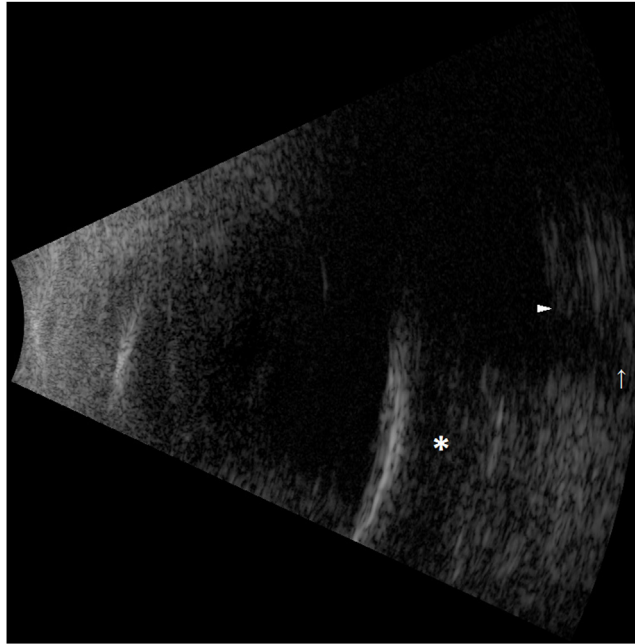


Fig. 2. Vertical B-scan ultrasound of the left eye, showing intravitreal blood clot (asterisk) posterior to silicon oil, peripapillary scleral edge (arrow head), and retracted optic nerve (arrow).

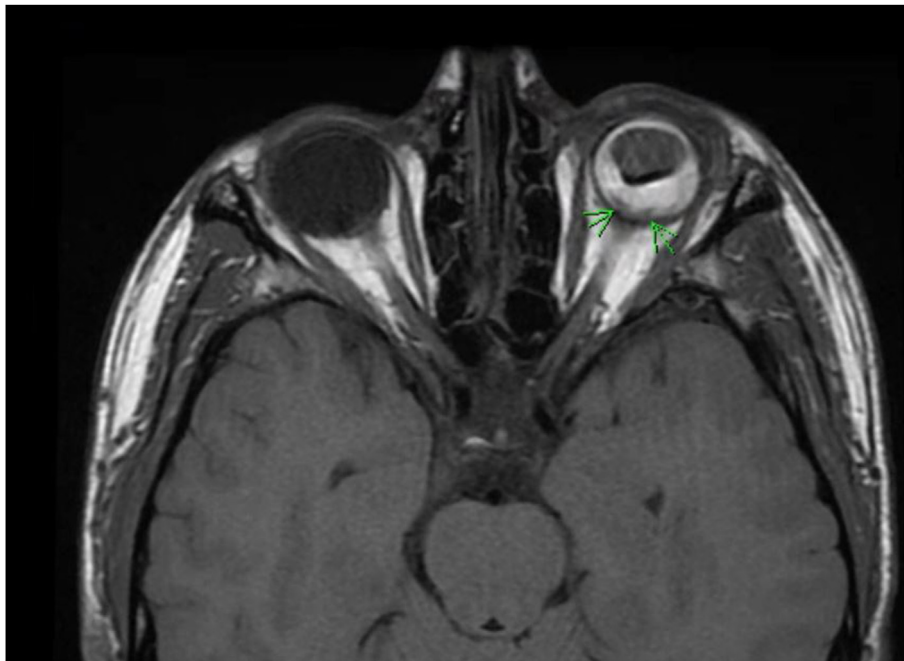
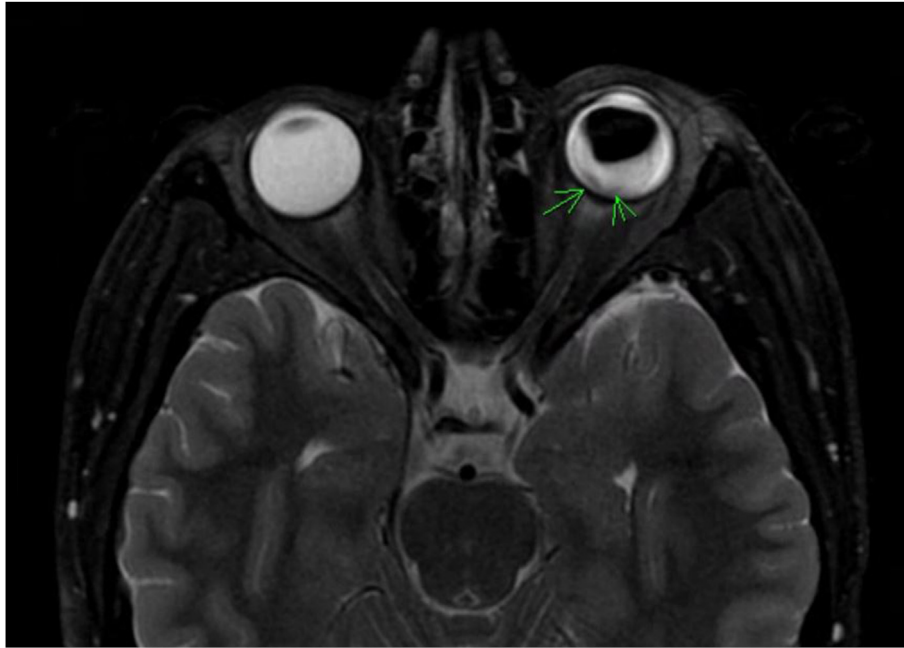


Fig. 3. Axial T1 scan shows left scleral defect indicative of ONA (slice thickness = 3 mm, repetition time = 650 ms).



**Fig. 4.** Axial T2 scan similarly shows scleral defect indicative of ONA (slice thickness = 3 mm, repetition time = 6550 ms).

retina,<sup>3</sup> to the best of our knowledge, this is the first case report in the literature of ONA from a metal BB projectile. Furthermore, the capture of ONA on both B-scan and MRI modalities in the same patient was not reported before, with one case in the literature capturing ONA on MRI.<sup>2</sup> MRI detection of ONA is rare since optic nerve dural sheaths usually tend to remain attached to the globe, making it difficult to detect. In addition, it is rare to see similar discontinuity of the sclera, which can be explained in this case by the forceful impact of the BB projectile on the optic nerve head causing ONH displacement and avulsion. This report demonstrates the importance of eye protection glasses, and the risk of severe optic nerve injuries from air-soft/BB guns even with indirect shots with decreased speeds. This report also demonstrates the value of MRI in the setting of unexplained vision loss when other modalities are inadequate, impossible, or inconclusive.

#### Funding

No funding or grant support.

#### Conflicts of interest

The following authors have no financial disclosures: LB, RA.

#### Authorship

All authors attest that they meet the current ICMJE criteria for Authorship.

#### Patient consent

Written consent to publish this case has not been obtained. This report does not contain any personal identifying information.

#### Acknowledgements

None.

#### References

1. Sawhney R, Kochhar S, Gupta R, Jain R, Sood S. Traumatic optic nerve avulsion: role of ultrasonography. *Eye*. 2003;17(5):667–670.
2. Paya C, Delyfer MN, Thoumzot F, et al. Traumatic optic nerve avulsion: a case report. *J Fr Ophthalmol*. 2012;35(5):360e1.
3. Ahmadabadi MN, Karkhaneh R, Valeshabad AK, Tabatabai A, Jager MJ, Ahmadabadi EN. Clinical presentation and outcome of perforating ocular injuries due to BB guns: a case series. *Injury*. 2011;42(5):492–495.