

Subcutaneous implantable cardioverter-defibrillator placement in a patient with a preexisting transvenous implantable cardioverter-defibrillator



Mohammad-Ali Jazayeri, MD,^{*} Martin P. Emert, MD, FACC, FHRS,^{*†} JoAnn Bartos, BSN,[‡] Ted Tabbert, BBA,[‡] Dhanunjaya R. Lakkireddy, MD, FACC, FHRS,^{*†} Mohammad-Reza Jazayeri, MD[§]

From the ^{*}Cardiovascular Research Institute, University of Kansas Medical Center, Kansas City, Kansas, [†]Bloch Heart Rhythm Center, Mid-America Cardiology, University of Kansas Hospital, Kansas City, Kansas, [‡]Cardiac Rhythm Management, Boston Scientific Corporation, St. Paul, Minnesota, and [§]Bellin Health Heart & Vascular Center, Green Bay, Wisconsin.

Introduction

The subcutaneous implantable cardioverter-defibrillator (S-ICD) is a safe and effective treatment for prevention of sudden cardiac death.¹ It is typically not used in patients who require additional therapies conferred by transvenous implantable cardioverter-defibrillator (TV-ICD) systems, such as bradycardia pacing or antitachycardia pacing (ATP) for ventricular tachycardia (VT). Despite reports of successful S-ICD implantation in patients with other cardiac implantable electronic devices (CIEDs),^{2–5} we are not aware of any reports to date in which S-ICD implantation complemented a pre-existing TV-ICD as a backup device for successful defibrillation. We report the case of a patient who presented with this clinical dilemma.

Case report

An 83-year-old man with a history of ischemic cardiomyopathy and dual-chamber TV-ICD placement 11 years prior for secondary prevention of VT was referred to the electrophysiology service at Bellin Health Heart & Vascular Center (Green Bay, WI), as his device generator had reached end of life. Because the device was originally implanted for secondary prevention, it was felt that defibrillator threshold (DFT) testing was warranted. Furthermore, the patient had experienced a decline in his left ventricular ejection fraction (LVEF) to 35% from 50% 1 year earlier.

During DFT testing with the new generator (INOGEN ICD; Boston Scientific Corp. (i.e. should read ‘Corp.’), St. Paul, MN), ventricular fibrillation (VF) was induced, and the ICD failed to successfully defibrillate even at its maximum

energy output of 41 joules. The patient was resuscitated with external defibrillation. None of the standard approaches was successful in adequately reducing the DFT below the device’s maximal energy, including reversal of polarity, “cold can” configuration, and even posterolateral placement of a subcutaneous array in the left chest. After it was felt that all reasonable available options were exhausted and additional VF inductions would not be beneficial, the newly implanted generator was left in place, and the pocket was closed. The patient was allowed approximately 24 hours of recovery time, after which DFT testing was repeated, with the same outcome.

Alternative options were discussed with the patient, including maintaining the status quo (which we felt was not an acceptable option at that point), pursuing a surgical approach for epicardial patch placement, or implantation of an S-ICD, and he opted for the latter modality. However, because historically he had responded to ATP therapy for VT and required atrial pacing nearly 100% of the time, we planned to preserve his TV-ICD.

Preliminary screening for S-ICD implantation showed he was a suitable candidate with respect to his QRS complexes, both paced and intrinsic. We proceeded with implantation of the S-ICD via the standard approach (Figure 1). VF was induced by a 50 Hz electrical burst delivered from the S-ICD, appropriately detected, and converted with a 65 J standard polarity shock (Figure 2A). Shock impedance was 72 ohms, and the time to therapy was 13 seconds. The device was programmed with the primary sensing vector (Figure 2B) at 2× gain and shock zone threshold of 230 beats per minute (bpm). DFT testing of the S-ICD was repeated with 3 different configurations of the TV-ICD at maximal pacing output: atrial sensing–ventricular pacing, atrial pacing–ventricular pacing, and atrial pacing–ventricular fusion. In each case the S-ICD succeeded in restoring sinus rhythm, with no inappropriate sensing resulting in inappropriate therapies.

Following our unsuccessful attempts to achieve a safe DFT, we turned off ATP therapy because of our concern it

KEYWORDS Transvenous ICD; Subcutaneous ICD; Sudden cardiac death; Implantable cardioverter-defibrillator; Defibrillation threshold (Heart Rhythm Case Reports 2017;3:306–310)

Address reprint requests and correspondence: Mohammad-Ali Jazayeri, MD, University of Kansas Hospital & Medical Center, 3901 Rainbow Blvd, MS 3006, Kansas City, KS 66160. E-mail address: mjazayeri@kumc.edu.

KEY TEACHING POINTS

- Despite emerging evidence demonstrating comparable implantable cardioverter-defibrillator (ICD) efficacy with or without routine defibrillator threshold (DFT) testing, in subsets of patients who are felt to be at particularly high risk and for whom guideline recommendations are less clear, DFT testing may be pursued by an implanting physician.
- In cases where DFT testing is felt to be clinically indicated, one should keep in mind that successful defibrillation of ventricular fibrillation is a probabilistic phenomenon, and performance in the past may not predict performance in the future.
- In this setting, subcutaneous ICD (S-ICD) therapy may be considered as a backup to a transvenous ICD in cases where a patient requires transvenous therapies, but the usual system revisions have been unsuccessful in achieving a satisfactory DFT. Rigorous testing of both devices should be performed to minimize interactions, particularly S-ICD double counting and undersensing.

may cause degeneration to VF and instead configured the transvenous device to treat VT with shocks. Furthermore, TV-ICD defibrillation therapies for VF were left on in the event they may be successful and with the acknowledgment that the S-ICD would serve as a backup if the TV-ICD failed to restore sinus rhythm. The VT/VF detection times of the TV-ICD were set short to preferentially try defibrillation first by the TV-ICD. The TV-ICD was programmed in DDD mode with a long atrioventricular interval to both help

promote intrinsic conduction with narrow QRS complexes and minimize inappropriate sensing resulting in inappropriate therapies. The patient tolerated the procedure well, and no complications were encountered during the implantation.

Just prior to reaching 6 months post-implantation, the patient experienced a run of symptomatic VT, which was appropriately converted with a 41 J shock from his TV-ICD (Figure 2C). Two days later he had 5 more runs of VT, all of which were terminated in like fashion. Interrogation of both ICD devices demonstrated normal function without any evidence of adverse interaction between them. The patient was started on sotalol and had no further recurrence of VT.

Discussion

S-ICD devices have been shown to be a safe and effective alternative to traditional TV-ICD devices in appropriate candidates.⁴ Previous reports have documented successful implantation of S-ICD devices in the presence of other CIEDs, including transvenous pacemakers,^{4,5} epicardial patches,² cardiac contractility modulators, and vagal nerve stimulators.³ In all cases the S-ICD was shown to function properly after undergoing rigorous testing for device–device interactions, especially defects in its sensing and shock delivery capabilities. Noting the historical significance of pacemaker–defibrillator interactions, we had concerns regarding whether the 2 devices would interfere with one another, in terms of both can–can interactions and the ability of the S-ICD algorithm to appropriately sense ventricular arrhythmias while the TV-ICD was pacing. Limited reports of experiences with concomitant pacemaker and S-ICD implantation have been uneventful when testing sensing and shocking capabilities of the S-ICD with a variety of pacemaker settings.^{2,3}

In our case, we found the S-ICD was able to appropriately sense ventricular arrhythmias with the primary sensing vector (i.e., from the xiphoid electrode to the S-ICD generator) at $2\times$ gain. There was occasional double counting noted with

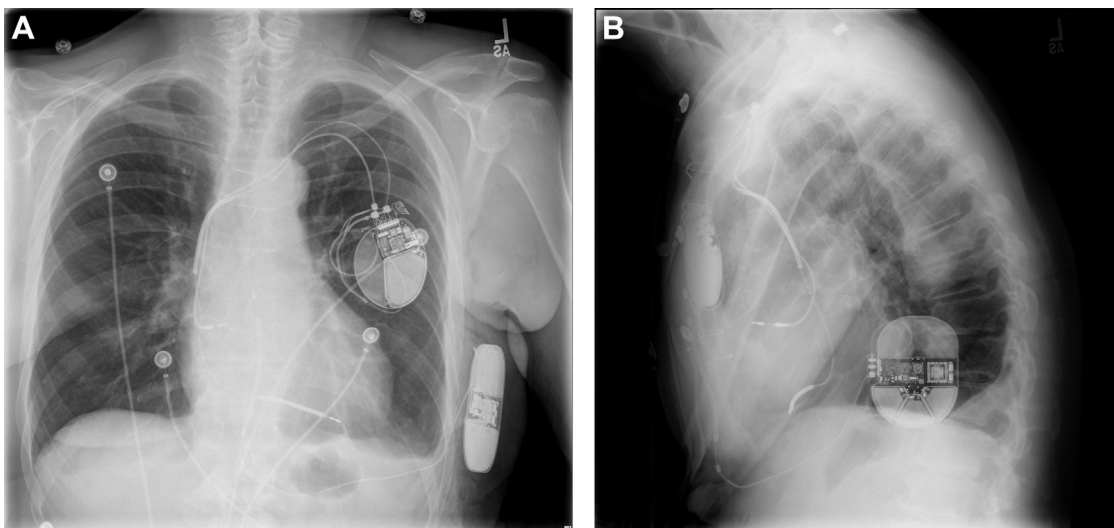


Figure 1 Anterior-posterior (A) and lateral (B) view chest radiographs following subcutaneous implantable cardioverter-defibrillator implantation.

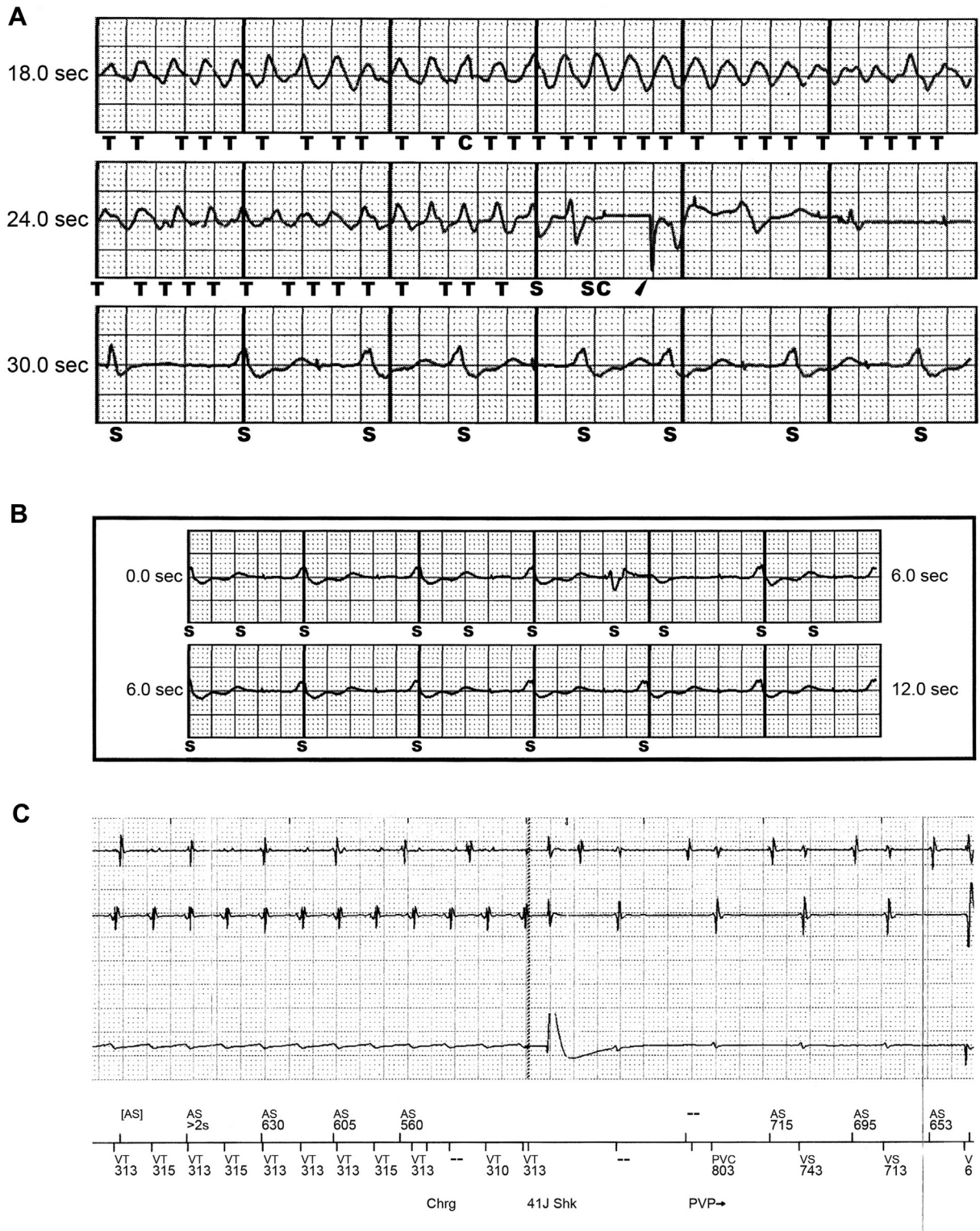


Figure 2 A: Subcutaneous implantable cardioverter-defibrillator (S-ICD) appropriately detecting and converting ventricular fibrillation on induction testing. B: S-ICD programmed with primary sensing vector and 2× gain demonstrating good capture and occasional double counting. C, Transvenous ICD delivering maximal shock (36.5 J) in response to spontaneous ventricular tachycardia.

ventricular pacing (Figure 2B), so sensing vector selection was in part determined by which vector was least affected by this phenomenon. As a precaution, we set the S-ICD shock zone threshold at 230 bpm to ensure that even in conditions of double counting the threshold would exceed the

maximum TV-ICD sensor and tracking rates of 110 bpm and minimize inappropriate shocks. Implantation of an S-ICD in the setting of other CIEDs in prior reports was a matter of pragmatism where it was felt a TV-ICD was not specifically indicated or was contraindicated for prevention of

sudden cardiac death. In the present case, however, the patient already had a functioning TV-ICD in place, but despite manipulation of the shock vector with various configurations and the addition of a subcutaneous electrode array, a safe DFT could not be achieved during the generator change procedure. During implantation of the TV-ICD 11 years prior, DFT testing had been successful, with no more than a 17 J shock. This was also the case during a generator change 5 years prior to presentation.

The role of DFT testing during ICD implantation remains controversial, with well-intentioned arguments from both proponents and opponents of the practice. Using a conventional 10 J safety margin, high DFTs requiring system modification occur in approximately 2%–12% of implants.⁶ A number of factors have been implicated as being associated with higher DFTs, such as low LVEF, New York Heart Association functional class III/IV heart failure, nonischemic cardiomyopathy, male sex, increased age, secondary prevention indication, and others.^{6,7} Proposed benefits of DFT testing and subsequent system modification for high DFTs include identification of catastrophic, albeit rare, device failure; potential improvement in first shock success; and detection of abnormal lead function. Historically, DFT testing has been a mainstay of clinical trials demonstrating the mortality benefit of ICD therapy and was incorporated into major trials for both primary and secondary prevention, as well as device labeling.^{8,9} Because system modifications can ameliorate high DFTs, some would argue the implanter has an ethical obligation to ensure, to the best of his or her ability, that the ICD system functions appropriately.

On the other hand, there are limitations and risks associated with DFT testing. Owing to the probabilistic nature of defibrillation, there is no guarantee that successful DFT testing will predict future successful termination of VT/VF. Achieving a safe DFT at the time of implantation does not account for substrate changes, metabolic derangements, medication effects, and other factors that may subsequently affect shock efficacy. DFT testing itself is not devoid of risk to the patient, nor are system revisions aimed at achieving an acceptable DFT. Improvements in device characteristics have led some to avoid the routine practice of DFT testing at initial implantation in up to 30% of cases.^{7,10} This perspective has been reinforced by the publication of randomized controlled trial data from the Shockless IMPLant Evaluation (SIMPLE) and the NO Regular Defibrillation testing In Cardioverter Defibrillator Implantation (NORDIC ICD) trials.^{11,12} Both showed no significant difference in shock efficacy in adult patients undergoing ICD implantation, randomized to either receive or forgo DFT testing. They additionally supported the overall safety of DFT testing. Guidelines from the 2015 HRS/EHRA/APHRS/SOLAECE expert consensus document confer a class IIa (Level of Evidence, B-R) recommendation in this regard: “It is reasonable to omit defibrillation efficacy testing in patients undergoing initial left pectoral transvenous ICD implantation procedures where appropriate sensing, pacing, and impedance values are obtained with fluoroscopically well-positioned RV leads.”¹³

Despite increasing evidence demonstrating inconsequential DFT testing in a majority of patients receiving high-output devices, our ability to accurately identify patients in whom system revision may be beneficial remains limited. In the case of our patient, his constellation of risk factors and newly depressed LVEF compelled us to pursue DFT testing. Unfortunately, the standard revision techniques were unable to yield a satisfactory DFT, and we ultimately pursued an alternative plan of S-ICD implantation as a backup to his transvenous device. We suspect its success was related both to a different shock vector achieved by the subcutaneous system (Figure 1) and to a higher energy delivered as compared with the existing TV-ICD. S-ICD implantation may therefore be considered as an option in rare situations when a pre-existing TV-ICD is incapable of achieving a satisfactory DFT and available alternative options have been exhausted.

Acknowledgments

The authors wish to express their gratitude to Melanie Wishart, for her assistance with preparation of the figures for this manuscript, and the University of Kansas One University Open Access Authors Fund, for their generous grant in support of this open access publication.

References

- Bardy GH, Smith WM, Hood MA, et al. An entirely subcutaneous implantable cardioverter-defibrillator. *N Engl J Med* 2010;363(1):36–44.
- Hong PS, Callinan P, Amit G, Healey JS. Successful implant of a subcutaneous ICD system in a patient with an ipsilateral epicardial pacemaker. *Indian Pacing Electrophysiol J* 2015;15(1):62–64.
- Kuschyk J, Stach K, Tulumen E, Rudic B, Liebe V, Schimpf R, Borggreffe M, Roger S. Subcutaneous implantable cardioverter-defibrillator: first single-center experience with other cardiac implantable electronic devices. *Heart Rhythm* 2015;12(11):2230–2238.
- Lambiase PD, Barr C, Theuns DA, et al. Worldwide experience with a totally subcutaneous implantable defibrillator: early results from the EFFORTLESS S-ICD Registry. *Eur Heart J* 2014;35(25):1657–1665.
- van Opstal J, Geskes G, Debie L. A completely subcutaneous implantable cardioverter defibrillator system functioning simultaneously with an endocardial implantable cardioverter defibrillator programmed as pacemaker. *Europace* 2011;13(1):141–142.
- Russo AM, Chung MK. Is defibrillation testing necessary for implantable transvenous defibrillators?: defibrillation testing is necessary at the time of implantable cardioverter defibrillator implantation. *Circ Arrhythm Electrophysiol* 2014;7(2):337–346.
- Hsu JC, Marcus GM, Al-Khatib SM, Wang Y, Curtis JP, Sood N, Parker MW, Kluger J, Lampert R, Russo AM. Predictors of an inadequate defibrillation safety margin at ICD implantation: insights from the National Cardiovascular Data Registry. *J Am Coll Cardiol* 2014;64(3):256–264.
- Connolly SJ, Hallstrom AP, Cappato R, Schron EB, Kuck KH, Zipes DP, Greene HL, Boczor S, Domanski M, Follmann D, Gent M, Roberts RS. Meta-analysis of the implantable cardioverter defibrillator secondary prevention trials. AVID, CASH and CIDS studies. *Antiarrhythmics vs Implantable Defibrillator study. Cardiac Arrest Study Hamburg. Canadian Implantable Defibrillator Study. Eur Heart J* 2000;21(24):2071–2078.
- Hess PL, Al-Khatib SM, Han JY, et al. Survival benefit of the primary prevention implantable cardioverter-defibrillator among older patients: does age matter? An analysis of pooled data from 5 clinical trials. *Circ Cardiovasc Qual Outcomes* 2015;8(2):179–186.
- Russo AM, Wang Y, Al-Khatib SM, Curtis JP, Lampert R. Patient, physician, and procedural factors influencing the use of defibrillation testing during initial implantable cardioverter defibrillator insertion: findings from the NCD(R). *Pacing Clin Electrophysiol* 2013;36(12):1522–1531.
- Bansch D, Bonnemeier H, Brandt J, Bode F, Svendsen JH, Taborsky M, Kuster S, Blomstrom-Lundqvist C, Felk A, Hauser T, Suling A,

- Wegscheider K. Intra-operative defibrillation testing and clinical shock efficacy in patients with implantable cardioverter-defibrillators: the NORDIC ICD randomized clinical trial. *Eur Heart J* 2015;36(37):2500–2507.
12. Healey JS, Hohnloser SH, Glikson M, et al. Cardioverter defibrillator implantation without induction of ventricular fibrillation: a single-blind, non-inferiority, randomised controlled trial (SIMPLE). *Lancet* 2015; 385(9970):785–791.
 13. Wilkoff BL, Fauchier L, Stiles MK, et al. 2015 HRS/EHRA/APHR/SOLAECE expert consensus statement on optimal implantable cardioverter-defibrillator programming and testing. *Heart Rhythm* 2016;13(2):e50–86.