

Efficacy and Toxicity of Peritumoral Delivery of Nanoconjugated Cisplatin in an In Vivo Murine Model of Head and Neck Squamous Cell Carcinoma

Stephanie M. Cohen, MD, MS; Nick Rockefeller, BS; Ridhwi Mukerji, MD; Dianne Durham, PhD; M. Laird Forrest, PhD; Shuang Cai, PhD; Mark S. Cohen, MD; Yelizaveta Shnayder, MD

Importance: Treatment of locally advanced head and neck squamous cell carcinoma (HNSCC) uses a multidisciplinary approach often limited by the toxicity and drug resistance of platinum agents.

Objectives: To test whether a nanocarrier-conjugated cisplatin boosting locoregional drug delivery improves tumor efficacy while decreasing systemic toxicity over systemic cisplatin in a murine model of locally advanced HNSCC.

Design: A randomized, controlled, in vivo study compared standard cisplatin with nanocarrier (hyaluronan [HA])–conjugated cisplatin (HA-cisplatin) each at 50% of the maximum tolerated doses in a murine model of locally advanced HNSCC (10 mice/arm, each injected with 1×10^6 MDA-1986 HNSCC cells, with phosphate-buffered saline and HA-only control arms). Mice were treated for 3 weeks and observed for 3 additional weeks.

Setting: Academic medical center.

Participants: Forty female Nu/Nu mice. Randomization and treatment arms were initiated once tumor volumes reached 30 mm³.

Intervention: Injection with MDA-1986 HNSCC cells followed by 3 weeks of treatment with cisplatin, HA-cisplatin, phosphate-buffered saline, or HA only.

Main Outcomes and Measures: Animal weights and tumor volumes were measured 3 times each week (modified RECIST [Response Evaluation Criteria in Solid Tumors]). At necropsy, animal kidneys were examined for nephrotoxic effects and cochleae were examined for ototoxic effects.

Results: The mice treated with HA-cisplatin showed superior tumor efficacy (1 with complete clinical response, 3 with partial response, 1 with stable disease, and 5 with progressive disease) compared with standard cisplatin (no animals with complete clinical response, 1 with partial response, 1 with stable disease, and 8 with progressive disease), which was statistically significant ($P = .003$). All control animals developed progressive disease. Weight loss and body score were surrogate measures of treatment toxicity. The HA-cisplatin group had the least weight loss (mean [SD], 10.8% [4.7%]) compared with the cisplatin group (13.6% [5.6%]; $P = .25$). Body score dropped to 2 or less in all cisplatin-treated mice but not in any HA-cisplatin-treated mice, which also lacked any histologic signs of nephrotoxic or ototoxic effects.

Conclusions and Relevance: Nanoconjugated HA-cisplatin significantly improves tumor efficacy with lower toxicity compared with standard cisplatin in locally advanced HNSCC in vivo, justifying additional translational studies.

JAMA Otolaryngol Head Neck Surg. 2013;139(4):382-387

Author Affiliations:

Departments of Surgery (Drs S. M. Cohen, Mukerji, and M. S. Cohen) and Otolaryngology–Head and Neck Surgery (Drs Durham and Shnayder), The University of Kansas Medical Center, Kansas City; and Department of Pharmaceutical Chemistry, The University of Kansas, Lawrence (Drs Forrest and Cai). Mr Rockefeller is a medical student at The University of Kansas, Kansas City.

IN THE PAST DECADE, MORE THAN 58 000 new cases of head and neck cancers were reported in the United States each year. Head and neck cancer is currently the eighth leading cause of new cancer cases among men, with more than 40 000 new cases predicted in the United States for 2012, and it results in more than 8000 deaths annually.^{1,2} Worldwide, more than 500 000 new cases of head and neck cancers are diagnosed each year.³ Overall, head and neck squamous cell carcinoma (HNSCC) accounts for greater than 90% of head and neck cancer cases. The median age for di-

agnosis of this disease is in the sixth decade of life, and this cancer type carries a significant male predominance, with a male to female incidence ratio of 3:1. Most patients with HNSCC present with advanced-stage locoregional disease, for which the standard of treatment is a multidisciplinary approach involving chemoradiotherapy and surgical resection.⁴ However, the overall 5-year survival rate from HNSCC remains less than 50% despite multiple combination therapy regimens during the past 2 decades.⁵ These combination multidrug-chemotherapy approaches typically use a platinum agent, such as cisplatin. The use

of this cytotoxic drug, while effective against HNSCC, is limited by its toxicity, specifically nephrotoxicity and ototoxicity, as well as by drug resistance in patients with HNSCC.^{6,7} Because of the limitations of platinum agents, novel therapeutic strategies that target head and neck cancers more effectively with reduced toxicity profiles are a priority in current research.

For patients with locally advanced HNSCC, studies have demonstrated an improved survival rate when radiotherapy is combined with concurrent platinum-based chemotherapy and surgical resection, increasing 5-year survival rates by up to 6.5%.^{8,9} Platinum agents, such as cisplatin, inhibit cancer growth by promoting DNA binding and cross-linking, thereby triggering apoptosis. However, this drug also carries systemic toxicities, the most notable being neurotoxicity, ototoxicity, and nephrotoxicity, which are likely related to high peak plasma concentration levels.^{10,11} In fact, more than 80% of patients experience severe toxic effects with current regimens, and more than 75% of patients receiving cisplatin develop ototoxic effects, which are cumulative and usually irreversible.^{12,13}

Although platinum agents have a mildly improved survival benefit in a concurrent setting, the overall survival and cure rates are still low for HNSCC, and the strong toxicity profile creates a critical need to improve the safety and tolerability of this chemotherapy regimen and to enhance its efficacy. The use of nanoconjugation with current chemotherapeutic agents, such as cisplatin, has been shown to provide a novel method for drug delivery through the locoregional lymphatics. This improves drug delivery and cancer targeting, lowers systemic toxicity, and still maintains therapeutic systemic levels.¹⁴ A previous study¹⁴ demonstrated that hyaluronan (HA), which has a nanoscopic molecular weight, can be combined with a chemotherapeutic agent, allowing the drug to be preferentially taken up initially by locoregional tissues and lymphatic channels without systemic bolus release as a result of the size and hydrophilicity of the conjugate. This construct also allows for a sustained-release kinetic profile, permitting improved efficacy at decreased doses.¹⁵ In vitro and in vivo models of nanoconjugated HA-cisplatin have been reported in breast cancer models.¹⁶⁻¹⁸ These studies have shown improved delivery of the chemotherapeutic agent to the lymphatic system with a decreased toxicity profile compared with the standard agent at all doses tested, including lower drug doses.

The most significant, dose-limiting toxicities of cisplatin therapy are neurotoxicity and nephrotoxicity, both of which are strongly influenced by peak plasma concentration.¹⁰ In studies using HA-cisplatin subcutaneously for lymphatic drug delivery, the peak plasma concentration of platinum from lymphatic HA-cisplatin nanoparticles was 64% less than that of intravenous cisplatin and the release was more sustained, consistent with longer lymphatic retention of the nanocarrier.¹⁵ Although HA-cisplatin demonstrated a lower peak plasma concentration, it maintained an area under the curve similar to that of platinum in the serum over time, comparable to systemic cisplatin. This equivalent plasma area under the curve is important for clinical success because adequate systemic drug levels are required to treat dis-

tant metastases. Nanocarriers can provide a real benefit by increasing locoregional lymph node basin concentrations compared with standard therapy, since standard systemic therapy achieves poor penetration in the lymph nodes.¹⁹ Thus, lymphatic nanoparticle chemotherapy may decrease systemic toxicity by eliminating the dangerous peaks inevitable with intravenous dosing yet provide equivalent or better distant control by improving the residence time of anticancer drugs such as cisplatin.

Therefore, we hypothesized that cisplatin, when conjugated to nanoscopic HA, will boost drug delivery to the locoregional tissues and lymphatics, improving tumor efficacy with decreased systemic toxicity over standard systemic cisplatin in HNSCC. The aim of this study was to test this hypothesis in a randomized, controlled, translational study comparing HA-cisplatin with standard cisplatin for efficacy and toxicity in a murine model of locally advanced HNSCC with cervical metastases.

METHODS

CELL CULTURE

An aggressive human oral squamous carcinoma cell line, MDA-1986, was maintained in Dulbecco modified Eagle medium (Sigma-Aldrich) supplemented with 10% fetal bovine serum, sodium pyruvate, nonessential amino acids, L-glutamine, a 2-fold modified Eagle medium–vitamin solution, and a combination of 1% penicillin and streptomycin sulfate (100 IU/mL and 100 µg/mL, respectively; Sigma-Aldrich). Adherent monolayer cultures were maintained in T-75 culture flasks and incubated at 37°C with 5% carbon dioxide until they achieved 85% confluency. The cells were trypsinized using 0.25% trypsin (Sigma Aldrich) and passaged into T-75 flasks at a density of 1×10^6 cells per 100 µL. On experiment days, cells were trypsinized and counted with a hemocytometer to determine the number of viable cells.

IN VIVO TUMOR MODEL AND TREATMENT

All animal studies were conducted in accordance with The University of Kansas Institutional Animal Care and Use Committee guidelines. The MDA-1986 HNSCC cells were prepared in a $1 \times$ PBS solution at a concentration of 1×10^6 cells per 100 µL. Cells (100 µL) were injected under isoflurane anesthesia into the retromandibular buccal mucosa of 4- to 6-week-old female Nu/Nu mice (20-25 g each, Charles River Laboratories) using a 25-gauge needle. Tumor size was measured 3 times weekly with a digital caliper and confirmed by 2 separate observers (S.M.C. and N.R.). Tumor volume was calculated using the following equation:

$$\text{Tumor Volume} = (\pi/6) \times (\text{Width})^2 \times \text{Length},$$

where volume is measured in cubic millimeters and width and length are measured in millimeters.

When tumors reached a minimum volume of 30 mm³, mice were randomized into control arms (PBS or HA only) or one of 2 treatment groups (50% maximum tolerated dose [MTD] cisplatin or 50% MTD HA-cisplatin). Ten mice were randomized into each arm for a total of 40 mice. Pharmaceutical-grade cisplatin was used for the standard treatment groups, as well as to create the nanocarrier formulation as previously described.¹⁷ Treatments in the HA-only control and HA-cisplatin groups were administered subcutaneously, 1 to 3 mm from the site of tumor implantation, and treatments in the PBS control and standard

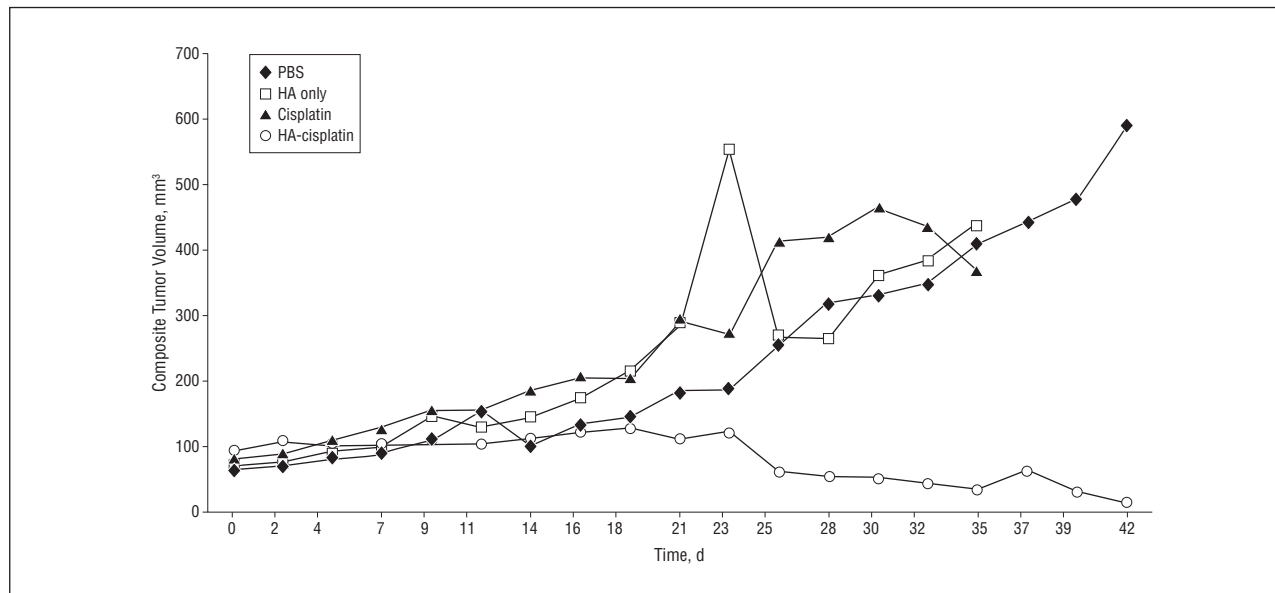


Figure 1. Comparison of head and neck tumor volumes with treatment. The graph shows a composite curve of the tumor volumes for the 10 animals in each control and treatment group (phosphate buffered saline [PBS], hyaluronan [HA] only, HA-cisplatin, and cisplatin) over time.

systemic cisplatin groups were administered intraperitoneally. The MTD level reported in mice for cisplatin is approximately 10 mg/kg per weekly intraperitoneal dose.^{20,21} All treatments were given once a week for 3 weeks. Mice were then monitored for an additional 3 weeks on completion of treatment for a total study period of 6 weeks. Mice were humanely killed before completion of the experiment if the tumor volume exceeded 1200 mm³ by 6 weeks after inoculation, if weight loss was significant, or if the body score markedly deteriorated.

HISTOLOGIC STUDIES

On completion of the study, 2 Nu/Nu mice from each treatment arm were examined at necropsy for gross pathologic findings and histologic analysis. The tumor site with surrounding skin and soft tissues, bilateral kidneys, cochleae, and bilateral cervical lymph nodes were harvested intact from the mice and stored in 10% formalin solution for fixation overnight prior to slide mounting. Mounting with hematoxylin-eosin staining was conducted by the Department of Pathology at The University of Kansas Medical Center, Kansas City, and histologic examination was performed by a blinded board-certified pathologist. Slide images were obtained using digital image-capture software (Aperio, version 10.0; Aperio Technologies Inc).

STATISTICAL ANALYSIS

Differences between 2 or more means were compared by unpaired *t* test (2 means) and Fisher exact test. Multivariate analysis was performed by 2-way analysis of variance followed by the Duncan multiple range test (≥ 2 means) and Bonferroni post hoc testing using a statistical analysis software package (SPSS, version 17.0; SPSS Inc). Significance was defined for $P < .05$.

RESULTS

IN VIVO EFFICACY ANALYSIS

To examine the efficacy of HA-cisplatin in vivo, tumor volumes were monitored in the mice. The control animals

(PBS and HA-only groups) demonstrated a standard exponential tumor growth curve, with tumor volumes exceeding 1200 mm³ by 6 weeks after inoculation, leading to humane killing per the animal care protocol. There was no difference noted in tumor growth curves between the PBS and HA-only control animals, confirming that HA by itself has no direct antitumor activity (**Figure 1**). Of the experimental groups, HA-cisplatin was noted to have a better overall efficacy, with 4 of the 10 mice (40%) showing response to treatment, specifically, 1 animal with a complete clinical response and 3 with a partial response, as well as 1 animal with stable disease. The remaining 5 animals demonstrated progressive disease (**Table**). In the standard cisplatin treatment arm, there were no animals with a complete clinical response, only 1 animal with a partial response, 1 with stable disease, and the remaining 8 animals (80%) with progressive disease (**Table**). When we analyzed the results of response among these treatment groups as a whole, this efficacy was noted to be statistically significant ($P = .003$) (**Figure 1**). A summary of the clinical responses to treatment based on modified RECIST (Response Evaluation Criteria in Solid Tumors) can be found in the **Table**.

IN VIVO TOXICITY ANALYSIS

All mice were monitored for signs of weight loss or deterioration in the body conditioning score as a surrogate clinical marker of treatment toxicity. Animals in both treatment groups demonstrated weight loss; however, the HA-cisplatin-treated mice exhibited the least amount of weight loss (mean [SD] weight loss, 10.8% [4.7%]) compared with the standard cisplatin-treated mice, which exhibited a mean weight loss of 13.6% (5.6%) ($P = .25$) (**Figure 2**). Body score was examined for all treated animals and was based on a scale of 1 to 5, where 1 indicates the mouse is emaciated with the entire vertebral col-

Table. Tumor Response Based on Modified RECIST Criteria

Treatment Group	Animal										
	1	2	3	4	5	6	7	8	9	10	
PBS control	PD	PD	PD	PD	PD	PD	PD	PD	PD	PD	PD
HA-only control	PD	PD	PD	PD	PD	PD	PD	PD	PD	PD	PD
50% MTD cisplatin	PD	PD	PD	PR	PD	PD	PD	SD	PD	PD	PD
50% MTD HA-cisplatin	CR	PR	PD	PD	PD	PR	SD	PD	PR	PD	PD

Abbreviations: CR, clinical response; HA, hyaluronan; MTD, maximum tolerated dose; PBS, phosphate-buffered saline; PD, progressive disease; PR, partial response; RECIST, Response Evaluation Criteria in Solid Tumors; SD, stable disease.

um distinctly visible; 2, the mouse is underconditioned with a segment of vertebral column visible; 3, the mouse is well conditioned; 4, the mouse is overconditioned; and 5, the mouse is obese. In this examination, we noted an appreciable difference between the 2 chemotherapy groups. Although all the mice treated with standard cisplatin sustained a deterioration in body score to a level of 2 or less throughout the study, requiring that they be killed prior to study completion, none of the HA-cisplatin-treated animals exhibited body score deterioration to less than 2 ($P < .01$).

PATHOLOGIC ANALYSIS

In the comparison of the 2 treatment arms, a complete response to treatment was observed in only 1 mouse in the HA-cisplatin group. This was noted grossly as no evidence of visible or palpable tumor (**Figure 3A**); conversely, visible tumor was observed in all mice in the standard cisplatin group (Figure 3B). To confirm the significance of these gross pathologic findings, animal tissues from each treatment group were collected at the time of necropsy and examined histologically for signs of local toxic effects as well as for nephrotoxic and ototoxic effects. These tissues included the tumor injection sites, as well as the bilateral cervical lymph nodes, cochleae, and kidneys. On histologic examination, no animals in the HA-cisplatin group demonstrated nephrotoxic or ototoxic effects. However, the standard cisplatin group demonstrated that half the animals developed nephrotoxic effects, although no animals in this treatment arm displayed any ototoxic effects on examination for cochlear hair cell damage or on acoustic emission testing.

COMMENT

Locally advanced HNSCC remains a challenge to treat successfully. Available chemotherapeutic agents, such as cisplatin, can be effective but are limited in use because of their significant local and systemic toxicities as well as drug resistance. Surgical resection in conjunction with chemoradiotherapy, although useful in reducing tumor burden and extending the time to progression, can be morbid to the patient, with a spectrum of complications ranging from minor sequelae, such as skin and wound infections, to more serious complications, such as chyle leaks, carotid rupture, fistulae, and spinal accessory nerve injuries leading to chronic shoulder dysfunction.^{22,23} These morbidities have been reported in the literature in as many as 60% of pa-

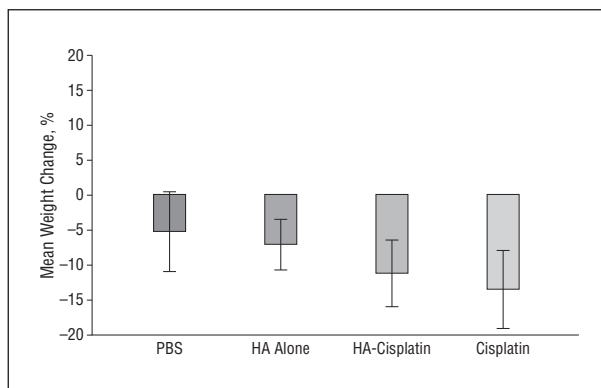


Figure 2. Mean (SD) weight change per treatment group of MDA-1986 Nu/Nu mice.

tients receiving surgical resection.²⁴ Another important therapeutic challenge involves the poor penetration of cytotoxic systemic chemotherapies into the locoregional tumor tissue and lymphatic system. This is due in part to the unidirectionality of lymphatic flow and the separation of the lymphatics from the systemic vasculature.¹⁹ As a result, only a small dose of the drug finally reaches the tumor tissue or the lymph nodes draining the tumor site.

Previous studies have examined the idea of enhanced chemotherapeutic agents for the treatment of head and neck cancer. Some have looked at enhancement of agents such as cisplatin with molecules such as 2-deoxy-D-glucose to increase cytotoxicity through metabolic oxidative stress, which showed promising results.²⁵ Others have begun to examine the role of targeted molecular agents in the treatment of HNSCC, whether in combination with agents such as cisplatin or as stand-alone agents.²⁶ Still other head and neck studies have examined the use of nanoparticles in the role of tumor suppression in HNSCC models,²⁷ but no studies, to our knowledge, have looked at the combination of nanoparticles with chemotherapeutic agents in a head and neck cancer model. Lymphatically delivered chemotherapy is a novel drug-delivery approach that has been shown to be effective in other cancer models, such as breast cancer, using single agents such as cisplatin in conjugation with nanoscopic-molecular-weight HA. Previous reports have shown that in vivo usage of this carrier with cisplatin demonstrated improved locoregional delivery of the drug to the site of greatest tumor burden in a locally advanced breast cancer model, with improved efficacy and decreased toxicity compared with the standard drug formulations.¹⁶⁻¹⁸ Although this mechanism

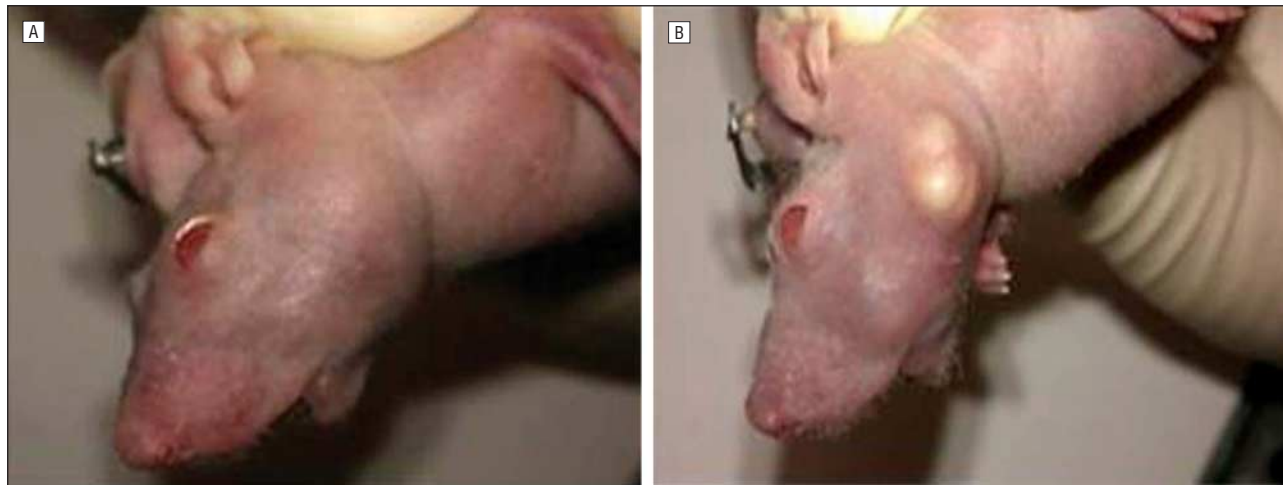


Figure 3. Photographs of tumor response in Nu/Nu mice after treatment. A, A mouse treated with nanocarrier (hyaluronan [HA])–conjugated cisplatin (HA-cisplatin). B, A mouse treated with standard cisplatin.

provides a boost in locoregional delivery, these previous experiments showed no loss of systemic penetration with these agents. Once the HA is cleaved from the drug by hyaluronidase in the lymphatics, the unconjugated chemotherapeutic agent is then released into the system, providing a mechanism for systemic delivery. Previous studies^{15,17} of these nanoconjugated agents in comparison with standard agents have been performed to measure systemic absorption. Those studies demonstrated comparable levels of systemic penetration between the nanoconjugates and standard therapy. Also, intratumoral and lymphatic levels of HA-cisplatin compared with systemic cisplatin demonstrated significantly increased levels of cisplatin at these sites in the HA-cisplatin group.¹³

The results of the present study demonstrate that HA-cisplatin treatment significantly improves efficacy (as demonstrated by better RECIST tumor response) over standard treatment when delivered at 50% MTDs in a murine model of locally advanced HNSCC. The nanoconjugate group had a 40% response rate (4 animals), with a 10% complete clinical response rate (1 animal) compared with an overall 10% partial response rate (1 animal) in the standard current cisplatin therapy at 50% MTD. Therefore, even at 50% of standard treatment doses, the nanoconjugate demonstrated superior efficacy.

The standard treatment of 50% MTD cisplatin resulted in significant morbidity and mortality, with all mice requiring humane killing before study completion because of significant clinical toxic effects as evidenced by decreased body scores and long-term weight loss. In contrast, this was not seen in the 50% MTD HA-cisplatin group, although a roughly 10% weight loss was noted in this group during treatment. In similar studies with HA-cisplatin in a locally advanced breast cancer model, this 10% weight loss was noted to be transient when the mice were observed for a longer period, and it was no longer present beyond 3 weeks after the completion of treatment. Because the present study followed up the mice for a total of 3 weeks after the completion of treatment, it is unclear whether the weight loss noted in the HA-cisplatin group is also transient or is a permanent effect. Although nephrotoxic effects were demonstrated in the

standard treatment group and not in the nanoconjugate group, ototoxic effects were not demonstrated in either group. Ototoxicity is a prevalent complication in human dosing of cisplatin, but it is believed to result from a cumulative dose effect. Therefore, it is likely that this sequela was not seen in the standard group because the short treatment course of 3 weeks and the reduced 50% MTD dose were not enough to create the cumulative dose effect that would result in ototoxic effects. Further translational investigation with longer follow-up and treatment regimens will provide an improved understanding of the chronic toxicity of the HA-cisplatin treatment.

In conclusion, this study demonstrates that nanoconjugated therapy with HA-cisplatin exhibits improved anticancer efficacy against a murine model of locally advanced HNSCC compared with standard cisplatin therapy at the same dose with a reduced toxicity profile. This effect was evident even with a reduced (50% MTD) dose of cisplatin. The limitations of this study include a small sample size for each group, a short (3-week) duration of therapy, and a short follow-up. Also, the nature of this short study does not address the efficacy of this treatment against distant metastases. Despite these limitations, statistical significance was observed when we compared antitumor efficacy and body scores between the HA-cisplatin–treated mice and the standard cisplatin–treated group.

Because this system uniquely targets the lymphatics and provides a locoregional boost without the loss of systemic penetration, it has potential to be translated clinically in patients who have locally advanced HNSCC, with a goal of reducing tumor burden and lymphatic disease before surgical resection to improve recurrence rates and possibly even survival. Other prospective applications include using it as a potential treatment for patients with locoregional recurrence in whom traditional systemic agents have failed due to toxic effects or drug resistance, in which a locoregional boost could limit the drug's systemic toxicity and improve locoregional tumor penetration to potentially overcome resistance. Finally, given its ability to improve antitumor efficacy with a reduced dose, this nanoconjugated agent could be extremely useful when combined with concurrent radiotherapy in the adjuvant treat-

ment of HNSCC. Data from this study, however, provide a solid foundation for additional translational proof-of-concept studies to advance this delivery system toward potential clinical applications in which novel treatment strategies that carry less toxicity and improved efficacy are needed for patients with advanced HNSCC.

Submitted for Publication: July 17, 2012; final revision received October 16, 2012; accepted November 20, 2012.

Correspondence: Yelizaveta Shnayder, MD, Department of Otolaryngology–Head and Neck Surgery, The University of Kansas Medical Center, 3901 Rainbow Blvd, Mail Stop 3010, Kansas City, KS 66160 (yshnayder@kumc.edu).

Author Contributions: Drs S. M. Cohen, Mukerji, and Shnayder had full access to all the data in the study and take responsibility for the integrity of the data and the accuracy of the data analysis. *Study concept and design:* Mukerji, Durham, Forrest, Cai, and Shnayder. *Acquisition of data:* S. M. Cohen, Rockefeller, and Mukerji. *Analysis and interpretation of data:* S. M. Cohen, Rockefeller, M. S. Cohen, and Shnayder. *Drafting of the manuscript:* S. M. Cohen. *Critical revision of the manuscript for important intellectual content:* All authors. *Statistical analysis:* S. M. Cohen, Rockefeller, and M. S. Cohen. *Obtained funding:* Shnayder. *Administrative, technical, and material support:* Rockefeller, Mukerji, Forrest, and Cai. *Study supervision:* S. M. Cohen, Mukerji, M. S. Cohen, and Shnayder. **Conflict of Interest Disclosures:** Drs Forrest and Cai have proprietary interest in patent 8 088 412 on the use of HA for drug delivery and have interest in a company that has licensed this technology. Dr M. S. Cohen is CEO of Nanopharm LLC, in which he has ownership interest but has received no financial revenues to date. He also reports having received a Susan G. Komen Foundation Career Catalyst Grant.

Funding/Support: The MDA-1986 cells were a gift from Jeffrey Myers, MD, PhD, of The University of Texas, MD Anderson Cancer Center, Houston. This work was completed through research grant–funding support from the American Academy of Otolaryngology–Head and Neck Surgery/American Head and Neck Society Centralized Otolaryngology Research Efforts (CORE) Grant Program Young Investigator Award (principal investigator [PI], Dr Shnayder; coinvestigators, Drs Durham, Forrest, and M. S. Cohen), Susan G. Komen Foundation Career Catalyst Grant KG090481 (PI, Dr M. S. Cohen), grant RSG-08-133-01-CDD from the American Cancer Society (PI, Dr Forrest; coinvestigator, Dr M. S. Cohen), grant NFP51505 (RGS-08-133-01-CDD) to The University of Kansas Center for Research from the American Cancer Society (PI, Dr Forrest; coinvestigator, Dr M. S. Cohen), and research support from the Departments of Surgery and Head and Neck Surgery, The University of Kansas, Kansas City.

REFERENCES

1. Jemal A, Siegel R, Xu J, Ward E. Cancer statistics, 2010. *CA Cancer J Clin*. 2010; 60(5):277-300.
2. Siegel R, Naishadham D, Jemal A. Cancer statistics, 2012. *CA Cancer J Clin*. 2012; 62(1):10-29.
3. Marur S, Forastiere AA. Head and neck cancer: changing epidemiology, diagnosis, and treatment. *Mayo Clin Proc*. 2008;83(4):489-501.
4. Kim L, King T, Agulnik M. Head and neck cancer: changing epidemiology and public health implications. *Oncology (Williston Park)*. 2010;24(10):915-919, 924.
5. Ragin CC, Modugno F, Gollin SM. The epidemiology and risk factors of head and neck cancer: a focus on human papillomavirus. *J Dent Res*. 2007;86(2):104-114.
6. Cooper JS, Pajak TF, Forastiere AA, et al; Radiation Therapy Oncology Group 9501/Intergroup. Postoperative concurrent radiotherapy and chemotherapy for high-risk squamous-cell carcinoma of the head and neck. *N Engl J Med*. 2004;350(19):1937-1944.
7. Goon PK, Stanley MA, Ebmeyer J, et al. HPV & head and neck cancer: a descriptive update. *Head Neck Oncol*. 2009;1:36. doi:10.1186/1758-3284-1-36.
8. Pignon JP. Meta-analysis of therapeutic trials: some leads for evaluating their quality and interpreting them. *Gynecol Obstet Fertil*. 2000;28(7-8):493-494.
9. Adelstein DJ, Saxton JP, Rybicki LA, et al. Multiagent concurrent chemoradiotherapy for locoregionally advanced squamous cell head and neck cancer: mature results from a single institution. *J Clin Oncol*. 2006;24(7):1064-1071.
10. Hartmann JT, Kollmannsberger C, Kanz L, Bokemeyer C. Platinum organ toxicity and possible prevention in patients with testicular cancer. *Int J Cancer*. 1999; 83(6):866-869.
11. Adelstein DJ, Li Y, Adams GL, et al. An intergroup phase III comparison of standard radiation therapy and two schedules of concurrent chemoradiotherapy in patients with unresectable squamous cell head and neck cancer. *J Clin Oncol*. 2003;21(1):92-98.
12. Zuur CL, Simis YJ, Verkaik RS, et al. Hearing loss due to concurrent daily low-dose cisplatin chemoradiation for locally advanced head and neck cancer. *Radiother Oncol*. 2008;89(1):38-43.
13. Conley BA. Treatment of advanced head and neck cancer: what lessons have we learned? *J Clin Oncol*. 2006;24(7):1023-1025.
14. Adair JH, Parette MP, Altinoğlu EI, Kester M. Nanoparticulate alternatives for drug delivery. *ACS Nano*. 2010;4(9):4967-4970.
15. Xie Y, Bagby TR, Cohen MS, Forrest ML. Drug delivery to the lymphatic system: importance in future cancer diagnosis and therapies. *Expert Opin Drug Deliv*. 2009; 6(8):785-792.
16. Cai S, Thati S, Bagby TR, et al. Localized doxorubicin chemotherapy with a biopolymeric nanocarrier improves survival and reduces toxicity in xenografts of human breast cancer. *J Control Release*. 2010;146(2):212-218.
17. Cai S, Xie Y, Bagby TR, Cohen MS, Forrest ML. Intralymphatic chemotherapy using a hyaluronan-cisplatin conjugate. *J Surg Res*. 2008;147(2):247-252.
18. Cohen SM, Mukerji R, Cai S, Damjanov I, Forrest ML, Cohen MS. Subcutaneous delivery of nanoconjugated doxorubicin and cisplatin for locally advanced breast cancer demonstrates improved efficacy and decreased toxicity at lower doses than standard systemic combination therapy in vivo. *Am J Surg*. 2011;202(6):646-653.
19. Chen JH, Ling R, Yao Q, et al. Effect of small-sized liposomal Adriamycin administered by various routes on a metastatic breast cancer model. *Endocr Relat Cancer*. 2005;12(1):93-100.
20. Feleszko W, Zagodzón R, Gołab J, Jakóbsiak M. Potentiated antitumor effects of cisplatin and lovastatin against MmB16 melanoma in mice. *Eur J Cancer*. 1998;34(3):406-411.
21. Graeser R, Esser N, Unger H, et al. INNO-206, the (6-maleimidocaproyl) hydrazine derivative of doxorubicin, shows superior antitumor efficacy compared to doxorubicin in different tumor xenograft models and in an orthotopic pancreas carcinoma model. *Invest New Drugs*. 2010;28(1):14-19.
22. Carvalho AP, Vital FM, Soares BG. Exercise interventions for shoulder dysfunction in patients treated for head and neck cancer. *Cochrane Database Syst Rev*. 2012;4:CD008693.
23. Corey JP, Caldarelli DD, Hutchinson JC Jr, et al. Surgical complications in patients with head and neck cancer receiving chemotherapy. *Arch Otolaryngol Head Neck Surg*. 1986;112(4):437-439.
24. Newman JP, Terris DJ, Pinto HA, Fee WE Jr, Goode RL, Goffinet DR. Surgical morbidity of neck dissection after chemoradiotherapy in advanced head and neck cancer. *Ann Otol Rhinol Laryngol*. 1997;106(2):117-122.
25. Simons AL, Ahmad IM, Mattson DM, Dornfeld KJ, Spitz DR. 2-Deoxy-D-glucose combined with cisplatin enhances cytotoxicity via metabolic oxidative stress in human head and neck cancer cells. *Cancer Res*. 2007;67(7):3364-3370.
26. Schrader C, Boehm A, Reiche A, Dietz A, Mozet C, Wichmann G. Combined effects of lapatinib and cisplatin on colony formation of head and neck squamous cell carcinoma [published correction appears in *Anticancer Res*. 2012;32(9):4169]. *Anticancer Res*. 2012;32(8):3191-3199.
27. Piao L, Zhang M, Datta J, et al. Lipid-based nanoparticle delivery of pre-miR-107 inhibits the tumorigenicity of head and neck squamous cell carcinoma. *Mol Ther*. 2012;20(6):1261-1269.