

University of Massachusetts Medical School
eScholarship@UMMS

[Open Access Articles](#)

[Open Access Publications by UMMS Authors](#)

2018-12-04

Explantation of infected thoracic endovascular aortic repair

Emily Y. Fan

University of Massachusetts Medical School

Et al.

Let us know how access to this document benefits you.

Follow this and additional works at: <https://escholarship.umassmed.edu/oapubs>



Part of the [Bacterial Infections and Mycoses Commons](#), [Surgery Commons](#), and the [Surgical Procedures, Operative Commons](#)

Repository Citation

Fan EY, Judelson DR, Schanzer A. (2018). Explantation of infected thoracic endovascular aortic repair. Open Access Articles. <https://doi.org/10.1016/j.jvscit.2018.02.010>. Retrieved from <https://escholarship.umassmed.edu/oapubs/3706>

Creative Commons License



This work is licensed under a [Creative Commons Attribution-NonCommercial-No Derivative Works 4.0 License](#). This material is brought to you by eScholarship@UMMS. It has been accepted for inclusion in Open Access Articles by an authorized administrator of eScholarship@UMMS. For more information, please contact Lisa.Palmer@umassmed.edu.

Explantation of infected thoracic endovascular aortic repair

Emily Y. Fan, BA,^a Dejah R. Judelson, MD,^b and Andres Schanzer, MD,^b Worcester, Mass

ABSTRACT

Prosthetic graft infection is a rare and serious complication of thoracic endovascular aortic repair associated with high mortality and posing unique challenges for treatment. The prosthetic graft infection is often identified late as patients present with mild nonspecific symptoms. We describe the successful medical management and surgical explantation of an infected thoracic endograft with an aorta-bronchial fistula, using an inline reconstruction with an antibiotic-soaked synthetic graft. In this report, we provide an example of a patient with an infected thoracic endograft and how inline reconstruction combined with appropriate medical management is an acceptable treatment strategy. (J Vasc Surg Cases and Innovative Techniques 2018;4:307-10.)

Thoracic endovascular aortic repair (TEVAR) is the accepted standard treatment strategy for adults presenting with blunt thoracic aortic injury (BTAI).^{1,2} Multiple studies have validated reduced morbidity and mortality of TEVAR compared with open repair.¹⁻³ With the evolution of TEVAR devices designed specifically for BTAI and multidisciplinary guidelines⁴ recommending TEVAR as the treatment of choice, reports have documented improved overall survival as well as decreased rates of device-related complications in applying TEVAR for BTAI.⁵

Endoleaks, device infection, and acute thrombosis have all been reported as rare complications from TEVAR.^{6,7} Infection is often discovered late, following prolonged fevers of unknown origin, and can be associated with aorta-esophageal or aorta-bronchial fistulas. Whereas the incidence of graft infection after endovascular aneurysm repair has been studied extensively and documented to occur in the range of 0.16% to 1.37%,^{8,9} the incidence of graft infection after TEVAR is less certain because of the relative rarity of this condition and is estimated to be approximately 1.7%.¹⁰ Although both medical and surgical management of TEVAR graft infections have been described,¹¹⁻¹³ there is no consensus on the standard of care.

This report describes the successful treatment of a TEVAR graft infection, secondary to an aorta-bronchial

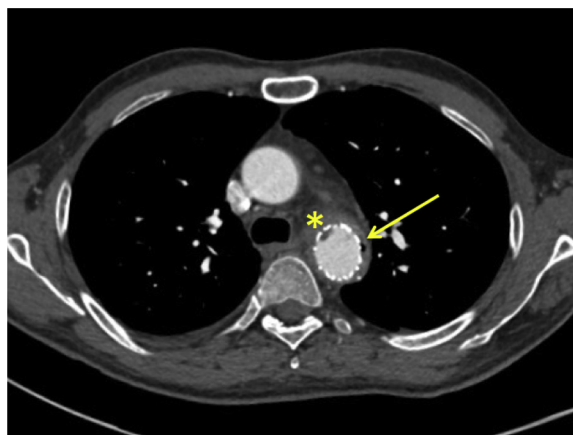


Fig 1. Air between the endograft and native wall of the aorta (*arrow*) and a vegetation adhering to the aortic endograft (*star*) are demonstrated on a preoperative axial computed tomography angiography scan.

fistula, that presented 17 years after the index repair. The patient provided consent to have this case published.

CASE REPORT

A 45-year-old man presented 17 years after a high-speed motor vehicle accident in which he sustained multiple injuries including a BTAI with near aortic transection (grade 3).¹⁴ He underwent an exploratory laparotomy with splenectomy and repair of a bladder injury. Because of his overall health, he was deemed at too high risk for a thoracotomy, so his aortic repair was performed with a compassionate use Gore TAG Endoprosthesis (W. L. Gore & Associates, Flagstaff, Ariz) measuring 26 mm × 7 cm with bilateral femoral cutdowns. The injury was 2.5 cm from the left subclavian artery; there was partial inadvertent coverage of the left subclavian artery with only 8 mm Hg of blood pressure difference between the arms. Several years later, he had thrombosis of the left subclavian artery that required a stent graft at the origin of the left subclavian artery.

Unfortunately, he was lost to follow-up after 3 years of surveillance. Eight months before his current presentation, he was evaluated at an outside hospital for a 1-week history of fever, chills, and malaise; he completed an outpatient course of

From the University of Massachusetts Medical School^a; and the Division of Vascular and Endovascular Surgery, University of Massachusetts Medical School.^b

Author conflict of interest: none.

Correspondence: Dejah R. Judelson, MD, Assistant Professor of Surgery, Division of Vascular and Endovascular Surgery, University of Massachusetts Medical School, 55 Lake Ave N, S3-743, Worcester, MA 01655 (e-mail: dejah.judelson@umassmemorial.org).

The editors and reviewers of this article have no relevant financial relationships to disclose per the Journal policy that requires reviewers to decline review of any manuscript for which they may have a conflict of interest.

2468-4287

© 2018 The Authors. Published by Elsevier Inc. on behalf of Society for Vascular Surgery. This is an open access article under the CC BY-NC-ND license (<http://creativecommons.org/licenses/by-nc-nd/4.0/>).

<https://doi.org/10.1016/j.jvscit.2018.02.010>

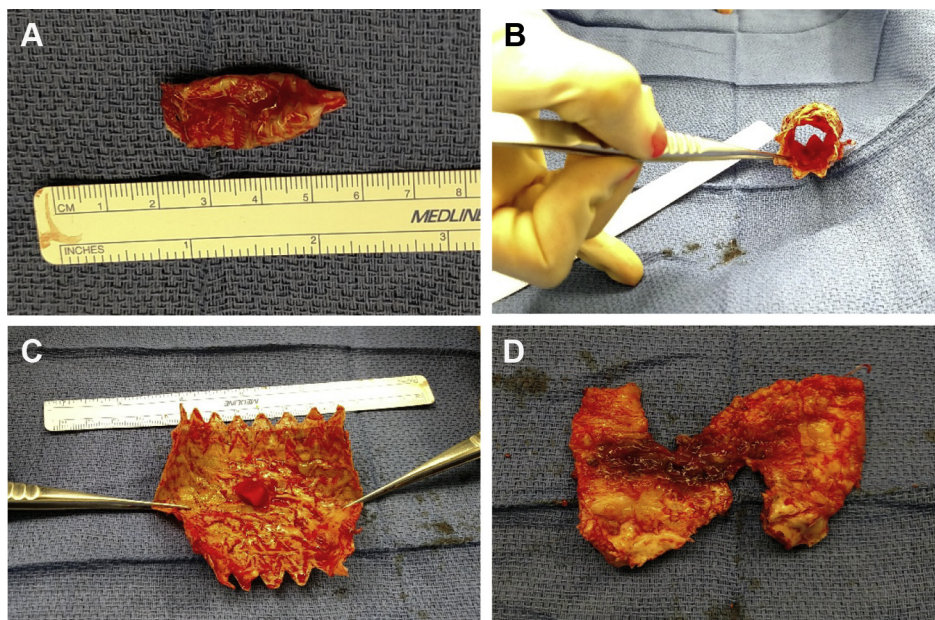


Fig 2. **A**, Intraoperative resection of aorta-bronchial fistula between the left upper lobe of the lung and the aortic endograft. **B** and **C**, Excised aortic endograft with an intraluminal vegetation. **D**, Portion of the excised infected native descending thoracic aorta.

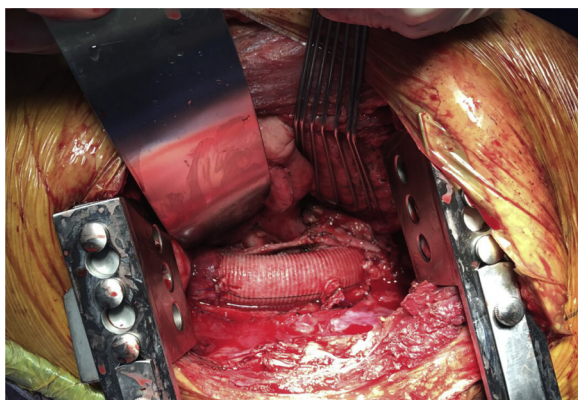


Fig 3. Inline anatomic reconstruction of the descending thoracic aorta with a rifampin antibiotic-soaked Dacron graft.

antibiotics for pneumonia. Two months later, he presented again with prolonged fevers and chills with *Streptococcus viridans* and *Mycoplasma* bacteremia that was treated with an inpatient course of parenteral antibiotics. During the subsequent 6 months, he continued to have intermittent fevers and a 30-pound weight loss. He presented to our institution with high fevers and sepsis from *Staphylococcus capitis* bacteremia and was admitted to the intensive care unit. Transthoracic echocardiography revealed two freely mobile pedunculated vegetations within the thoracic aortic endograft, the largest measuring 1 cm without evidence of valvular vegetations. Computed tomography angiography of the chest revealed a right lower lobe consolidation with collapse and bilateral pleural effusions. The thoracic aortic endograft extended from the aortic arch, abutting the left subclavian stent graft. The native

aortic wall around the stent graft was diffusely thickened with several foci of air between the graft and the native wall of the aorta (Fig 1).

We proceeded with an open surgical explantation of the aortic endograft and left subclavian artery stent graft, aortic débridement, and inline reconstruction with a rifampin antibiotic-soaked prefabricated Dacron graft. Other considered options included extra-anatomic bypass with an axillobifemoral bypass (given his young age, we were concerned about the decreased long-term patency with this approach)¹⁵ and reconstruction with cryopreserved aorta (an adequate size match for his thoracic aorta was not available).

The chest was entered through a left posterolateral thoracotomy at the fourth intercostal space. Dense adhesions between the left upper lobe of the lung and the aortic wall were dissected, revealing a focal abscess that penetrated the aortic wall to the fabric of the endograft, consistent with an aortopulmonary fistula (Fig 2, A). A wedge resection of this portion of involved lung was performed using a 60-mm TA stapler (Covidien, Mansfield, Mass). Under hypothermic circulatory arrest down to 16.3°C, the aortic endograft (Fig 2, B and C), left subclavian artery stent graft, and proximal descending thoracic aorta (Fig 2, D) were all excised with wide débridement. Inline anatomic reconstruction of the aorta was performed using a 24-mm rifampin-soaked Dacron graft, as previously described (Fig 3).¹⁶ There was no tissue coverage. The patient was extubated with no immediate complications.

Intraoperative cultures from the endograft, aortic wall, and vegetations grew *Candida*. With consultation of our infectious disease colleagues, he was initiated on lifelong oral antifungal (fluconazole) therapy and a short course of broad-spectrum antibiotics. His postoperative course was complicated by a

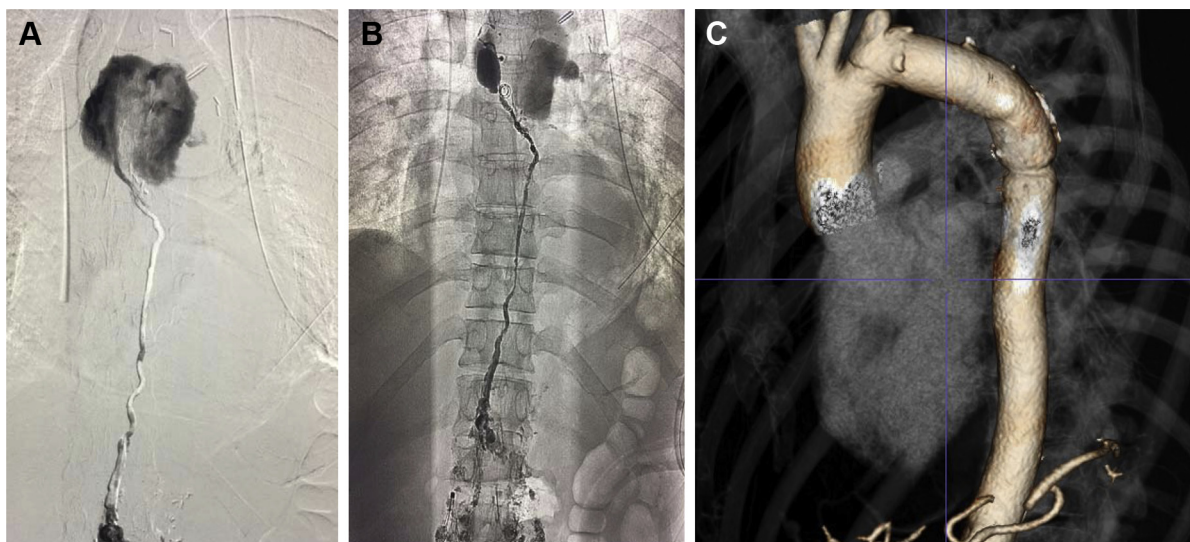


Fig 4. Postoperative chylothorax secondary to thoracic duct disruption (**A**) that was treated successfully with percutaneous coil embolization and Onyx glue (**B**). **C**, Reconstruction image obtained 2 months postoperatively demonstrates thoracic aorta with excellent patency.

chylothorax, which was initially managed with total parenteral nutrition but ultimately required coil embolization and Onyx glue (ev3, Covidien, Plymouth, Minn) obliteration of the thoracic duct (Fig 4, A and B). He was discharged home on postoperative day 11. At 2 months, computed tomography angiography demonstrated a patent repair and no evidence of infection (Fig 4, C). He is still doing well at his 6-month postoperative check.

DISCUSSION

As TEVAR continues to become more commonplace in younger patients, managing complications of these endografts will become increasingly important. We describe the treatment of an infected endograft 17 years after TEVAR for a BTAI. Patients who require explantation because of infection have poorer outcomes than those with endoleaks or inadequate aneurysm exclusion because of underlying sepsis and the extent of resection required.¹⁷ Mortality rates have been reported to be as high as 83% to 100% at 2 months for those treated with medical management only,^{12,18} whereas the addition of surgical explantation has been shown to have an overall 5-year survival of 51%.¹⁸ Infections of thoracic endografts are difficult to manage because the source is often discovered late if at all. Most patients present with prolonged fevers of unknown origin, weight loss, or general malaise. In addition, thoracic graft infections are often associated with fistula to an adjacent organ (as in this case, the lung) that is not identified until the time of surgery, which can lead to even higher mortality.

Surgical excision of all prosthetic material with wide débridement remains the “gold standard” treatment. Aortic reconstruction can be performed in situ using prosthetic grafts, cryopreserved arterial allografts, or an extra-anatomic bypass. We used an inline reconstruction with a rifampin-soaked graft after wide débridement.

Previous studies have demonstrated excellent results using antibiotic-soaked grafts, with studies reporting low rates of reinfection and excellent graft patency.¹⁹

A key adjunct for this surgical approach is for early medical management targeted toward the specific pathogen causing the infection. Identifying the source of infection in a timely manner is critically important. This patient had recent bacteremia that never fully resolved, associated with a pneumonia that caused partial lung collapse, pleural effusions, and an aorta-bronchial fistula that eroded into the endograft. He was started on broad-spectrum antibiotics immediately after admission, and the regimen was later tailored to the microbiology results; now he is receiving lifelong antifungal therapy.

Our case was complicated by a postoperative chylothorax, a rare but serious injury. The reported incidence of thoracic duct injuries ranges from 0.5% to 2%.²⁰ It can lead to nutritional deficiencies, respiratory dysfunction, and immunosuppression with a mortality rate of up to 50%.²¹ Whereas conservative management has been reported with low-fat diets or drainage by chest tubes, the overall failure rate is high, and more than half will require surgical intervention later.²² His chylothorax was treated by direct cannulation of the cisterna chyli and definitive coiling of the thoracic duct. His chest tube output ceased immediately after this procedure and did not recur after normal diet was reinitiated.

CONCLUSIONS

The treatment of infected thoracic endografts is challenging and associated with high morbidity and mortality. With prompt detection of infection and aggressive surgical treatment with appropriate antibiotic therapy,

they can be successfully managed. Complete long-term freedom from reinfection remains unclear and requires lifelong imaging surveillance.

REFERENCES

- Demetriades D, Velmahos GC, Scalea TM, Jurkovich GJ, Karmy-Jones R, Teixeira PC, et al. Operative repair or endovascular stent graft in blunt traumatic thoracic aortic injuries: results of an American Association for the Surgery of Trauma multicenter study. *J Trauma* 2008;64:561-70.
- Lee WA, Matsumura JS, Mitchell RS, Farber MA, Greenberg RK, Azzizadeh A, et al. Endovascular repair of traumatic thoracic aortic injury: clinical practice guidelines of the Society for Vascular Surgery. *J Vasc Surg* 2011;53:187-92.
- Tang GL, Tehrani HY, Usman A, Katariya K, Otero C, Perez E, et al. Reduced mortality, paraplegia, and stroke with stent graft repair of blunt aortic transections: a modern meta-analysis. *J Vasc Surg* 2008;47:671-5.
- Heneghan RE, Aarabi S, Quiroga E, Gunn ML, Singh N, Starnes BW. Call for a new classification system and treatment strategy in blunt aortic injury. *J Vasc Surg* 2016;64:171-6.
- Dubose JJ, Leake SS, Brenner M, Pasley J, O'Callaghan T, Luo-Owen X, et al. Contemporary management and outcomes of blunt thoracic aortic injury: a multicenter retrospective study. *J Trauma Acute Care Surg* 2015;78:360-9.
- LeMaire SA, Green SY, Kim JH, Sameri A, Parenti JL, Lin PH, et al. Thoracic or thoracoabdominal approaches to endovascular device removal and open aortic repair. *Ann Thorac Surg* 2012;93:726-32.
- Turney EJ, Steenberge SP, Lyden SP, Eagleton MJ, Srivastava SD, Sarac TP, et al. Late graft explants in endovascular aneurysm repair. *J Vasc Surg* 2014;59:886-93.
- Vogel TR, Symons R, Flum DR. The incidence and factors associated with graft infection after aortic aneurysm repair. *J Vasc Surg* 2008;47:264-9.
- Cernohorsky P, Reijnen MM, Tielliu IF, van Sterkenburg SM, van den Dungen JJ, Zeebregts CJ. The relevance of aortic endograft prosthetic infection. *J Vasc Surg* 2011;54:327-33.
- Chiesa R, Melissano G, Marone EM, Marrocco-Trischitta MM, Kahlberg A. Aorto-esophageal and aortobronchial fistulae following thoracic endovascular aortic repair: a national survey. *Eur J Vasc Endovasc Surg* 2010;39:273-9.
- Riesenman PJ, Farber MA. Management of a thoracic endograft infection through an ascending to descending extra-anatomic aortic bypass and endograft explantation. *J Vasc Surg* 2010;51:207-9.
- Murphy EH, Szeto WY, Herdrich BJ, Jackson BM, Wang GJ, Bavaria JE, et al. The management of endograft infections following endovascular thoracic and abdominal aneurysm repair. *J Vasc Surg* 2013;58:1179-85.
- Gagne-Loranger M, Dumont E, Voisine P, Mohammadi S, Dagenais F. Arch to descending aorta extra-anatomic aortic repair for thoracic stent graft infection. *Can J Cardiol* 2016;32:135.e13-5.
- Azizzadeh A, Keyhani K, Miller CC, Coogan SM, Safi HJ, Estrera AL. Blunt traumatic aortic injury: initial experience with endovascular repair. *J Vasc Surg* 2009;49:1403-8.
- Oderich GS, Bower TC, Cheery KJ, Panneton JM, Sullivan TM, Noel AA, et al. Evolution from axillofemoral to in situ prosthetic reconstruction for the treatment of aortic graft infections at a single center. *J Vasc Surg* 2005;43:1166-74.
- Bandyk DF, Novotney ML, Johnson BL, Back MR, Roth SR. Use of rifampin-soaked gelatin-sealed polyester grafts for in situ treatment of primary aortic and vascular prosthetic infections. *J Surg Res* 2001;95:44-9.
- Arya S, Coleman DM, Knepper J, Henke PK, Upchurch GR, Rectenwald JE, et al. Outcomes after late explantation of aortic endografts depend on indication for explantation. *Ann Vasc Surg* 2013;27:865-73.
- Smeds MR, Duncan AA, Harlander-Locke MP, Lawrence PF, Lyden S, Fatima J, et al. Treatment and outcomes of aortic endograft infection. *J Vasc Surg* 2016;63:332-40.
- Oderich GS, Bower TC, Hofer J, Kalra M, Duncan AA, Wilson JW, et al. In situ rifampin-soaked grafts with omental coverage and antibiotic suppression are durable with low reinfection rates in patients with aortic graft enteric erosion or fistula. *J Vasc Surg* 2011;53:99-106.
- Fahimi H, Casselman FP, Mariani MA, van Boven WJ, Knaepen PJ, van Swieten HA. Current management of postoperative chylothorax. *Ann Thorac Surg* 2001;71:448-51.
- Graham DD, McGahren ED, Tribble CG, Daniel TM, Rodgers BM. Use of video-assisted thoracic surgery in the treatment of chylothorax. *Ann Thorac Surg* 1994;57:1507-12.
- Inderbitzi RG, Krebs T, Stirneman T, Ulrich A. Treatment of postoperative chylothorax by fibrin glue application under thoracoscopic view with use of local anesthesia. *J Thorac Cardiovasc Surg* 1992;104:209-10.

Submitted Nov 24, 2017; accepted Feb 19, 2018.