

Marquette University
e-Publications@Marquette

School of Dentistry Faculty Research and
Publications

Dentistry, School of

8-1-2011

Lubricin Immunohistochemical Expression in Human Temporomandibular Joint Disc with Internal Derangement

Rosalia Leonardi
University of Catania

Luis Eduardo Almeida
Marquette University, luis.almeida@marquette.edu

Carla Loreto
University of Catania

Accepted version. *Journal of Oral Pathology & Medicine*, Vol. 40, No. 7 (August 2011): 587-592. DOI.

© 2011 John Wiley & Sons A/S. Used with permission.

Luis Eduard Almeida was affiliated with Center for Health and Biological Sciences, Pontifical Catholic University of Paraná, Curitiba, Brazil at the time of publication.

Marquette University

e-Publications@Marquette

Dentistry Faculty Research and Publications/School of Dentistry

This paper is NOT THE PUBLISHED VERSION; but the author's final, peer-reviewed manuscript. The published version may be accessed by following the link in the citation below.

Journal of Oral Pathology & Medicine, Vol. 40, No. 7 (August 2011): 587-592. [DOI](#). This article is © Wiley and permission has been granted for this version to appear in [e-Publications@Marquette](#). Wiley does not grant permission for this article to be further copied/distributed or hosted elsewhere without the express permission from Wiley.

Lubricin immunohistochemical expression in human temporomandibular joint disc with internal derangement

Rosalia Leonardi

Department of Dentistry, Faculty of Dentistry, University of Catania, Policlinico Universitario, Catania, Italy

Luis Eduardo Almeida

School of Dentistry, Marquette University, Milwaukee, WI, USA

Center for Health and Biological Sciences, Pontifical Catholic University of Paraná, Curitiba, Brazil

Carla Loreto

Department of Anatomy, Diagnostic Pathology, Forensic Medicine, Hygiene and Public Health, University of Catania, Catania, Italy

Abstract

Lubricin is a chondroprotective, mucinous glycoprotein which contribute to joint lubrication, especially to boundary lubrication and maintains joint integrity. The present investigation aimed to study the immunolocalization of lubricin in TMJ discs from patients affected by anterior disc displacement with reduction (ADDwR) ADDwoR. Eighteen TMJ displaced disc affected by ADDwoR were processed immunohistochemically, with a polyclonal anti-lubricin antibody, used at 1:50 working dilution. The percentage of lubricin immunopositive cells (extent score = ES) and the extent of lubricin staining of the disc extracellular matrix

(ECM), were evaluated. Each sample was scored for histopathological changes. Percentage of immunostained surface disc cells was the same (ES = 4) in both control and ADDwOR cells, being this data not statistically significant ($P < 0.05$). In pathological specimens the percentages of lubricin-stained cells was very high with an ES of 4 respect to control specimen, and this difference was statistically significant different ($P > 0.05$). The extracellular matrix (ECM) of discs at the disc surfaces of both pathological and normal specimens was very heavily stained (++++). Both the ES and ECM staining were not statistically correlated to the TMJ degeneration score according to the Spearman's rank correlation coefficient. According to our findings, a longstanding TMJ disc injury, affects lubricin expression in the TMJ disc tissue and not its surfaces, moreover, lubricin immunostaining is not correlated to TMJ disc histopathological changes.

Keywords

Derangement, disc, lubrication, temporomandibular joint disorders

Introduction

Disc displacement or internal derangement (ID) of the temporomandibular joint (TMJ) is defined as an abnormal positional relationship of the disc relative to the mandibular condyle and the articular eminence (1). There are two common types of ID: as an anterior disc displacement with reduction (ADDwR) and an anterior disc displacement without reduction (ADDwoR) (2, 3). ID is a frequent condition that has been documented by clinical, anatomical, radiographical and surgical observations (4, 5). It should be noted that ID frequently precedes the onset of TMJ osteoarthritis (OA). The process of TMJ-OA is characterized by degenerative joint changes, such as deterioration and abrasion of articular cartilage and disc surfaces, as well as occurrence of thickening and remodelling of the underlying bone. Nevertheless, little is known about the aetiopathogenic mechanisms leading to disc displacement as investigations did not reach consistent results (6-10).

Trauma, functional overloading, joint laxity, lack of lubrication, hyperactivity of the lateral pterygoid muscle as well as occlusal factors have also been mentioned in this respect (4). Actually, it is believed that the most significant aberration of all suggested processes, terminating in disc displacement, is an increase in joint friction (6), because of a reduction in boundary lubrication. As a consequence, joint lubrication can be considered of great importance for a better understanding of the pathophysiology of the TMJ diseases (11).

Several molecules present in synovial fluid have been reported to contribute to joint lubrication, especially to boundary lubrication (1, 6). Among them, a mucinous glycoprotein called lubricin. Lubricin is a chondroprotective, mucinous glycoprotein, which is a product of the proteoglycan 4 (PRG4) gene, and is homologous to molecules referred to as superficial zone protein (SZP). Lubricin, also known as SZP, megakaryocyte stimulating factor, hemangiopoietin or PRG4 has been found in a number of tissues, including synovial membrane and fluid (12-14), superficial zone of cartilage (15), tendon (16) and meniscus (17, 18). The essential role for lubricin, in maintaining joint integrity, has been demonstrated through the identification of disease-causing mutations in patients with the autosomal recessive disorder camptodactyly-arthropathy-coxa vara-pericarditis syndrome (19).

As far as the TMJ is concerned, several reviews (6, 11, 20) have underlined the importance of lubricin as a biochemical factor associated with the regulation of TMJ lubrication. Nonetheless, data from these investigations were based on joints other than TMJ. In fact, except for one study which demonstrated the importance of lubricin in bovine mandibular condyle cartilage (15), no data are available for TMJ disc. Accordingly, the present investigation aimed to study the immunolocalization of lubricin in TMJ discs from patients affected by ADDwoR vs. normal TMJ discs, to determine any difference between these two samples in the percentage of disc cells that contained lubricin and the degree of extracellular matrix (ECM) staining.

Materials and methods

Patients and tissues

Eighteen TMJ-displaced disc specimens were collected from consecutive patients treated between 2002 and 2009 at the University of Pontifical Catholic University of Paraná, Brazil. Sixteen virtually unaffected human TMJ discs were studied along with the pathological material. After project approval by the ethic committee of the same University, informed consent was obtained from each patient before tissue collection.

The discs (10 from the right TMJ and 8 from the left) were obtained from 14 female and 4 male patients, affected by ADDwoR, as confirmed by their clinical history, examination and magnetic resonance imaging studies. The mean age of all patients was 43.2 ± 5.4 years. The diagnosis that led to surgery was disc derangement with associated pain and impairment of function. These patients had been unsuccessfully non-surgical treated before surgery and had TMJ pain or interference with mandibular movements. TMJ discs from patients with other TMJ diseases, dentofacial deformity, major jaw trauma, previous TMJ surgery and previous steroid injections in the TMJ were not included in this study.

All the surgically removed patients' discs were macroscopically deformed, none of the discs having a normal biconcave shape.

The previously mentioned sixteen autopsy TMJ disc specimens were obtained bilaterally from eight cadavers (three males and five females). The mean period (and standard deviation) between the death of the donor and tissue harvest was 14 ± 2 h. The cadaver donors' mean age was 44 ± 6 years, at the time of death. The causes of death of the donors were cardiovascular disease and cancer.

None of the donors' clinical history revealed generalized joint disease or TMJ arthropathy. Macroscopic examination of the discs showed no signs of degenerative or inflammatory joint disease nor disc displacement and no pathological changes at microscopic examination. The original sample collection, previously used in former studies ([21-25](#)), was from the Institute of Anatomy at the University of Catania, Catania, Italy. Both patients and autopsy specimens included the anterior band, intermediate band and the posterior band.

Immunohistochemistry

The discs were fixed overnight in 10% neutral-buffered formalin (Bio-Optica, Milan, Italy). After fixation and overnight washing, each disc was sectioned through its centre along a parasagittal plane, perpendicular to its long axis. Each tissue block was dehydrated in graded ethanol and embedded in paraffin, preserving the longitudinal anatomical orientation. Specimens were sectioned at a thickness of $5 \mu\text{m}$ using a microtome, placed on silanized glass slides (the anterior band being always on the right side of the slides), and warmed at 60°C for a minimum of 2 h to ensure proper tissue adhesion to the slides prior to immunohistochemical staining. The TMJ disc sections were deparaffinized in xylene and rehydrated in reagent alcohol, and then, they were treated with hydrogen peroxide for 10 min to quench endogenous peroxidase activity. Then the sections were heated ($5 \text{ min} \times 3$) in capped polypropylene slide holders with citrate buffer (pH 6), using a microwave oven (750 W) to unmask antigenic sites. Non-specific binding site blocking was achieved by treating the specimens with 5% horse serum for 30 min.

For immunohistochemical staining, we used a rabbit polyclonal anti-lubricin antibody (Novus Biologicals, LLC, Littleton, CO, USA), used at 1:50 working dilution. The antibody was applied onto sections, and afterwards, they were incubated overnight at 4°C in a moist chamber. The secondary antibody, biotinylated anti-mouse/anti-rabbit IgG was applied (for 30 min, at RT), followed by the avidin-biotin-peroxidase complex (Vector Elite Kit Abbott, Chicago, IL, USA) for 30 min, at room temperature. The immunoreaction was visualized by incubating the sections for 4 min in a 0.1% 3,3'-diaminobenzidine and 0.02% hydrogen peroxide solution (DAB substrate kit; Vector Laboratories, Burlingame, CA, USA). The sections were lightly counterstained with Mayer's

haematoxylin (Histolab Products AB, Goteborg, Sweden) and finally mounted in GVA mount (Zymed Laboratories Inc., San Francisco, CA, USA).

Evaluation of immunohistochemistry

The lubricin-staining status was identified as either negative or positive. The percentage of lubricin immunopositive cells (extent score = ES) was independently evaluated and scored as a percentage of the final number of 100 cells in four categories: 0 = <5%; 1 = 6–30%; 2 = 31–50%; 3 = >51–75% and 4 = >76–100%. Counting was performed at ×200 magnification. Positive staining was defined as the presence of a brown detection chromogen on the edge of the haematoxylin-stained cell nucleus, distributed within the cytoplasm, or in the immediate lacunar/pericellular space. We also graded the lubricin staining of the disc ECM according to 0 to ++++ scale with the arbitrary cut-offs: 0 = none; + = up to 25% of the area; ++ = 26–50% of the area; +++ = 51–75% of the area and ++++ = 76–100% of the area at ×200 magnification. Three different TMJ disc tissue compartments were analysed, namely the central region (i.e. the inner portion) of the disc and the temporal (superior) and condylar (inferior) disc surfaces.

Positive and negative controls

Positive and negative controls were performed to test the specific reaction of primary antibodies used in this study at a protein level. For positive control testing, the sections from bovine calf stifle joint underwent an immunoperoxidase process (17). The positive immunolabelling for lubricin was both perinuclear and cytoplasmic. For negative control testing, sections of TMJ displaced discs were randomly drawn from degenerated disc samples. These were then treated with normal rabbit serum instead of the specific antibodies.

Histopathological degeneration grading score

One of three sections for each disc was stained with haematoxylin & eosin (H&E), to assign a histopathological degeneration score. Briefly, this score takes into account pathological disc tissue transformation, i.e. collagen bundles, non-specific degenerative changes and the presence of blood vessels. This grading system results in a score ranging from 0 up to 8 for heavily degenerated disc tissue (26).

Statistical analysis

Mean values and standard deviations were obtained for the ES and ECM staining of three disc portions examined in each sample. Data were further analysed using Mann–Whitney *U*-tests to evaluate any significant statistical difference, both for pathological and for normal discs. Comparisons were made based on the anatomical region of the disc, i.e. central portion, as well as superior and inferior disc surfaces. The non-parametric Spearman rank correlation test was used to obtain the correlation coefficient between the lubricin staining of the extracellular matrix and the percentage of cells staining for lubricin. *P*-values of <0.05 were considered statistically significant. All data were analysed with the SPSS program (SPSS® release 16.0; SPSS, Chicago, IL, USA).

Results

All TMJ patients had been unsuccessfully treated with other, various, interventions, for at least 6 months before surgery. Diseased TMJ disc sections, stained with haematoxylin (routine staining), showed a different severity of morphological damage, ranging from an altered collagen bundles architecture to the fragmentation of collagen bundles. A decrease in cellularity was appreciated too, in the more damaged discs. In contrast, the control discs showed a preservation of multidirectional collagen bundles; predominately fibrocyte-like cell populations with few chondrocyte-like cell aggregates; absence of clefts and/or fraying.

The average TMJ disc degeneration score of our TMJ ADDwoR disc sample was 3.52 ± 1.17 .

Every TMJ disc sections, from pathological and control samples, displayed lubricin-positive immunohistochemical staining, although to a different extent. Lubricin staining within the TMJ disc cells was ubiquitous and appreciated in fibroblast-like cells, fibrochondrocytes or chondrocyte-like cells. In almost all cells, immunostaining was cytoplasmic or pericellular in nature ([Fig. 1](#)). Percentage of immunostained surface disc cells was the same (ES = 4) in both control and ADDwoR cells, being this data not statistically significant ($P > 0.05$). In the two samples, no statistically significant difference ($P > 0.05$) was obtained when comparing cell immunolabelling at the superior and inferior disc surfaces between. On the other hand, in the inner portion of the disc, the percentage of immunolabelled cells was statistically significant different ($P < 0.05$) between the two samples. In pathological specimens, the percentage of lubricin-stained cells was very high with an ES of 4 being cells immunostained in almost all of the cases ([Fig. 2](#)). In control specimens, this percentage was lower with an ES of 2, thus no more of 50% of cells were immunolabelled in each field. In fact, not every cell was immunolabelled by lubricin antibody, in the inner portion of the discs ([Table 1](#)).

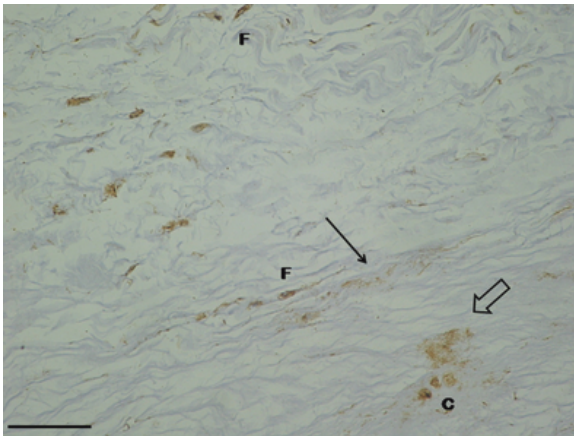


Figure 1

Control temporomandibular joint (TMJ) disc specimen. Lubricin staining evidenced by brown chromogen in the different cell phenotypes of TMJ disc, fibroblast-like cells (f) and chondrocyte-like cells (c). Chromogen deposition appears granular (empty arrow) or band-like (arrow) at and/or between adjacent collagen bundles. Bar 50 \times .

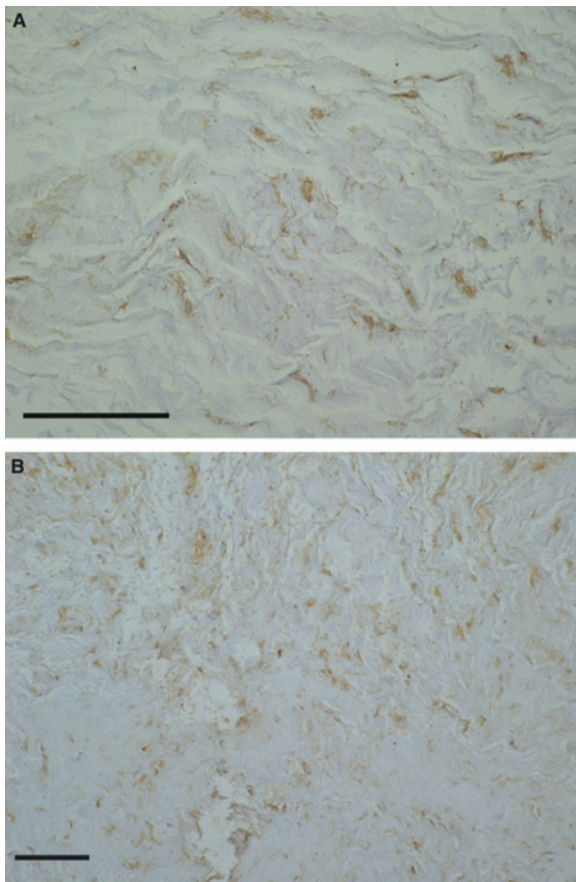


Figure 2

Immunohistochemical staining of human control temporomandibular joint (TMJ) disc (A) and TMJ disc affected by ADDwoR (B). Extracellular matrix is much more heavily stained in diseased disc specimen. Bar 100 \times .

Table 1. Extent score and extracellular matrix immunostaining for lubricin in normal temporomandibular joint (TMJ) disc and anterior disc displacement without reduction (ADDwoR)

	Number of specimens	ES at the disc surfaces	ES at the disc inner portion	ECM staining at the disc surfaces	ECM staining at the disc inner portion
Normal TMJ discs	16	4	2	++++	+
ADDwoR TMJ disc	18	4	4	++++	+++ (12 discs of 18) ++ (6 discs of 18)

Extent score (ES) = percentage of lubricin immunolabelled cells: 0 = <5%; 1 = 6–30%; 2 = 31–50%; 3 = 51–75% and 4 = >76–100%. Lubricin staining of the disc extracellular matrix (ECM): 0 = none; + = up to 25% of the area; ++ = 26–50% of the area; +++ = 51–75% of the area and ++++ = 76–100%.

Within the ECM of discs, lubricin immunolabelling was observed in every disc specimen, although to a different extent, according to the disc region (Figs 1–3). ECM at the disc surfaces of both pathological (Fig. 3) and normal specimens was very heavily stained (++++ by lubricin antibody. On the contrary in the inner portion, ADDwoR discs were moderately immunolabelled in some instances, but a faint (+) or high immunostaining (+++) was also appreciated in few other specimens (Fig. 2). In control disc specimens, at the same topographical area, it was always observed a faint staining (+). This ECM staining was particularly noted at the interface of collagen fibre bundles, and it was characterized by intense chromogen deposition that appeared granular or band-like at and/or between adjacent collagen bundles (Fig. 1) (Table 1). Newly formed vessels and areas of chondroid metaplasia were heavily immunostained by lubricin antibody (Fig. 4A,B).

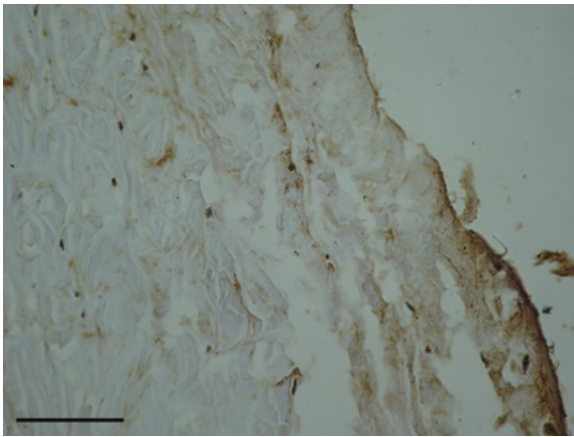


Figure 3

Lubricin staining on disc surface. On the disc surface, both cells and extracellular matrix are immunolabelled by lubricin antibodies. Bar 200 \times .

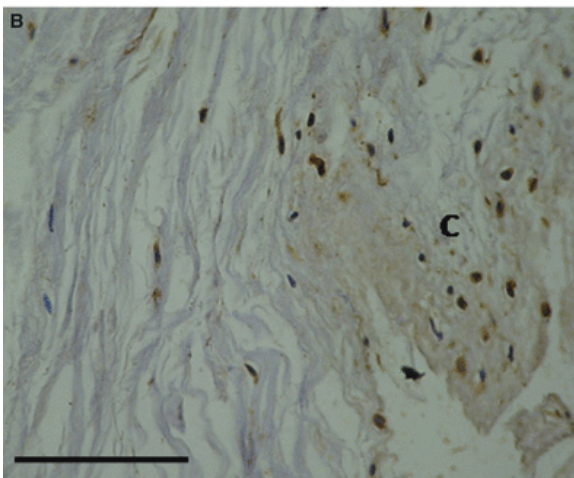
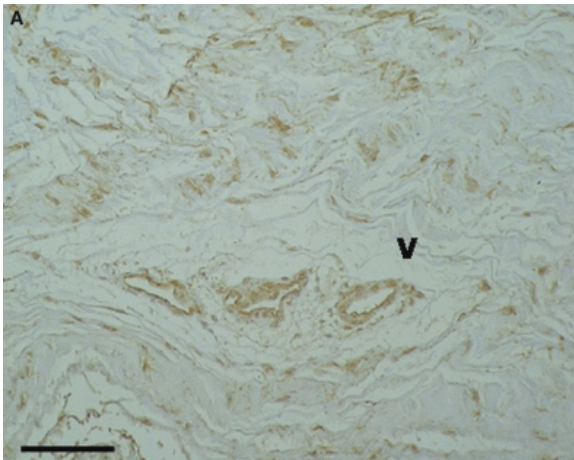


Figure 4

Diseased disc specimen from temporomandibular joint. Lubricin is immunohistochemically detected in newly formed blood vessels (V) inside the disc (A) and in area of chondroid (C) metaplasia (B). Bar 100 \times .

Both the ES and ECM staining were not statistically correlated to the TMJ degeneration score according to the Spearman's rank correlation coefficient.

No chromogen was detected in any of the 20 negative control disc sections.

Discussion

In fact, optimal functionality of synovial joints depends on maintaining extremely low coefficients of friction. In this respect, lubricin acts as a vital counteragent against aberrant protein and/or cellular adhesion, infiltration and overproliferation and serves as a critical boundary lubricant between opposing articular surfaces ([12](#), [13](#), [27](#), [28](#)), in such a way that alterations in its metabolism may profoundly impact joint function. A recent study has shown that lubricin expression may vary with health and disease, and it is involved in joint osteoarthritis ([29](#)). Several investigations have been carried out on joints ([12](#), [16](#), [18](#), [30](#)) other than TMJ, and to the authors' knowledge, this is the first report regarding the presence of lubricin in human TMJ discs affected by ADDwoR.

Data from this study demonstrated that lubricin is significantly overexpressed at a protein level in cells of the inner portion of the discs affected by ADDwoR respect to the control specimen. Differences in lubricin immunostaining, although not statistically significant, were detected also for ECM; in fact, lubricin immunolabelling in some instances was more heavily expressed in TMJ with ADDwoR. The presence of lubricin in the extracellular matrix suggests a lubricin release from disc cells, diffusing through the tissue. This overexpression of lubricin in macroscopically deformed TMJ disc affected by ADDwoR may be explained both by mechanical and by biochemical factors. In ID with ADDwoR, the disc is permanently displaced or dislocated remaining in an incorrect position, and the jaw's range of motion is limited ([2](#), [3](#)), meanwhile several cytokines are released in TMJ disc synovial fluid (SF) and tissue. In this respect, numerous investigations have demonstrated that different load conditions may alter disc cell biosynthesis of a variety of molecules, and several studies in other musculoskeletal tissues support that lubricin expression can be regulated by mechanical stimuli ([31](#)). Accordingly, it has been reported that lubricin is expressed by chondrocytes from the superficial zone of cartilage, because the cells are subjected to more shear force than those in the deeper zones. Furthermore, lubricin has been detected, also, in load-bearing regions of meniscus ([17](#)).

Lubricin biosynthesis varies also in response to growth factors and cytokines. It has been assumed that the proinflammatory cytokines initiate a cascade of events that lead to a decrease in joint lubrication and an increase in joint damage. Although, later the lubricin levels eventually return to normal or they are even upregulated, ongoing damage has been initiated ([32](#)). However, it has also been demonstrated that lubricin expression is downregulated by pro-inflammatory cytokines, such as interleukin-1 beta, interleukin-6 and tumour necrosis factor alpha ([32](#)). On the contrary, transforming growth factor beta increased lubricin synthesis, secretion and cartilage boundary association. Therefore, a dysregulation of lubricin metabolism, under the influence of elevated cytokine concentrations in diseased or damaged joints, might thereby lead to lubrication changes and loss-of-function ([27](#)). The overexpression of lubricin at an immunohistochemical level, detected in our sample of ADDwoR TMJ discs, corroborates previous findings obtained in long-standing joint injury. In fact, it has been reported that following injury ([32](#)) in the SF of injured joints, lubricin levels were significantly lower compared with the contralateral joints at the early stage following injury, but normal lubricin levels were approached within 12 months, and a significant increase in the lubricin concentration with time post-injury was recorded later ([32](#)). The lack of any correlation between the extent of lubricin staining of the TMJ disc cell and extracellular matrix with ADDwoR and the histopathological score obtained in our sample is in accordance with previous findings, which reported that the extent of lubricin present in the intervertebral disc extracellular matrix and native disc cells was independent of the Thompson grade ([33](#)).

Thus, according to our findings, a long-standing TMJ disc injury affects lubricin expression in the TMJ disc tissue and not its surfaces; moreover, lubricin immunostaining is not correlated to TMJ disc histopathological changes.

Understanding the factors that may lead to, or result from, disc displacement is essential not only to permit the choice of optimal treatment but also to develop preventive treatment modalities ([6](#)). The fact that lubricin is constitutively expressed in TMJ disc and it is overexpressed during long-standing disease deserves further

studies to correlate its expression to the time of disease onset and cytokine expression to choose the proper kind of treatment.

New therapeutic perspectives, in fact, are going to be opened, for joints other than TMJ, that could be beneficial in the treatment of TMJ diseases, at least at the early beginning of disease (15, 34-36). These strategies consist of rescuing lubricin dysfunction. Moreover, the capacity for recombinant lubricin to effectively bind to and lubricate articular cartilage surfaces suggests therapeutic implications for the delivery of applicable biolubricant formulations.

References

1. Wilkes, CH. Internal derangements of the temporomandibular joint. Pathological variations. *Arch Otolaryngol Head Neck Surg* 1989; 115: 469– 77.
2. Nebbe, B, Major, PW. Prevalence of TMJ disc displacement in a pre-orthodontic adolescent sample. *Angle Orthod* 2000; 70: 454– 63.
3. Sato, S, Goto, S, Kawamura, H, Motegi, K. The natural course of nonreducing disc displacement of the TMJ: relationship of clinical findings at initial visit to outcome after 12 months without treatment. *J Orofac Pain* 1997; 11: 315– 20.
4. Hall, HD, Werther, JR, Gibbs, SJ. The mechanism of disc displacement. *J Oral Maxillofac Surg* 2001; 59: 961– 2.
5. Limchaichana, N, Nilsson, H, Ekberg, EC, Nilner, M, Petersson, A. Clinical diagnoses and MRI findings in patients with TMD pain. *J Oral Rehabil* 2007; 34: 237– 45.
6. Nitzan, DW. The process of lubrication impairment and its involvement in temporomandibular joint disc displacement: a theoretical concept. *J Oral Maxillofac Surg* 2001; 59: 36– 45.
7. Shibuya, T, Kino, K, Sugisaki, M, *et al.* Comparison of occlusal discomfort in patients with temporomandibular disorders between myofascial pain and disc displacement. *J Med Dent Sci* 2009; 56: 139– 47.
8. Taskaya-Yilmaz, N, Ceylan, G, Incesu, L, Muglali, M. A possible etiology of the internal derangement of the temporomandibular joint based on the MRI observations of the lateral pterygoid muscle. *Surg Radiol Anat* 2005; 27: 19– 24.
9. Bauss, O, Sadat-Khonsari, R, Fenske, C, Engelke, W, Schwestka-Polly, R. Temporomandibular joint dysfunction in Marfan syndrome. *Oral Surg Oral Med Oral Pathol Oral Radiol Endod* 2004; 97: 592– 8.
10. Emshoff, R, Brandlmaier, I, Bertram, S, Rudisch, A. Risk factors for temporomandibular joint pain in patients with disc displacement without reduction - a magnetic resonance imaging study. *J Oral Rehabil* 2003; 30: 537– 43.
11. Tanaka, E, Detamore, MS, Tanimoto, K, Kawai, N. Lubrication of the temporomandibular joint. *Ann Biomed Eng* 2008; 36: 14– 29.
12. Jay, GD, Torres, JR, Warman, ML, Laderer, MC, Breuer, KS. The role of lubricin in the mechanical behavior of synovial fluid. *Proc Natl Acad Sci USA* 2007; 104: 6194– 9.
13. Klein, J. Molecular mechanisms of synovial joint lubrication. *Proc Inst Mech Eng Part J: J Eng Tribol* 2006; 220: 691– 710.
14. Nugent-Derfus, GE, Chan, AH, Schumacher, BL, Sah, RL. PRG4 exchange between the articular cartilage surface and synovial fluid. *J Orthop Res* 2007; 25: 1269– 76.
15. Ohno, S, Schmid, T, Tanne, Y, *et al.* Expression of superficial zone protein in mandibular condyle cartilage. *Osteoarthritis Cartilage* 2006; 14: 807– 13.
16. Funakoshi, T, Schmid, T, Hsu, HP, Spector, M. Lubricin distribution in the goat infraspinatus tendon: a basis for interfascicular lubrication. *J Bone Joint Surg Am* 2008; 90: 803– 14.
17. Schumacher, BL, Schmidt, TA, Voegtline, MS, Chen, AC, Sah, RL. Proteoglycan 4 (PRG4) synthesis and immunolocalization in bovine meniscus. *J Orthop Res* 2005; 23: 562– 8.
18. Shine, KM, Spector, M. The presence and distribution of lubricin in the caprine intervertebral disc. *J Orthop Res* 2008; 26: 1398– 406.

19. Marcelino, J, Carpten, JD, Suwairi, WM, *et al.* CACP, encoding a secreted proteoglycan, is mutated in camptodactyly-arthropathy-coxa vara-pericarditis syndrome. *Nat Genet* 1999; 23: 319– 22.
20. Meng, QG, Long, X. A hypothetical biological synovial fluid for treatment of temporomandibular joint disease. *Med Hypotheses* 2008; 70: 835– 7.
21. Leonardi, R, Lo Muzio, L, Bernasconi, G, Caltabiano, C, Piacentini, C, Caltabiano, M. Expression of vascular endothelial growth factor in human dysfunctional temporomandibular joint discs. *Arch Oral Biol* 2003; 48: 185– 92.
22. Leonardi, R, Loreto, C, Barbato, E, *et al.* MMP-13 (collagenase 3) localization in human temporomandibular joint discs with internal derangement. *Acta Histochem* 2008; 110: 314– 8.
23. Leonardi, R, Villari, L, Piacentini, C, Bernasconi, G, Baciliero, U, Travali, S. CD44 standard form (CD44H) expression and distribution in dysfunctional human temporomandibular joint discs. *Int J Oral Maxillofac Surg* 2000; 29: 296– 300.
24. Loreto, C, Musumeci, G, Leonardi, R. Chondrocyte-like apoptosis in temporomandibular joint disc internal derangement as a repair-limiting mechanism. An in vivo study. *Histol Histopathol* 2009; 24: 293– 8.
25. Leonardi, R, Villari, L, Bernasconi, G, Piacentini, C, Baciliero, U, Travali, S. Cellular S-100 protein immunostaining in human dysfunctional temporomandibular joint discs. *Arch Oral Biol* 2000; 45: 411– 8.
26. Leonardi, R, Rusu, MC, Loreto, C. Temporomandibular joint disc: a proposed histopathological degeneration grading score system. *Histol Histopathol* 2010; 25: 1117– 22.
27. Schmidt, TA, Gastelum, NS, Nguyen, QT, Schumacher, BL, Sah, RL. Boundary lubrication of articular cartilage – role of synovial fluid constituents. *Arthritis Rheum* 2007; 56: 882– 91.
28. Wright, V, Dowson, D. Lubrication and cartilage. *J Anat* 1976; 121: 107– 18.
29. Young, AA, McLennan, S, Smith, MM, *et al.* Proteoglycan 4 downregulation in a sheep meniscectomy model of early osteoarthritis. *Arthritis Res Ther* 2006; 8: R41.
30. Jay, GD, Haberstroh, K, Cha, CJ. Comparison of the boundary-lubricating ability of bovine synovial fluid, lubricin, and Healon. *J Biomed Mater Res* 1998; 40: 414– 8.
31. Grad, S, Lee, CR, Wimmer, MA, Alini, M. Chondrocyte gene expression under applied surface motion. *Biorheology* 2006; 43: 259– 69.
32. Elsaid, KA, Fleming, BC, Oksendahl, HL, *et al.* Decreased lubricin concentrations and markers of joint inflammation in the synovial fluid of patients with anterior cruciate ligament injury. *Arthritis Rheum* 2008; 58: 1707– 15.
33. Shine, KM, Simson, JA, Spector, M. Lubricin distribution in the human intervertebral disc. *J Bone Joint Surg Am* 2009; 91: 2205– 12.
34. Flannery, CR, Zollner, R, Corcoran, C, *et al.* Prevention of Cartilage Degeneration in a Rat Model of Osteoarthritis by Intraarticular Treatment with Recombinant Lubricin. *Arthritis Rheum* 2009; 60: 840– 7.
35. Jones, ARC, Flannery, CR. Bioregulation of lubricin expression by growth factors and cytokines. *Eur Cell Mater* 2007; 13: 40– 5.
36. Khalafi, A, Schmid, TM, Neu, C, Reddi, AH. Increased accumulation of superficial zone protein (SZP) in articular cartilage in response to bone morphogenetic protein-7 and growth factors. *J Orthop Res* 2007; 25: 293– 303.