

Marquette University
e-Publications@Marquette

School of Dentistry Faculty Research and
Publications

Dentistry, School of

9-1-2012

Expression and Localization of aquaporin-1 in Temporomandibular Joint Disc with Internal Derangement

Carla Loreto
University of Catania

Concetta Galanti
University of Catania

Luis Eduardo Almeida
Marquette University, luis.almeida@marquette.edu

Rosalia Leonardi
University of Catania

Giuseppe Pannone
University of Foggia

See next page for additional authors

Accepted version. *Journal of Oral Pathology & Medicine*, Vol 41, No. 8 (September 2012): 642-647.

DOI. © 2012 John Wiley & Sons, Inc. Used with permission.

Luis Eduardo Almeida was affiliated with Center for Health and Biological Sciences, Pontifical Catholic, University of Paraná, Curitiba, Brazil at the time of publication.

Authors

Carla Loreto, Concetta Galanti, Luis Eduardo Almeida, Rosalia Leonardi, Giuseppe Pannone, Giuseppe Musumeci, Maria Luisa Carnazza, and Rosario Caltabiano

Marquette University

e-Publications@Marquette

Dentistry Faculty Research and Publications/School of Dentistry

This paper is NOT THE PUBLISHED VERSION; but the author's final, peer-reviewed manuscript.

The published version may be accessed by following the link in the citation below.

Journal of Oral Pathology & Medicine. Vol. 41. No. 8 (2012): 642-647. [DOI](#). This article is © Wiley and permission has been granted for this version to appear in [e-Publications@Marquette](#). Wiley does not grant permission for this article to be further copied/distributed or hosted elsewhere without the express permission from Wiley.

Expression and Localization of Aquaporin-1 in Temporomandibular Joint Disc with Internal Derangement

Carla Loreto

Department of Biomedical Sciences, University of Catania, Catania, Italy

Concetta Galanti

Department of Dentistry, University of Catania, Policlinico Universitario, Catania, Italy

Luis Eduardo Almeida

Center for Health and Biological Sciences, Pontifical Catholic, University of Paraná, Curitiba, Brazil

Rosalia Leonardi

Department of Dentistry, University of Catania, Policlinico Universitario, Catania, Italy

Guiseppe Pannone

Department of Surgical Sciences, Institute of Pathology and Cytopathology, University of Foggia, Foggia, Italy

Guiseppe Musmucei

Department of Biomedical Sciences, University of Catania, Catania, Italy

Maria Luisa Carnazza

Department of Biomedical Sciences, University of Catania, Catania, Italy

Rosario Caltabiano

Department of Anatomy, Diagnostic Pathology, Forensic Medicine, Hygiene and Public Health, University of Catania, Catania, Italy

Abstract

Background: Internal derangement is the most frequent arthropathy affecting the temporomandibular joint, where its commonest form is anterior disc displacement with or without reduction. Despite the frequency of the disorder, the biochemical features of displaced discs are still unclear.

Methods: We investigated the expression pattern and localization of aquaporin-1, an important channel protein involved in plasma membrane water permeability, in patients with anterior disc displacement (both with and without reduction), with a view to assessing the characteristics of local tissue responses to the microenvironmental changes induced by abnormal mechanical loading of the displaced disc. Protein expression was studied by immunohistochemistry in different areas of discs from 18 patients with anterior disc displacement with or without reduction and in four normal controls.

Results: A greater proportion of cells immunopositive for aquaporin-1 were detected in diseased than in normal discs. Whereas protein expression was substantially similar in the different areas of normal discs, a significantly larger number of immunopositive cells were detected in the posterior band of displaced discs without reduction and in the anterior and intermediate bands of those with reduction.

Conclusions: These findings suggest that aquaporin-1 is expressed and upregulated in temporomandibular joint with anterior disc displacement (both with and without reduction).

Introduction

Internal derangement (ID), the most common arthropathy affecting the temporomandibular joint (TMJ), involves an anatomical disturbance in the disc–condyle complex. The most frequent type of TMJ ID is anterior disc displacement (ADD) with or without reduction (ADDwR and ADDwoR, respectively). In ADDwR, the disc slides into and out of its normal functional position as the jaw opens and closes; in ADDwoR, it glides anteriorly to a lower resting position, remaining stuck in the anterior joint recess and failing to revert to its normal position with condylar movement. If the disc slips out of place or is displaced, it can prevent proper condyle movement and cause dysfunction. The disc can also deform, becoming misshapen or even torn.

Histologically, disc displacement is associated with degenerative tissue alterations that involve an active cell response with a change in phenotype from fibroblast-like cells to fibrochondrocytes and eventually to chondrocyte-like cells [\(1-4\)](#). The histological features of discs removed from patients with TMJ ID reflect a general remodelling caused by abnormal loading. However, degenerative joint changes are also known to be influenced by the type and degree of disc displacement; advanced ID corresponds to a severely deformed disc configuration [\(2, 5\)](#).

Although TMJ ID is quite common, few data are available on the biochemical characteristics of displaced disc and none on the molecular components involved in water movement into and from disc cells.

Water transport across the cell membrane is vital for the maintenance of homeostasis and tissue function because it has a central role in volume regulation in response to mechanical stimuli and changes in osmolarity (6-13). Water movement across cell membranes also seems to be involved in important processes such as cell migration and differentiation (14-20).

Aquaporin-1 (AQP-1) is a member of a family of hydrophobic transmembrane channel proteins that confer bidirectional water permeability on and allow water movement across cell membranes in the direction of the osmotic gradient. AQP-1 is constitutively expressed in many epithelial, endothelial and other tissues (21-23), where it participates in physiological processes as well as in the counter-current multiplication system and in cerebrospinal fluid formation. AQP-1 is also involved in pathological conditions such as brain oedema (24) and in the invasive growth and metastatic potential of tumours (18). Although its expression is well explored in several tissues and organs, few studies have addressed the joints. These have documented AQP-1 expression mostly in chondrocytes, synoviocytes and synovial microvessels, besides a heightened expression in osteoarticular disorders such as osteoarthritis and rheumatoid arthritis (25-29). AQP-1 expression has been demonstrated in normal human intervertebral disc (IVD) (30) and in aging degeneration of IVD (31), but never in TMJ disc with ID.

We hypothesized that AQP-1 would be expressed in ID and that its expression would be altered as a result of the disruption of TMJ disc tissue homeostasis. This study was devised to investigate AQP-1 immunexpression patterns in patients with anterior disc displacement with reduction (ADDwR) and anterior disc displacement without reduction (ADDwoR) and in three representative disc areas (anterior, intermediate and posterior bands), with a view to assessing the characteristics of local tissue responses to the microenvironmental changes induced by abnormal mechanical loading of the displaced disc.

Materials and methods

Patients and tissues

Surgical TMJ disc specimens from 14 female and four male patients aged 24– 41 years (mean, 34.6 ± 5.4 years) were obtained from the Pontifical Catholic University of Paraná, Brazil. The diagnosis that led to disc excision was a painful disc derangement with impaired function. The diagnosis was based on patient history, physical examination records and magnetic resonance scans. The study was approved by the Ethics Committee of the Pontifical Catholic University of Paraná according to Resolution 196/96 of the National Health Council (registration no. 104). The informed consent of each patient was obtained prior to disc removal. Donor sex, age distribution and symptom severity are detailed in [Tables 1 and 2](#). All patients had previously undergone unsuccessful conservative treatment including bite splinting, chiropractic manipulation, drug therapy and vitamin supplementation, for at least 6 months. Unassisted maximum mouth opening (MMO) was measured with a millimetre ruler as the interincisal distance on MMO as a measure of disease severity. Pain intensity in the preceding week was measured on a 100-point visual analogue scale (VAS) with anchor points 0 for ‘no pain’ and 100 for ‘the worst imaginable pain’.

Table 1. Clinical characteristics of the patients with temporomandibular joint internal derangement

Patient	Ethnicity	Gender (M/F)	Age (years)	Diagnosis	Side affected	
					Right	Left
1	Caucasian	F	33	ADDwR	X	
2	Caucasian	F	38	ADDwR	X	

3	Native American	F	29	ADDwR		X
4	African Brazilian	M	36	ADDwR	X	
5	Native American	F	24	ADDwR		X
6	Caucasian	F	41	ADDwR		X
7	Native American	M	37	ADDwR		X
8	Caucasian	F	28	ADDwR	X	
9	Caucasian	F	25	ADDwR	X	
10	Native American	F	34	ADDwR		X
11	Native American	F	35	ADDwR	X	
12	Caucasian	F	40	ADDwoR	X	
13	African Brazilian	M	33	ADDwoR	X	
14	African Brazilian	F	36	ADDwoR		X
15	Native American	F	28	ADDwoR		X
16	Caucasian	M	41	ADDwoR	X	
17	Caucasian	F	40	ADDwoR	X	
18	African Brazilian	F	39	ADDwoR		X

ADDwR, anterior disc displacement with reduction; ADDwoR, anterior disc displacement without reduction.

Table 2. Pain on maximum mouth opening (MMO) reported by patients with reference to a visual analogue scale (VAS); anchor points 0 ('no pain') and 100 ('worst imaginable pain'). Values are mean \pm standard deviation (SD)

	Age		MMO		VAS	
	Mean	SD	Mean	SD	Mean	SD
ADDwR	32.7	5.5	35.6	5.1	78	6
ADDwoR	36.5	4.4	27.3	4.3	87	7

ADDwoR, anterior disc displacement without reduction; ADDwR, anterior disc displacement with reduction.

Discectomy has come under increasing attack as the standard therapy for disc displacement, because a number of surgeons now favour a conservative approach; nonetheless, several researchers still believe in its value (32-34). Open surgery for ID therefore has an ethical justification. This small sample of whole TMJ discs was used because they provide exhaustive information on degree of disc degeneration.

Inclusion criteria were unsuccessful non-surgical management, a diagnosis of TMJ ID, and tenderness to TMJ palpation or interference with mandibular movement. Exclusion criteria were other TMJ disorders, dentofacial deformity, major jaw trauma, previous TMJ surgery, and previous steroid injections in the TMJ.

After removal, all discs were found to be well preserved; they were macroscopically deformed, and none had a normal biconcave shape. The anterior, intermediate and posterior bands were consistently preserved. Patients were divided into ADDwR and ADDwoR.

Four virtually normal human TMJ discs from cadavers of the collection of the Anatomy Section, Department of Bio-Medical Sciences of Catania University, Italy, were also studied. These paraffin-embedded autopsy specimens from one male and three female subjects (mean age, 49.7 \pm 4.4

years) were selected because the donors' clinical history was negative for generalized joint disease or TMJ arthropathy; none had macroscopic signs of degenerative or inflammatory joint disease on dissection and none were displaced. They stained with Mayer's haematoxylin (Histolab Products AB, Goteborg, Sweden) on light microscopy and exhibited no detectable pathological changes.

Immunohistochemistry

Specimens were fixed overnight in 10% neutral buffer formalin (Bio-Optica, Milano, Italy). After fixation and overnight washing, each disc was sectioned through its centre along a parasagittal plane perpendicular to its long axis. Each tissue block was dehydrated in graded ethanol and embedded in paraffin, preserving the longitudinal anatomical orientation. Specimens were cut into 5- μ m-thick sections and placed on silanised glass slides with the anterior band on the right side of the slide.

Endogenous peroxidase activity was quenched with 3% H₂O₂ for 10 min. Non-specific antibody binding was blocked with normal horse/goat serum diluted 1:20 in phosphate-buffered saline (PBS) with 0.1% bovine serum albumin. Sections were irradiated (5 min \times 3) in capped polypropylene slide-holders with citrate buffer (pH 6.0) using a microwave oven (750 W) to unmask antigen sites. They were then rinsed in PBS and incubated overnight at 4°C in a moist chamber with mouse monoclonal anti-AQP-1 antibody (Santa Cruz Biotechnology, Santa Cruz, CA, USA) diluted 1:50 in PBS. The sections were rinsed again in PBS, and the secondary antibody, biotinylated anti-mouse/anti-rabbit IgG, was applied for 15 min at room temperature (RT), followed by avidin–biotin–peroxidase complex (Vector Elite Kit; Vector Laboratories, Burlingame, CA, USA) for 15 min at RT. The immunoreaction was visualized by incubating the sections for 4 min in 0.1% 3,3'-diaminobenzidine and 0.02% hydrogen peroxide solution (DAB substrate kit; Vector Laboratories). Sections were lightly counterstained with Mayer's haematoxylin and finally mounted in GVA mount (Zymed Laboratories Inc., San Francisco, CA, USA).

Immunohistochemical evaluation

Immunostained slides were evaluated on a consensus basis by three anatomists—who were blinded to sample type, patient identity, clinical status and group identification—using a double-headed light microscope.

The AQP-1 staining status was identified as either negative or positive. Positive staining was the presence of brown chromogen on the cytoplasmic membrane.

Intensity of staining (IS) and the proportion of AQP-1-immunopositive cells in the anterior, intermediate and posterior bands were assessed and recorded. IS was graded on a 0–4 scale as follows: 0 = no detectable staining, 1 = weak staining, 2 = moderate staining, 3 = strong staining and 4 = very strong staining. The percentage of AQP-1-immunopositive cells extent score (ES) was independently evaluated by the three anatomists and scored as a proportion of the final number of 100 cells into four categories: 0 = < 5%, 1 = 6–30%, 2 = 31–50%, 3 = 50–75% and 4 = > 75%. Counting was performed at 200 \times magnification.

The final staining score (FSS) was the sum of IS and ES ([Table 3](#)).

Table 3. Final staining score (FSS), the sum of the staining intensity score (IS) and the extent score (ES), in the three disc areas examined

Subject	Diagnosis	Anterior band			Intermediate band			Posterior band		
		FSS	IS	ES	FSS	IS	ES	FSS	IS	ES
1	ADDwR	5	2	3	7	3	4	3	2	1
2	ADDwR	6	3	3	6	4	2	4	2	2
3	ADDwR	5	2	3	4	3	1	2	1	1
4	ADDwR	6	2	4	5	2	3	3	2	1
5	ADDwR	5	3	2	4	1	3	2	1	1
6	ADDwR	7	3	4	5	2	3	3	2	1
7	ADDwR	8	3	5	6	3	3	4	3	1
8	ADDwR	6	3	3	5	2	3	3	1	2
9	ADDwR	6	4	2	6	2	4	2	1	1
10	ADDwR	7	4	3	5	2	3	4	2	2
11	ADDwR	7	3	4	5	2	3	3	2	1
12	ADDwoR	4	3	1	3	2	1	8	4	4
13	ADDwoR	2	1	1	4	3	1	7	4	3
14	ADDwoR	3	2	1	4	2	2	6	2	4
15	ADDwoR	4	2	2	3	2	1	8	3	5
16	ADDwoR	3	1	2	3	1	2	6	3	3
17	ADDwoR	4	2	2	3	2	1	7	2	5
18	ADDwoR	3	2	1	4	3	1	8	4	4
19	Control	2	1	1	2	1	1	2	1	1
20	Control	2	1	1	3	1	2	3	2	1
21	Control	3	1	2	2	1	1	2	1	1
22	Control	2	1	1	2	1	1	3	2	1

Staining intensity (0, no detectable staining; 1, weak staining; 2, moderate staining; 3, strong staining; 4, very strong staining) and proportion of labelled cells (extent score, 0: <5%; 1: 6–30%; 2: 31–50%; 3: >50%; and 4: >75%). ADDwR, anterior disc displacement with reduction; ADDwoR, anterior disc displacement without reduction.

Positive and negative controls

Positive and negative controls were performed to test the specific reaction of the primary antibody at the protein level. For positive control tests, kidney tissue was exposed to immunoperoxidase. For negative controls, randomly selected TMJ disc sections were treated with normal rabbit serum instead of the specific antibody.

Statistical analysis

All experiments were performed at least in triplicate. Data were analysed using the Mann–Whitney *U*-test; $P < 0.05$ was considered significant. The Mann–Whitney *U*-test was also applied to compare protein expression between disc specimens. Comparisons were made for the anterior, intermediated and posterior bands in ADDwR and ADDwoR patients. All data were analysed with the SPSS program (SPSS® release 16.0; SPSS, Chicago, IL, USA).

Results

While all normal discs had a biconcave shape, the surgical specimens never had a normal shape and consistently showed varying degrees of deformation.

Histological examination of haematoxylin-stained diseased discs showed abnormal collagen fibre arrangement and collagen bundle fragmentation and tearing, whereas multidirectional collagen bundles were preserved in control discs. The deformed discs showed reduced cellularity and altered cell population ratios, with an increase in chondrocyte-like cells that was related to the severity of the morphological damage; in particular, a decreased number of fibroblast-like cells were detected in ADDwoR discs. Chondrocyte-like cell proliferation led to the formation of small islands of chondroid tissue. The discs with ID showed new vessel formation and mucoid degeneration of the disc matrix.

Aquaporin-1 labelling was demonstrated in all disc sections, with different patterns of immunoreactivity being found in the different areas and donor groups. In particular, immunoreactivity was detected in the cell membrane of fibroblast-like cells and fibrochondrocytes.

A greater proportion of AQP-1-immunopositive cells were detected in ADDwR and ADDwoR ($IS = 3$; $ES = 3$) than in normal disc sections ($IS = 1-2$; $ES = 2$). Immunopositivity varied in the different areas of the deformed discs: labelled cells in ADDwoR sections were significantly more numerous ($P < 0.01$) in the posterior band (Fig. 1) than in the anterior (Fig. 2) and intermediate bands (Fig. 3). In addition, a significantly greater proportion of labelled cells were seen in the anterior (+) and intermediate (++) bands of ADDwR compared with the respective ADDwoR bands ($P < 0.05$).

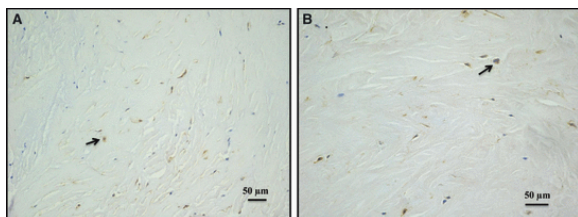


Figure 1 (A) Posterior band of anterior disc displacement without reduction disc. Almost all cells are Aquaporin-1 (AQP-1) immunopositive (200 \times). (B) (400 \times). Black arrows indicate AQP-1-immunopositive chondrocyte-like cells. Bar: 50 μ m.

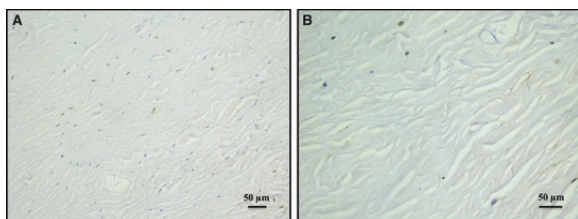


Figure 2 (A) Aquaporin-1 (AQP-1) positivity in anterior band of ADDwoR disc (200 \times). (B) (400 \times). Bar: 50 μ m.

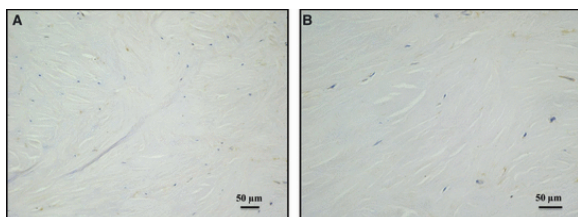


Figure 3 (A) Intermediate band of anterior disc displacement without reduction disc staining for Aquaporin-1 antibody (200×). (B) (400×). Bar: 50 μm .

No difference between disc regions was noted in normal specimens, where AQP-1-immunopositive cells were few and scattered.

Discussion

The present study documents AQP-1 immunoexpression in TMJ discs with ID with and without reduction. AQP-1 expression was upregulated in the diseased discs, albeit with considerable differences between disc bands. In particular, it was strong in ADDwR specimens, where a large proportion of immunopositive cells were detected principally in the anterior and intermediate bands; in specimens from ADDwoR patients, high IS and ES were seen chiefly in the posterior band.

These findings are related to the abnormal compression exerted by the condyle on the disc during anterior disc displacement, which entails different effects on different disc regions in ADDwR and ADDwoR patients. In particular, in the former, disc compression is greater on the anterior band before disc recapture; when the disc is reduced, the stress is exerted on the intermediate zone. In ADDwoR, the maximum compressive stress is exerted on the posterior band [\(35\)](#).

The healthy TMJ also undergoes a variety of functional strains and continuously adapts to changing functional demands to preserve structural and functional integrity. Indeed, AQP-1 expression has recently been demonstrated by our group also in normal TMJ disc [\(36\)](#). Although certain disc areas are more heavily loaded than others during jaw movement or in the jaw-closed position [\(37\)](#), even in healthy joints, we found similar AQP-1 expression in different areas of normal discs [\(36\)](#).

Temporomandibular joint disc displacement is associated with a general remodelling response caused by abnormal mechanical loading, which affects the osmotic environment of disc tissue. The metabolic activity of fibrocartilage cells and of articular cartilage chondrocytes, which have similar features, is influenced by physicochemical factors such as the ionic and osmotic environments, which in turn affect the shape and volume of resident cells. Disc cells are particularly sensitive to the ionic and osmotic characteristics of their physicochemical environment; osmotic stress entails a reorganization of their actin cytoskeleton and activation of various mechanisms to change the cell volume in response to adverse conditions [\(25-29\)](#). Increased AQP-1 expression may be one such mechanism, and its upregulation may be an important adaptive change allowing cell shape and volume regulation in pathological conditions such as TMJ disc displacement.

In a recent study, Wang and Zhu suggest that AQP-1, as an active membrane transport channel that balances concentration gradients, may have a role in facilitating cell adaptability to a number of adverse extracellular matrix environments in aging degeneration of IVD [\(31\)](#). They demonstrated that AQP-1 expression can be affected by extracellular osmolarity and O^2 concentrations and that AQP-1 has O^2 permeability and is upregulated to facilitate O^2 diffusion across the cell membrane in hypoxic conditions. These findings are consistent with the increased AQP-1 immunoexpression found in deformed TMJ disc in the present study.

Aquaporin-1 is also involved in cell migration [\(14\)](#). This process entails the transient formation of cell membrane protrusions (lamellipodia and membrane ruffles) that require rapid local changes in ion fluxes and cell volume, which are probably accompanied by rapid transmembrane water movement

(15, 16). AQP-1-mediated plasma membrane water permeability is known to play an important role in chondrocyte migration (17). These findings suggest that AQP-1 could be involved in cell migration in ADDwR and ADDwoR.

As a protein involved in cell differentiation (18-20), AQP-1 may also play a key role in the changes in cell population ratios that occur in degenerating TMJ disc. Contrary to normal disc, where fibroblast-like cells are the most numerous cell types, fibrochondrocytes and chondrocyte-like cells are the most abundant cell types in deformed discs. The change in cell phenotype and the formation of areas of chondroid metaplasia in the damaged disc is a response to excessive loading and may be strongly influenced by AQP-1 molecular activity.

In conclusion, we provide evidence that AQP-1 is expressed and upregulated in TMJ disc tissue of patients with ADDwR and ADDwoR. In light of these data, further studies are needed to fully characterize the biomolecular and microscopic aspects of TMJ disc with ID.

References

- 1 Loreto, C, Musumeci, G, Leonardi, R. Chondrocyte-like apoptosis in temporomandibular joint disc internal derangement as a repair-limiting mechanism. An in vivo study. *Histol Histopathol* 2009; **24**: 293– 8.
- 2 Loreto, C, Almeida, LE, Trevilatto, P, Leonardi, R. Apoptosis in displaced temporomandibular joint disc with and without reduction: an immunohistochemical study. *J Oral Pathol Med* 2011; **40**:103– 10.
- 3 Leonardi, R, Almeida, LE, Trevilatto, PC, Loreto, C. Occurrence and regional distribution of TRAIL and DR5 on temporomandibular joint discs: comparison of disc derangement with and without reduction. *Oral Surg Oral Med Oral Pathol Oral Radiol Endod* 2010; **109**: 244– 51.
- 4 Leonardi, R, Loreto, C, Barbato, E, Polimeni, A, Caltabiano, R, Lo Muzio, L. A histochemical survey of the human temporomandibular joint disc of patients with internal derangement without reduction. *J Craniofac Surg* 2007; **18**: 1429– 33.
- 5 Leonardi, R, Loreto, C, Barbato, E, *et al.* MMP-13 (collagenase 3) localization in human temporomandibular joint discs with internal derangement. *Acta Histochem* 2008; **110**: 314– 8.
- 6 Guilak, F, Ratcliffe, A, Mow, VC. Chondrocyte deformation and local tissue strain in articular cartilage: a confocal microscopy study. *J Orthop Res* 1995; **13**: 410– 21.
- 7 Guilak, F. The deformation behaviour and viscoelastic properties of chondrocytes in articular cartilage. *Biorheology* 2000; **37**: 27– 44.
- 8 Guilak, F, Erickson, GR, Ting-Beall, HP. The effects of osmotic stress on the viscoelastic and physical properties of articular chondrocytes. *Biophys J* 2002; **82**: 720– 7.
- 9 Lang, F, Busch, GL, Ritter, M, *et al.* Functional significance of cell volume regulatory mechanism. *Physiol Rev* 1998; **78**: 247– 306.
- 10 Ishihara, H, Warensjo, K, Roberts, S, Urban, JP. Proteoglycan synthesis in the intervertebral disk nucleus: the role of extracellular osmolality. *Am J Physiol* 1997; **272**: 1499– 506.
- 11 Mobasher, A, Mobasher, R, Francis, MJ, Trujillo, E, Alvarez de la Rosa, D, Martin-Vasallo, P. Ion transport in chondrocytes: membrane transporters involved in intracellular ion homeostasis and the regulation of cell volume, free [Ca²⁺] and pH. *Histol Histopathol* 1998; **13**: 893– 910.
- 12 Prichard, S, Erickson, GR, Guilak, F. Hyperosmotically induced volume change and calcium signaling in intervertebral disk cells: the role of the actin cytoskeleton. *Biophys J* 2002; **83**: 2502– 10.

- 13 Wuertz, K, Urban, JP, Klase, J, *et al.* Influence of extracellular osmolarity and mechanical stimulation on gene expression of intervertebral disc cells. *J Orthop Res* 2007; **25**: 1513– 22.
- 14 Albertini, R, Bianchi, R. Aquaporins and glia. *Curr Neuropharmacol* 2010; **8**: 84– 91.
- 15 Condeelis, J. Life at the leading edge: the formation of cell protrusions. *Annu Rev Cell Biol* 1993; **9**: 411– 44.
- 16 Lauffenburger, DA, Horwitz, AF. Cell migration: a physically integrated molecular process. *Cell* 1996; **84**: 359– 69.
- 17 Liang, HT, Feng, XC, Ma, TH. Water channel activity of plasma membrane affects chondrocyte migration and adhesion. *Clin Exp Pharmacol Physiol* 2008; **35**: 7– 10.
- 18 Machida, Y, Ueda, Y, Shimasaki, M. Relationship of aquaporin 1, 3, and 5 expression in lung cancer cells to cellular differentiation, invasive growth, and metastasis potential. *Hum Pathol* 2010; **42**: 669– 78.
- 19 Kim, J, Kim, WY, Han, KH, Knepper, MA, Nielsen, S, Madsen, KM. Developmental expression of aquaporin 1 in the rat renal vasculature. *Am J Physiol Renal Physiol* 1999; **276**: 498– 509.
- 20 Xu, H, Zhang, Y, Wei, W, Shen, L, Wu, W. Differential expression of aquaporin-4 in human gastric normal and cancer tissues. *Gastroenterol Clin Biol* 2009; **33**: 72– 6.
- 21 Mobasher, A, Marples, D. Expression of the AQP-1 water channel in normal human tissues: a semiquantitative study using tissue microarray technology. *Am J Physiol Cell Physiol* 2004; **286**: 529– 37.
- 22 Verkman, AS. Aquaporin water channels and endothelial cell function. *J Anat* 2002; **200**: 617– 27.
- 23 Verkman, AS. More than just water channels: unexpected cellular roles of aquaporins. *J Cell Sci* 2005; **118**: 3225– 32.
- 24 Tran, ND, Kim, S, Vincent, HK, *et al.* Aquaporin-1-mediated cerebral edema following traumatic brain injury: effects of acidosis and corticosteroid administration. *J Neurosurg* 2010; **112**: 1095– 104.
- 25 Mobasher, A, Trujillo, E, Bell, S, *et al.* Aquaporin water channels AQP1 and AQP3, are expressed in equine articular chondrocytes. *Vet J* 2004; **168**: 143– 50.
- 26 Meng, J, Ma, X, Ma, D, Xu, C. Microarray analysis of differential gene expression in temporomandibular joint condylar cartilage after experimentally induced osteoarthritis. *Osteoarthr Cartilage* 2005; **13**: 1115– 25.
- 27 Meng, JH, Ma, XC, Li, ZM, Wu, DC. Aquaporin-1 and aquaporin-3 expressions in the temporomandibular joint condylar cartilage after an experimentally induced osteoarthritis. *Chin Med J* 2007; **120**: 2191– 4.
- 28 Geyer, M, Grassel, S, Straub, RH. Differential transcriptome analysis of intraarticular lesional vs intact cartilage reveals new candidate genes in osteoarthritis pathophysiology. *Osteoarthr Cartilage* 2009; **17**: 328– 35.
- 29 Trujillo, E, González, T, Marín, R, Martín-Vasallo, P, Marples, D, Mobasher, A. Human articular chondrocytes, synoviocytes and synovial microvessels express aquaporin water channels; upregulation of AQP1 in rheumatoid arthritis. *Histol Histopathol* 2004; **19**: 435– 44.
- 30 Richardson, SM, Knowles, R, Marples, D, Hoyland, JA, Mobasher, A. Aquaporin expression in the human intervertebral disc. *J Mol Hist* 2008; **39**: 303– 9.
- 31 Wang, F, Zhu, Y. Aquaporin-1: a potential membrane channel for facilitating the adaptability of rabbit nucleus pulposus cells to an extracellular matrix environmental. *J Orthop Sci* 2011; **16**: 304– 12.
- 32 Dimitroulis, G. The role of surgery in the management of disorders of the temporomandibular joint: a critical review of the literature. Part 2. *Int J Oral Maxillofac Surg* 2005; **34**: 231– 7.

- 33 Dolwick, MF. Temporomandibular joint surgery for internal derangement. *Dent Clin North Am* 2007; **51**: 195– 208.
- 34 Miloro, M, Henriksen, B. Discectomy as the primary surgical option for internal derangement of the temporomandibular joint. *J Oral Maxillofac Surg* 2010; **68**: 782– 9.
- 35 Pèrez del Palomar, A, Doblaré, M. An accurate simulation model of anteriorly displaced TMJ discs with and without reduction. *Med Eng Phys* 2007; **29**: 216– 26.
- 36 Loreto, C, Lo Castro, E, Musumeci, G, *et al.* Artículo AQP-1 in human temporomandibular disc. *Acta Histochem* 2012; In press.
- 37 Tanaka, E, van Eijden, T. Biomechanical behavior of the temporomandibular joint disc. *Crit Rev Oral Biol Med* 2003; **14**: 138– 50.