

Marquette University
e-Publications@Marquette

Biomedical Engineering Faculty Research and
Publications

Biomedical Engineering, Department of

3-1-2016

Instrumented Lumbar Corpectomy and Spinal Reconstruction Comparing rhBMP-2/Compression-Resistant Matrix, rhBMP-2/Absorbable Collagen Sponge/Ceramic Granules Mixture, and Autograft in Two Different Devices: A Study in Sheep

Jeffrey M. Toth

Marquette University, jeffrey.toth@marquette.edu

David G. Schwartz

OrthoIndy

Jean-Piere Mobasser

Goodman Campbell Brain and Spine

Joseph Williams

Orthopedic Center of Illinois

Accepted version. *The Spine Journal*, Vol. 41, No. 6 (March 2016). DOI. © 2016 Elsevier. Used with permission.

Biomedical Engineering Faculty Research and Publications/College of Engineering

This paper is NOT THE PUBLISHED VERSION; but the author’s final, peer-reviewed manuscript.
The published version may be accessed by following the link in the citation below.

The Spine Journal, Vol. 41, No. 6 (March, 2016). [DOI](#). This article is © Elsevier and permission has been granted for this version to appear in [e-Publications@Marquette](#). Elsevier does not grant permission for this article to be further copied/distributed or hosted elsewhere without the express permission from Elsevier.

Contents

Abstract.....	2
MATERIALS AND METHODS.....	5
Surgical Procedure.....	5
Graft Materials and Treatment Groups.....	6
Corpectomy Devices.....	6
Bone Graft and Bone Graft Substitutes.....	6
Autograft.....	7
rhBMP-2/CRM.....	7
rhBMP-2/ACS with MASTERGRAFT.....	7
Computerized Tomography.....	7
Undecalcified Histology and Microradiography.....	7
RESULTS.....	8
Clinical.....	8
Radiographic.....	8
Histologic.....	8
DISCUSSION.....	13
Key Points.....	15
Acknowledgements.....	15

Instrumented Lumbar Corpectomy and Spinal Reconstruction Comparing rhBMP-2/Compression-Resistant Matrix, rhBMP-2/Absorbable Collagen Sponge/Ceramic Granules Mixture, and Autograft in Two Different Devices: A Study in Sheep

Jeffrey M. Toth

Department of Orthopaedic Surgery, The Medical College of Wisconsin, Milwaukee, WI

David G. Schwartz

OrthoIndy, Indianapolis, IN

Jean-Pierre Mobasser

Goodman Campbell Brain and Spine, Indianapolis, IN

Joseph Williams

Orthopedic Center of Illinois, Springfield, IL

Abstract

Study Design. Fusion success with rhBMP-2 and autograft in titanium or PEEK corpectomy devices was evaluated in a sheep lumbar corpectomy model. The 6 treatment groups included titanium mesh or PEEK corpectomy devices filled with rhBMP-2 on a compression-resistant matrix (CRM) carrier; rhBMP-2 in a morselized absorbable collagen sponge (ACS) carrier combined with resorbable ceramic granules; and autograft.

Objective. The aim of this study was to determine fusion rates associated with 2 different preparations of rhBMP-2 as well as autograft in an instrumented ovine lumbar corpectomy model 6 months postoperatively.

Summary of Background Data. Vertebral reconstruction with corpectomy devices requires bone graft. Bone graft substitutes have the potential to avoid a second operation, donor site pain, and attendant morbidity associated with autograft.

Methods. Twenty-four sheep in 6 treatment groups underwent lumbar corpectomy *via* a retroperitoneal trans-psoas approach. Spines were reconstructed with autograft, rhBMP-2 on a CRM, or rhBMP-2 on an ACS mixed with ceramic granules. Grafting materials were placed in either a titanium mesh or PEEK conduit in spines with internal fixation. Computed tomographic (CT) scans were evaluated for fusion. Undecalcified histology was used to evaluate for fusion as well as the amount and extent of graft incorporation and graft resorption.

Results. Regardless of corpectomy device used, rhBMP-2/CRM or rhBMP-2/ACS with MASTERGRAFT resulted in a 100% fusion rate. The autograft group had a lower (75%) radiographic fusion rate. Using either preparation of rhBMP-2 resulted in the length of the defect filling with solid bone. Autograft fragments and ceramic granules were incorporated into the fusion masses with much of the ceramic granules being resorbed by 6 months.

Conclusion. Both of the rhBMP-2 formulations have the potential to effect bony fusion and vertebral reconstruction within the corpectomy devices.

Key words: arthrodesis, autograft, bone morphogenetic protein 2, corpectomy, instrumented, lumbar spine fusion, PEEK, rhBMP-2, sheep model, titanium.

Corpectomy is a surgical procedure performed subsequent to a fracture, a tumor, infection, or degenerative spondylitic disease, which involves removing all or part of the vertebral body and intervertebral discs to provide neural decompression followed by surgical reconstruction of the corpectomy defect using a strut autograft, strut allograft, or a corpectomy device filled with

autograft bone. Autograft bone, locally harvested from the vertebral body, the anterolateral spine, or harvested from the iliac crest, rib, or fibula is often considered the “gold standard” for achieving bony fusion following corpectomy and subsequent vertebral body reconstruction. Although bone autograft is more osteogenic that facilitates early graft healing and incorporation, harvesting of iliac crest, rib, or fibular autograft is known to be associated with donor site pain and donor site complications, including injury to nerves or blood vessels, hematoma formation, infection at the donor site, cosmetic deformity, abdominal hernia, and/or fracture at the donor site.¹⁻⁹

In addition to bone autograft, a strut bone allograft from a donor femur, tibia, or humerus may be used to reconstruct the vertebral body after corpectomy. Similar to strut autograft, strut allograft provides a biomechanical advantage with early structural support provided by the intact cortical bone. The use of strut allograft for corpectomy has the added advantage of decreasing operative time, blood loss, and avoiding donor site pain and morbidity associated with autograft harvest. However, strut allograft lacks the osteogenic potential and ability to become fully incorporated in contrast to cancellous

bone autograft. For this reason, strut allografts for corpectomy reconstruction can be filled with autograft bone or a bone graft substitute to enhance osteoconductive and osteoinductive qualities. Allograft bone also has additional concerns of pseudarthrosis and disease transmission due to insufficient or improper donor evaluation, contamination, recipient infection, and positive serologic tests.¹⁰

Often times, lack of volume of local bone or iliac crest volume to be used for reconstruction can become problematic. Bone morphogenetic proteins (BMPs) are a group of growth factors also known as cytokines that were discovered due to their ability to induce de novo bone and cartilage formation. Previous literature has shown that BMP-2 is a potent osteoinductive morphogen capable of inducing de novo bone formation in ectopic sites and stimulating bony healing and repair in orthotopic bony sites. The mechanism of action of rhBMP-2 involves the osteoinductive signaling and regulation of gene-expression pathways involving the recruitment and differentiation of mesenchymal progenitor cells into osteoblasts resulting in bone formation at the implantation site.^{11,12} In 2002 and following U.S. Food and Drug Administration (FDA)-approved clinical studies, the combination of 1.5 mg/mL of rhBMP-2 on an absorbable collagen sponge (ACS) carrier (INFUSE Bone Graft, Medtronic Sofamor Danek, Memphis, TN) was approved as an autograft replacement in specific anterior lumbar interbody fusions (ALIFs).¹³⁻¹⁵ Since its introduction in 2002, INFUSE Bone Graft has been used to induce spinal fusion, although clinical complications associated with the off-label use of rhBMP-2 have been reported in the literature.^{16,17}

There is a paucity of literature on the use of rhBMP-2 for vertebral reconstruction subsequent to corpectomy. Using a bovine corpectomy model, White et al¹⁸ evaluated rhBMP-2 within strut allograft (N¼8) and local autograft within strut allograft (N¼8) for reconstruction of calf lumbar (L3) corpectomy defects at 4 months. Radiography and histology demonstrated comparable fusion (7/8 versus 8/8 for rhBMP-2) at the host allograft junction.¹⁸ The authors concluded: "Large cortical strut allografts (after lumbar corpectomy) supplemented with rhBMP-2 had incorporation and fusion strength comparable to allografts enhanced with cancellous autograft."¹⁸

In a clinical case series of 15 patients with vertebral instability and/or neurological compromise due to vertebral osteomyelitis, Aryan et al¹⁹ describe their experience in performing corpectomy and fusion with titanium cages filled with morselized allograft/autograft and rhBMP-2 in conjunction with tailored antibiotic therapy. Even though rhBMP-2 is contraindicated in patients with an active infection at the operative site, radiography demonstrated evidence of fusion in all patients at the last follow-up examination despite the underlying infections.¹⁹ In 2013, Pourtaheri et al²⁰ described 5-year outcome results from 24 consecutive patients with cervical spondylosis who were treated with cervical corpectomy and a lower dose of rhBMP-2 (0.26–0.35 mg/level) mixed with local autograft and demineralized bone matrix (DBM) within a polyetheretherketone (PEEK) spacer with supplemental anterior instrumentation. The authors found that the 100% fusion rate at 6 months was maintained at a mean 5-year followup, with no cervical swelling, hematoma formation, or increase in length of stay.²⁰

To our knowledge, there have been no studies to evaluate recombinant human BMP-2 (rhBMP-2) as an alternative to autograft bone for reconstruction of a corpectomy. The purpose of this study was to evaluate 2 different formulations of rhBMP-2 in addition to autograft within 2 different corpectomy devices in an instrumented ovine lumbar corpectomy model. CT radiography and undecalcified histology were conducted in a blinded fashion to assess the efficacy of the 6 treatment groups to effect vertebral reconstruction following instrumented lumbar corpectomy at 6 months.

MATERIALS AND METHODS

Surgical Procedure

A total of 24 skeletally mature (2–3 year old) female sheep were assigned to 1 of 6 treatment groups. All experimental procedures were approved by the Institutional Animal Care and Use Committee. Sheep were placed in right lateral recumbency and a left retroperitoneal transpsoas approach to the lumbar spine was made. A corpectomy of the L2 (intended) lumbar vertebral body was performed followed by preparation of the remaining endplates for arthrodesis. Once the vertebral body and intervertebral discs were excised, the staples were placed on the vertebral bodies above and below the vertebrectomy level and the awl was passed through the staple followed by tapping of the awl holes. Next, screws were placed through the staple to secure it to the vertebral body. After a measuring caliper was used to determine the required device length, the PEEK or titanium corpectomy device filled with the bone graft or bone graft substitute was inserted into the prepared space between the endplates as shown in Figure 1A and B. As seen in Figure 1C, the spinal construct also included supplemental instrumentation (CD HORIZON ANTARES Spinal System; Medtronic, Memphis, TN) consisting of 4 screws with 2 rods and crosslink plates, and vertebral body staples. Animals received 15mg fentanyl patches for 3 postoperative days for pain control as well as a postoperative antibiotic and were individually housed.

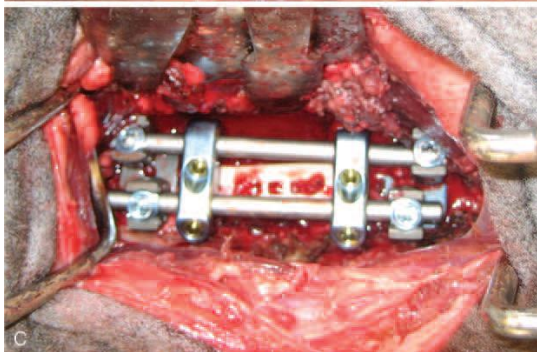
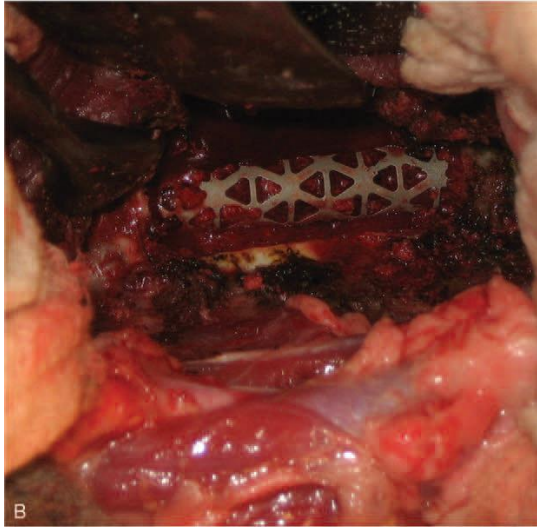
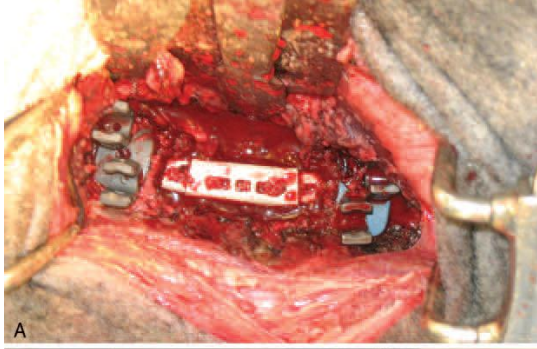


Figure 1. (A) PEEK corpectomy device implanted into a corpectomy defect in the sheep lumbar spine. (B) Pyramesh device implanted into a corpectomy defect in a sheep spine. (C) PEEK corpectomy device implanted into a corpectomy defect with supplemental instrumentation (CD HORIZON ANTARES Spinal System; Medtronic Spinal and Biologics, Memphis, TN).

Graft Materials and Treatment Groups

Corpectomy Devices

A PEEK vertebral body replacement implant (VERTESTACK CORNERSTONE PSR PEEK Implant; Medtronic)

was used to reconstruct the vertebral body and used with supplemental fixation. The PEEK device was modular with the central portion of the device measuring 14mm_11mm_25mm. To this central portion, additional modules were placed at each end so that the PEEK construct matched the size of the created corpectomy defect. Titanium surgical mesh devices (PyrameshC Titanium Mesh Implant; Medtronic, Memphis, TN) were also used. These devices were 13mm in diameter.

Bone Graft and Bone Graft Substitutes

Sheep were assigned to 1 of 6 treatment groups as summarized in Table 1. Three of the groups included the titanium mesh devices filled with rhBMP-2 on a CRM [rhBMP-2/CRM], rhBMP-2 on ACS mixed with biphasic HA/TCP (15% Hydroxyapatite/85% Tricalcium Phosphate) ceramic granules [rhBMP-2/ACS

with MASTERGRAFT], or autograft. The other 3 groups consisted of the PEEK corpectomy devices filled with the same bone graft/substitute preparations.

Autograft

Locally harvested cancellous bone autograft from the excised vertebral body was implanted within and around the corpectomy device.

rhBMP-2/CRM

Around 2.5mL of 0.86 mg/mL rhBMP-2 solution was evenly distributed and allowed to soak into a 5-mL block of CRM [2.15mg total dose of rhBMP-2]. The CRM (MasterGraft Matrix; Medtronic) consists of 97.5% biphasic calcium phosphate granules (15% HA/85%b-TCP) and 2.5% Type I bovine collagen by weight.

rhBMP-2/ACS with MASTERGRAFT

One 5.0 cm_2.5 cm_0.35 cm dry ACS and one 4.0 cm_2.5 cm_0.35 cm dry ACS were cut into approximately 40 small pieces. Around 2.5mL of 0.43 mg/mL rhBMP-2 solution was then evenly distributed onto the ACS pieces [1.08mg total dose of rhBMP-2]. After the prescribed 15-minute soak time, 2.5mL of Ceramic Granules (MASTERGRAFT Granules; Medtronic) were combined with the ACS pieces to create approximately 5mL of morselized mixture. This mixture was then packed into each type of corpectomy implant. A dose concentration of 0.43 mg/mL of rhBMP-2 on ACS has been used in several ovine interbody fusion studies.^{13,21}

Computerized Tomography

At the 6-month postoperative time period, computed tomographic (CT) scans were performed on all 24 specimens in 1.5mm slice widths. Sagittal and coronal reconstructions as well as axial scans were evaluated by an independent neuroradiologist, neurosurgeons, and orthopedic spine surgeons to determine the continuity of fusion mass and presence of bone. Criteria for fusion based on the CT scan was determined to be any continuous vertical column of bone from endplate to endplate.

Group	Treatment	Samples	Fusion	Nonfusion
1	PEEK Verte-Stack Cornerstone PSR+rhBMP-2/CRM	4	4	0
2	Pyramesh þ rhBMP-2/CRM	4	4	0
3	PEEK Verte-Stack Cornerstone PSR þ rhBMP-2/ACS with MASTERGRAFT	4	4	0
4	Pyramesh þ rhBMP-2/ACS with MASTERGRAFT	4	4	0
5	PEEK Verte-Stack Cornerstone PSR þ autograft	4	4	0
6	Pyramesh þ autograft	4	2	2

Undecalcified Histology and Microradiography

After fixation was effected, tissue samples were rinsed in running tap water, sequentially dehydrated in graded alcohols, cleared in xylene, and infiltrated and embedded in graded catalyzed methyl ethacrylate. Undecalcified sections were cut in the sagittal plane continuously through the treated

spines on diamond saws to an approximate thickness of 200 to 350mm. Differential staining using a trichrome stain was used to permit both histological and cytological differentiation.

In addition to stained undecalcified sections, microradiographs of 3 to 4 undecalcified sections from each treated level were produced. Microradiographs were ideal for differentiation of bone, ceramic granules, and the corpectomy devices because of radiodensity differences of these materials. The histological sections and microradiographs were evaluated concurrently for histologic fusion (continuous bony bridge from the cranial to the caudal vertebra) or the presence of pseudarthroses. The spinal levels were considered to be fused if greater than (>) 50% of the sections showed continuous bony bridging in any 1 region. A partial fusion existed if less than or equal to (≤) 50% of the sections showed continuous bony bridging in any 1 region. A nonfusion existed if none of the sections showed continuous bony bridging.

RESULTS

Clinical

The majority of the sheep underwent the surgical procedure and recovered without complications. Mean operative time ranged from 97 minutes for the PEEK Verte-Stack Cornerstone PSR and rhBMP-2/CRM group to 154 minutes for the Pyramesh and rhBMP-2/CRM group. Differences in operative time were not statistically significant between individual treatment groups [$P < 0.13$, analysis of variance (ANOVA)]; although when data were pooled by corpectomy device and examined, the mean operative time of 110 minutes for the PEEK corpectomy device groups was significantly less than the 130-minute mean operative time for the titanium mesh corpectomy device groups ($P < 0.047$, one-tail t test).

Mean blood loss for the treatment groups ranged from 190 to 700mL with statistically significant differences for blood loss between treatment groups observed ($P < 0.01$, ANOVA). The Pyramesh and autograft group had significantly more blood loss than the Pyramesh and rhBMP-2/CRM group and the Pyramesh and rhBMP-2/ACS with MASTERGRAFT group (both $P < 0.04$, pairwise comparison, Student's t). Similarly, the PEEK Verte-Stack Cornerstone PSR and autograft group had significantly more blood loss than the Pyramesh and rhBMP-2/CRM group and the Pyramesh and rhBMP-2/ACS with MASTERGRAFT group (both $P < 0.01$, pairwise comparison, Student's t). Finally, the PEEK Verte-Stack Cornerstone PSR and rhBMP-2/CRM group had significantly more blood loss than both the Pyramesh and rhBMP-2/CRM group as well as the Pyramesh and rhBMP-2/ACS with MASTERGRAFT group (both $P < 0.002$, pairwise comparison, Student's t).

Radiographic

Sagittal CT scan reconstructions (as seen in Figure 2) were used for the evaluation of fusion. CT radiographic results summarized by treatment group are presented in Table 1. All treated spines were determined to be fused with the exception of nonfusions in 2 of 4 spines in the Pyramesh and autograft group, resulting in a 50% radiographic fusion rate for that group. For rhBMP-2, 16 of 16 fusions occurred (100%), while in the autograft cohort, 6 of 8 (75%) fused ($P = 0.038$, Chi-squared test; $P = 0.10$, Fisher's exact test).

Histologic

Histologic fusion results summarized by treatment group and presented in Table 2 compared favorably with CT radiographic fusion results as presented in Table 1. A subclinical infection was found in the peri-

implant histology of 1 of the sheep in the Pyramesh and autograft group (Group 6). Although the infection was not detected clinically, the infection most likely inhibited bone growth and subsequently obviated histologic fusion in this sheep. As such, this sheep was excluded from the group 6 fusion analysis in Table 2, so that for Group 6, (Pyramesh and autograft), N was reduced to 3. A representative stained, undecalcified, histologic section and corresponding microradiograph, which shows a partial histologic fusion with bridging bone with incomplete bone fill inside the titanium corpectomy device filled with autograft (Group 6), is seen in Figure 3. Representative stained, undecalcified, histologic sections and corresponding microradiographs, which show histologic fusion with bridging bone and complete de novo bone fill inside the titanium corpectomy devices filled with rhBMP-2/CRM (Group 2) as well as rhBMP-2/ACS with MASTERGRAFT (Group 4), are seen in Figures 4 and 5, respectively. Radiopaque incorporated ceramic granules are seen within the fusion masses in the corresponding microradiographs (Figures 4B and 5B) within the titanium mesh devices. In addition to bony bridging within the corpectomy devices, bony bridging was also seen ventral to both of the titanium mesh corpectomy devices in Figures 4 and 5.

Similar to the Pyramesh þ autograft group, 2 fusions, 1 partial histologic fusion and 1 nonfusion, were found in the PEEK Verte-Stack Cornerstone PSR and autograft group. A representative stained, undecalcified, histologic section and corresponding microradiograph, which shows a histologic fusion with bridging bone with complete bone fill inside the PEEK corpectomy device filled with autograft (Group 5), is seen in Figure 6. Representative stained, undecalcified, histologic sections and corresponding microradiographs, which show histologic fusion with bridging bone and complete de novo bone fill inside the PEEK corpectomy devices filled with rhBMP-2/CRM (Group 1) as well as rhBMP-2/ACS with MASTERGRAFT (Group 3), are seen in Figures 7 and 8, respectively. Radiopaque incorporated ceramic granules were seen within the fusion masses in the corresponding microradiographs (Figures 7B and 8B) within the PEEK corpectomy devices. In addition, Figures 6B, 7B, and 8B show that the PEEK device is radiolucent. Bony bridging is observed ventral to all 3 of the PEEK corpectomy devices in Figures 6 through 8 in addition to bony bridging within the PEEK corpectomy devices.

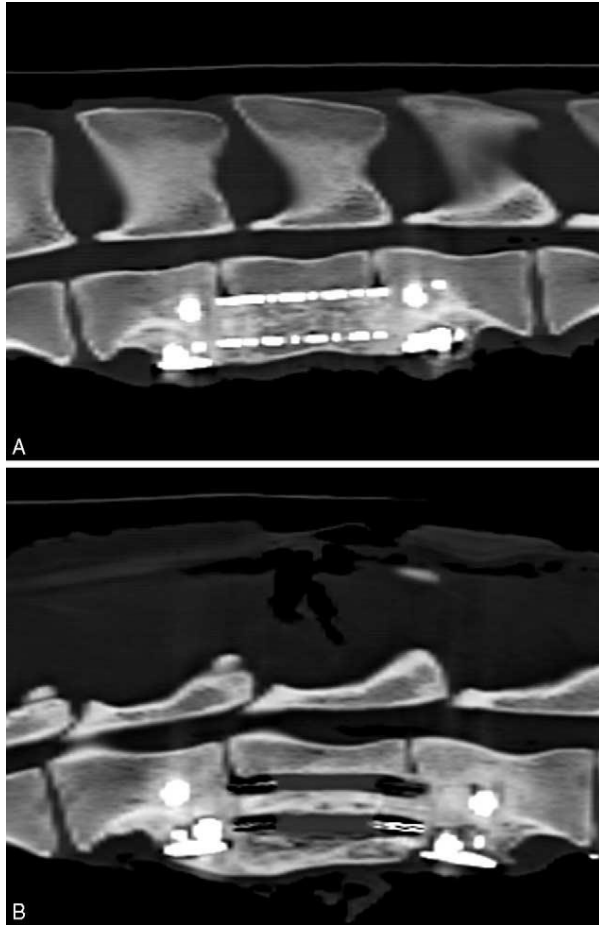


Figure 2. (A) Sagittal reconstruction showing continuous bony bridging through a titanium corpectomy device implanted at 6 months in the sheep lumbar spine. (B) Sagittal reconstruction showing continuous bony bridging through a PEEK corpectomy device implanted at 6 months in the sheep lumbar spine.

Table 2. Summary Table of Histologic Fusion Results					
Group	Treatment	Samples (N)	Histologic Fusion	Partial Fusion	Nonfusion
1	PEEK Verte-Stack Cornerstone PSR þ rhBMP-2/CRM	4	4	0	0
2	Pyramesh þ rhBMP-2/CRM	4	4	0	0
3	PEEK Verte-Stack Cornerstone PSR þ rhBMP-2/ACS with MASTERGRAFT	4	3	1	0
4	Pyramesh þ rhBMP-2/ACS with MASTERGRAFT	4	2	2	0
5	PEEK Verte-Stack Cornerstone PSR + autograft	4	2	1	1
6	Pyramesh + autograft	3*	2	1	0

*Sheep #55 in Group 6 showed an infection. This most likely inhibited bone growth and subsequently obviated histologic fusion. As such, it has been excluded from the group fusion analysis, so that for Group 6, N=3.

Histology demonstrated de novo bone within a majority of the corpectomy devices, resulting in complete bone fill. Ceramic granules and autograft fragments were incorporated into fusion masses within the corpectomy device. Unincorporated autograft fragments and unincorporated ceramic granules were not observed. As summarized in Table 2, a few of the spines were rated as partial histologic fusions. In these spines, some histologic sections showed full fusion with complete bone fill. Other sections from the same spine showed thin (<1mm) ventral to dorsal bands of nonbony tissues obviating fusion. Despite the presence of these thin pseudarthroses, these sections also showed nearly complete bone fill within the rest of the corpectomy device. The resultant fusion rates for autograft and rhBMP-2 can be calculated by analyzing the histologic fusion data presented in Table 2 and combining “fusion” and “partial fusion” results versus “nonfusion.” For rhBMP-2, 16 of 16 histologic fusions occurred (100%), while in the autograft cohort, 6 of 7 (85.7%) fused ($P=0.12$, Chi-squared test; $P=0.30$, Fisher’s exact test).

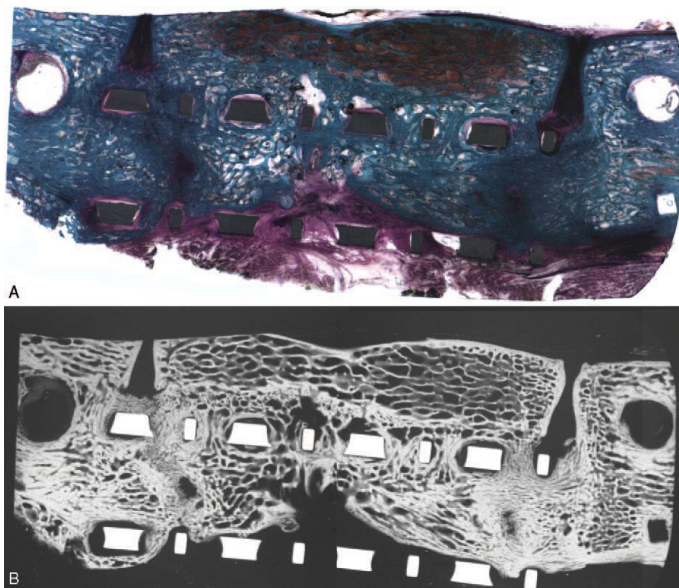


Figure 3. Representative stained, undecalcified, histologic section (A) and corresponding microradiograph (B) showing partial histologic fusion with bridging bone with incomplete bone fill inside the titanium corpectomy device filled with autograft (Group 6). No infection was present in peri-implant tissues.

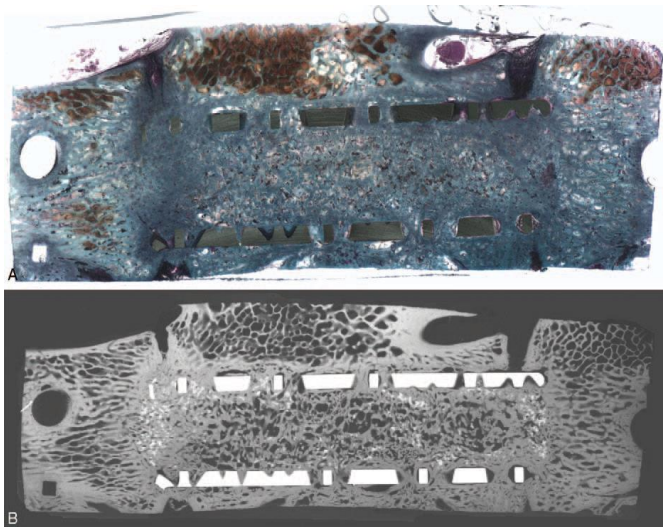


Figure 4. Representative stained, undecalcified, histologic section (A) and corresponding microradiograph (B) showing histologic fusion with bridging bone and complete de novo bone fill inside the titanium corpectomy device filled with rhBMP-2/CRM (Group 2). Radiopaque incorporated ceramic granules are seen within the fusion mass in the corresponding microradiograph (B). In addition to bone within the corpectomy device, bony bridging is seen ventral to the device in both figures.




Figure 5. Stained, undecalcified, histologic section (A) and corresponding microradiograph (B) showing histologic fusion with bridging bone and complete de novo bone fill inside the titanium corpectomy device filled with rhBMP-2/ACS with MASTERGRAFT (Group 4). Radiopaque incorporated ceramic granules are seen within the fusion mass in the corresponding microradiograph (B).

In addition to bone within the corpectomy device, bony bridging is seen ventral to the device in both figures.

DISCUSSION

On the basis of histology and CT scans, vertebral reconstruction with either formulation of rhBMP-2 resulted in 100% fusion regardless of corpectomy device. There was continuous bone formation from endplate to endplate in all reconstructions using either formulation of rhBMP-2. Those vertebral defects undergoing reconstruction with autograft achieved only a 75% radiographic fusion rate. Although no animal model can fully predict human clinical results, 6 postoperative months appeared to




Figure 6. Representative stained, undecalcified, histologic section (A) and corresponding microradiograph (B) showing histologic fusion with bridging bone and complete bone fill inside the PEEK corpectomy device filled with autograft (Group 5). In addition to bone within the corpectomy device, bony bridging is seen ventral to the device in both figures.




Figure 7. Representative stained, undecalcified, histologic section (A) and corresponding microradiograph (B) showing histologic fusion with bridging bone and complete de novo bone fill inside the PEEK corpectomy device filled with rhBMP-2/CRM. Radiopaque incorporated ceramic granules are seen within the fusion mass in the corresponding microradiograph (B). In addition to bone within the corpectomy device, bony bridging is seen ventral to the device in both figures.

provide valuable data on the ability of the instrumented corpectomy devices filled with bone graft and the bone graft substitutes to effect lumbar spinal fusion in the ovine model. In fact, both the PEEK and titanium corpectomy devices provided a sheltered environment for angiogenesis, the expression of the rhBMP-2 morphogen with the maintenance of a 3-D internal geometry, and the induction of a bony fusion mass with subsequent arthrodesis of the lumbar spinal level.

Thin pseudarthroses, observed by histology in some sections, would likely not be detectable by current radiographic methods, explaining the slight discrepancy between histologic fusion results and CT radiographic fusion results. One of the limitations of the current study is the fact that formal biomechanical testing was not conducted on the spines. Therefore, it is not known whether the thin pseudoarthroses detected by histology might be clinically relevant due to the biomechanical stability offered by the instrumented construct.




Figure 8. Representative stained, undecalcified, histologic section (A) and corresponding microradiograph (B) showing histologic fusion with bridging bone and complete de novo bone fill inside the PEEK corpectomy device filled with rhBMP-2/ACS with MASTERGRAFT (Group 3). Radiopaque incorporated ceramic granules are seen within the fusion mass in the corresponding microradiograph (B).

Although differences in operative time were not statistically significant between individual treatment groups, data pooled by corpectomy device were statistically significant with the mean operative time for the PEEK corpectomy device groups being significantly less than the mean operative time for the titanium mesh corpectomy device groups. The titanium mesh devices took longer to prepare because of the requirement to cut the device in order to fit the vertebral defect. Thus, the modularity of the PEEK device with various sizes compared with the need to measure and cut the titanium mesh device is a possible reason for the observed statistically significant differences in mean operative time between corpectomy device groups. Differences in the mean operative time between treatment groups using bone autograft versus the synthetic bone graft substitutes were not statistically significant. With respect to blood loss, statistically significant differences for blood loss between treatment groups were observed in the current study with the Pyramesh and autograft group having significantly more blood loss than the Pyramesh and rhBMP-2/CRM group and the Pyramesh and rhBMP-2/ACS with MASTERGRAFT group. This finding is consistent with previous clinical literature that has documented decreased blood loss with the use of bone graft substitutes over bone autograft.²²⁻²⁵

With respect to efficacy, in the current study, vertebral reconstruction with either formulation of rhBMP-2 resulted in 100% fusion regardless of conduit. In the current study, adverse events including bone resorption and ectopic bone formation were not observed at 6 months. Obtaining enough bone graft material can be a challenge in spinal surgery. Although there are numerous biomaterials that are alternatives to or extenders of bone autograft in spine surgery, none are as efficacious as autograft. Autograft remains the gold standard for vertebral body reconstruction. Clinical outcomes for rhBMP-2 in spinal fusion have shown better clinical results than iliac crest bone while decreasing blood loss, operating time and costs while increasing patient satisfaction and fusion outcomes.^{26,27} To our knowledge, there have been no studies to date that show rhBMP-2 to be an acceptable alternative to autologous bone for reconstruction of a corpectomy. This study demonstrates that using rhBMP-2 may be a viable alternative to autologous bone graft in vertebral reconstruction, regardless of the conduit, especially when there is a limit to the amount of autogenous bone graft that can be harvested.

Key Points

Regardless of corpectomy device used, rhBMP-2/CRM or rhBMP-2/ACS with MASTERGRAFT resulted in a 100% fusion rate compared with a 75% radiographic fusion rate in the autograft groups, indicating that both of the rhBMP-2 formulations have the potential to effect bony fusion and vertebral reconstruction within corpectomy devices.

Both autograft fragments and ceramic granules were incorporated into the fusion masses with much of the ceramic granules being resorbed by 6 months.

PEEK corpectomy devices were radiolucent, which could allow for an easier determination of radiographic fusion than the radiopaque titanium mesh devices.

Acknowledgements

The authors wish to thank and acknowledge Amy Rizzo, MT (ASCP) and Sharath Chandra Venkata Chedella, BDS, MS for technical expertise in histologic processing of the tissues; Amisha Patel, MS for her work on the study; and Joseph Riina, MD for his interest and valuable assistance in completing this study.

References

- Younger EM, Chapman MW. Morbidity at bone graft donor sites. *J Orthop Trauma* 1989;3:192–5.
- Kim DH, Rhim R, Li L, et al. Prospective study of iliac crest bone graft harvest site pain and morbidity. *Spine J* 2009;9:886–92.
- Ebraheim NA, Elgafy H, Xu R. Bone-graft harvesting from iliac and fibular donor sites: techniques and complications. *J Am Acad Orthop Surg* 2001;9:210–8.
- Arrington ED, Smith WJ, Chambers HG, et al. Complications of iliac crest bone graft harvesting. *Clin Orthop Relat Res* 1996;329:300–9.
- Banwart JC, Asher AM, Hassanein RS. Iliac crest bone graft harvest donor site morbidity: a statistical evaluation. *Spine* 1995;20:1055–60.
- Summers BN, Eisenstein SM. Donor site pain from the ilium: a complication of lumbar spine fusion. *J Bone Joint Surg Br* 1989;71:677–80.
- Fernyhough JC, Schimandle JJ, Weigel MC, et al. Chronic donor site pain complicating bone graft harvesting from the posterior iliac crest for spinal fusion. *Spine* 1992;17:1474–80.
- Keller EE, Triplett WW. Iliac bone grafting: review of 160 consecutive cases. *J Oral Maxillofac Surg* 1987;45:11–4.
- Delawi D, Dhert WJ, Castelein RM, et al. The incidence of donor site pain after bone graft harvesting from the posterior iliac crest may be overestimated: a study on spine fracture patients. *Spine* 2007;32:1865–8.
- Mroz TE, Joyce MJ, Steinmetz MP, et al. Musculoskeletal allograft risks and recalls in the United States. *J Am Acad Orthop Surg* 2008;16:559–65.
- Ji X, Chen D, Xu C, et al. Patterns of gene expression associated with BMP-2 induced osteoblast and adipocyte differentiation of mesenchymal progenitor cell 3T3-F442A. *J Bone Miner Metab* 2000;18:132–9.
- Chaudari A, Ron E, Rethman MP. Recombinant human bone morphogenetic protein-2 stimulates differentiation in primary cultures of fetal cat calvarial osteoblasts. *Mol Cell Biochem* 1997;167:31–9.
- Sandhu HS, Toth JM, Diwan AD, et al. Histologic evaluation of the efficacy of rhbmp-2 compared with autograft bone in sheep spinal anterior interbody fusion. *Spine* 2002;27: 567–75.
- Boden SD, Zdeblick TA, Sandhu HS, et al. The use of rhBMP-2 in interbody cages. Definitive evidence of osteoinduction in humans: a preliminary report. *Spine* 2000;25:376–81.
- Burkus JK, Gornet MF, Dickman CA, et al. Anterior lumbar interbody fusion using rhBMP-2 with tapered interbody cages. *J Spinal Disord Tech* 2002;15:337–49.
- Simmonds MC, Brown JV, Heirs MK, et al. Safety and effectiveness of recombinant human bone morphogenetic protein-2 for spinal fusion: a meta-analysis of individual-participant data. *Ann Intern Med* 2013;158:877–89.

Fu R, Selph S, McDonagh M, et al. Effectiveness and harms of recombinant human bone morphogenetic protein-2 in spine fusion: a systematic review and meta-analysis. *Ann Intern Med* 2013;158:890–902.

White KK, Bawa M, Ahn J-S, et al. Strut allograft union and remodeling using rhBMP-2 in a spinal corpectomy model. *Spine* 2005;30:1386–95.

Aryan HE, Lu DC, Acosta FL Jr, et al. Corpectomy followed by the placement of instrumentation with titanium cages and recombinant human bone morphogenetic protein-2 for vertebral osteomyelitis. *J Neurosurg Spine* 2007;6:23–30.

Pourtaheri S, Emami A, Hwang K, et al. Cervical corpectomy with ultra-low-dose rhBMP-2 in high-risk patients: 5-year outcomes. *Orthopedics* 2013;36:931–5.

Toth JM, Wang M, Estes BT, et al. Polyetheretherketone as a biomaterial for spinal applications. *Biomaterials* 2006;27: 324–34.

Crawford CH 3rd, Bridwell KH, Cho W, et al. *Spine* 2010;35: 1843–8.

Dimar JR 2nd, Glassman SD, Burkus JK, et al. Clinical and radiographic analysis of an optimized rhBMP-2 formulation as an autograft replacement in posterolateral lumbar spine arthrodesis. *J Bone Joint Surg Am* 2009;91:1377–86.

Dimar JR, Glassman SD, Burkus KJ, et al. Clinical outcomes and fusion success at 2 years of single-level instrumented posterolateral fusions with recombinant human bone morphogenetic protein-2/ compression resistant matrix versus iliac crest bone graft. *Spine* 2006;31:2534–9.

Haid RW Jr, Branch CL Jr, Alexander JT, et al. Posterior lumbar interbody fusion using recombinant human bone morphogenetic protein type 2 with cylindrical interbody cages. *Spine J* 2004; 4:527–38.

Burkus JK, Transfeldt EE, Kitchel SH, et al. Clinical and radiographic outcomes of anterior lumbar interbody fusion using recombinant human bone morphogenetic protein-2. *Spine* 2002;27:2396–408.

Kahn S, Lane J. The use of recombinant human bone morphogenetic protein-2 in orthopaedic applications. *Expert Opin Biol Ther* 2004;4:741–8.