

Marquette University
e-Publications@Marquette

Biomedical Engineering Faculty Research and
Publications

Biomedical Engineering, Department of

9-1-2016

Segmental Kinematic Analysis of Planovalgus Feet in Children with Cerebral Palsy

K. Kruger

Marquette University

K. Konop

Marquette University

Joseph Krzak

Shriners Hospitals for Children

Adam Graf

Shriners Hospitals for Children

Gerald F. Harris

Marquette University, gerald.harris@marquette.edu

Accepted version. *Developmental Medicine & Child Neurology*, Vol. 58, No. S5 (September 2016): 31.
DOI. © 2016 John Wiley & Sons, Inc. Used with permission.

Segmental Kinematic Analysis Of Planovalgus Feet In Children With Cerebral Palsy

K Kruger

Biomedical Engineering, Marquette University, Milwaukee, WI

K Konop

Biomedical Engineering, Marquette University, Milwaukee, WI

J Krzak

Midwestern University, Shriners Hospitals for Children, Downers Grove, IL

A Graf

G Harris

*Marquette University OREC & Shriners Hospital for Children - Chicago,
Menomonee Falls, WI*

Background and Objective(s):

Pes planovalgus (PV) is characterized by flattening of the medial longitudinal arch, along with hindfoot valgus. It is the most common foot deformity in ambulatory cerebral palsy (CP) and accounts for 25–30% of all surgical procedures in children with CP. Previous studies have addressed the need for multi-segment foot models to understand pathologic function and kinematic variability. The Milwaukee Foot Model (MFM) includes skeletal indexing of the foot and ankle using a series of radiographs to quantify multi-segmental kinematics during gait. The goal of this unique process is to provide new insight into the underlying skeletal motion resulting from PV. Improvements in quantitative

characterization, treatment planning, and post-treatment follow-up are the primary objectives of this work.

Study Design:

Retrospective Cohort Study

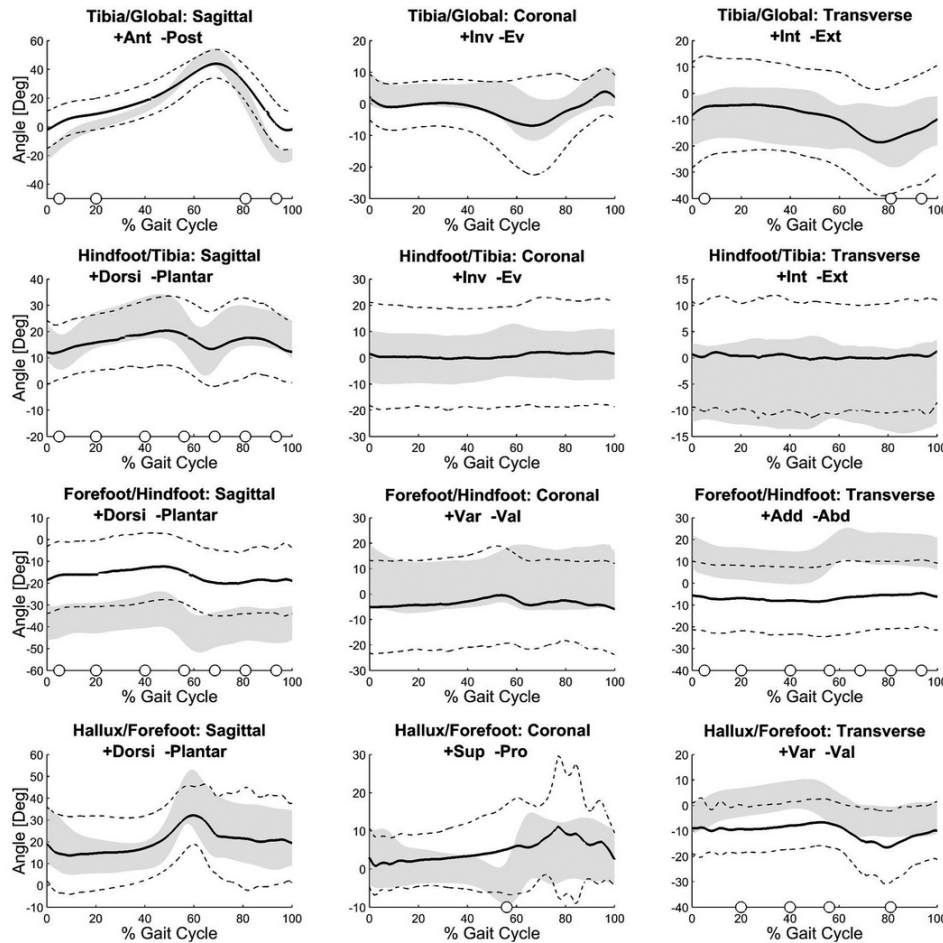


Figure 1: Multi-segment kinematics of the typically developing group (Grey band: Mean +/- SD) and the Planovalgus Group (Black line: Mean, Dashed lines +/- SD). Circles indicate significance for particular phases of the gait cycle ($p < 0.001$).

Study Participants & Setting:

The study population (PV group) included 20 children (aged 11.2 ± 2.1 yrs) identified with pes planovalgus (10 unilateral and 10 bilateral, for a total of 30 feet), and a control group consisting of 16 typically developing (TD) children (32 feet total, aged 11.3 ± 2.0 yrs).

Materials/Methods:

Gait analysis was performed using the MFM to characterize segmental kinematics of the foot and ankle. Each affected foot was instrumented with twelve reflective markers ($d = 9$ mm) placed on bony anatomical landmarks during the gait analysis. Weight-bearing radiographs were taken from anterior/posterior, lateral, and modified coronal plane views and processed using a custom MATLAB script which aligns the marker-based reference system with the radiographic bone-based (skeletal) system.

Statistical comparisons between the PV and TD populations were made among kinematic peaks and joint excursions within each of the seven phases of gait. Statistical analysis was performed using a Welch two-sample t-test to compare differences in segmental foot kinematics between the two populations.

Results:

The PV group tibia showed decreased ROM in the sagittal plane during stance and mid-swing and more anterior tilt through most of the gait cycle. The hindfoot was more plantar flexed through the gait cycle with decreased ROM in mid-stance through mid-swing. The joint was more plantar-flexed throughout the gait cycle. There was significant variability at the hindfoot among individuals in the PV population in the coronal and transverse planes. The PV group forefoot showed decreased plantarflexion and increased abduction relative to the TD group.

Conclusions/Significance:

This study demonstrates an application of a radiographically indexed, skeletal-based approach to segmental foot analysis in pediatric pes planovalgus. Most results are consistent with known characteristics of the deformity. The key finding of these data was that the PV hindfoot did not consistently show more eversion than the TD hindfoot. Rather, the coronal plane kinematics of the hindfoot confirmed a distribution of PV foot cases with the hindfoot in inversion, eversion, and neutral. This improved understanding of underlying bony orientation and segmental kinematics during ambulation can be used to improve surgical and rehabilitative strategies.