

5-1-2014

Treatment of Abscessed Primary Molars Utilizing Lesion Sterilization and Tissue Repair: Literature Review and Report of Three Cases

David Burrus

Lori Barbeau
Children's Hospital of Wisconsin

Brian D. Hodgson
Marquette University, brian.hodgson@marquette.edu

Case Report

Treatment of Abscessed Primary Molars Utilizing Lesion Sterilization and Tissue Repair: Literature Review and Report of Three Cases

David Burrus, DDS¹ • Lori Barbeau, DDS² • Brian Hodgson, DDS³

Abstract: Purpose: The purpose of this report was to review an emerging alternative treatment to pulpectomies and extractions for nonvital primary teeth called lesion sterilization and tissue repair (LSTR) and provide the results of three clinical case applications. LSTR is a noninstrumentation endodontic treatment that involves a triantibiotic mixture in a propylene glycol vehicle, which is used to disinfect root canal systems. This concept was developed by the cariology research unit of the School of Dentistry, Niigata University, Niigata, Niigata Prefecture, Japan. This article reviews the development of the technique, clinical procedures required for the technique, three clinical applications and radiographic documentation and follow-up, and a short literature review of the current evidence supporting its application in clinical practice. (*Pediatr Dent* 2014;36:240-4) Received January 18, 2013 | Last Revision June 5, 2013 | Accepted June 19, 2013

KEYWORDS: DECIDUOUS TOOTH, NONVITAL TOOTH, 3-MIX OINTMENT

Pediatric dentists are often faced with the management of primary teeth that show signs of irreversible pulpitis or necrosis.¹ Traditionally accepted treatment options for teeth with infected root canals/periradicular tissues are pulpectomy or extraction.¹ Although extraction with space maintenance remains a viable treatment option, a successfully restored primary tooth is a far superior space maintainer than an appliance.^{2,3}

With pulpectomy treatment, necrotic or abscessed primary teeth have acceptable outcomes approximately 85 percent of the time⁴, but the technique can be very challenging given the continuous changes in the apical foramen as a result of physiologic and pathologic resorption. Overinstrumentation may injure the developing permanent tooth bud.^{4,6} Sjogren et al. found that, even after thorough mechanical and chemical cleaning of the canals, up to 40 percent of the canals may still exhibit positive bacterial cultures.⁷

These findings led researchers to investigate antibiotic options for disinfecting root canal systems. As a result, the cariology research unit of the School of Dentistry, Niigata University, Niigata, Niigata Prefecture, Japan, developed the concept of lesion sterilization and tissue repair (LSTR) therapy, which is a noninstrumentation endodontic treatment that employs a mixture of antibacterial drugs in a propylene glycol vehicle for the disinfection of dentinal, pulpal, and periapical lesions. If lesions are completely disinfected, tissue repair can be expected.⁸

Bacterial constituents of intraoral pathology have been analyzed under strict anaerobic conditions to understand the target bacteria in LSTR endodontic treatment.⁸⁻¹⁷ Metronidazole was chosen initially for its wide bactericidal spectrum against anaerobes commonly found in oral sites. However, even high concentrations of metronidazole could not eliminate all the bacteria in the lesions. Therefore, two additional antibacterial drugs, ciprofloxacin and minocycline, were added in an

effort to fully eradicate all of the bacteria.¹⁸ Windley et al. noted that this combination of antibiotics would also decrease the likelihood of the development of resistant bacterial strains.¹⁹

Extensive in vitro and in situ studies have shown that the mixture (3-Mix) of metronidazole, ciprofloxacin, and minocycline is effective against oral bacteria, including those in the endodontic lesions of primary teeth.^{8,13,19-31} Furthermore, this same antibiotic combination has been successful in permanent tooth disinfection and regenerative endodontic treatments.³²⁻³⁴ Cruz et al. showed that the addition of propylene glycol and macrogol (MP) as a carrier vehicle greatly improved the penetration ability of these medications.³⁵

Takushige et al.⁸ clinically applied this LSTR theory in a trial involving 87 infected primary molars in 56 four to 18-year-olds. Fifty-four of the infected primary molars showed radiolucencies on radiographs, 52 had gingival swellings, and 22 had fistulas. Their results showed that 83 of the 87 cases demonstrated healing after one application of the 3-Mix-MP Dental Paste. In those 83 cases, pain, swelling, and fistulas resolved within one week of therapy. The four nonresponding teeth were retreated due to continued swelling, and, consequently, all symptoms resolved. The mean function time of the treated primary teeth in this study was 680 days. Success was described as follows: no mobility, functional tooth, and no pain or infection.

The purpose of this literature review and report of cases was to inform dental practitioners of lesion sterilization and tissue repair therapy for nonvital pulp therapy in primary teeth.

Methods

Modification of Takushige et al.'s technique. A compounding pharmacist was enlisted to review and suggest an alternative antibiotic to minocycline, because minocycline has been shown in the permanent dentition to cause black staining and discoloration of the tooth and gums.^{22,23,36} Clindamycin was chosen due to its effectiveness against streptococci and anaerobes.³⁷ Iodoform was also added to the 3-Mix-MP dental paste (3-Mix-MP-R), making it radiopaque and allowing radiographic confirmation of proper paste placement. As provided by the compounding pharmacist, the 3-Mix-MP-R is supplied as a two-part system. The dry powder component

¹ Dr. Burrus is a pediatric dentist in private practice, Bend, Ore.; ² Dr. Barbeau is medical director, Pediatric Dental residency program, Children's Hospital of Wisconsin; and ³ Dr. Hodgson is an associate professor, Division of Pediatric Dentistry, Marquette University School of Dentistry, both in Milwaukee, Wis., USA. Correspond with Dr. Burrus at davidburrusdds@gmail.com

contains metronidazole USP, ciprofloxacin HCl USP, clindamycin HCl USP, and iodoform (triiodomethane) USP. The liquid component contains polyethylene glycol 300 and macrogol. The two components are mixed immediately prior to use.

Clinical procedure of LSTR using 3-Mix-MP-R. The following is a description of the clinical procedure of LSTR and final restoration performed on each of the three cases presented here. A dental examination with appropriate radiographs was completed, and a clinical diagnosis was determined. After discussion of the risks, benefits, and alternatives, informed consent was obtained. The teeth were anesthetized and isolated with a rubber dam and pulpal access was obtained. The necrotic tissues were removed from the coronal portion of the pulp chamber, and the canal orifices enlarged with a round bur (one mm diameter and two mm depth) to create medication receptacles. The walls of the chamber were cleansed with 35 percent phosphoric acid (Ultra Etch, Ultradent, South Jordan, Utah, USA), rinsed, and dried using an air and water syringe. Phosphoric acid was used for its bactericidal properties. Any refractory hemorrhage was controlled by applying a cotton pellet soaked in 10 percent NaOCl (Pure Bright, KIK International Inc, Concord, Ontario, Canada) until hemostasis was achieved.

The 3-Mix-MP-R was placed in the medication receptacles and over the pulpal floor. The access opening was sealed with a glass ionomer cement (Fugi IX, GC America, Alsip, Ill., USA), and the tooth was restored with a stainless steel crown [(SSC); 3M ESPE Unitek Stainless Steel Crowns, St. Paul, Minn., USA], the most effective long-term restoration for pulpally treated primary teeth.² The additional use of systemic antibiotics was considered if significant vestibular swelling was noted or if a large furcation radiolucency was present.

Case descriptions

Case 1. A seven-year-old Caucasian male, with a medical history positive for neurofibromatosis type I and a stable optic glioma, presented to the pediatric dental residency clinic at the Children's Hospital of Wisconsin, Milwaukee, Wis, for the evaluation and treatment of a mandibular right posterior swelling in association with his primary mandibular right second molar and a one-week history of pain. Based on the parent's description of the swelling via a phone interview the week prior, the patient was prescribed a course of systemic antibiotics. The

dental history revealed that the patient had previously received operative treatment on this tooth by a community pediatric dentist.

Clinical examination revealed a vestibular abscess adjacent to the primary mandibular right second molar. Sensitivity was documented with percussion, and the tooth had greater than physiologic mobility. On palpation, there was pain and exudate. A periapical radiograph revealed bone alterations and a furcation radiolucency of the primary mandibular right second molar (Figure 1a). An existing composite resin restoration was in place and in close proximity to the mesial pulp horn. Considering the history, symptoms, and clinical and radiographic findings, the primary mandibular right second molar was diagnosed with a necrotic pulp and acute furcal dentoalveolar abscess.

The clinical procedure of LSTR using 3-Mix-MP-R was completed. The pulp chamber contained only necrotic tissue, and no hemorrhage was present. The patient was asymptomatic when he returned for his four-week follow-up. Clinical evaluation showed complete soft tissue healing of the abscess. The tooth had normal mobility and was negative to percussion and palpation. Increased furcation radiolucency and trabeculation were detected on a radiograph.

The patient was symptom-free when he returned four months later and again for examination of the primary mandibular right second molar 11 months post-LSTR. Radiographic findings demonstrated continued stability and furcation bone healing (Figure 1b).

Case 2. A six-year-old African-American female presented to the Children's Hospital of Wisconsin pediatric dental residency program for an emergency pain assessment appointment with the chief complaint of a toothache on the lower right side for one week. The patient had never received dental care. The patient reported spontaneous waking pain and elicited pain with eating and drinking. No significant medical or family history was reported, and she otherwise appeared healthy.

A clinical examination revealed a large, purulent, vestibular abscess adjacent to the primary mandibular right first molar. The tooth exhibited pathologic mobility and was depressible to occlusal forces. The patient was highly sensitive to percussion, and on palpation there was pain and exudate. A periapical radiograph revealed distal-occlusal caries extending into the

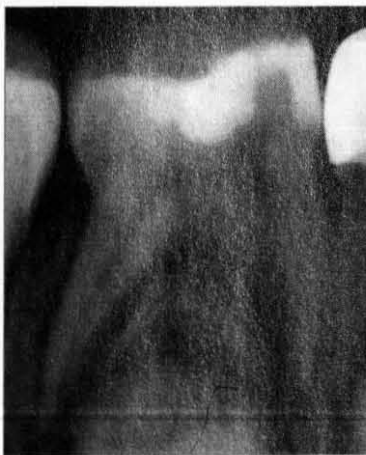

Figure 1a. Initial periapical radiograph showing a furcation radiolucency.

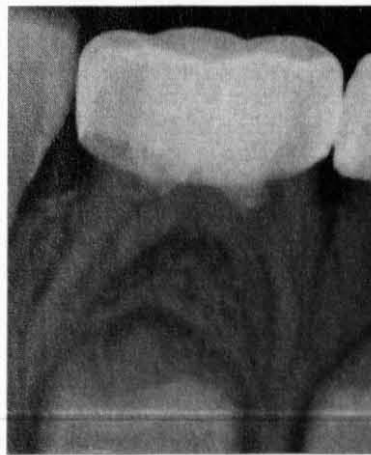

Figure 1b. Eleven months post-op, a periapical radiograph showed continued stability and furcation bone healing.

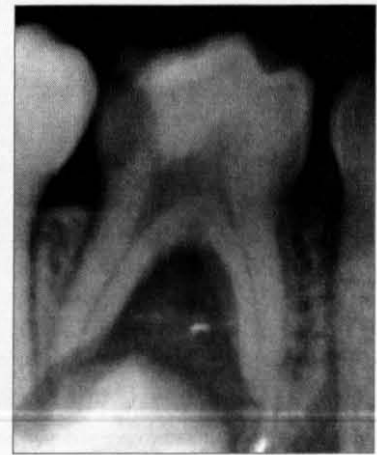

Figure 2a. Initial periapical radiograph showed dental caries extending to the distal pulp horn and a furcation radiolucency.

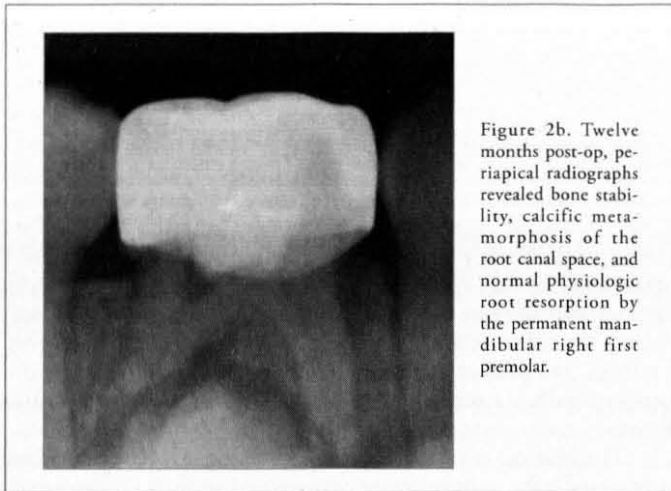


Figure 2b. Twelve months post-op, periapical radiographs revealed bone stability, calcific metamorphosis of the root canal space, and normal physiologic root resorption by the permanent mandibular right first premolar.

distal pulp horn of the primary mandibular right first molar (Figure 2a). A furcation radiolucency and loss of lamina dura were noted. The tooth was diagnosed with necrotic pulp and an acute apical dentoalveolar abscess. The patient was prescribed systemic antibiotics and scheduled for a treatment appointment.

Following a one-week course of a systemic antibiotic, the clinical procedure of LSTR using 3-Mix-MP-R was completed. The pulp chamber was found to contain only dry necrotic tissue. At the three-month follow-up appointment, no symptoms were reported. On clinical exam, the primary mandibular right first molar was negative to percussion and palpation and had physiologic mobility. The soft tissue showed complete healing of the abscess. A periapical radiograph was taken and demonstrated increased deposition of bone in the furcation area and the return of the lamina dura.

The patient was asymptomatic 12 months post-LSTR and showed nothing remarkable during a clinical exam. Radiographic findings revealed bone stability, calcific metamorphosis of the root canal space, and normal physiologic root resorption by the permanent mandibular right first premolar (Figure 2b).

Case 3. A four-year-old Hispanic female without a significant medical and family history was referred to the Children's Hospital of Wisconsin's pediatric dental residency program for evaluation and dental care. The patient reported severe tooth pain on her lower right side. On clinical examination, a large carious lesion was noted on the occlusal surface of the primary mandibular right second molar along with a buccal vestibular abscess. The tooth had normal physiologic mobility but was positive to percussion and palpation. A lower right periapical radiograph revealed a furcation radiolucency overlying the succedaneous tooth bud (Figure 3a). Based on the clinical and radiographic findings, the tooth was diagnosed with a necrotic pulp/irreversible pulpitis with acute apical dentoalveolar infection.

During the clinical procedure, necrotic tissue was found in the mesial canal and hemorrhage was present in the distal canal. Necrotic tissue was removed and the chamber was cleansed with 35 percent phosphoric acid. Hemostasis in the distal canal was achieved by applying pressure with a cotton pellet saturated with 10 percent NaOCl. The remainder of the protocol was then completed.

The patient was asymptomatic when she returned for a one-month follow-up visit. Clinical evaluation showed soft tissue healing of the abscess. The tooth continued to have physiologic mobility and responded normally to palpation and percussion.

At the four-month and 10-month visit post-LSTR, the patient continued to be asymptomatic. The soft tissue remained healthy. Periapical radiographs demonstrated increased trabeculation and radiodensity in the furcation area. Slight internal resorption of the distal canal was noted at the four-month follow-up; however, the radiograph from the 10-month follow-up showed reversal of this internal resorption. (Figure 3b and 3c).

Discussion

To date, there have been limited evidence-based clinical studies of 3-Mix-MP-R employed in LSTR therapy. The techniques have varied slightly, and the results have been inconsistent. Nakornchai et al.³⁸ compared the clinical and radiographic success of 3-Mix-MP and Vitapex (premixed calcium hydroxide-

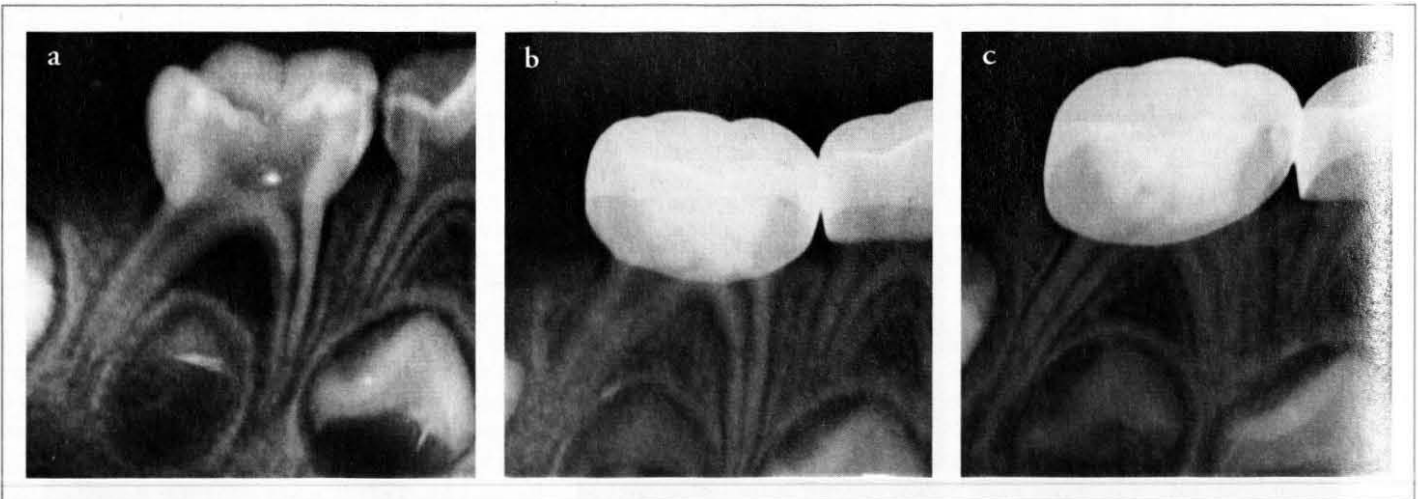


Figure 3. (a) Initial periapical radiograph showing occlusal caries extending into the pulp chamber with a furcation radiolucency overlying the permanent tooth bud. (b) Four months post-op, the periapical radiograph demonstrated increased trabeculation in the furcation area. Slight internal resorption noted in the distal canal. (c) Ten months post-op, radiographic findings demonstrated stability of the inter-radicular and periapical structures and a normal periodontal ligament space. Internal resorption in the distal canal has resolved.

and iodoform root canal medicament; Neo Dental International, Federal Way, Wash., USA) for root canal treatment on pulpally involved primary molars using 2.5 percent NaOCl as a cleansing agent. No significant differences were found clinically or radiographically between the two groups at 12 months, and they concluded that both 3-Mix-MP and Vitapex can be used as root canal treatment agents in pulpally involved primary teeth. They summarized that the simple and short procedures of 3-Mix-MP may be superior to other materials used for root canal treatment in children and more advantageous in teeth with preoperative root resorption.

Prabhakar et al.³⁹ evaluated the success of 3-Mix-MP LSTR in two groups using no bactericidal cleansing agent, only saline. In the first group, only the necrotic coronal pulp was removed, which was similar to the procedure performed by Takushige et al.⁸ In the second group, both the necrotic coronal and accessible radicular pulp tissue were extirpated. Both groups were treated with the 3-Mix-MP Dental Paste and restored with composite resin. They found that both groups showed considerable clinical and radiographic success. Statistical significance was found between the two groups concerning radiographic evaluation. The second group showed more bone regeneration, less static bone morphology, and no increase in lesion size when compared to the first group. This finding can likely be attributed to the fact that the second group had more infected tissue removed with the extirpation of the radicular pulp, possibly increasing the chances for success.

Trairatvorakul et al.⁴⁰ evaluated the success rates of 3-Mix-MP LSTR treatments in primary mandibular molars using ethylenediamine tetraacetic acid (CU-Dent, Bangkok, Thailand) as the cleansing agent at 24 to 27 months post-operation. They found satisfactory clinical success with LSTR but low success rates based on radiographic evaluation, which may be attributed to their radiographic criteria. Nakornchaio et al.³⁸ and Prabhakar et al.³⁹ defined radiographic success as a decrease in the radiolucency compared to the preoperative status or an unchanged radiolucent state in a static relationship; however, Trairatvorakul et al.⁴⁰ categorized static cases that showed no change at six months into a "further observation group" and considered them as failures with unchanged pathology at the 12-month follow-up.

Agarwal et al.⁴¹ evaluated the success of 3-Mix-MP LSTR, Pulpotec (a mixture of polyoxymethylene, iodoform, dexamethasone acetate, formaldehyde, phenol, and guaiacol, Produits Dentaires SA, Vevey, Switzerland) pulpotomy, and traditional zinc oxide eugenol pulpotomy of primary molars with vital carious exposure that showed no clinical or radiographic signs of pathology. They found that 3-Mix-MP using five percent NaOCl immersed in cotton to control the hemorrhage had significantly lower success rates with vital pulps. This study did not address necrotic primary molars.

The three cases completed using the Children's Hospital of Wisconsin's 3-Mix-MP-R appear promising and support the clinical findings of Takushige et al.⁸ It was found that LSTR therapy provided an excellent alternative to pulpectomies and extractions for nonvital primary teeth. However, caution should be taken when dentists administer local or systemic medications. Takushige et al.⁸ reported no side effects with the delivery of topical antibiotics, but LSTR should be avoided if a child is sensitive or allergic to any of the antibiotics or chemicals involved.

If clinical symptoms do not improve or reappear, retreatment is warranted with special attention to a fresh preparation of 3-Mix-MP-R and a tight seal that prevents microleakage.

To the best of our knowledge, no research has been completed to compare the effectiveness of the original and new formulations, but theoretical empirical evidence suggests that the substitution of clindamycin for the minocycline would be similarly effective as the original formula studied by Takushige et al.⁸

Given the positive results of the three completed cases, further controlled clinical trials are warranted with long-term follow-up to assess the exfoliation of the treated teeth and to determine the implications, if any, to the succedaneous teeth. Additionally, for LSTR to become a reliable treatment option, the selection criteria and protocol need to be continually redefined and updated to yield the best predictable outcomes.

Clinical cases of LSTR therapy show exciting and promising results for the future of pediatric dentistry. LSTR therapy is particularly favorable for young patients because it can potentially avoid extraction and is relatively nontraumatic to the patient. In addition, the restored tooth is more stable in the dental arch than a space maintainer and the procedure time is shortened. With continued research and consistent favorable results, LSTR certainly has the potential to be a revolutionary therapy for the treatment of abscessed primary molars.

Acknowledgment

The authors wish to thank the compounding pharmacist, Jacob Olson, PharmD, president and CEO of Skywalk Pharmacy and Carli DiGioia, DMD, attending pediatric dentist, both at the Children's Hospital of Wisconsin, for their guidance in the preparation of this manuscript. This paper is dedicated to the memory of Dr. Charles Post, DDS, devoted director of Children's Hospital of Wisconsin pediatric dental residency program, mentor, and friend.

References

1. McDonald RE, Avery DR, Dean JA. Treatment of deep caries, vital pulp exposure, and pulpless teeth. In: McDonald RE, Avery DR, eds. *Dentistry for the Child and Adolescent*. 8th ed. Philadelphia, Pa: CV Mosby Co; 2004:388-412.
2. American Academy of Pediatric Dentistry. Guideline on management of developing dentition and occlusion in pediatric dentistry. *Pediatr Dent* 2012;34:239-51.
3. Belanger G. Pulp therapy for the primary dentition. *Pediatr Dent* 1988;10:257-67.
4. AAPD. *Handbook of Pediatric Dentistry*. Casamassimo P, Nowak A. 3rd ed. Edinburg, Scotland: Elsevier; 2008.
5. Chougule R, Padmanabhan M, Mandal M. A comparative evaluation of root canal length measurement techniques in primary teeth. *Pediatr Dent* 2012;34:e53-e56.
6. Johnson M, Britto L, Guelmann M. Impact of a biological barrier in pulpectomies of primary molars. *Pediatr Dent* 2006;28:506-10.
7. Sjogren U, Figdor D, Persson S, Sundqvist G. Influence of infection at the time of root filling on the outcome of endodontic treatment of teeth with apical periodontitis. *Int Endod J* 1997;30:297-306.
8. Takushige T, Cruz E, Moral A, Hoshino E. Endodontic treatment of primary teeth using a combination of antibacterial drugs. *Int Endod J* 2004;37:132-8.
9. Hoshino E. Predominant obligate anaerobes in human carious dentine. *J Dent Res* 1985;64:1195-8.
10. Hoshino E, Ando N, Sato M, Kota K. Bacterial invasion of non-exposed dental pulp. *Int Endod J* 1992;25:2-5.

11. Ando N, Hoshino E. Predominant obligate anaerobes invading the deep layers of root canal dentine. *Int Endod J* 1990;23:20-7.
12. Sato T, Hoshino E, Uematsu H, Noda T. Predominant obligate anaerobes in necrotic pulps of human deciduous teeth. *Microb Ecol Health Dis* 1993;6:269-75.
13. Kiryu T, Hoshino E. Bacteria invading periapical cementum. *J Endod* 1994;20:169-72.
14. Hoshino E, Sato M, Sasano T, Kota K. Characterization of bacterial deposits formed in vivo on hydrogen-ion-sensitive field transistor electrodes and enamel surfaces. *Jap J Oral Biol* 1989;31:102-6.
15. Hori R, Kohno S, Hoshino E. Tongue microflora in edentulous geriatric denture-wearers. *Microb Ecol Health Dis* 1999;11:89-95.
16. Uematsu H, Hoshino E. Predominant obligate anaerobes in human periodontal pockets. *J Periodontol Res* 1992;27:15-9.
17. Hoshino E, Echigo S, Yamada T, Teshima T. Isolation of propionibacterium acnes from sclerosing osteomyelitis of mandibles. *Jap J Oral Biol* 1984;26:48-51.
18. Sato T, Hoshino E, Uematsu H, Noda T. In vitro antimicrobial susceptibility to combinations of drugs of bacteria from carious and endodontic lesions of human deciduous teeth. *Oral Microbiol Immunol* 1993;8:172-6.
19. Windley W III, Teixeira F, Levin L, Sigurdsson A, Trope M. Disinfection of immature teeth with triple antibiotic paste. *J Endod* 2005;31:439-43.
20. Hoshino E, Iwaku M, Sato M, Ando N, Kota K. Bactericidal efficacy of metronidazole against bacteria of human carious dentine in vivo. *Caries Res* 1989;23:78-80.
21. Hoshino E, Sato M, Uematsu H, Kota K. Bactericidal efficacy of metronidazole against bacteria of human periodontal pockets in vitro. *Jap J Oral Biol* 1991;33:483-9.
22. Hoshino E, Ando N, Sato I et al. In vitro antimicrobial susceptibility of bacteria taken from infected root dentine to a mixture of ciprofloxacin, metronidazole, and minocycline. *Int Endod J* 1996;29:125-30.
23. Sato I, Kurihara-Ando N, Kota K, Iwaku M, Hoshino E. Sterilization of infected root-canal dentine by topical application of a mixture of ciprofloxacin, metronidazole, and minocycline in situ. *Int Endod J* 1996;29:118-24.
24. Hori R, Kohno S, Hoshino E. Bactericidal eradication from carious lesions of prepared abutments by an antibacterial temporary cement. *J Prosthet Dent* 1997;77:348-52.
25. Takushige T, Hoshino E. Clinical evaluation of 3Mix-MP method in endodontic treatment. *Jap J Conserv Dent* 1998;41:970-4.
26. Sato T, Hoshino E, Uematsu H, Kota K, Iwaku M, Noda T. Bactericidal efficacy of a mixture of ciprofloxacin, metronidazole, minocycline and rifampicin against bacteria of carious and endodontic lesions of human deciduous teeth. *Microb Ecol Health Dis* 1992;5:171-7.
27. Er K, Kustarci A, Ozan U, Tasdemir T. Nonsurgical endodontic treatment of dens invaginatus in a mandibular premolar with large periradicular lesion: a case report. *J Endod* 2007;33:322-4.
28. Ozan U, Er K. Endodontic treatment of a large cyst like periradicular lesion using a combination of antibiotic drugs: a case report. *J Endod* 2005;31:898-900.
29. Kusgoz A, Yildirim T, Er K, Arslan I. Retreatment of a resected tooth associated with a large periradicular lesion by using a triple antibiotic paste and mineral trioxide aggregate: a case report with a thirty-month follow-up. *J Endod* 2009;35:1603-6.
30. Taneja S, Kumari M, Parkash H. Nonsurgical healing of large periradicular lesions using a triple antibiotic paste: a case series. *Contemp Clin Dent* 2010;1:31-5.
31. Manuel ST, Parolia A, Kundabala M, Vikram M. Non-surgical endodontic therapy using triple-antibiotic paste. *KDJ* 2010;33:88-90.
32. Iwaya S, Ikawa M, Kubota M. Revascularization of an immature permanent tooth with apical periodontitis and sinus tract. *Dent Traumatol* 2001;17:185-7.
33. Banchs F, Trope M. Revascularization of an immature permanent teeth with apical periodontitis: new treatment protocol? *J Endod* 2004;30:196-200.
34. Jung I, Lee S, Hargreaves K. Biologically based treatment of immature permanent teeth with pulpal necrosis: a case series. *J Endod* 2008;34:876-87.
35. Cruz EV, Kota K, Huque J, Iwaku M, Hoshino E. Penetration of propylene glycol into dentine. *Int Endod J* 2002;35:330-6.
36. Kim J, Kim Y, Shin S, Park J, Jung I. Tooth discoloration of immature permanent incisor associated with triple antibiotic therapy: a case report. *J Endod* 2010;36:1086-91.
37. Christian J. Odontogenic infections. In: Flint P, Haughey B, Lund V, et al, eds. *Cummings Otolaryngology: Head and Neck Surgery*. 5th ed. Maryland Heights, Mo: Mosby Co; 2010:177-90.
38. Nakornchai S, Banditsing P, Visetratana N. Clinical evaluation of 3Mix and Vitapex as treatment options for pulpally involved primary molars. *Int J Paediatr Dent* 2010;20:214-21.
39. Prabhakar AR, Sridevi E, Raju OS, Satish V. Endodontic treatment of primary teeth using combination of antibacterial drugs: an in vivo study. *J Indian Soc Pedod Prev Dent* 2008;26:5-10.
40. Trairatvorakul C, Detsomboonrat P. Success rates of mixture of ciprofloxacin, metronidazole, and minocycline antibiotics used in the non-instrumentation endodontic treatment of mandibular primary molars with carious pulp involvement. *Int J Paediatr Dent* 2012;22:217-27.
41. Agarwal M, Das UM, Vishwanath D. A comparative evaluation of noninstrumentation endodontic techniques with conventional ZOE pulpectomy in deciduous molars: an in vivo study. *World J Dent* 2011;2:187-92.