

Marquette University
e-Publications@Marquette

Physician Assistant Studies Faculty Research and
Publications

Physician Assistant Studies, Department

12-17-2010

Abnormalities Caused by Left Bundle Branch Block

James F. Ginter
Aurora Cardiovascular Services

Patrick Loftis
Marquette University, patrick.loftis@marquette.edu

Published version. *Journal of the American Academy of Physician Assistants*, Vol. 23, No. 12 (December 2010). [Permalink](#). © 2010, American Academy of Physician Assistants and Haymarket Media Inc. Used with permission.

Abnormalities caused by left bundle branch block

[James F. Ginter, MPAS, PA-C](#), [Patrick Loftis, PA-C, MPAS, RN](#)

December 17 2010

One of the keys to achieving maximal cardiac output is simultaneous contraction of the atria followed by simultaneous contraction of the ventricles. The cardiac conduction system (**Figure 1**) coordinates the polarization and contraction of the heart chambers. As reviewed in the earlier segment of this department on right bundle branch block (RBBB), the process begins with a stimulus from the sinoatrial (SA) node. The stimulus is then slowed in the atrioventricular (AV) node, allowing complete contraction of the atria. From there, the stimulus proceeds to the His bundle and then to the left and right bundle branches. The bundle branches are responsible for delivering the stimulus to the Purkinje fibers of the left and right ventricles at the same speed, which allows simultaneous contraction of the ventricles. Bundle branch blocks are common disorders of the cardiac conduction system. They can affect the right bundle, the left bundle, or one of its branches (fascicular block), or they may occur in combination.

Symptoms A left bundle branch block (LBBB) does not usually cause symptoms, but it can diminish cardiac performance in a healthy heart. A LBBB causes the ventricles to be activated sequentially rather than simultaneously; this leads to wall-motion abnormalities. When the two papillary muscles are not simultaneously activated, mitral regurgitation can result. The significance of these abnormalities may not be apparent in the patient with adequate left ventricular systolic function, but they can make systolic dysfunction more pronounced.

Etiology Unlike a right bundle branch block, left bundle branch block rarely occurs in the normal heart. LBBB is an acquired condition that usually reflects underlying cardiac disease. In a patient who has no apparent cardiac disease when LBBB is discovered, development of cardiac disease is likely. Left bundle branch block is generally an indicator of left ventricular disease, most often cardiomyopathy. Common causes of LBBB are hypertension; coronary artery disease; acute myocarditis; and valvular disease, especially aortic stenosis.

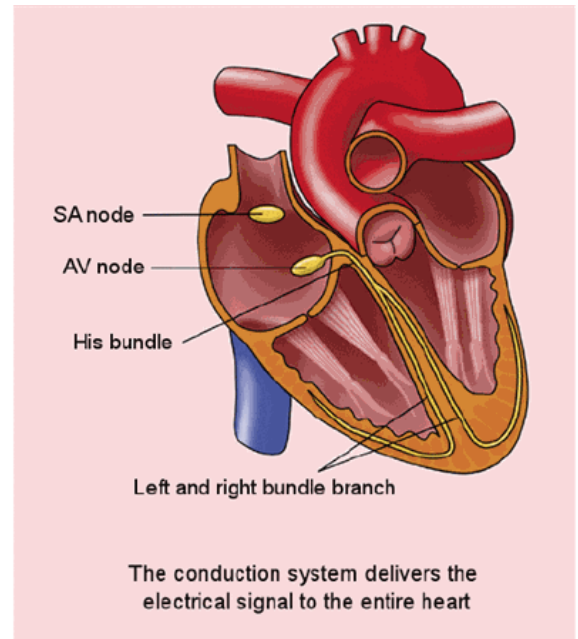


FIGURE 1. Normal conduction pathway (Purkinje fibers not shown)

ECG findings

Left bundle branch block Partial or complete interruption in the conduction of electricity through the left bundle branch has a twofold effect: (1) a slowing in overall ventricular depolarization, causing the duration of the QRS complex to increase to more than 120 milliseconds and (2) depolarization and contraction occurring at different times in the two ventricles. On the ECG, LBBB is best recognized in the precordial leads V₁ and V₆. In lead V₁, the QRS complex is below the baseline (**Figure 2**). In lead V₆, the small Q wave is absent, and there is a prolongation in the rise of the R wave, which may be slurred or notched on the top (**Figure 3**). The RSR' waves or "bunny ears" are not as pronounced in LBBB as they are in RBBB. In an uncomplicated LBBB, the direction of the ST segment and T wave is opposite to that of the QRS complex (eg, discordant) in leads V₁, V₂, and V₅ or V₆. In the patient who has left bundle branch block and myocardial disease, such as cardiomyopathy or ischemia, the direction of the ST segment and T wave is the same as that of the QRS complex (concordant) in those leads.

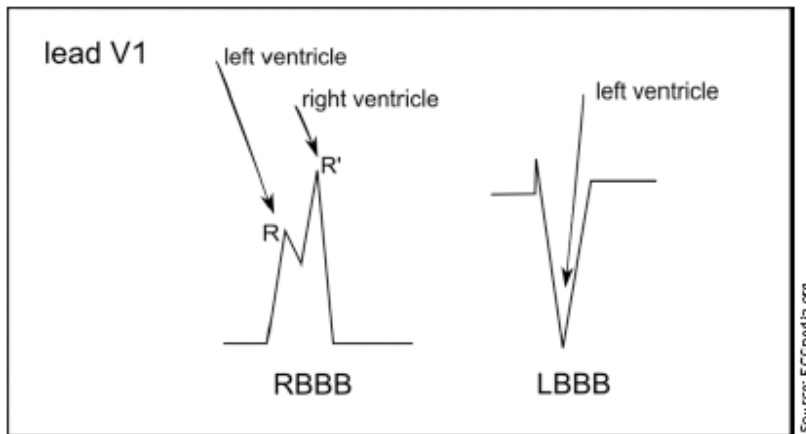


FIGURE 2. In left bundle branch block, the QRS complex in lead V₁ is below the baseline and the RSR' is less prominent than in a right bundle branch block.

Fascicular blocks Unlike the right bundle branch, which is long and thin, the left bundle branch divides into the left anterior and left posterior fascicles (**Figure 4**). An isolated left anterior fascicular block is a common occurrence, but an isolated left posterior fascicular block is rare.¹

A *left anterior fascicular block (LAFB)* is the interruption of electrical activity in the anterior fascicle of the left bundle and results in delayed depolarization of the upper anterior part of the left ventricle. When this happens, the ECG shows left axis deviation (usually less than -60°), small Q waves in leads I and aVL, a small R wave in leads II, III, and aVF, and QRS duration that is less than 0.12 seconds in all leads (**Figure 5**). LAFB is commonly a result of hypertension, ischemic heart disease, cardiomyopathy, and aortic valve disease. No treatment is required for the LAFB, but patients should receive therapy directed at the underlying cause.

Left posterior fascicular block (LPFB) is the interruption of electrical conductivity in the posterior fascicle of the left bundle. LPFB results in delayed depolarization of the lower posterior part of the left ventricle. The ECG of a patient with LPFB demonstrates right axis deviation greater than $+120^\circ$; a small R wave in leads I and aVL; a small Q wave in leads II, III, and aVF; and a QRS duration

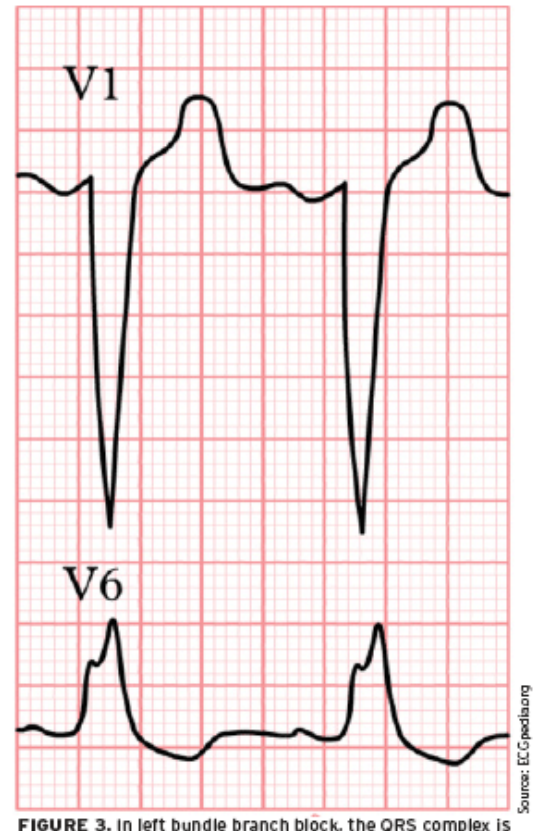

FIGURE 3. In left bundle branch block, the QRS complex is

that is less than 0.12 seconds in all leads. LPFB is an uncommon occurrence and a diagnosis of exclusion. The causes of LPFB are the same as those of LAFB. Treatment should be directed at the underlying cause.

below the baseline in lead V1 and there is prolongation of the R wave, which may appear notched at the top.

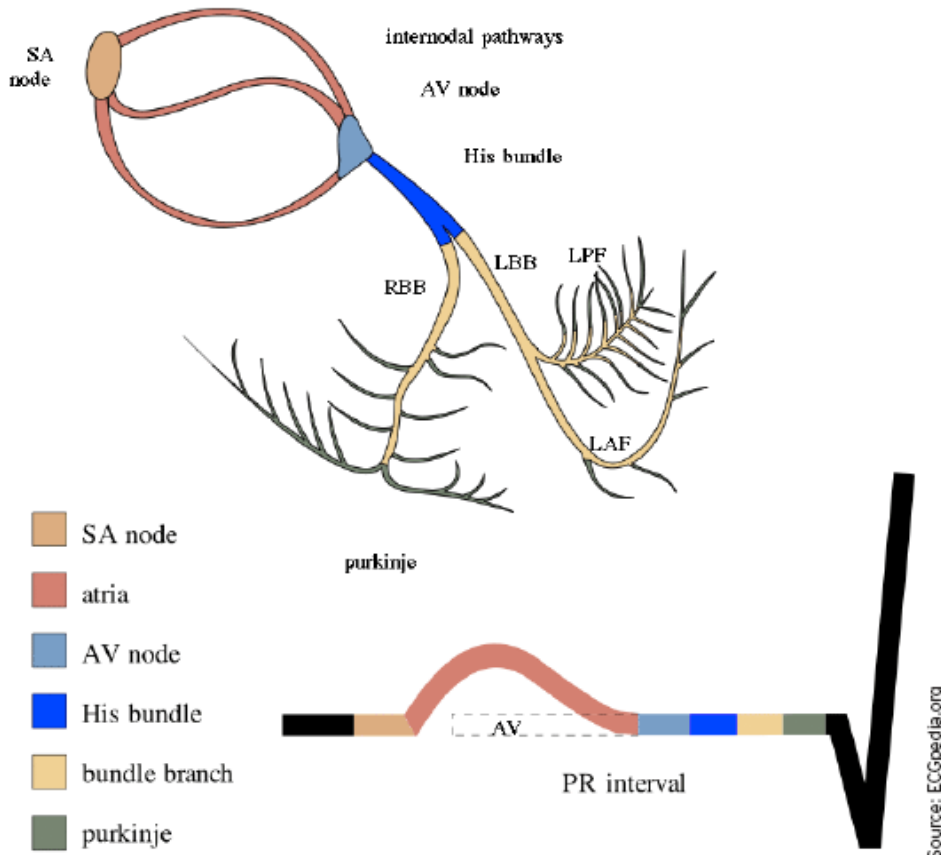


FIGURE 4. Right bundle branch and left bundle branch with its left anterior and posterior fascicles

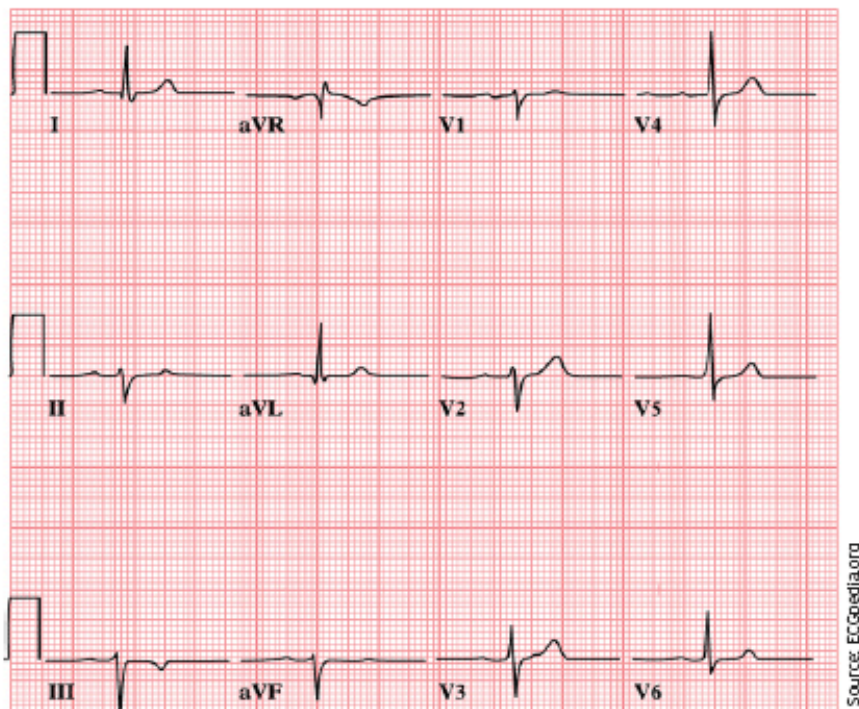
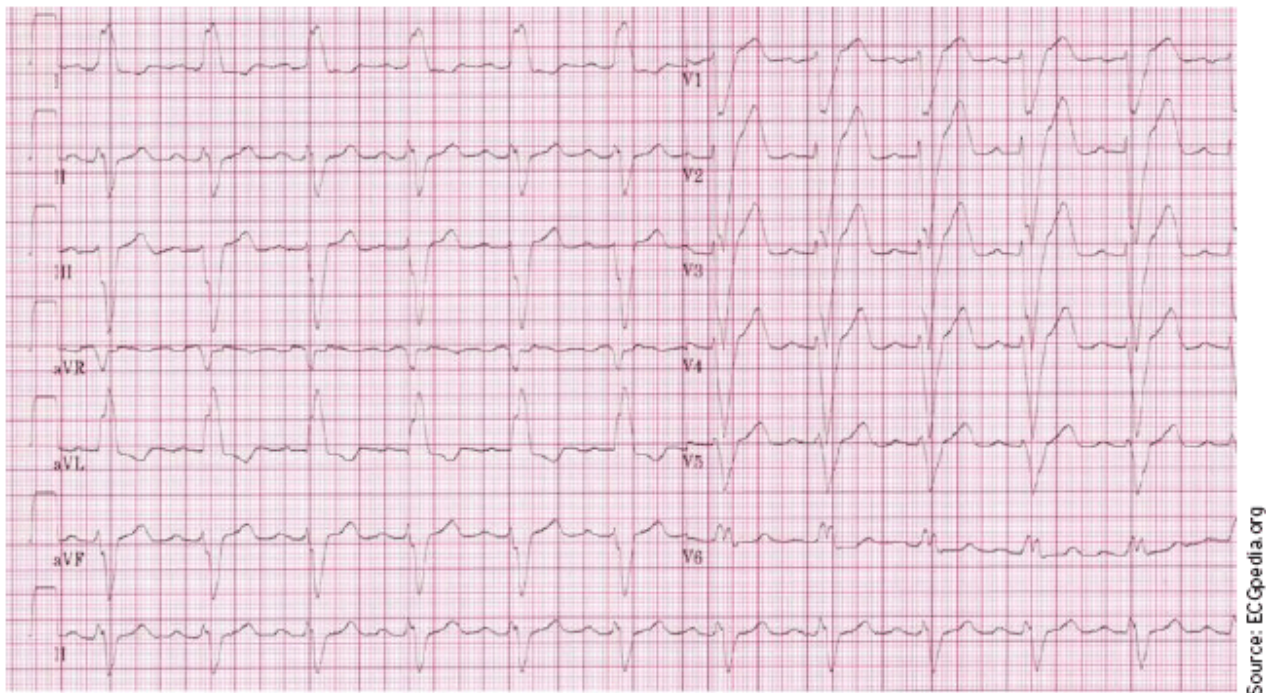

FIGURE 5. ECG of a patient with left anterior fascicular block



Source: ECGpedia.org

FIGURE 6. ECG of a 76-year-old man with hypertension and known heart failure

ECG challenge

A 76-year-old man with hypertension and known heart failure presented with dyspnea. On physical examination, no heart murmur was appreciated but rales were heard in both lung fields. Chest radiography revealed cardiomegaly with pulmonary congestion. The patient was taking diuretics and an ACE inhibitor. An ECG was obtained (**Figure 6**) and compared with an ECG recorded 3 months prior to this evaluation.

Stepwise analysis of the ECG

1. Is the ECG **regular**? Yes. The QRS complexes march out.
2. Determine the patient's heart **rate** by finding a QRS complex on or near a dark line.

Method A: There are approximately four large boxes between QRS complexes. Counting 300, 150, 100, 75 gives us a rate of 75 beats per minute.

Method B: About eight QRS complexes occur in 6 seconds (30 large boxes), which estimates the heart rate at 80 beats per minute (8×10).

Method C: Dividing 300 by the number of large boxes between R waves (four) gives us an estimated heart rate of 75 beats per minute.

3. There is a **P wave** for each QRS, and all P waves look the same.
4. The **PR interval** spans about six small boxes, which is 240 milliseconds. This is first-degree heart block.
5. The **QRS complex** spans more than three small boxes (120 milliseconds), which is wider than normal. This finding may indicate a bundle branch block or a nonspecific intraventricular conduction delay. To distinguish between the two, we need to examine the QRS in leads V₁, V₂, and V₆. In leads V₁ and V₂, the QRS is below baseline. Looking at lead V₆, we see a notched R wave. All these findings indicate the presence of a left bundle

branch block.

6. **ST-segment deviation** is unreliable in the setting of a bundle branch block, as the block itself causes some changes here.
7. **T-wave** is concordant (eg, occurs in the same direction as the QRS) in V₆. This is a normal finding in a patient with a bundle branch block and heart failure.
8. **No U waves** are present.

Treatment The current ECG was similar to the ECG recorded 3 months prior to this evaluation. The patient was admitted for his heart failure symptoms, and an electrophysiology consult was obtained for possible pacemaker placement. [JAAPA](#)

Jim Ginter practices at Aurora Cardiovascular Services in Milwaukee, Wisconsin. **Patrick Loftis** practices emergency medicine and is clinical assistant professor in the Department of Physician Assistant Studies, Marquette University, Milwaukee, Wisconsin. The authors have no relationships to disclose relating to the contents of this article.

REFERENCE

1. Rosenbaum MB, Elizari MV, Lazzari JO. *The Hemiblocks: New Concepts of Intraventricular Conduction Based on Human Anatomical, Physiological, and Clinical Studies*. Oldsmar, FL: Tampa Tracings; 1970:100.