

10-1-1966

Pneumonia Due to Mycoplasma in Gnotobiotic Mice I. Pathogenicity of *Mycoplasma pneumoniae*, *Mycoplasma salivarium*, and *Mycoplasma pulmonis* for the Lungs of Conventional and Gnotobiotic Mice

Irving I. Lutsky  
*Marquette University*

Avrum B. Organick  
*Marquette University*

# Pneumonia Due to *Mycoplasma* in Gnotobiotic Mice

## I. Pathogenicity of *Mycoplasma pneumoniae*, *Mycoplasma salivarium*, and *Mycoplasma pulmonis* for the Lungs of Conventional and Gnotobiotic Mice

IRVING I. LUTSKY AND AVRUM B. ORGANICK

*Allen-Bradley Medical Science Laboratory and Department of Medicine, Marquette University School of Medicine, Milwaukee, Wisconsin*

Received for publication 18 June 1966

### ABSTRACTS

LUTSKY, IRVING I. (Marquette University School of Medicine, Milwaukee, Wis.), AND AVRUM B. ORGANICK. Pneumonia due to mycoplasma in gnotobiotic mice. I. Pathogenicity of *Mycoplasma pneumoniae*, *Mycoplasma salivarium*, and *Mycoplasma pulmonis* for the lungs of conventional and gnotobiotic mice. *J. Bacteriol.* **92**:1154-1163. 1966.—Two species of mycoplasma of human origin, *Mycoplasma pneumoniae* and *M. salivarium*, were tested for their ability to produce respiratory disease in the Ha/ICR mouse when inoculated by the intranasal route. The mouse pathogen *M. pulmonis* was studied as a positive control. Conventional and gnotobiotic Ha/ICR mice were employed, the latter to provide a system free from indigenous mycoplasma and bacteria. Pneumonia from which mycoplasma were isolated was produced in all groups of the conventional Ha/ICR mice, including those inoculated with sterile broth. Only *M. pulmonis* produced disease when inoculated intranasally into the gnotobiotic mice, and the gross and microscopic lesions resembled those described in conventional mice. The gnotobiotic mouse provided a tool to study the pathogenicity of different mycoplasma species, and indicated marked differences in host specificity that could not be clearly seen when conventional mice were used.

The demonstration that the agent of atypical pneumonia in man is a mycoplasma, *Mycoplasma pneumoniae* (1, 2), suggested that other mycoplasma species commonly found in the upper respiratory tract, e.g., *M. salivarium*, might be capable of causing respiratory disease. Studies of experimental infection with mycoplasma of human origin in laboratory animals (3, 4, 7) have the disadvantage of altering the factor of host-parasite specificity, but they afford the opportunity to examine details of the infectious process not readily available in human studies, such as the evolution of lesions and the localization of microorganisms. Intranasal inoculations in conventional rodents are often complicated by pneumonias due to indigenous murine pathogens (9). In the animal studies to be reported, gnotobiotic mice provided a system free from indigenous murine mycoplasmata and bacteria. The mouse pathogen, *M. pulmonis*, was used as a positive control with which the results of intranasal inoculations of mycoplasma of human origin, *M. pneumoniae* and *M. salivarium*, might be compared.

### MATERIALS AND METHODS

Conventional and gnotobiotic Ha/ICR mice, 4 to 6 weeks of age and of both sexes, were used throughout the study. The gnotobiotic Ha/ICR mice (supplied by A. R. Schmidt Co., Madison, Wis.) were derived originally from Ha/ICR mice by use of hysterectomy, and foster-nursed on gnotobiotic ND-1 mice. Preliminary screening in our laboratory revealed that the lungs, liver, spleen, and kidneys of these gnotobiotic mice were free from mycoplasma and bacteria.

Mice were housed in clear, autoclavable plastic cages within flexible film isolators. With conventional animals, the isolators were used to prevent aerosol cross-contamination in concurrent experiments in which different mycoplasma species were used. Three species of mycoplasma were used in the experiments: *M. pneumoniae* (M-52 strain), *M. salivarium*, and a murine mycoplasma species which produces infectious catarrh in mice, *M. pulmonis* (8).

The M-52 strain of *M. pneumoniae* (ATCC 15293; obtained from York E. Crawford, Naval Medical Research Unit No. 4, Great Lakes, Ill.) was passed four times in 20% horse serum-enriched PPLO broth (2) containing 25% yeast extract, 1,000 µg/ml of penicillin, 1:2,000 thallium acetate, and 5 µg/ml of

amphotericin B, hereafter referred to as mycoplasma broth. A 7-day growth in mycoplasma broth was divided into 2-ml portions, distributed into sterile glass ampoules, sealed, quick-frozen in an alcohol-Dry Ice mixture, and stored at  $-65^{\circ}\text{C}$ . After 10 days, colony counts performed in triplicate after thawing showed  $1.2 \times 10^7$  colony-forming units (CFU) per milliliter.

The *M. salivarium* strain was isolated from the pharynx of a normal human subject, and samples of a 24-hr growth in mycoplasma broth contained  $2.8 \times 10^7$  CFU/ml.

The *M. pulmonis* strain (kindly provided by John B. Nelson, Rockefeller University, New York, N.Y.) was derived from mice inoculated with a 30th mouse lung passage. Lungs of these mice were ground in a tissue grinder and passed five times in mycoplasma broth. Samples of a 5-day growth in mycoplasma broth contained  $1.8 \times 10^6$  CFU after a single freeze-thaw cycle. The inoculum in control animals consisted of sterile mycoplasma broth.

Intranasal inoculation of the mice with 0.05 ml of the inoculum was made with a Microtiter (Cooke Engineering, Alexandria, Va.) delivery pipette (delivering 0.025 ml per drop) to mice in the isolators after ether anesthesia.

In the studies involving the gnotobiotic mice, samplings of feces, bedding, and water for bacteria, mycoplasma, and fungi were made according to standard isolator techniques (12). The clinical appearance of the animals was observed several times daily through the clear cages, and all animals found dead were removed as soon as possible. Mice to be sacrificed were killed by traction of the neck. Sterile paper bags were used to transfer gnotobiotic mice from the isolator to a sterile field within a hood, where the mice were necropsied. Impressions of cut surfaces of lungs were cultured on mycoplasma agar and on blood-agar, and portions of lungs were cultured in thioglycolate broth. Portions of lung were fixed in 10% formaldehyde, Bouin's or Helle's fixative, and histological sections were stained with hematoxylin and eosin.

## RESULTS

*Intranasal inoculation of mycoplasma in conventional mice.* To serve as a basis for comparison with the studies in gnotobiotic mice, 151 conventional mice were used in an initial study. The results are summarized in Table 1. Pneumonia was produced in all groups of conventional mice receiving intranasal inoculations, even those receiving sterile broth. The percentage of animals that developed pneumonia after inoculation with *M. pulmonis* was significantly greater than the controls ( $\chi^2 = 16.64$ ). *M. pulmonis* was also more pathogenic than the two mycoplasma species of human origin, *M. pneumoniae* and *M. salivarium*. Although the pathogenicity of these latter species was indistinguishable *inter se*, they were more pathogenic than sterile broth ( $\chi^2 = 9.48$ ). Mycoplasma indigenous to the mice

TABLE 1. Results of intranasal inoculation with sterile broth and with three mycoplasma species in 151 conventional mice

Inoculum	Dose in colony-forming units	No. of mice	Gross findings of pneumonia	Per cent
Sterile broth (control) . . . . .	—	28 <sup>a</sup>	5/27	18.5
<i>M. pneumoniae</i> . . . . .	$6.0 \times 10^5$	64 <sup>b</sup>	32/60	53.3
<i>M. salivarium</i> . . . . .	$1.4 \times 10^6$	30	17/30	56.6
<i>M. pulmonis</i> . . . . .	$9.0 \times 10^4$	29 <sup>c</sup>	22/28	78.5

<sup>a</sup> One mouse was cannibalized and not necropsied.

<sup>b</sup> Four mice were cannibalized and not necropsied.

<sup>c</sup> One mouse was cannibalized and not necropsied.

were indeed present, as demonstrated by the presence of pneumonia and isolation of mycoplasma from animals receiving sterile broth (Table 2). It is possible that these indigenous mycoplasma contributed to some extent to the disease produced by inoculation with the other mycoplasma species.

Bacteria indigenous to the conventional mice also might have played a role (Table 3). Large numbers of bacteria (heavy growth of bacteria in impressions on blood-agar) were present in 24 of 71 animals with pneumonia inoculated intranasally with material containing only mycoplasma. Most of these isolations (20 of 24) were from pneumonic lungs which also contained mycoplasma. Bacteria were isolated only once from 47 normal lungs, but mycoplasma were also isolated from this specimen.

*General observations on intranasal inoculation of mycoplasma in gnotobiotic mice.* Although studies in which conventional mice were used (Table 1) indicated that pneumonia was often associated with indigenous mycoplasma and bacteria, the studies with gnotobiotic mice showed clear-cut results (Table 4). Intranasal inoculation of sterile broth in 66 gnotobiotic mice did not produce a single instance of pneumonia. Furthermore, at no time were mycoplasma or bacteria ever isolated from the lungs of these control animals. Gross pneumonia was evident only in mice inoculated with *M. pulmonis*, but not in mice inoculated with the two mycoplasmata of human respiratory-tract origin, *M. pneumoniae* and *M. salivarium*.

*Results of intranasal inoculation with M. pulmonis in gnotobiotic mice.* The association of gross lesions of pneumonia with the isolation of mycoplasma is seen in Table 5. Mycoplasma were

TABLE 2. Results of intranasal inoculation with sterile broth in 28 conventional mice

Microbiological findings	Anatomical findings		
	Gross pneumonia	Grossly normal lungs	Total <sup>a</sup>
Mycoplasma . . . . .	4	2	6
Mycoplasma and bacteria . . . . .	0	0	0
Bacteria . . . . .	0	0	0
No growth . . . . .	1	20	21

<sup>a</sup> One mouse was cannibalized, and therefore not tested.

TABLE 3. Results of intranasal inoculation with bacteriologically sterile broth cultures of *Mycoplasma pneumoniae*, *M. salivarium*, and *M. pulmonis* in 123 conventional mice

Microbiological findings	Anatomical findings		
	Gross pneumonia	Grossly normal lungs	Totals <sup>a</sup>
Mycoplasma . . . . .	43	11	54
Mycoplasma and bacteria . . . . .	20	1	21
Bacteria . . . . .	4	0	4
No growth . . . . .	4	35	39

<sup>a</sup> Five mice were cannibalized, and therefore not tested.

TABLE 4. Results of intranasal inoculation with sterile broth and with three mycoplasma species in 214 gnotobiotic mice

Inoculum	Dose in colony-forming units	No. of mice	Gross findings of pneumonia
Sterile broth (control) . . . . .	—	66	0
<i>M. pneumoniae</i> . . . . .	$6.0 \times 10^5$	34	0
<i>M. salivarium</i> . . . . .	$1.4 \times 10^6$	35	0
<i>M. pulmonis</i> . . . . .	$9.0 \times 10^4$	79 <sup>a</sup>	50/73

<sup>a</sup> Six mice were cannibalized and not necropsied.

isolated in 50 of 51 lungs when pneumonia was evident grossly. Mycoplasma were also isolated in 15 of 22 instances where the lungs were grossly normal. Microscopic lesions, however, were present in 6 of these 15 lung specimens. These findings, and the absence of mycoplasma from the lungs of control gnotobiotic animals inoculated with sterile broth, confirm the sensitivity of the culture techniques employed.

The morphological features of mycoplasma colonies isolated from the lungs of mice in this

TABLE 5. Results of intranasal inoculation with *Mycoplasma pulmonis* in 79 gnotobiotic mice

Microbiological findings	Anatomical findings		
	Gross pneumonia	Grossly normal lungs	Totals <sup>a</sup>
Mycoplasma . . . . .	50 <sup>b</sup>	15 <sup>c</sup>	65
Mycoplasma and bacteria . . . . .	0	0	0
Bacteria . . . . .	0	0	0
No growth . . . . .	1	7 <sup>d</sup>	8

<sup>a</sup> Six mice were cannibalized, and therefore not tested.

<sup>b</sup> Includes one mouse sacrificed at 2 days.

<sup>c</sup> Includes two mice sacrificed 2 hr after inoculation, and four mice sacrificed 2 days after inoculation.

<sup>d</sup> Includes two mice sacrificed immediately after inoculation, and two mice sacrificed 2 hr after inoculation.

portion of the experiment were similar to those of the inoculum. Colonies were characterized by a highly vacuolated peripheral zone and by irregular and indistinct central portions (11). The periphery of the colonies was often irregular on the primary isolations from cut surfaces of lungs on mycoplasma agar, but was usually smoother on subculture (Fig. 1).

The clinical course of pneumonia in mice inoculated with *M. pulmonis* was observed and compared with the appearance and behavior of mice inoculated with sterile broth. Most animals recovered quickly from the effects of anesthesia and of the intranasal inoculation. On the day after the intranasal inoculation and during the subsequent 48 to 72 hr, all mice appeared normal. By the 4th day, however, a number of mice that had received *M. pulmonis* appeared ill. Labored respirations, ruffled fur, and slowness of movement were evident. Cyanosis was detected in the skin of the tail and feet and in a darker than normal red reflex from the eyes. Disease progressed rapidly in some animals, and the first deaths occurred on the 5th day. Between the 5th and 12th days after inoculation with *M. pulmonis*, most of the mice appeared ill. Of the 18 deaths, 16 occurred during this period (Fig. 2). Cannibalization of dead mice was frequent (in 6 of the 18). When necropsies were performed, total or nearly total involvement of all lobes with firm, uniform red to reddish-gray consolidation was seen, and mycoplasma were isolated from such lungs in every instance. After the 12th day, surviving mice appeared to improve somewhat, although they never appeared as healthy as control animals. Their food and

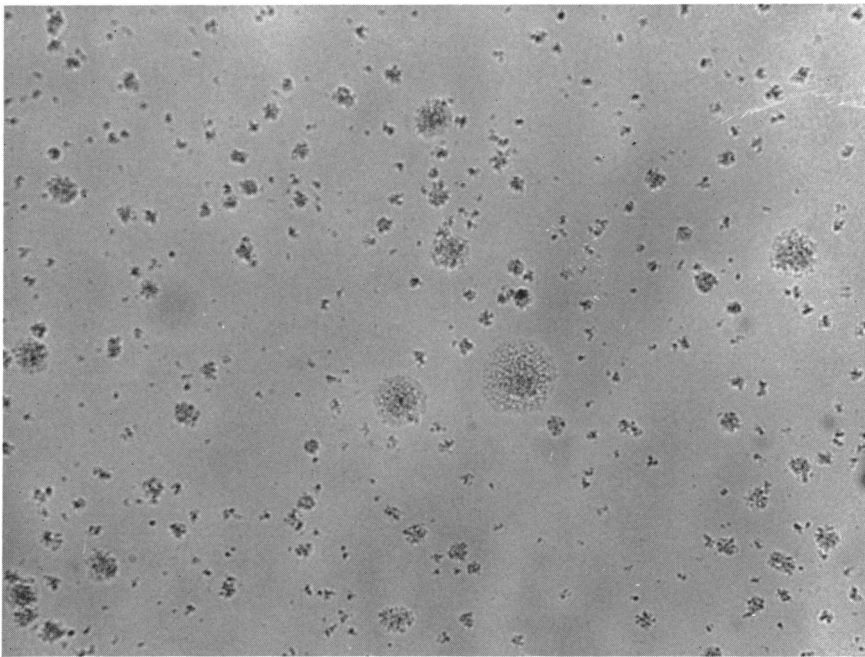


FIG. 1. Colonies of *Mycoplasma pulmonis* in subculture on mycoplasma agar ( $\times 100$ ). The larger colonies have a granular peripheral zone, and the central zone is not clearly demarcated.

water consumption remained diminished, and their growth rate was retarded. After the initial peak in mortality, deaths occurred in two animals during the 4th week.

The gross and microscopic lesions in gnotobiotic mice were similar to those described in conventional mice (5, 8, 10). Early pulmonary lesions (4 to 7 days) were grossly red to reddish-gray, and involved segments or entire lobes usually on the dorsal aspect of the lungs. Microscopically, the early lesions showed capillary engorgement, edema, hemorrhage into the alveolar spaces, and a brisk polymorphonuclear leukocytic response in the alveoli and bronchi, the lumen of bronchi often filled with exudate of these leukocytes (Fig. 3). Small numbers of round cells, principally small lymphocytes, began to appear in the interstitial spaces surrounding medium-sized blood vessels between the 4th and 7th days (Fig. 4). At 2, 3, and 4 weeks, gross lesions were gray and translucent instead of red. Infiltration by lymphocytes became more conspicuous first in the perivascular and then in the peribronchial spaces. The peribronchial and perivascular infiltrate with large and small lymphocytes and with plasma cells became the most conspicuous microscopic feature at 3 and 4 weeks (Fig. 5 and 6). In the alveoli, large pink-staining foamy macrophages were the predominant cell type, although polymorpho-

nuclear leukocytes persisted in some pneumonic areas. The exudate in the lumen of bronchi remained predominantly polymorphonuclear in type.

In spite of the vigorous cellular response during the acute stages, necrosis of bronchial epithelial cells, abscess formation, and empyema were never seen among gnotobiotics inoculated with *M. pulmonis*. Purulent exudate was expressed from the nasal passages in a small number of instances. The upper respiratory tract and middle ears were not routinely examined. No gross or microscopic lesions were noted in the spleen, liver, kidneys, or small intestine. Mycoplasma were isolated in small numbers from 4 of 5 normal-appearing spleens 4 and 7 days after inoculation.

*Results of intranasal inoculations with M. pneumoniae and M. salivarium in gnotobiotic mice.* No deaths, clinical illness, or pneumonia on gross or microscopic examination of the lungs was seen in any of 34 gnotobiotic mice inoculated with *M. pneumoniae*. Mycoplasma colonies were isolated from the lungs of 3 of 17 mice sacrificed 2 weeks after intranasal inoculation, but from none of 17 mice sacrificed 4 weeks after intranasal inoculation (Table 6). The 35 gnotobiotic mice inoculated intranasally with *M. salivarium* remained healthy throughout the 30-day observation period. The lungs were grossly and microscopically normal, and no mycoplasma were

## TIME COURSE OF DISEASE IN 365 CONVENTIONAL AND GNOTOBIOTIC MICE

DAY OF DEATH IN RELATION TO INOCULATION

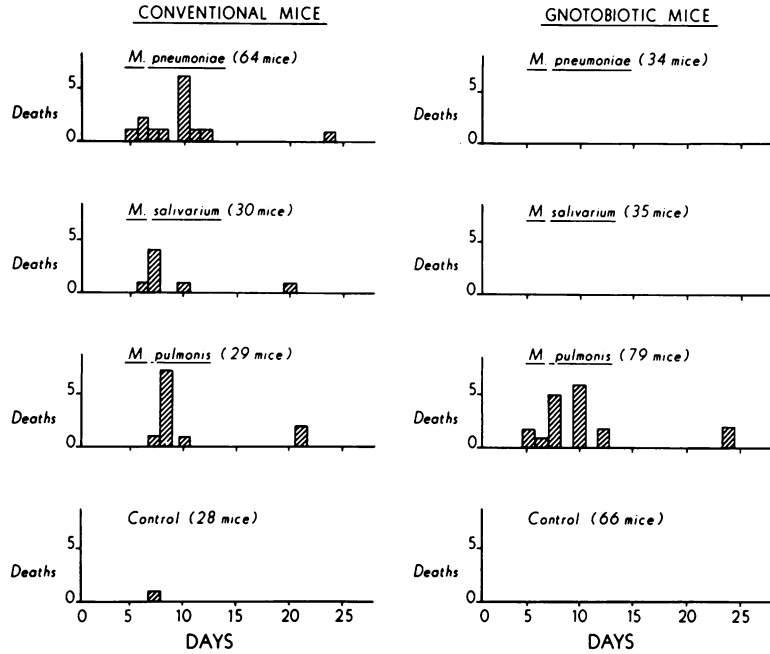


FIG. 2. Occurrence of deaths in 365 conventional and gnotobiotic mice in relation to the time of intranasal inoculation.

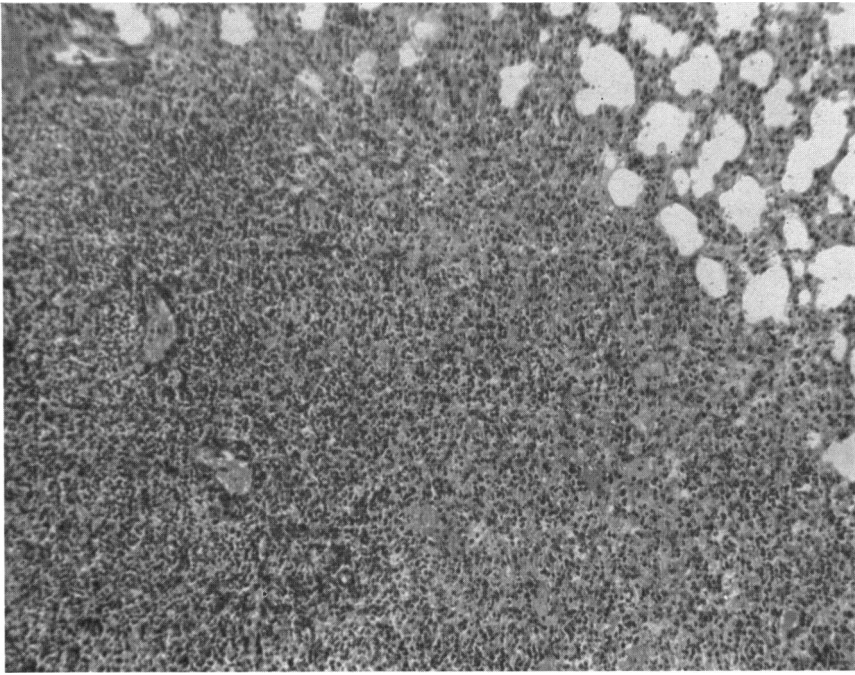
isolated from the lungs at sacrifice 2 and 4 weeks after intranasal inoculation.

*General observations on comparison of disease in gnotobiotic and conventional mice.* The time course of the disease is seen in Fig. 2, which shows the day of death in relation to the date of inoculation in 365 inoculated mice. A peak in mortality between the 5th and 12th day in all of the conventional animals corresponded to the peak in mortality in gnotobiotic mice inoculated with *M. pulmonis*. These data strongly suggest that pathogenic mycoplasma of murine origin were primarily responsible for disease and deaths in conventional mice. Isolation of mycoplasma from the lungs of mice inoculated with sterile broth (Table 2) confirmed that conventional mice harbor indigenous murine mycoplasmata, and supported the view that disease in conventional animals is due to these murine mycoplasma.

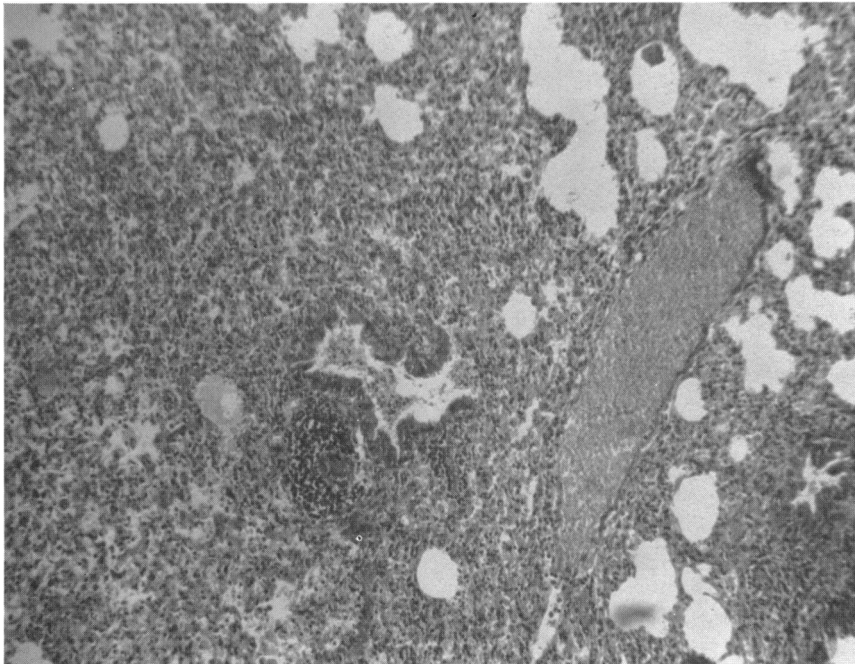
The microscopic pathology of the lung lesions and the disease course through the acute and chronic stages were the same in the conventional mice as in gnotobiotic mice inoculated with *M.*

*pulmonis*, with but three exceptions. In these three cases, abscesses were present on gross and microscopic examination of the lungs, and significant numbers of bacterial colonies were present in impressions of the lungs on blood-agar; thus, the role of bacterial infection in these conventional animals was unmistakable (Fig. 7). The role of bacterial infection in the remaining animals can only be surmised, because bacterial isolations were common in lungs showing gross evidence of pneumonia, and were rare in lungs not showing pneumonia (Table 3).

An additional difference between conventional and gnotobiotic mice was the striking absence of round-cell infiltration in the perivascular and peribronchial interstitial spaces in gnotobiotic mice inoculated with sterile broth. This finding presented a contrast to the regular appearance of small numbers of round cells in the interstitial spaces in conventional mice inoculated intranasally with sterile broth. The lungs of these gnotobiotic mice were not totally devoid of lymphocytes, for lymphocytes were seen in hilar lymph nodes and in small lymphatic vessels.



**FIG. 3.** Microscopic appearance of the early (2nd day) pulmonary lesion in the gnotobiotic mouse ( $\times 125$ ). Hematoxylin and eosin stain. Areas of consolidation have a uniform appearance; the alveolar exudate consists of pink-staining fluid and polymorphonuclear leukocytes. Small vessels and bronchi are visible within the pneumonic zone, but they have no distinguishing features.



**FIG. 4.** Pneumonia in the gnotobiotic mouse 4 days after intranasal inoculation with *Mycoplasma pulmonis* ( $\times 125$ ). Hematoxylin and eosin stain. A zone of darkly staining lymphocytes is visible surrounding a small peribronchial blood vessel. The adjacent bronchus contains an exudate of polymorphonuclear leukocytes, but there is no peribronchial infiltration by lymphocytes.

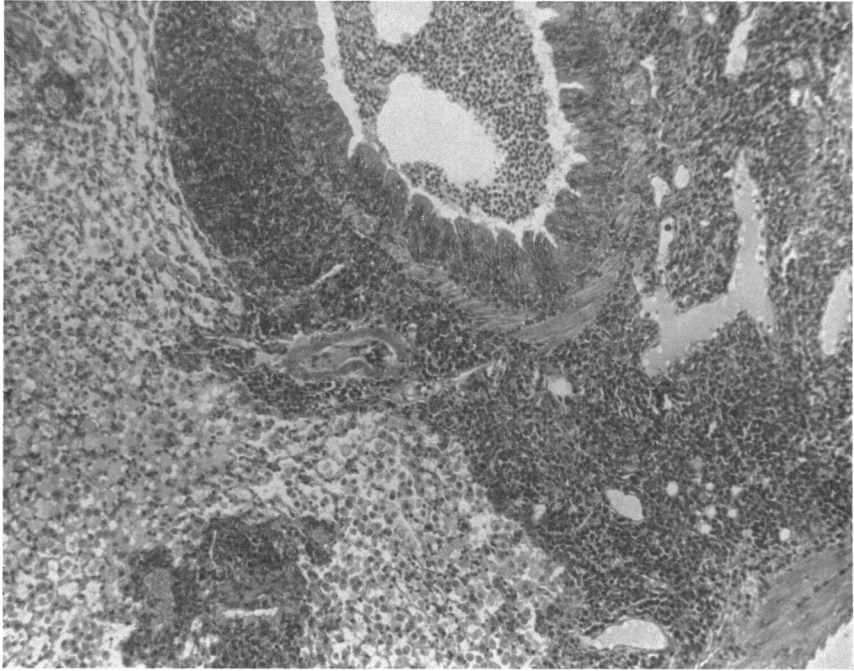


FIG. 5. Features of pneumonia in the gnotobiotic mouse 3 weeks after intranasal inoculation with *Mycoplasma pulmonis* ( $\times 125$ ). Hematoxylin and eosin stain. A large bronchus is nearly occluded by polymorphonuclear exudate. Broad zones of darkly staining lymphocytes and plasma cells surround bronchi and vessels. Alveoli contain large mononuclear cells.

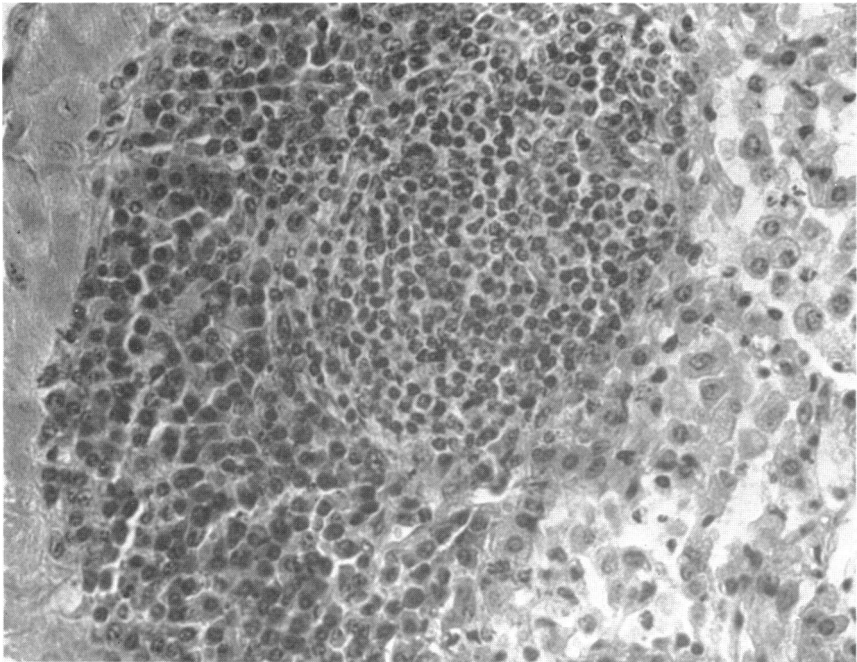


FIG. 6. Perivascular zone in the lung of a gnotobiotic mouse 3 weeks after intranasal inoculation with *Mycoplasma pulmonis* ( $\times 550$ ). Hematoxylin and eosin stain. A nodule of small, darkly staining lymphocytes and densely packed, polyhedral plasma cells can be seen. Adjacent alveoli contain large, pale-staining mononuclear cells with abundant cytoplasm.



Also, the gnotobiotic mouse was found capable of a round-cell response and of proliferation of these cells, since round cells made an appearance in the perivascular interstitial tissue within 4 to 6 days after intranasal inoculation with *M. pulmonis* and proliferated rapidly in these locations. By 2 to 4 weeks, the multiplication of round cells in the interstitial spaces was so massive that, in the infected animals, gnotobiotics as well as conventionals, round-cell proliferation represented the outstanding histological feature.

The final difference noted was the absence of spontaneous pulmonary neoplasms in the lungs

of these young gnotobiotic mice. On microscopic examination, neoplasms were found in 17 of 102 conventional mice, but not once in the lungs of 179 gnotobiotic mice of the same strain (Ha/ICR) and age.

DISCUSSION

The selection of gnotobiotic mice for this study represents a logical extension of the work of previous investigators (5, 8, 10), who recognized the need for stocks of mice free from catarrh for experiments involving intranasal inoculations. A primary concern in 1940 was the validity of experiments involving intranasal inoculations of viruses: "For virus research, the ideal would be stocks of animals as far as possible free from all latent infections, just as uncontaminated nutrient media are essential for the study of bacteria" (5). This statement is no less true for research involving mycoplasma administered by the intranasal route. Technical advances in gnotobiotic methods since 1950 have made available stocks of animals which, in the main, conform to the ideal set by Edward in 1940. The lungs of the control groups in the gnotobiotic mice used in our studies were consistently negative for mycoplasma and bacteria after the stress of intranasal inoculation of sterile broth.

The factor of host specificity is of extreme im-

TABLE 6. Results of intranasal inoculation with *Mycoplasma pneumoniae* in 34 gnotobiotic mice

Microbiological findings	Anatomical findings		
	Gross pneumonia	Grossly normal lungs	Total
Mycoplasma.....	0	3 <sup>a</sup>	3
Mycoplasma and bacteria.....	0	0	0
Bacteria.....	0	0	0
No growth.....	0	31	31

<sup>a</sup> Colonies morphologically consistent with *M. pneumoniae* were isolated in 3 of 17 animals sacrificed 2 weeks after inoculation.

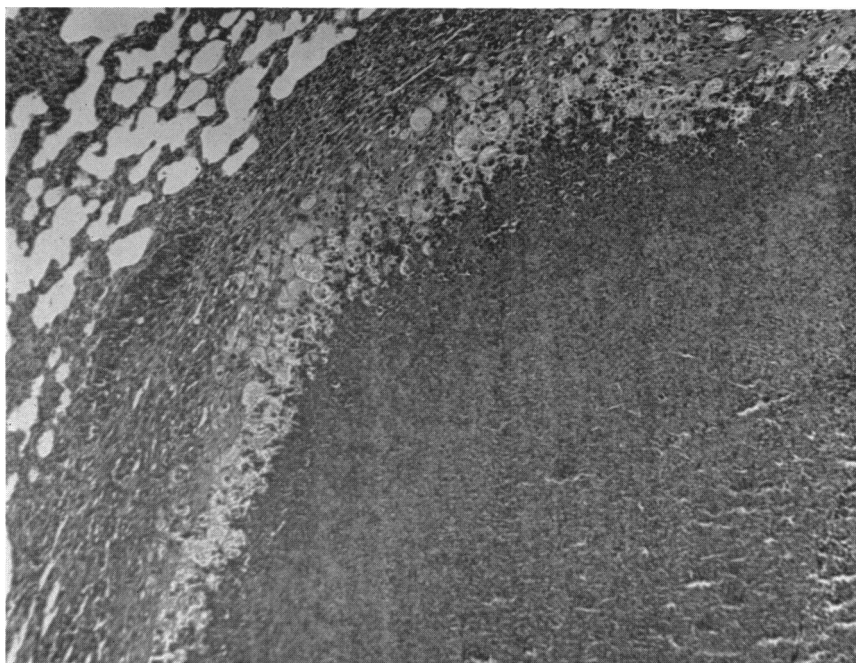


FIG. 7. Portion of a large abscess in the lung of a conventional mouse inoculated with *Mycoplasma pulmonis* (X 125). Hematoxylin and eosin stain.

portance and should be discussed in its proper perspective. The host specificity in the gnotobiotic Ha/ICR mouse is very marked, for not only did *M. salivarium*, a commensal organism present in the pharynx of approximately 50% of normal human subjects, fail to produce any measurable effect, but even *M. pneumoniae*, a pathogenic species of human origin which produces bronchitis and pneumonia (the "atypical pneumonia" associated with cold agglutinins) in man, failed to produce a single instance of illness or gross pneumonia. *M. pulmonis*, on the other hand, a pathogenic mycoplasma of mouse origin, produced illness and pneumonia in a high proportion of animals.

The conventional Ha/ICR mouse represents a different host for which *M. salivarium* and *M. pneumoniae* were distinctly more pathogenic than was sterile broth. It was not possible to distinguish the pathogenicity of the two species of human origin, *M. salivarium* and *M. pneumoniae* *inter se*, but both were less pathogenic than *M. pulmonis*. The results in the conventional animal are difficult to interpret. Synergistic action of *M. salivarium* or *M. pneumoniae* with indigenous murine mycoplasma in the conventional Ha/ICR stock and with indigenous bacteria could be an important factor. Gnotobiotic animals may be more, rather than less, resistant to inoculation with large numbers of a single microbial species introduced from the outside than conventional animals. It has been found difficult to establish certain single bacterial species in germ-free mice (6). The complete disappearance of *M. salivarium* from the lungs of all of the inoculated gnotobiotic mice by 2 weeks shows impressive ability of the mammalian organism to clear itself of certain foreign microbes.

The pathogenicity of *M. pulmonis* for the gnotobiotic Ha/ICR mouse was very striking. To the authors' knowledge, this is the first description of the use of the gnotobiotic mouse in pathogenicity studies involving intranasal inoculations of mycoplasma. Compared with the slower onset of disease in conventional mice described by Nelson (8) and Edward (5), the clinical course that we observed was more rapid. Sullivan and Dienes (10) also observed deaths within a few days after intranasal inoculation of a suspension of lungs with almost total pulmonary consolidation, but did not describe the histopathology of the acute stage. The difference in time course of the disease may be related to differences in the dose of organism or to the strain of mouse used.

The round-cell infiltration of the peribronchial space of the conventional animals would seem

to represent morphological evidence of an immune response in animals living in a normal environment to microbes which impinge upon the respiratory passageways. The absence of round-cell infiltration from the respiratory tract of the control gnotobiotic mice would seem to represent an equivalent to the conspicuous diminution or absence of round cell infiltration in the submucosal tissues of the gastrointestinal tract of gnotobiotics in the absence of viable microbes in the fecal stream.

Our observation on the absence of pulmonary neoplasms in gnotobiotics is of interest, because it does not confirm previous reports (Ward, Federation Proc., 20:150, 1961) that spontaneous tumors have an approximately equal incidence in gnotobiotic and conventional animals. The discrepancy in findings may be due to the fact that all of the mice in our study were 10 weeks of age or less.

#### ACKNOWLEDGMENTS

This investigation was supported by grants from The American Thoracic Society, Public Health Service general research support grant 5 SO1FR 5434, training grant 5T1 HE 5538, and Public Health Service grant AM4150-05 from the National Institute of Arthritis and Metabolic Diseases.

The technical assistance of Patricia Goggans is gratefully acknowledged. We also wish to acknowledge the help of the Staff of the Veterans Administration Biostatistics Research Support Center, Hines, Ill., in the statistical analysis.

#### LITERATURE CITED

1. CHANOCK, R. M., L. DIENES, M. D. EATON, D. G. FF. EDWARD, E. A. FREUNDT, L. HAYFLICK, J. F. PH. HERS, K. E. JENSEN, C. LIU, B. P. MARMION, H. E. MORTON, M. A. MUFSON, P. F. SMITH, N. L. SOMERSON, AND D. TAYLOR-ROBINSON. 1963. *Mycoplasma pneumoniae*: proposed nomenclature for atypical pneumonia organism (Eaton agent). *Science* 140:662.
2. CHANOCK, R. M., L. HAYFLICK, AND M. F. BARILE. 1962. Growth on artificial medium of an agent associated with atypical pneumonia and its identification as a PPLO. *Proc. Natl. Acad. Sci. U.S.* 48:41-49.
3. DAJANI, A. S., W. A. CLYDE, AND F. W. DENNY. 1965. Experimental infection with *Mycoplasma pneumoniae* (Eaton's agent). *J. Exptl. Med.* 121:1071-1086.
4. EATON, M. D., G. MEIKLEJOHN, AND W. VAN HERICK. 1944. Studies on the etiology of primary atypical pneumonia. A filterable agent transmissible to cotton rats, hamsters, and chick embryos. *J. Exptl. Med.* 79:649-668.
5. EDWARD, D. G. FF. 1940. The occurrence in

- normal mice of pleuropneumonia-like organisms capable of producing pneumonia. *J. Pathol. Bacteriol.* **50**:409-418.
6. GIBBONS, R. J., S. S. SOCRANSKY, AND B. KAP-SIMALIS. 1964. Establishment of human indigenous bacteria in germ-free mice. *J. Bacteriol.* **88**:1316-1323.
  7. GOODBURN, G., AND B. P. MARMION. 1962. A study of the properties of Eaton's primary atypical pneumonia organism. *J. Gen. Microbiol.* **29**:271-290.
  8. NELSON, J. B. 1937. Infectious catarrh of mice. *J. Exptl. Med.* **65**:833-860.
  9. NELSON, J. B. 1958. Infection in laboratory animals with pleuropneumonia-like organisms. *J. Natl. Cancer Inst.* **20**:911-915.
  10. SULLIVAN, E. R., AND L. DIENES. 1939. Pneumonia in white mice produced by a pleuropneumonia-like micro-organism. *Proc. Soc. Exptl. Biol. Med.* **41**:620-622.
  11. TULLY, J. G. 1965. Biochemical, morphological, and serological characterization of mycoplasma of murine origin. *J. Infect. Diseases* **115**:171-185.
  12. WAGNER, M. 1959. Determination of germ-free status. *Ann. N.Y. Acad. Sci.* **78**:89-100.