

**Marquette University**  
**e-Publications@Marquette**

---

Biomedical Engineering Faculty Research and  
Publications

Biomedical Engineering, Department of

---

1-1-2015

# Recent Developments in Osteogenesis Imperfecta

Joseph L. Shaker

*Medical College of Wisconsin*

Carolyne Albert

*Marquette University, carolyne.albert@marquette.edu*

Jessica M. Fritz

*Marquette University, jessica.fritz@marquette.edu*

Gerald F. Harris

*Marquette University, gerald.harris@marquette.edu*

---

Published version. *F1000Reserach*, (2015). DOI. © 2015 Shaker JL et al. Used with permission.



REVIEW

# Recent developments in osteogenesis imperfecta [version 1; referees: 3 approved]

Joseph L. Shaker<sup>1</sup>, Carolyne Albert<sup>2,3</sup>, Jessica Fritz<sup>2</sup>, Gerald Harris<sup>2,3</sup>

<sup>1</sup>Endocrinology, Medical College of Wisconsin, Milwaukee, WI, USA

<sup>2</sup>Orthopaedic and Rehabilitation Engineering Center, Marquette University and Medical College of Wisconsin, Milwaukee, WI, USA

<sup>3</sup>Shriners Hospitals for Children, Chicago, IL, USA

**v1** **First published:** 07 Sep 2015, 4(F1000 Faculty Rev):681 (doi: [10.12688/f1000research.6398.1](https://doi.org/10.12688/f1000research.6398.1))  
**Latest published:** 07 Sep 2015, 4(F1000 Faculty Rev):681 (doi: [10.12688/f1000research.6398.1](https://doi.org/10.12688/f1000research.6398.1))

**Abstract**

Osteogenesis imperfecta (OI) is an uncommon genetic bone disease associated with brittle bones and fractures in children and adults. Although OI is most commonly associated with mutations of the genes for type I collagen, many other genes (some associated with type I collagen processing) have now been identified. The genetics of OI and advances in our understanding of the biomechanical properties of OI bone are reviewed in this article. Treatment includes physiotherapy, fall prevention, and sometimes orthopedic procedures. In this brief review, we will also discuss current understanding of pharmacologic therapies for treatment of OI.



This article is included in the **F1000 Faculty Reviews** channel.

**Open Peer Review**

**Referee Status:**

	Invited Referees		
	1	2	3
<b>version 1</b> published 07 Sep 2015			

- 1 Malachi McKenna**, St. Vincent's University Hospital Ireland
- 2 Dhanwada Sudhaker Rao**, Henry Ford Hospital USA
- 3 Bart Clarke**, Mayo Clinic College of Medicine USA

**Discuss this article**

[Comments \(1\)](#)

**Corresponding author:** Joseph L. Shaker ([joseph.shaker@froedtert.com](mailto:joseph.shaker@froedtert.com))

**How to cite this article:** Shaker JL, Albert C, Fritz J and Harris G. **Recent developments in osteogenesis imperfecta [version 1; referees: 3 approved]** *F1000Research* 2015, 4(F1000 Faculty Rev):681 (doi: [10.12688/f1000research.6398.1](https://doi.org/10.12688/f1000research.6398.1))

**Copyright:** © 2015 Shaker JL *et al.* This is an open access article distributed under the terms of the [Creative Commons Attribution Licence](#), which permits unrestricted use, distribution, and reproduction in any medium, provided the original work is properly cited.

**Grant information:** The author(s) declared that no grants were involved in supporting this work.

**Competing interests:** JS is a consultant for Alexion Pharmaceuticals. The other authors declare that they have no competing interests.

**First published:** 07 Sep 2015, 4(F1000 Faculty Rev):681 (doi: [10.12688/f1000research.6398.1](https://doi.org/10.12688/f1000research.6398.1))

## Introduction

Osteogenesis imperfecta (OI) is an unusual heritable disease that occurs in about 1 in 10,000 to 20,000 live births<sup>1</sup>. The major clinical manifestation is skeletal fragility. Skeletal deformity, joint laxity, and scoliosis may be present<sup>2</sup>. Other extraskelatal manifestations include hearing loss, dentinogenesis imperfecta, blue/gray sclerae, hypercalciuria, aortic root dilatation, and neurologic conditions such as macrocephaly, hydrocephalus, and basilar invagination<sup>1-5</sup>. The phenotype is variable, ranging from osteoporosis presenting in adulthood to lethality in children<sup>3</sup>. Even adults with “mild” OI may have significant musculoskeletal symptoms, including arthritis, fractures, back pain, scoliosis, and tendon ruptures<sup>6</sup>.

About 90% of patients have mutations in type I collagen genes (*COL1A1* and *COL1A2*)<sup>3</sup>; however, many other genes have now been described. Some of the genes encode proteins related to type I collagen (for example, enzymes that modify type I collagen, chaperone proteins, and signaling proteins). In 1979, Sillence *et al.* proposed a classification system for OI with four types based on severity: type I mild non-deforming, type II perinatal lethal, type III severely deforming, and type IV moderately deforming<sup>7</sup>. This classification has been expanded as new genes were discovered. Phenotypic classification (types I to V with multiple genes

included in some of the types) has been proposed<sup>5</sup>. Alternatively, classification by genetics has been proposed (see [Table 1](#)), which was created through modifications of references<sup>8-10</sup>.

There have been recent advances in the understanding of the structure and mechanical properties of bone in children with OI. These advances may lead to improved finite element (FE) models that help predict fracture risk of specific activities and help plan physiotherapy.

In addition to physiotherapy and orthopedic surgery when needed, intravenous bisphosphonates have been used extensively in moderate to severe OI in childhood. Less is known about pharmacologic treatment in adults. Anabolic therapy with PTH 1-34 has been studied in adults with OI. Future therapies may include antibodies to sclerostin, transforming growth factor beta (TGFβ) antagonism, gene therapy, and cell-based therapies.

## Genes and classification

OI is most commonly caused by mutations in type I collagen. Type I collagen is a rod-like structure formed from a trimer of 2 *COL1A1* and 1 *COL1A2* subunits<sup>3</sup>, which requires post-translational modification. Many of the other rare forms of OI are due to defects in

**Table 1. Classification of osteogenesis imperfecta.**

Type	Inheritance	Gene	Protein	Defect	Phenotype
I	AD	<i>COL1A1/COLA2</i>	α1(1) collagen	Collagen quantity	Mild, non-deforming
II	AD	<i>COL1A1/COLA2</i>	α1(1)/α2(1) collagen	Collagen structure	Perinatal lethal
III	AD	<i>COL1A1/COLA2</i>	α1(1)/α2(1) collagen	Collagen structure	Progressively deforming
IV	AD	<i>COL1A1/COLA2</i>	α1(1)/α2(1) collagen	Collagen structure	Moderately deforming
V	AD	<i>IFITM5</i>	BRIL	Matrix mineralization	Moderate, distinct histology
VI	AR	<i>SERPINF1</i>	PEDF		Moderate to severe, distinct histology
VII	AR	<i>CRTAP</i>	CRTAP	Prolyl 3 hydroxylation	Severe to lethal
VIII	AR	<i>LEPRE1</i>	P3H1	Prolyl 3 hydroxylation	Severe to lethal
IX	AR	<i>PPIB</i>	CyPB	Prolyl 3 hydroxylation	Moderate to lethal
X	AR	<i>SERPINH1</i>	HSP47	Collagen chaperoning	Severe
XI	AR	<i>FKBP10</i>	FKBP65	Telopeptide hydroxylation	Progressively deforming (Bruck syndrome)
XII	AR	<i>SP7</i>	SP7/osterix	Osteoblast development	Moderate
XIII	AR	<i>BMP1</i>	BMP1/mTLD	Collagen processing	Severe, high bone mass
XIV	AR	<i>TMEM38B</i>	TRIC-B	Cation channel defect	Moderate to severe
XV	AR	<i>WNT1</i>	WNT1		Variable
XV	AD	<i>WNT1</i>	WNT1		Early-onset osteoporosis
Others					
	AR	<i>CREB3L1</i>	Oasis	COL1A1 transcription	Progressively deforming
	XL	<i>PLS3</i>	Plastin	Osteocyte defect	Mild
	AR	<i>PLOD2</i>	Lysyl hydroxylase 2	Collagen telopeptide hydroxylation	Progressively deforming

AD, autosomal dominant; AR, autosomal recessive; XL, x-linked.

proteins involved in cross-linking, hydroxylation, and mineralization of type I collagen.

Mutations of *CRTAP*, which encodes cartilage-associated protein, have been shown to cause recessive OI<sup>11–14</sup>. Mutations of *LEPRE1*, which encodes prolyl 3 hydroxylase<sup>14–16</sup>, and *PPIB* (protein cyclophilin B)<sup>17–19</sup> also cause recessive OI. The proteins described above form a complex that modifies specific prolines in the collagen and these mutations result in moderate to lethal OI.

*SERPINH1* mutations cause severe recessive OI<sup>20</sup>. The protein affected in *SERPINH1* mutations, HSP47, is a collagen chaperone protein<sup>8</sup>. *FKBP10* mutations cause recessive OI (progressively deforming)<sup>21</sup>. This gene encodes the protein FKBP65, which appears to be needed for hydroxylation of collagen telopeptide lysine<sup>22</sup>. Both HSP47 and FKBP65 are needed for the proper folding of the collagen triple helix. Furthermore, Bruck syndrome (OI and congenital contractures) can be caused by homozygous mutations on FKBP10<sup>23</sup>, and Kuskokwim syndrome (congenital contractures with mild skeletal problems seen in Yup'ik people in Alaska) is caused by *FKBP10* mutations<sup>24</sup>. *PLOD2* mutations also cause recessive OI<sup>25</sup>. *PLOD-2* encodes lysyl hydroxylase 2, which hydroxylates collagen telopeptide lysine. Bruck syndrome can also be caused by homozygous mutations of *PLOD2*<sup>25</sup>.

*BMP1* (bone morphogenetic protein 1) mutations also cause recessive OI<sup>26,27</sup>. The protein, BMP1, is a protease that cleaves the c-propeptide of type I collagen<sup>26,27</sup> but also has other substrates. *SP7* mutations cause recessive OI<sup>28</sup>. *SP7* encodes the protein osterix, which may be needed for osteoblast differentiation<sup>10</sup>. *WNT1* mutations<sup>29–31</sup> have been reported in early-onset osteoporosis (dominant) and OI (recessive). The protein, WNT1, may be important in the beta catenin system, which stimulates bone formation<sup>29–31</sup>.

*TMEM38B* mutations have been reported in recessive OI<sup>32</sup>. This gene encodes TRIC-B, which may be important in intracellular calcium signaling. Defective TRIC-B may cause bone disease through defective calcium signaling in bone cells<sup>10</sup>. *CREB3L1* mutations cause recessive OI<sup>33</sup>. *CREB3L1* encodes the protein OASIS, which may activate transcription of *COL1A1*<sup>34</sup>. *PLS3* (plastin 3) mutations have been reported in x-linked osteoporosis<sup>35–37</sup>. Plastin 3 is expressed in osteocyte dendrites and may be important in mechanosensing<sup>35</sup>. Bone biopsies from patients with *PLS3* mutations have shown cortical and trabecular osteoporosis with normal to low bone formation rates<sup>36,37</sup>. There is no mineralization defect<sup>36,37</sup>.

Mutations in *IFITM5*, a bone-restricted IFITM-like protein (BRIL) (dominant) cause type V OI<sup>38–42</sup>. These patients have prominent callus formation and ossification of the forearm interosseous membrane<sup>38–42</sup>. They also have mesh-like lamellation on bone biopsy as well as a mineralization defect<sup>38–42</sup>. There appear to be substantial differences in phenotypic presentation even with similar mutations<sup>40–42</sup>. Type VI OI is caused by mutations in *SERPINF1* (protein PEDF)<sup>43,44</sup>. Children with type VI OI have elevated alkaline phosphatase, and bone biopsy reveals fish-scale pattern under polarized light as well as broad bands of unmineralized osteoid<sup>43,44</sup>. Interestingly, some patients with BRIL mutations have phenotypic type VI

OI (rather than type V)<sup>45</sup>. BRIL and PEDF are related, and it appears that mutations causing gain-of-function of BRIL cause OI type V and that those causing loss-of-function of BRIL look phenotypically like OI type VI<sup>46</sup>.

## Structure and mechanical properties of bones in osteogenesis imperfecta

From a mechanical perspective, increased fracture risk in individuals with OI could stem from a combination of reduced bone mass, decreased bone material quality, and, in some individuals, the presence of bone deformity.

### Bone mass

Low bone mass is a clinical characteristic of OI, and individuals with this disorder tend to have markedly reduced areal bone mineral density (BMD)<sup>47–49</sup>. This reduced bone mass can be the consequence of decreased bone size or decreased volumetric BMD or both<sup>49,50</sup>. Studies of iliac crest biopsies have revealed lower bone tissue quantity in children with moderate and severe OI, including reduced bone volume fraction, and decreased trabecular and cortical thicknesses<sup>51–53</sup>. Decreased bone volume, though less marked, was also noted in some children with mild OI<sup>51,52</sup>.

In cortical bone specimens from the long bone shafts of children with OI, “atypical, flattened, and large resorption lacunae”<sup>54</sup> and abnormally elevated porosity have been observed<sup>54–57</sup>. For example, an average intracortical vascular porosity of 21% was found in bone shaft osteotomies from children with OI by synchrotron radiation micro-computed tomography<sup>55,57</sup>; the corresponding value in normal pediatric bones was 3%<sup>57</sup>. From a structural perspective, reduced bone mass can lead to increased stresses within the bone as a result of a smaller area of bone tissue present to support physiological loads. For this reason, low bone mass is likely a considerable contributor to bone fragility in OI.

### Bone material quality

In addition to the structural deficiency (low bone mass), mechanical quality of the bone material in OI is reduced. The genetic defects causing OI affect type I collagen, the main organic component of bone. As discussed earlier, most forms of OI (types I to IV) are attributed to insufficient collagen production or amino acid substitution defects within the collagen molecules or both<sup>58–63</sup>, and less common recessive forms have been associated with abnormalities in other proteins that interact with type I collagen<sup>9,64</sup>. Since type I collagen is an integral component of bone tissues, it should be no surprise that abnormalities affecting this protein would impact bone material quality. At the ultrastructural level, irregularities in collagen and mineral geometry as well as abnormalities in mineral composition have been reported<sup>65–70</sup>. Studies in mice indicated that the material abnormalities in OI have a negative impact on bone material properties<sup>71–76</sup>. A few studies have also used biopsy and osteotomy specimens to measure bone material properties in humans with this disorder. Some of these studies used nanoindentation, a technique in which a diamond-tip indenter is pressed into the polished surface of a material (in this case, bone), creating an indent a few microns in size. With this test, elastic modulus and hardness—that is, properties representing the material’s resistance to elastic (recoverable)

and plastic (non-recoverable) deformation, respectively—are determined at the submicrostructural level. Based on nanoindentation, slightly higher elastic modulus and hardness were found in children with mild (type I) versus severe (type III) OI<sup>77</sup>, whereas these properties were not found to differ between children with severe (type III) versus moderately severe (type IV) phenotypes<sup>78</sup>. However, exactly how these properties compare with normal tissues remains unclear; one study reported higher elastic modulus and hardness in children with severe OI versus controls<sup>79</sup>, whereas another reported the opposite<sup>80</sup>. Furthermore, bone tissues have a complex hierarchical structure, which results in properties that differ between length scales, and nanoindentation provides only limited insight regarding bone tissue properties at the submicrostructural scale. Another limitation with this technique is that it does not measure strength, a property representing the ability of a material to carry stress without breaking or sustaining damage.

Recent studies have measured cortical bone material properties, including strength, at a larger scale by using surgical bone specimens from long bone diaphyses of children with OI<sup>55,56,81</sup>. In these studies, small osteotomy specimens were machined into parallelepiped-shaped specimens and loaded to failure in either bending<sup>55,81</sup> or compression<sup>56</sup>. Bone material strength was confirmed to be lower than normal in these children, and this property was found to be negatively related to an abnormally elevated intracortical porosity. These findings suggest that increased cortical porosity contributes to increased risk of long bone fractures in OI.

### Bone deformity

In addition to decreased bone mass and reduced bone material quality (low bone material strength), deformities of the spine and long bones are common in OI. For example, children with severe OI often exhibit anterolateral bowing of the femur and anterior bowing of the tibia<sup>7,47</sup>. Increased curvature in long bones leads to an increase in maximum stresses within the bone shaft<sup>82</sup>. The increased stresses attributed to bone deformities in OI can further contribute to the risk of bone fracture.

### Fracture prediction based on mechanical models

Mechanical modeling through the use of FE analysis is a well-established technique that allows detailed analysis of composite structures under a variety of load conditions. In the field of orthopedic biomechanics, FE modeling is frequently used to examine the responses of bone to loading<sup>83–86</sup>. Patient-specific FE models have been effective for bone strain and fracture strength assessment, and as recently as 2009 Fritz *et al.* applied these models to predict fractures in OI<sup>87,88</sup>. A femoral model including muscle forces was analyzed during all seven phases of the gait cycle and geometrically matched to bone anatomy with x-rays. The most current work includes advanced meshing techniques for improved geometric biofidelity and updated mechanical property data<sup>55</sup>. Other FE models for assessing OI bones have also been reported. Orwoll *et al.* used FE modeling to estimate vertebral strength in a study of the effects of teriparatide treatment in adults with OI<sup>89</sup>. Caouette *et al.* developed an FE model to assess fracture risk at the tibia in children with OI<sup>90</sup>. This tibia model examined fracture risk during

two-legged hopping, lateral loading, and torsional loading. Future applications of FE modeling may prove invaluable for better quantification of fracture risk in OI. These models could help identify activities that pose greater risk of fracture and, through appropriate controls, may enable persons with OI to participate safely and more fully in a greater spectrum of daily and recreational activities.

## Management

### Physical therapy

The goals of the treatment in OI are to decrease pain and fractures and to maximize mobility. Physical therapy/rehabilitation<sup>91</sup> is particularly important in children to improve weight bearing and prevent fractures as well as to increase strength and mobility during fracture recovery. Some children may require wheelchairs or walking aids. Occupational therapy may be needed to help with daily living activities.

### Pharmacologic therapy

#### Bisphosphonates

Bisphosphonates (BPs) are non-hydrolysable synthetic analogs of pyrophosphate<sup>92</sup>. BPs adhere to mineralized surfaces, inhibit osteoclastic bone resorption, and have very long skeletal half-lives<sup>92</sup>. Intravenous BPs are currently the primary treatment of children with moderate to severe OI. BPs increase BMD and size in children with OI<sup>49</sup>. BPs do not appear to impair bone formation that increases cortical width in children with OI<sup>93</sup>. Observational studies suggest decreased fractures<sup>94,95</sup>, decreased bone pain, and improved vertebral shape<sup>94,95</sup>. Ability to perform activities of daily living may also be improved. However, it has been difficult to confirm all of these benefits in randomized trials, and the optimal duration of BP treatment is unknown.

In a study of children with predominantly mild OI, oral risedronate increased BMD and appeared to decrease clinical fractures<sup>96</sup>. Atypical fractures have been reported in children with OI treated with bisphosphonates<sup>97,98</sup>; however, osteonecrosis of the jaw does not appear to be a major problem in children with OI treated with BPs<sup>99–101</sup>. Several studies have been done on the use of intravenous or oral BPs in adults with OI. Although BMD increases have been reported during these treatments, fracture data are equivocal<sup>102–106</sup>. A Cochrane review found increased BMD in patients with OI treated with BPs but did not find definitive evidence of fracture reduction<sup>107</sup>. Furthermore, a recent meta-analysis of placebo-controlled trials suggested that the effects of BPs for fracture prevention in OI were inconclusive<sup>108</sup>.

#### Growth hormone

Growth hormone has anabolic effects on bone. A 1-year randomized trial of the BP, neridronate, with or without growth hormone showed greater increase in BMD and growth velocity with growth hormone, but there was no fracture benefit of growth hormone<sup>109</sup>.

#### Teriparatide

Teriparatide (PTH1-34) is an anabolic agent that stimulates bone formation (and ultimately bone resorption). This drug decreases vertebral and non-vertebral fractures in post-menopausal women



with osteoporosis<sup>110</sup>. Observational data in adults with OI suggest increased BMD with teriparatide<sup>107,111</sup>. Recently, a randomized trial of teriparatide in adults with OI showed increased BMD as well as increased vertebral strength estimated by FE analysis<sup>91</sup>. The benefits appeared to occur in mild (type I) OI but not in more severe OI (types III and IV).

### Denosumab

Denosumab is a monoclonal antibody to receptor activator of nuclear factor kappa B ligand that decreases bone resorption, increases bone density, and reduces fractures in women with postmenopausal osteoporosis<sup>112</sup>. This drug may represent a future therapy in OI. In a study of four children with type VI OI, increased BMD and mobility and improved vertebral shape were reported after denosumab treatment, and the outcomes of this study indicated that this treatment appears to be safe<sup>113</sup>. There is also a report of denosumab use in two children with OI caused by COL1A1/A2 mutations<sup>114</sup>. As with BPs, “zebra lines” were present, suggesting continued longitudinal growth<sup>114</sup>. Denosumab has been reported to cause hypophosphatemia, hypocalcemia, and secondary hyperparathyroidism in a child with fibrous dysplasia of bone<sup>115</sup>. There was rebound hypercalcemia after stopping denosumab<sup>115</sup>.

### Possible future therapies

Sclerostin is an inhibitor of the LRP5/Wnt system that decreases bone formation. Antibodies to sclerostin are in clinical trials for treatment of osteoporosis with the goal to increase bone density<sup>116</sup>. Sclerostin antibody appeared to be effective in a mouse model of moderately severe OI<sup>117,118</sup> but less so in a mouse model of more severe OI<sup>119</sup>. TGF $\beta$  is secreted by osteoblasts and increases osteoclastic bone resorption<sup>120</sup>. Excessive TGF $\beta$  signaling may be important in some forms of OI, and anti-TGF $\beta$  therapy represents an interesting prospect for the future treatment of OI<sup>120</sup>.

Cell-based therapy, such as bone marrow<sup>121</sup> or mesenchymal stem cell<sup>122–124</sup> transplantation, has also been investigated and may have promise; but these could also have significant risks. Gene therapy with allele-specific silencing may represent a future therapy<sup>125</sup>.

### Summary

Although most cases of OI are caused by COL1A1/A2 mutations, many new genetic causes have been identified in recent years. Some of these genes are related to the processing of type I collagen. Furthermore, we have greater understanding of the biomechanics of OI bone, including material properties, muscle and gait load effects, and fracture strength assessment. Biomechanical models could help identify activities that pose greater risk of fracture and, through appropriate controls, may enable persons with OI to participate safely and more fully in a greater spectrum of activities. Physical therapy is an important part of the management of these patients. Intravenous BPs are commonly used in children with moderate to severe OI. Some of the benefits seen in observational studies have been hard to prove in controlled studies. Treatment of adults with OI is less well studied. BPs and teriparatide appear to increase BMD, but fracture data are lacking. Teriparatide appears to increase bone strength as estimated by FE analysis in adults with mild OI. Other promising treatments for OI are under investigation.



### Competing interests

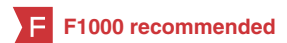JS is a consultant for Alexion Pharmaceuticals. The other authors declare that they have no competing interests.

### Grant information

The author(s) declared that no grants were involved in supporting this work.

### References

- Monti E, Mottes M, Fraschini P, *et al.*: **Current and emerging treatments for the management of osteogenesis imperfecta.** *Ther Clin Risk Manag.* 2010; **6**: 367–81.  
[PubMed Abstract](#) | [Publisher Full Text](#) | [Free Full Text](#)
- Arponen H, Mäkitie O, Waltimo-Sirén J: **Association between joint hypermobility, scoliosis, and cranial base anomalies in paediatric Osteogenesis imperfecta patients: a retrospective cross-sectional study.** *BMC Musculoskelet Disord.* 2014; **15**: 428.  
[PubMed Abstract](#) | [Publisher Full Text](#) | [Free Full Text](#)
- Lindahl K, Langdahl B, Ljunggren Ö, *et al.*: **Treatment of osteogenesis imperfecta in adults.** *Eur J Endocrinol.* 2014; **171**(2): R79–90.  
[PubMed Abstract](#) | [Publisher Full Text](#)
- Lamanna A, Fayers T, Clarke S, *et al.*: **Valvular and aortic diseases in osteogenesis imperfecta.** *Heart Lung Circ.* 2013; **22**(10): 801–10.  
[PubMed Abstract](#) | [Publisher Full Text](#)
- Biggin A, Munns CF: **Osteogenesis imperfecta: diagnosis and treatment.** *Curr Osteoporos Rep.* 2014; **12**(3): 279–88.  
[PubMed Abstract](#) | [Publisher Full Text](#)
- McKiernan FE: **Musculoskeletal manifestations of mild osteogenesis imperfecta in the adult.** *Osteoporos Int.* 2005; **16**(12): 1698–702.  
[PubMed Abstract](#) | [Publisher Full Text](#)
- Sillence DO, Senn A, Danks DM: **Genetic heterogeneity in osteogenesis imperfecta.** *J Med Genet.* 1979; **16**(2): 101–16.  
[PubMed Abstract](#) | [Publisher Full Text](#) | [Free Full Text](#)
- Valadares ER, Carneiro TB, Santos PM, *et al.*: **What is new in genetics and osteogenesis imperfecta classification?** *J Pediatr (Rio J).* 2014; **90**(6): 536–41.  
[PubMed Abstract](#) | [Publisher Full Text](#)
- Forlino A, Cabral WA, Barnes AM, *et al.*: **New perspectives on osteogenesis imperfecta.** *Nat Rev Endocrinol.* 2011; **7**(9): 540–57.  
[PubMed Abstract](#) | [Publisher Full Text](#) | [Free Full Text](#)
- Marini JC, Reich A, Smith SM: **Osteogenesis imperfecta due to mutations in non-collagenous genes: lessons in the biology of bone formation.** *Curr Opin Pediatr.* 2014; **26**(4): 500–7.  
[PubMed Abstract](#) | [Publisher Full Text](#) | [Free Full Text](#)
-  Barnes AM, Chang W, Morello R, *et al.*: **Deficiency of cartilage-associated protein in recessive lethal osteogenesis imperfecta.** *N Engl J Med.* 2006; **355**(26): 2757–64.  
[PubMed Abstract](#) | [Publisher Full Text](#) | [F1000 Recommendation](#)
-  Morello R, Bertin TK, Chen Y, *et al.*: **CRTAP is required for prolyl 3- hydroxylation and mutations cause recessive osteogenesis imperfecta.** *Cell.* 2006; **127**(2): 291–304.  
[PubMed Abstract](#) | [Publisher Full Text](#) | [F1000 Recommendation](#)
- Baldrige D, Schwarze U, Morello R, *et al.*: **CRTAP and LEPRE1 mutations in recessive osteogenesis imperfecta.** *Hum Mutat.* 2008; **29**(12): 1435–42.  
[PubMed Abstract](#) | [Publisher Full Text](#) | [Free Full Text](#)
- Marini JC, Cabral WA, Barnes AM: **Null mutations in LEPRE1 and CRTAP cause severe recessive osteogenesis imperfecta.** *Cell Tissue Res.* 2010; **339**(1): 59–70.  
[PubMed Abstract](#) | [Publisher Full Text](#) | [Free Full Text](#)



15. Pepin MG, Schwarze U, Singh V, *et al.*: **Allelic background of *LEPRE1* mutations that cause recessive forms of osteogenesis imperfecta in different populations.** *Mol Genet Genomic Med.* 2013; 1(4): 194–205.  
[PubMed Abstract](#) | [Publisher Full Text](#) | [Free Full Text](#)
16. Cabral WA, Chang W, Barnes AM, *et al.*: **Prolyl 3-hydroxylase 1 deficiency causes a recessive metabolic bone disorder resembling lethal/severe osteogenesis imperfecta.** *Nat Genet.* 2007; 39(3): 359–65.  
[PubMed Abstract](#) | [Publisher Full Text](#) | [F1000 Recommendation](#)
17. van Dijk FS, Nesbitt IM, Zwikstra EH, *et al.*: ***PP1B* mutations cause severe osteogenesis imperfecta.** *Am J Hum Genet.* 2009; 85(4): 521–7.  
[PubMed Abstract](#) | [Publisher Full Text](#) | [Free Full Text](#)
18. Barnes AM, Carter EM, Cabral WA, *et al.*: **Lack of cyclophilin B in osteogenesis imperfecta with normal collagen folding.** *N Engl J Med.* 2010; 362(6): 521–8.  
[PubMed Abstract](#) | [Publisher Full Text](#) | [Free Full Text](#)
19. Pyott SM, Schwarze U, Christiansen HE, *et al.*: **Mutations in *PP1B* (cyclophilin B) delay type I procollagen chain association and result in perinatal lethal to moderate osteogenesis imperfecta phenotypes.** *Hum Mol Genet.* 2011; 20(8): 1595–609.  
[PubMed Abstract](#) | [Publisher Full Text](#) | [Free Full Text](#)
20. Christiansen HE, Schwarze U, Pyott SM, *et al.*: **Homozygosity for a missense mutation in *SERP1NH1*, which encodes the collagen chaperone protein HSP47, results in severe recessive osteogenesis imperfecta.** *Am J Hum Genet.* 2010; 86(3): 389–98.  
[PubMed Abstract](#) | [Publisher Full Text](#) | [Free Full Text](#) | [F1000 Recommendation](#)
21. Alanay Y, Avaygan H, Camacho N, *et al.*: **Mutations in the gene encoding the RER protein *FKBP65* cause autosomal-recessive osteogenesis imperfecta.** *Am J Hum Genet.* 2010; 86(4): 551–9.  
[PubMed Abstract](#) | [Publisher Full Text](#) | [Free Full Text](#) | [F1000 Recommendation](#)
22. Barnes AM, Cabral WA, Weis M, *et al.*: **Absence of *FKBP10* in recessive type XI osteogenesis imperfecta leads to diminished collagen cross-linking and reduced collagen deposition in extracellular matrix.** *Hum Mutat.* 2012; 33(11): 1589–98.  
[PubMed Abstract](#) | [Publisher Full Text](#) | [Free Full Text](#)
23. Kelley BP, Malfait F, Bonafe L, *et al.*: **Mutations in *FKBP10* cause recessive osteogenesis imperfecta and Bruck syndrome.** *J Bone Miner Res.* 2011; 26(3): 666–72.  
[PubMed Abstract](#) | [Publisher Full Text](#) | [Free Full Text](#)
24. Barnes AM, Duncan G, Weis M, *et al.*: **Kuskokwim syndrome, a recessive congenital contracture disorder, extends the phenotype of *FKBP10* mutations.** *Hum Mutat.* 2013; 34(9): 1279–88.  
[PubMed Abstract](#) | [Publisher Full Text](#) | [Free Full Text](#)
25. Puig-Hervás MT, Temtamy S, Aglan M, *et al.*: **Mutations in *PLOD2* cause autosomal-recessive connective tissue disorders within the Bruck syndrome–osteogenesis imperfecta phenotypic spectrum.** *Hum Mutat.* 2012; 33(10): 1444–9.  
[PubMed Abstract](#) | [Publisher Full Text](#)
26. Martínez-Glez V, Valencia M, Caparrós-Martín JA, *et al.*: **Identification of a mutation causing deficient *BMP1*/mTLD proteolytic activity in autosomal recessive osteogenesis imperfecta.** *Hum Mutat.* 2012; 33(2): 343–50.  
[PubMed Abstract](#) | [Publisher Full Text](#) | [Free Full Text](#) | [F1000 Recommendation](#)
27. Valencia M, Caparrós-Martín JA, Sierrol-Piquer MS, *et al.*: **Report of a newly identified patient with mutations in *BMP1* and underlying pathogenetic aspects.** *Am J Med Genet A.* 2014; 164A(5): 1143–50.  
[PubMed Abstract](#) | [Publisher Full Text](#)
28. Lapunzina P, Aglan M, Temtamy S, *et al.*: **Identification of a frameshift mutation in *Osterix* in a patient with recessive osteogenesis imperfecta.** *Am J Hum Genet.* 2010; 87(1): 110–4.  
[PubMed Abstract](#) | [Publisher Full Text](#) | [Free Full Text](#) | [F1000 Recommendation](#)
29. Keupp K, Beleggia F, Kayserili H, *et al.*: **Mutations in *WNT1* cause different forms of bone fragility.** *Am J Hum Genet.* 2013; 92(4): 565–74.  
[PubMed Abstract](#) | [Publisher Full Text](#) | [Free Full Text](#) | [F1000 Recommendation](#)
30. Pyott SM, Tran TT, Leistriz DF, *et al.*: ***WNT1* mutations in families affected by moderately severe and progressive recessive osteogenesis imperfecta.** *Am J Hum Genet.* 2013; 92(4): 590–7.  
[PubMed Abstract](#) | [Publisher Full Text](#) | [Free Full Text](#) | [F1000 Recommendation](#)
31. Laine CM, Joeng KS, Campeau PM, *et al.*: ***WNT1* mutations in early-onset osteoporosis and osteogenesis imperfecta.** *N Engl J Med.* 2013; 368(19): 1809–16.  
[PubMed Abstract](#) | [Publisher Full Text](#) | [Free Full Text](#) | [F1000 Recommendation](#)
32. Shaheen R, Alazami AM, Alshammari MJ, *et al.*: **Study of autosomal recessive osteogenesis imperfecta in Arabia reveals a novel locus defined by *TMEM38B* mutation.** *J Med Genet.* 2012; 49(10): 630–5.  
[PubMed Abstract](#) | [Publisher Full Text](#) | [F1000 Recommendation](#)
33. Symoens S, Malfait F, D'hondt S, *et al.*: **Deficiency for the ER-stress transducer OASIS causes severe recessive osteogenesis imperfecta in humans.** *Orphanet J Rare Dis.* 2013; 8: 154.  
[PubMed Abstract](#) | [Publisher Full Text](#) | [Free Full Text](#)
34. Murakami T, Saito A, Hino S, *et al.*: **Signalling mediated by the endoplasmic reticulum stress transducer OASIS is involved in bone formation.** *Nat cell biol.* 2009; 11(10): 1205–11.  
[PubMed Abstract](#) | [Publisher Full Text](#) | [F1000 Recommendation](#)
35. van Dijk FS, Zillikens MC, Micha D, *et al.*: ***PLS3* mutations in X-linked osteoporosis with fractures.** *N Engl J Med.* 2013; 369(16): 1529–36.  
[PubMed Abstract](#) | [Publisher Full Text](#) | [F1000 Recommendation](#)
36. Fahiminiya S, Majewski J, Al-Jallad H, *et al.*: **Osteoporosis caused by mutations in *PLS3*: clinical and bone tissue characteristics.** *J Bone Miner Res.* 2014; 29(8): 1805–14.  
[PubMed Abstract](#) | [Publisher Full Text](#)
37. Laine CM, Wessman M, Toivainen-Salo S, *et al.*: **A novel splice mutation in *PLS3* causes X-linked early onset low-turnover osteoporosis.** *J Bone Miner Res.* 2015; 30(3): 510–8.  
[PubMed Abstract](#) | [Publisher Full Text](#)
38. Cho TJ, Lee KE, Lee SK: **A single recurrent mutation in the 5'-UTR of *IFITM5* causes osteogenesis imperfecta type V.** *Am J Hum Genet.* 2012; 91(2): 343–8.  
[PubMed Abstract](#) | [Publisher Full Text](#) | [Free Full Text](#) | [F1000 Recommendation](#)
39. Semler O, Garbes L, Keupp K, *et al.*: **A mutation in the 5'-UTR of *IFITM5* creates an in-frame start codon and causes autosomal-dominant osteogenesis imperfecta type V with hyperplastic callus.** *Am J Hum Genet.* 2012; 91(2): 349–57.  
[PubMed Abstract](#) | [Publisher Full Text](#) | [Free Full Text](#) | [F1000 Recommendation](#)
40. Grover M, Campeau PM, Lietman CD, *et al.*: **Osteogenesis imperfecta without features of type V caused by a mutation in the *IFITM5* gene.** *J Bone Miner Res.* 2013; 28(11): 2333–7.  
[PubMed Abstract](#) | [Publisher Full Text](#) | [Free Full Text](#)
41. Shapiro JR, Lietman C, Grover M, *et al.*: **Phenotypic variability of osteogenesis imperfecta type V caused by an *IFITM5* mutation.** *J Bone Miner Res.* 2013; 28(7): 1523–30.  
[PubMed Abstract](#) | [Publisher Full Text](#) | [Free Full Text](#) | [F1000 Recommendation](#)
42. Rauch F, Moffatt P, Cheung M, *et al.*: **Osteogenesis imperfecta type V: marked phenotypic variability despite the presence of the *IFITM5* c.-14C>T mutation in all patients.** *J Med Genet.* 2013; 50(1): 21–4.  
[PubMed Abstract](#) | [Publisher Full Text](#) | [F1000 Recommendation](#)
43. Becker J, Semler O, Gilissen C, *et al.*: **Exome sequencing identifies truncating mutations in human *SERPINF1* in autosomal-recessive osteogenesis imperfecta.** *Am J Hum Genet.* 2011; 88(3): 362–71.  
[PubMed Abstract](#) | [Publisher Full Text](#) | [Free Full Text](#) | [F1000 Recommendation](#)
44. Homan EP, Rauch F, Grate I, *et al.*: **Mutations in *SERPINF1* cause osteogenesis imperfecta type VI.** *J Bone Miner Res.* 2011; 26(12): 2798–803.  
[PubMed Abstract](#) | [Publisher Full Text](#) | [Free Full Text](#)
45. Guillén-Navarro E, Ballesta-Martínez MJ, Valencia M, *et al.*: **Two mutations in *IFITM5* causing distinct forms of osteogenesis imperfecta.** *Am J Med Genet A.* 2014; 164A(5): 1136–42.  
[PubMed Abstract](#) | [Publisher Full Text](#) | [F1000 Recommendation](#)
46. Farber CR, Reich A, Barnes AM, *et al.*: **A novel *IFITM5* mutation in severe atypical osteogenesis imperfecta type VI impairs osteoblast production of pigment epithelium-derived factor.** *J Bone Miner Res.* 2014; 29(6): 1402–11.  
[PubMed Abstract](#) | [Publisher Full Text](#) | [Free Full Text](#) | [F1000 Recommendation](#)
47. Renaud A, Accourt J, Weill J, *et al.*: **Radiographic features of osteogenesis imperfecta.** *Insights imaging.* 2013; 4(4): 417–29.  
[PubMed Abstract](#) | [Publisher Full Text](#) | [Free Full Text](#)
48. Kusumi K, Ayoob R, Bowden SA, *et al.*: **Beneficial effects of intravenous pamidronate treatment in children with osteogenesis imperfecta under 24 months of age.** *J Bone Miner Metab.* 2014.  
[PubMed Abstract](#) | [Publisher Full Text](#)
49. Rauch F, Plotkin H, Zeitlin L, *et al.*: **Bone mass, size, and density in children and adolescents with osteogenesis imperfecta: effect of intravenous pamidronate therapy.** *J Bone Miner Res.* 2003; 18(4): 610–4.  
[PubMed Abstract](#) | [Publisher Full Text](#)
50. Rauch F, Tuttlewski B, Schönau E, *et al.*: **The bone behind a low areal bone mineral density: peripheral quantitative computed tomographic analysis in a woman with osteogenesis imperfecta.** *J Musculoskelet Neuronal Interact.* 2002; 2(4): 306–8.  
[PubMed Abstract](#)
51. Jones SJ, Glorieux FH, Travers R, *et al.*: **The microscopic structure of bone in normal children and patients with osteogenesis imperfecta: a survey using backscattered electron imaging.** *Calcif Tissue Int.* 1999; 64(1): 8–17.  
[PubMed Abstract](#) | [Publisher Full Text](#)
52. Rauch F, Travers R, Parfitt AM, *et al.*: **Static and dynamic bone histomorphometry in children with osteogenesis imperfecta.** *Bone.* 2000; 26(6): 581–9.  
[PubMed Abstract](#) | [Publisher Full Text](#)
53. Roschger P, Fratzl-Zelman N, Misof BM, *et al.*: **Evidence that abnormal high bone mineralization in growing children with osteogenesis imperfecta is not associated with specific collagen mutations.** *Calcif Tissue Int.* 2008; 82(4): 263–70.  
[PubMed Abstract](#) | [Publisher Full Text](#)
54. Pazzaglia UE, Congiu T, Brunelli PC, *et al.*: **The long bone deformity of osteogenesis imperfecta III: analysis of structural changes carried out with scanning electron microscopic morphometry.** *Calcif Tissue Int.* 2013; 93(5): 453–61.  
[PubMed Abstract](#) | [Publisher Full Text](#)

55. Albert C, Jameson J, Smith P, *et al.*: **Reduced diaphyseal strength associated with high intracortical vascular porosity within long bones of children with osteogenesis imperfecta.** *Bone.* 2014; **66**: 121–30.  
[PubMed Abstract](#) | [Publisher Full Text](#) | [Free Full Text](#)
56. Vardakastani V, Saletti D, Skalli W, *et al.*: **Increased intra-cortical porosity reduces bone stiffness and strength in pediatric patients with osteogenesis imperfecta.** *Bone.* 2014; **69**: 61–7.  
[PubMed Abstract](#) | [Publisher Full Text](#)
57. Jameson JR, Albert CI, Busse B, *et al.*: **3D micron-scale imaging of the cortical bone canal network in human osteogenesis imperfecta (OI).** In *Proceedings of SPIE, Medical Imaging 2013: Biomedical Applications in Molecular, Structural, and Functional Imaging.* JB Weaver and RC Molthen, Editors. 2013, International Society for Optics and Photonics: Lake Buena Vista, FL. 2013; **8672**.  
[Publisher Full Text](#)
58. Wenstrup RJ, Willing MC, Starman BJ, *et al.*: **Distinct biochemical phenotypes predict clinical severity in nonlethal variants of osteogenesis imperfecta.** *Am J Hum Genet.* 1990; **46**(5): 975–82.  
[PubMed Abstract](#) | [Free Full Text](#)
59. Byers PH, Wallis GA, Willing MC: **Osteogenesis imperfecta: translation of mutation to phenotype.** *J Med Genet.* 1991; **28**(7): 433–42.  
[PubMed Abstract](#) | [Publisher Full Text](#) | [Free Full Text](#)
60. Marini JC, Forlino A, Cabral WA, *et al.*: **Consortium for osteogenesis imperfecta mutations in the helical domain of type I collagen: regions rich in lethal mutations align with collagen binding sites for integrins and proteoglycans.** *Hum Mutat.* 2007; **28**(3): 209–21.  
[PubMed Abstract](#) | [Publisher Full Text](#) | [Free Full Text](#)
61. Barsh GS, David KE, Byers PH: **Type I osteogenesis imperfecta: a nonfunctional allele for pro alpha 1(I) chains of type I procollagen.** *Proc Natl Acad Sci U S A.* 1982; **79**(12): 3838–42.  
[PubMed Abstract](#) | [Publisher Full Text](#) | [Free Full Text](#)
62. Sykes B, Francis MJ, Smith R: **Altered relation of two collagen types in osteogenesis imperfecta.** *N Engl J Med.* 1977; **296**(21): 1200–3.  
[PubMed Abstract](#) | [Publisher Full Text](#)
63. Willing MC, Deschenes SP, Scott DA, *et al.*: **Osteogenesis imperfecta type I: molecular heterogeneity for COL1A1 null alleles of type I collagen.** *Am J Hum Genet.* 1994; **55**(4): 638–47.  
[PubMed Abstract](#) | [Free Full Text](#)
64. Shapiro JR: **Clinical and genetic classification of osteogenesis imperfecta and epidemiology.** In *Osteogenesis imperfecta - a translational approach to brittle bone disease.* JR Shapiro, *et al.*, Editors. Academic Press: San Diego, CA. 2014: 15–22.  
[Publisher Full Text](#)
65. Cassella JP, Ali SY: **Abnormal collagen and mineral formation in osteogenesis imperfecta.** *Bone Miner.* 1992; **17**(2): 123–8.  
[PubMed Abstract](#) | [Publisher Full Text](#)
66. Cassella JP, Barber P, Catterall AC, *et al.*: **A morphometric analysis of osteoid collagen fibril diameter in osteogenesis imperfecta.** *Bone.* 1994; **15**(3): 329–34.  
[PubMed Abstract](#) | [Publisher Full Text](#)
67. Stöss H, Freisinger P: **Collagen fibrils of osteoid in osteogenesis imperfecta: morphometrical analysis of the fibril diameter.** *Am J Med Genet.* 1993; **45**(2): 257.  
[PubMed Abstract](#) | [Publisher Full Text](#)
68. Vetter U, Eanes ED, Kopp JB, *et al.*: **Changes in apatite crystal size in bones of patients with osteogenesis imperfecta.** *Calcif Tissue Int.* 1991; **49**(4): 248–50.  
[PubMed Abstract](#) | [Publisher Full Text](#)
69. Traub W, Arad T, Vetter U, *et al.*: **Ultrastructural studies of bones from patients with osteogenesis imperfecta.** *Matrix Biol.* 1994; **14**(4): 337–45.  
[PubMed Abstract](#) | [Publisher Full Text](#)
70. Fratzi-Zelman N, Schmidt I, Roschger P, *et al.*: **Unique micro- and nano-scale mineralization pattern of human osteogenesis imperfecta type VI bone.** *Bone.* 2015; **73**: 233–41.  
[PubMed Abstract](#) | [Publisher Full Text](#)
71. Kozloff KM, Carden A, Bergwitz C, *et al.*: **Brittle IV mouse model for osteogenesis imperfecta IV demonstrates postpubertal adaptations to improve whole bone strength.** *J Bone Miner Res.* 2004; **19**(4): 614–22.  
[PubMed Abstract](#) | [Publisher Full Text](#)
72. Jepsen KJ, Schaffler MB, Kuhn JL, *et al.*: **Type I collagen mutation alters the strength and fatigue behavior of Mov13 cortical tissue.** *J Biomech.* 1997; **30**(11–12): 1141–7.  
[PubMed Abstract](#) | [Publisher Full Text](#)
73. McCarthy EA, Raggio CL, Hossack MD, *et al.*: **Alendronate treatment for infants with osteogenesis imperfecta: demonstration of efficacy in a mouse model.** *Pediatr Res.* 2002; **52**(5): 660–70.  
[PubMed Abstract](#) | [Publisher Full Text](#)
74. Misof BM, Roschger P, Baldini T, *et al.*: **Differential effects of alendronate treatment on bone from growing osteogenesis imperfecta and wild-type mouse.** *Bone.* 2005; **36**(1): 150–8.  
[PubMed Abstract](#) | [Publisher Full Text](#)
75. Miller E, Delos D, Baldini T, *et al.*: **Abnormal mineral-matrix interactions are a significant contributor to fragility in oim/oim bone.** *Calcif Tissue Int.* 2007; **81**(3): 206–14.  
[PubMed Abstract](#) | [Publisher Full Text](#) | [Free Full Text](#)
76. Rao SH, Evans KD, Oberbauer AM, *et al.*: **Bisphosphonate treatment in the oim mouse model alters bone modeling during growth.** *J Biomech.* 2008; **41**(16): 3371–6.  
[PubMed Abstract](#) | [Publisher Full Text](#) | [Free Full Text](#)
77. Albert C, Jameson J, Toth JM, *et al.*: **Bone properties by nanoindentation in mild and severe osteogenesis imperfecta.** *Clin Biomech (Bristol, Avon).* 2013; **28**(1): 110–6.  
[PubMed Abstract](#) | [Publisher Full Text](#)
78. Fan Z, Smith PA, Harris GF, *et al.*: **Comparison of nanoindentation measurements between osteogenesis imperfecta Type III and Type IV and between different anatomic locations (femur/tibia versus iliac crest).** *Connect Tissue Res.* 2007; **48**(2): 70–5.  
[PubMed Abstract](#) | [Publisher Full Text](#)
79. Weber M, Roschger P, Fratzi-Zelman N, *et al.*: **Pamidronate does not adversely affect bone intrinsic material properties in children with osteogenesis imperfecta.** *Bone.* 2006; **39**(3): 616–22.  
[PubMed Abstract](#) | [Publisher Full Text](#)
80. Imbert L, Aurégnan J, Pernelle K, *et al.*: **Mechanical and mineral properties of osteogenesis imperfecta human bones at the tissue level.** *Bone.* 2014; **65**: 18–24.  
[PubMed Abstract](#) | [Publisher Full Text](#)
81. Albert CI, Jameson J, Harris G: **Design and validation of bending test method for characterization of miniature pediatric cortical bone specimens.** *Proc Inst Mech Eng H.* 2013; **227**(2): 105–13.  
[PubMed Abstract](#) | [Publisher Full Text](#)
82. Fritz JM, Grosland NM, Smith PA, *et al.*: **Brittle bone fracture risk with transverse isotropy.** In *Proceedings of the 37th Annual Meeting of the American Society of Biomechanics.* September 4–7. Omaha, NE, 2013.  
[Reference Source](#)
83. Boyd SK, Müller R: **Smooth surface meshing for automated finite element model generation from 3D image data.** *J Biomech.* 2006; **39**(7): 1287–95.  
[PubMed Abstract](#) | [Publisher Full Text](#)
84. Shim VB, Pitto RP, Streicher RM, *et al.*: **The use of sparse CT datasets for auto-generating accurate FE models of the femur and pelvis.** *J Biomech.* 2007; **40**(1): 26–35.  
[PubMed Abstract](#) | [Publisher Full Text](#)
85. Edwards WB, Troy KL: **Simulating distal radius fracture strength using biomechanical tests: a modeling study examining the influence of boundary conditions.** *J Biomech Eng.* 2011; **133**(11): 114501.  
[PubMed Abstract](#) | [Publisher Full Text](#)
86. Edwards WB, Troy KL: **Finite element prediction of surface strain and fracture strength at the distal radius.** *Med Eng Phys.* 2012; **34**(3): 290–8.  
[PubMed Abstract](#) | [Publisher Full Text](#)
87. Fritz JM, Guan Y, Wang M, *et al.*: **A fracture risk assessment model of the femur in children with osteogenesis imperfecta (OI) during gait.** *Med Eng Phys.* 2009; **31**(9): 1043–8.  
[PubMed Abstract](#) | [Publisher Full Text](#)
88. Fritz JM, Guan Y, Wang M, *et al.*: **Muscle force sensitivity of a finite element fracture risk assessment model in osteogenesis imperfecta - biomed 2009.** *Biomed Sci Instrum.* 2009; **45**: 316–21.  
[PubMed Abstract](#)
89. **F** Orwoll ES, Shapiro J, Veith S, *et al.*: **Evaluation of teriparatide treatment in adults with osteogenesis imperfecta.** *J Clin Invest.* 2014; **124**(2): 491–8.  
[PubMed Abstract](#) | [Publisher Full Text](#) | [Free Full Text](#) | [F1000 Recommendation](#)
90. **F** Caouette C, Rauch F, Villemure I, *et al.*: **Biomechanical analysis of fracture risk associated with tibia deformity in children with osteogenesis imperfecta: a finite element analysis.** *J Musculoskelet Neuronal Interact.* 2014; **14**(2): 205–12.  
[PubMed Abstract](#) | [F1000 Recommendation](#)
91. **F** Hoyer-Kuhn H, Semler O, Stark C, *et al.*: **A specialized rehabilitation approach improves mobility in children with osteogenesis imperfecta.** *J Musculoskelet Neuronal Interact.* 2014; **14**(4): 445–53.  
[PubMed Abstract](#) | [F1000 Recommendation](#)
92. Licata AA: **Discovery, clinical development, and therapeutic uses of bisphosphonates.** *Ann Pharmacother.* 2005; **39**(4): 668–77.  
[PubMed Abstract](#) | [Publisher Full Text](#)
93. Rauch F, Travers R, Plotkin H, *et al.*: **The effects of intravenous pamidronate on the bone tissue of children and adolescents with osteogenesis imperfecta.** *J Clin Invest.* 2002; **110**(9): 1293–9.  
[PubMed Abstract](#) | [Publisher Full Text](#) | [Free Full Text](#)
94. Plotkin H, Rauch F, Bishop NJ, *et al.*: **Pamidronate treatment of severe osteogenesis imperfecta in children under 3 years of age.** *J Clin Endocrinol Metab.* 2000; **85**(5): 1846–50.  
[PubMed Abstract](#) | [Publisher Full Text](#)
95. Land C, Rauch F, Munns CF, *et al.*: **Vertebral morphometry in children and adolescents with osteogenesis imperfecta: effect of intravenous pamidronate treatment.** *Bone.* 2006; **39**(4): 901–6.  
[PubMed Abstract](#) | [Publisher Full Text](#)
96. **F** Bishop N, Adami S, Ahmed SF, *et al.*: **Risedronate in children with osteogenesis imperfecta: a randomised, double-blind, placebo-controlled trial.** *Lancet.* 2013; **382**(9902): 1424–32.  
[PubMed Abstract](#) | [Publisher Full Text](#) | [F1000 Recommendation](#)



97. Nicolaou N, Agrawal Y, Padman M, *et al.*: **Changing pattern of femoral fractures in osteogenesis imperfecta with prolonged use of bisphosphonates.** *J Child Orthop.* 2012; **6**(1): 21–7.  
[PubMed Abstract](#) | [Publisher Full Text](#) | [Free Full Text](#)
98. Carpintero P, Del Fresno JA, Ruiz-Sanz J, *et al.*: **Atypical fracture in a child with osteogenesis imperfecta.** *Joint Bone Spine.* 2015; **82**(4): 287–8.  
[PubMed Abstract](#) | [Publisher Full Text](#)
99. Malmgren B, Aström E, Söderhäll S: **No osteonecrosis in jaws of young patients with osteogenesis imperfecta treated with bisphosphonates.** *J Oral Pathol Med.* 2008; **37**(4): 196–200.  
[PubMed Abstract](#) | [Publisher Full Text](#)
100. Chahine C, Cheung MS, Head TW, *et al.*: **Tooth extraction socket healing in pediatric patients treated with intravenous pamidronate.** *J Pediatr.* 2008; **153**(5): 719–20.  
[PubMed Abstract](#) | [Publisher Full Text](#)
101. Hennedige AA, Jayasinghe J, Khajeh J, *et al.*: **Systematic review on the incidence of bisphosphonate related osteonecrosis of the jaw in children diagnosed with osteogenesis imperfecta.** *J Oral Maxillofac Res.* 2014; **4**(4): e1.  
[PubMed Abstract](#) | [Free Full Text](#)
102. Adami S, Gatti D, Colapietro F, *et al.*: **Intravenous neridronate in adults with osteogenesis imperfecta.** *J Bone Miner Res.* 2003; **18**(1): 126–30.  
[PubMed Abstract](#) | [Publisher Full Text](#)
103. Chevrel G, Schott AM, Fontanges E, *et al.*: **Effects of oral alendronate on BMD in adult patients with osteogenesis imperfecta: a 3-year randomized placebo-controlled trial.** *J Bone Miner Res.* 2006; **21**(2): 300–6.  
[PubMed Abstract](#) | [Publisher Full Text](#)
104. Shapiro JR, Thompson CB, Wu Y, *et al.*: **Bone mineral density and fracture rate in response to intravenous and oral bisphosphonates in adult osteogenesis imperfecta.** *Calcif Tissue Int.* 2010; **87**(2): 120–9.  
[PubMed Abstract](#) | [Publisher Full Text](#)
105. Bradbury LA, Barlow S, Geoghegan F, *et al.*: **Risedronate in adults with osteogenesis imperfecta type I: increased bone mineral density and decreased bone turnover, but high fracture rate persists.** *Osteoporos Int.* 2012; **23**(1): 285–94.  
[PubMed Abstract](#) | [Publisher Full Text](#)
106. O'Sullivan ES, van der Kamp S, Kilbane M, *et al.*: **Osteogenesis imperfecta in adults: phenotypic characteristics and response to treatment in an Irish cohort.** *Ir J Med Sci.* 2014; **183**(2): 225–30.  
[PubMed Abstract](#) | [Publisher Full Text](#)
107. **F** Phillipi CA, Remington T, Steiner RD: **Bisphosphonate therapy for osteogenesis imperfecta.** *Cochrane Database Syst Rev.* 2008; (4): CD005088.  
[PubMed Abstract](#) | [Publisher Full Text](#) | [F1000 Recommendation](#)
108. **F** Hald JD, Evangelou E, Langdahl BL, *et al.*: **Bisphosphonates for the prevention of fractures in osteogenesis imperfecta: meta-analysis of placebo-controlled trials.** *J Bone Miner Res.* 2015; **30**(5): 929–33.  
[PubMed Abstract](#) | [Publisher Full Text](#) | [F1000 Recommendation](#)
109. **F** Antoniazzi F, Monti E, Venturi G, *et al.*: **GH in combination with bisphosphonate treatment in osteogenesis imperfecta.** *Eur J Endocrinol.* 2010; **163**(3): 479–87.  
[PubMed Abstract](#) | [Publisher Full Text](#) | [F1000 Recommendation](#)
110. Neer RM, Arnaud CD, Zanchetta JR, *et al.*: **Effect of parathyroid hormone (1-34) on fractures and bone mineral density in postmenopausal women with osteoporosis.** *N Engl J Med.* 2001; **344**(19): 1434–41.  
[PubMed Abstract](#) | [Publisher Full Text](#)
111. **F** Gatti D, Rossini M, Viapiana O, *et al.*: **Teriparatide treatment in adult patients with osteogenesis imperfecta type I.** *Calcif Tissue Int.* 2013; **93**(5): 448–52.  
[PubMed Abstract](#) | [Publisher Full Text](#) | [F1000 Recommendation](#)
112. **F** Cummings SR, San Martin J, McClung MR, *et al.*: **Denosumab for prevention of fractures in postmenopausal women with osteoporosis.** *N Engl J Med.* 2009; **361**(8): 756–65.  
[PubMed Abstract](#) | [Publisher Full Text](#) | [F1000 Recommendation](#)
113. **F** Hoyer-Kuhn H, Netzer C, Koerber F, *et al.*: **Two years' experience with denosumab for children with osteogenesis imperfecta type VI.** *Orphanet J Rare Dis.* 2014; **9**: 145.  
[PubMed Abstract](#) | [Publisher Full Text](#) | [Free Full Text](#) | [F1000 Recommendation](#)
114. Hoyer-Kuhn H, Semler O, Schoenau E: **Effect of denosumab on the growing skeleton in osteogenesis imperfecta.** *J Clin Endocrinol Metab.* 2014; **99**(11): 3954–5.  
[PubMed Abstract](#) | [Publisher Full Text](#)
115. Boyce AM, Chong WH, Yao J, *et al.*: **Denosumab treatment for fibrous dysplasia.** *J Bone Miner Res.* 2012; **27**(7): 1462–70.  
[PubMed Abstract](#) | [Publisher Full Text](#) | [Free Full Text](#)
116. **F** McClung MR, Grauer A, Boonen S, *et al.*: **Romosozumab in postmenopausal women with low bone mineral density.** *N Engl J Med.* 2014; **370**(5): 412–20.  
[PubMed Abstract](#) | [Publisher Full Text](#) | [F1000 Recommendation](#)
117. **F** Sinder BP, Eddy MM, Ominsky MS, *et al.*: **Sclerostin antibody improves skeletal parameters in a Brtl/+ mouse model of osteogenesis imperfecta.** *J Bone Miner Res.* 2013; **28**(1): 73–80.  
[PubMed Abstract](#) | [Publisher Full Text](#) | [Free Full Text](#) | [F1000 Recommendation](#)
118. **F** Sinder BP, White LE, Salemi JD, *et al.*: **Adult Brtl/+ mouse model of osteogenesis imperfecta demonstrates anabolic response to sclerostin antibody treatment with increased bone mass and strength.** *Osteoporos Int.* 2014; **25**(8): 2097–107.  
[PubMed Abstract](#) | [Publisher Full Text](#) | [Free Full Text](#) | [F1000 Recommendation](#)
119. **F** Roschger A, Roschger P, Keplinger P, *et al.*: **Effect of sclerostin antibody treatment in a mouse model of severe osteogenesis imperfecta.** *Bone.* 2014; **66**: 182–8.  
[PubMed Abstract](#) | [Publisher Full Text](#) | [F1000 Recommendation](#)
120. **F** Grafe I, Yang T, Alexander S, *et al.*: **Excessive transforming growth factor- $\beta$  signaling is a common mechanism in osteogenesis imperfecta.** *Nat Med.* 2014; **20**(6): 670–5.  
[PubMed Abstract](#) | [Publisher Full Text](#) | [Free Full Text](#) | [F1000 Recommendation](#)
121. Horwitz EM, Prockop DJ, Gordon PL, *et al.*: **Clinical responses to bone marrow transplantation in children with severe osteogenesis imperfecta.** *Blood.* 2001; **97**(5): 1227–31.  
[PubMed Abstract](#) | [Publisher Full Text](#)
122. **F** Horwitz EM, Gordon PL, Koo WK, *et al.*: **Isolated allogeneic bone marrow-derived mesenchymal cells engraft and stimulate growth in children with osteogenesis imperfecta: Implications for cell therapy of bone.** *Proc Natl Acad Sci U S A.* 2002; **99**(13): 8932–7.  
[PubMed Abstract](#) | [Publisher Full Text](#) | [Free Full Text](#) | [F1000 Recommendation](#)
123. **F** Le Blanc K, Götherström C, Ringdén O, *et al.*: **Fetal mesenchymal stem-cell engraftment in bone after in utero transplantation in a patient with severe osteogenesis imperfecta.** *Transplantation.* 2005; **79**(11): 1607–14.  
[PubMed Abstract](#) | [Publisher Full Text](#) | [F1000 Recommendation](#)
124. Amin MT, Shazly SA: **In utero stem cell transplantation for radical treatment of osteogenesis imperfecta: perspectives and controversies.** *Am J Perinatol.* 2014; **31**(10): 829–36.  
[PubMed Abstract](#) | [Publisher Full Text](#)
125. **F** Lindahl K, Kindmark A, Laxman N, *et al.*: **Allele dependent silencing of collagen type I using small interfering RNAs targeting 3'UTR Indels - a novel therapeutic approach in osteogenesis imperfecta.** *Int J Med Sci.* 2013; **10**(10): 1333–43.  
[PubMed Abstract](#) | [Publisher Full Text](#) | [Free Full Text](#) | [F1000 Recommendation](#)

# Open Peer Review

Current Referee Status:



## Version 1

Referee Report 07 September 2015

doi:[10.5256/f1000research.6864.r10219](https://doi.org/10.5256/f1000research.6864.r10219)



**Bart Clarke**

Division of Endocrinology, Diabetes, Metabolism, and Nutrition, Mayo Clinic College of Medicine, Rochester, MN, USA

**I have read this submission. I believe that I have an appropriate level of expertise to confirm that it is of an acceptable scientific standard.**

**Competing Interests:** No competing interests were disclosed.

Referee Report 07 September 2015

doi:[10.5256/f1000research.6864.r10218](https://doi.org/10.5256/f1000research.6864.r10218)



**Dhanwada Sudhaker Rao**

Division of Endocrinology, Diabetes and Bone & Mineral Disorders, Henry Ford Hospital, Detroit, MI, USA

**I have read this submission. I believe that I have an appropriate level of expertise to confirm that it is of an acceptable scientific standard.**

**Competing Interests:** No competing interests were disclosed.

Referee Report 07 September 2015

doi:[10.5256/f1000research.6864.r10217](https://doi.org/10.5256/f1000research.6864.r10217)



**Malachi McKenna**

St. Vincent's University Hospital, Dublin, Ireland

**I have read this submission. I believe that I have an appropriate level of expertise to confirm that it is of an acceptable scientific standard.**

**Competing Interests:** No competing interests were disclosed.

---

## Discuss this Article

Version 1

Reader Comment 30 Sep 2015

**Raymond Dalgleish**, University of Leicester, UK

I have noted a few issues in this article:

1. On page 2, in the section headed "Genes and classification", gene symbols (*COL1A1* and *COL1A2*) are inappropriately used to designate the component protein chains of type I collagen. Gene symbols and protein product names should not be used interchangeably. The protein chains are  $\alpha 1(I)$  and  $\alpha 2(I)$  respectively.
2. In Table 1, the gene symbols for the mutant genes leading to OI types I, II, III and IV are incorrect. They should be *COL1A1* and *COL1A2*, not *COL1A1* and *COLA2*.
3. In Table 1, the gene symbol for the gene encoding the protein prolyl-3 hydroxylase is *P3H1*, not *LEPRE1*. The gene symbol for this gene was changed to *P3H1* in December 2014.
4. Table 1 continues to propagate the notion that there are very many OI types when, in reality, there are really only five true types which can be clearly distinguished clinically (types I to V). The problem has been caused by several new OI types being created to correspond to newly discovered genes which harbour OI-causing sequence variants. This has only served to confuse matters and is discussed at length by Van Dijk and Sillence (2014) (<http://www.ncbi.nlm.nih.gov/pubmed/24715559>).
5. It is perhaps unsurprising that the article gives emphasis to pharmacological interventions for OI, given that one of the authors is employed by Alexion Pharmaceuticals, but it is improper to ignore surgical interventions such as rodding of long bones and mesenchymal stem cell therapy.
6. There is no mention in the article of the fact that there is a comprehensive database of gene variants leading to OI: <https://oi.gene.le.ac.uk/>.
7. The list of OI genes is incomplete in Table 1. A comprehensive list of genes may be found at <https://oi.gene.le.ac.uk/status.php>.

**Competing Interests:** I declare that I curate the database of OI gene variants which is mentioned in comment 6.

---