

Marquette University
e-Publications@Marquette

Physician Assistant Studies Faculty Research and
Publications

Physician Assistant Studies, Department

7-15-2010

Determining Axis and Axis Deviation on an ECG

Patrick Loftis

Marquette University, patrick.loftis@marquette.edu

Accepted version. *Journal of the American Academy of Physician Assistants* (July 2010). a
[href="http://journals.lww.com/jaapa/pages/default.aspx"](http://journals.lww.com/jaapa/pages/default.aspx) target="_blank".Publisher link.. © 2010,
American Academy of Physician Assistants and Haymarket Media Inc. Reproduced with permission.
The published version of the journal article is also available [here](#).

Determining axis and axis deviation on an ECG

[Patrick Loftis, PA-C, MPAS, RN](#)

July 15 2010

Each lead shown on an ECG represents electrical changes in the heart that are detected by two electrodes. A wave of depolarization that is moving *toward* a positive electrode creates a positive deflection on the ECG, while a wave of depolarization that is moving *away from* a positive electrode creates a negative deflection. A perpendicular wave will create a biphasic deflection that contains both positive and negative components.

The average direction of electrical flow detected by a lead at any point in time is the lead's orientation angle. It can be represented by an arrow, or *vector*. The *electrical axis* is the average direction, or the mean vector, of all the waves of depolarization in the heart at a given point in time. Deviations from a normal axis may or may not suggest hypertrophy of a chamber. Increased electrical activity within the enlarged muscle can cause a change in the axis.

Determining the axis

In order to determine the axis, the electrocardiograph makes one electrode positive and one or more electrodes negative. The instrument then calculates the direction of depolarization, or the vector, for each lead and averages those results to yield the heart's axis. Interpretation of a 12-lead ECG depends on precise placement of the various electrodes. The placement of electrodes for the limb leads (I, II, III, aVR, aVL, and aVF) is based on a universally accepted schematic that uses a circle representing the area between the chin and the pubic symphysis (**Figure 1**). The limb leads track the electrical changes in the frontal plane.

Recording of an ECG begins with placement of one electrode on each extremity. Lead I is formed by making the electrode on the left arm positive and making the electrode on the right arm negative. This lead looks at the electrical changes between the negative right electrode and the positive left

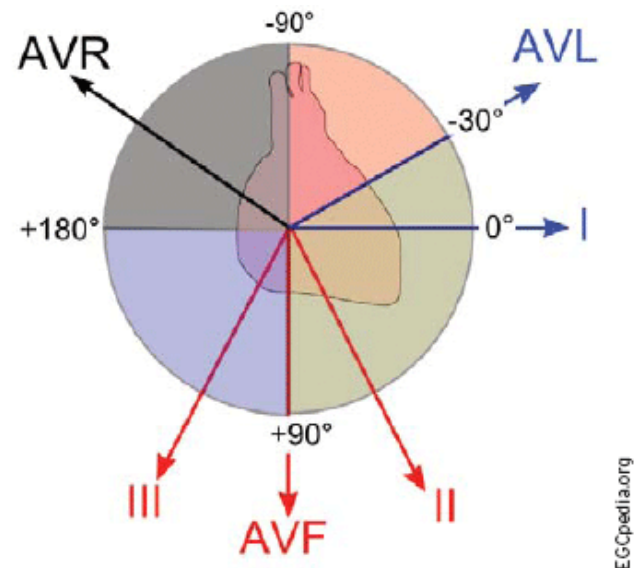


FIGURE 1. Schematic used to determine the

electrode. In addition to creating an orientation angle of 0° for this lead in the normal heart, the line divides the circle into two hemispheres of 180° each. Angles around the circle are read from the point representing the left electrode and are positive in the lower hemisphere and negative in the upper hemisphere.

direction of electrical changes in the six limb leads on an ECG.

Lead II is formed by making the leg leads positive and an electrode on the right arm negative. The electrocardiograph views the electrical changes from the perspective of the negative right arm electrode along the line to the positive electrode and forms an orientation angle of $+60^\circ$. Lead III is formed by making the leg leads positive and the left arm negative, creating an orientation angle of $+120^\circ$. Leads aVL, aVR, and aVF are *augmented* leads. In an augmented lead, a single electrode is made positive and all the other electrodes are made negative, with their average serving as the negative electrode. Lead aVL is created by making the electrode on the left arm positive, resulting in a -30° angle of orientation. Lead aVR is created by making the right arm positive, resulting in a -150° angle of orientation. Lead aVF is created by making both legs positive, resulting in a $+90^\circ$ angle of orientation.

In leads V₁-V₆, the four electrodes on the extremities are averaged and used as a single negative electrode at the center of the body. The six positive electrodes are placed horizontally across the precordium, and the electrocardiograph views the electrical activity from the “central” negative electrode to each positive electrode. These leads measure the wave of depolarization on the horizontal plane.

Clinical relevance

The clinical relevance of vectors and the axis is based on the fact that the left ventricle is the most muscular portion of the normal heart. The mass of the left ventricle and its orientation in the body results in a wave of depolarization for the heart as a whole that generally points down and left. The lead that best portrays the axis of a “normal” heart is lead II, with its downward and leftward orientation. A normal axis that points down and to the left is between 0° and $+90^\circ$. An axis outside this range is considered *deviated*.

Determining the exact degree of the axis is much less important clinically than determining whether it is normal or deviated. We determine whether an axis is normal or deviated to the left or right by looking at the QRS complex of leads I and aVF because these are the leads located at 0° and 90° , respectively. An upward deflection is positive and a downward deflection is negative (**Table 1**).

TABLE 1. Using leads I and aVF to distinguish between a normal and deviated axis

Axis	Lead I	Lead aVF
Normal	+	+
Left deviation	+	-
Right deviation	-	+
Extreme right deviation	-	-

Deviation of the axis suggests a change in the mean vector of electrical flow within the heart. This change can be the result of anomalies in the heart that cause the direction of depolarization to change. Improperly positioned electrodes can also cause an axis shift. The most likely cause of axis deviation is hypertrophy. Hypertrophy of either ventricle can shift the axis toward the area that is hypertrophied. Hypertrophy of the left ventricle is most commonly caused by hypertension; other less common causes include hypertrophic cardiomyopathy, extreme exercise, and aortic disease. Hypertrophy of the right ventricle is most commonly caused by severe lung disease; other causes are pulmonary embolus and pulmonary valve disease.

ECG Challenge

Figure 2 is the ECG of a 66-year-old man with long-standing hypertension who presented to his primary care clinician for a physical examination prior to undergoing foot surgery.

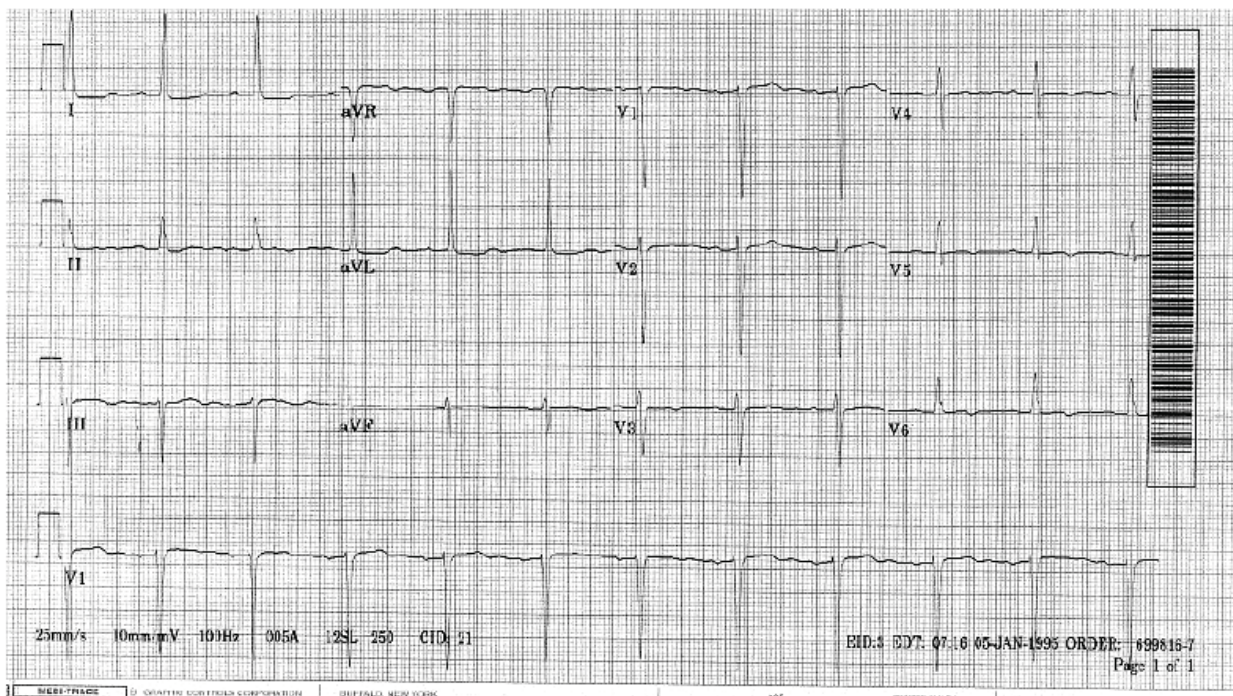


FIGURE 2. Preoperative ECG of a man with hypertension.

Using the stepwise approach presented in “[Electrocardiography: Understanding the basics](#),” we need to check the following:

(1) Is this ECG **regular**? Yes, the QRS complexes march out.

(2) What is the **heart rate**? Find a QRS complex on or near a dark line.

Method A: Counting the large boxes, we see that the span between QRS complexes is just slightly more than four large boxes. Four boxes would put the heart rate at 75 beats per minute, so we can estimate it at just less than that, or 70 beats per minute.

Method B: The number of QRS complexes in 6 seconds (30 large boxes) is seven. Multiplying that number by 10 gives us the number of beats in 60 seconds or a heart rate of 70 beats per minute.

Method C: Dividing 300 by the number of large boxes (four) between QRS complexes gives us an estimated heart rate of 75 beats per minute.

(3) There is a **P wave** for every QRS complex, and each looks the same as the next.

(4) The **PR interval** is approximately three small boxes, which is 0.12 seconds. This means the patient has a sinus rhythm.

(5) The **QRS complex** spans less than three small boxes, which is normal.

(6) The **ST segments** are slightly elevated. This is consistent with an early repolarization abnormality, which is a normal variant.

(7) The **T waves** are inverted in leads V₃-V₆. This is a nonspecific finding that can represent early ischemia and may need to be investigated.

(8) **U waves** are absent.

Determine the axis by looking at leads I and aVF. Lead I shows a QRS complex with a positive deflection, while

the aVF lead shows a biphasic QRS that is more negative than positive. According to Table 1, the combination of a positive deflection in lead I and a negative deflection in lead aVF indicates left axis deviation.

Symptoms

By itself, left axis deviation is associated with no specific symptoms. If the deviation is due to left ventricular hypertrophy (LVH) and the hypertrophy has resulted in heart failure, then the patient may demonstrate such symptoms of heart failure as dyspnea on exertion or leg edema.

Etiology

As noted earlier, axis deviation is most commonly a result of ventricular hypertrophy. The most common cause of LVH is hypertension, which is present in this patient.

Treatment

There is no specific treatment for left axis deviation, although its presence may suggest the need for further evaluation of the ventricles. [JAAPA](#)

Suggested reading

Thaler M. *The Only EKG Book You'll Ever Need*. 6th ed. New York, NY: Lippincott Williams & Wilkins; 2010:65-74.

Patrick Loftis practices emergency medicine and is clinical assistant professor, Department of Physician Assistant Studies, Marquette University, Milwaukee, Wisconsin. The author has no relationships to disclose relating to the contents of this article.