

Marquette University  
**e-Publications@Marquette**

---

Physician Assistant Studies Faculty Research and  
Publications

Physician Assistant Studies, Department

---

8-12-2010

# The P Wave: Indicator of Atrial Enlargement

Patrick Loftis

Marquette University, [patrick.loftis@marquette.edu](mailto:patrick.loftis@marquette.edu)

---

Accepted version. *Journal of the American Academy of Physician Assistants* (August 2010).

[Permalink](#). © 2010, American Academy of Physician Assistants and Haymarket Media Inc. Used with permission.

# The P wave: Indicator of atrial enlargement

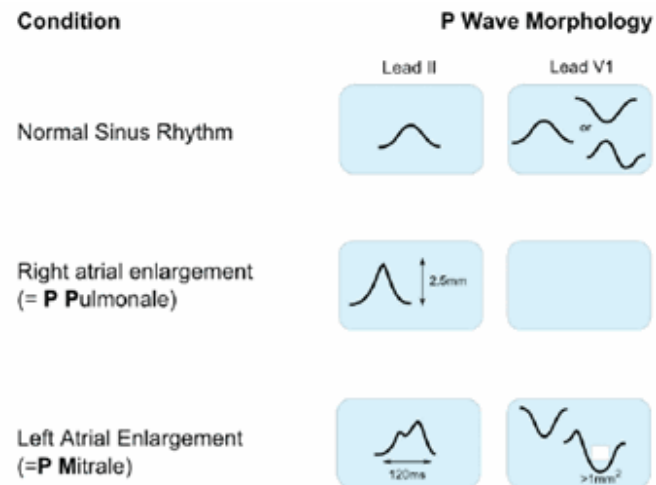
[James F. Ginter, MPAS, PA-C](#), [Patrick Loftis, PA-C, MPAS, RN](#)

August 12 2010

Once you've determined that a P wave precedes each QRS complex, you must scrutinize the P wave for contour and size. The normal P wave is less than 0.12 seconds in duration, and the largest deflection, whether positive or negative, should not exceed 2.5 mm. An abnormal P wave may indicate atrial enlargement.

Atrial depolarization follows the discharge of the sinus node. Normally depolarization occurs first in the right atrium and then in the left atrium. Atrial enlargement is best observed in the P waves of leads II and V<sub>1</sub>. Lead II is oriented parallel to the flow of current through the atrium and is the main P wave vector. V<sub>1</sub> is oriented perpendicular to the flow of current through the atrium. This results in a biphasic P wave, in which the first peak represents depolarization of the right atrium and the second peak represents depolarization of the left atrium, allowing for easy differentiation between the atria.

**Right atrial enlargement (RAE)** leads to delayed activation of the right atrium. This delay causes activation and the subsequent polarization of the atria to occur simultaneously. The simultaneous polarization is reflected in a P wave that is peaked and narrower than usual (**Figure 1**). The peak in the P wave is the result of the increased amount of depolarized tissue. Although depolarization is prolonged in an enlarged right atrium, the P wave appears narrower because depolarization of the right atrium is hidden by depolarization of the left atrium. Enlargement of the right atrium may cause the vector of atrial depolarization to shift to the right and exceed 20°, causing the tallest P wave to appear in the ECG tracing for lead III or aVF rather than the tracing for lead II.



**FIGURE 1.** Effect of atrial enlargement on P wave morphology

RAE is also known as P pulmonale because it is often a result of severe lung disease. The ECG is diagnostic if it

reveals

- (1) Peaked P waves greater than or equal to 2.5 mm in leads II, III, and aVF and a larger positive first deflection in V<sub>1</sub> than negative deflection in the terminal portion of the P wave
- (2) No change in P wave duration
- (3) Possible right axis deviation of the P wave

**Left atrial enlargement (LAE)** leads to delayed activation of the left atrium and thus prolonged depolarization and a prolonged P wave. The increased tissue mass will cause the terminal, or negative, portion of the P wave in lead V<sub>1</sub> to increase in amplitude by at least 1 mm.

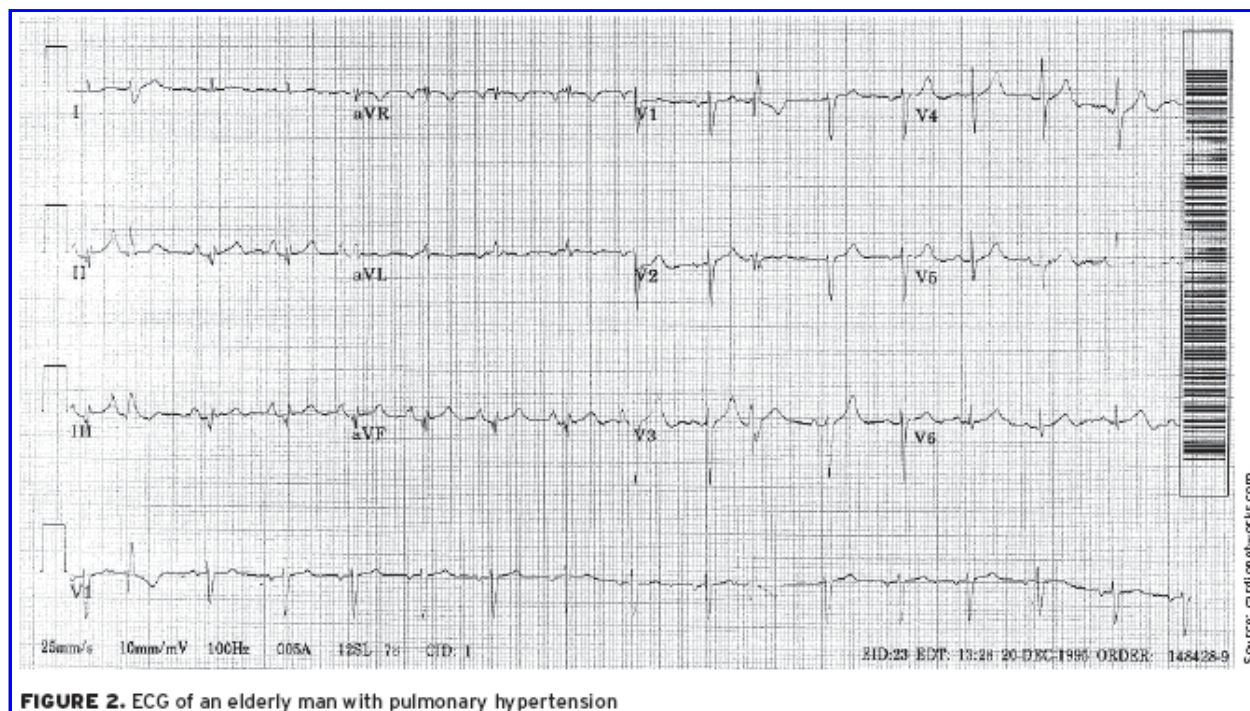
LAE is also known as P mitrale because it is associated with mitral valve disease. Diagnosis is based on the following ECG findings:

- (1) A notched P wave in lead II
- (2) Amplitude of the terminal component of the P wave that descends at least 1 mm below the isoelectric line in lead V<sub>1</sub>
- (3) Increased duration of the P wave; terminal portion of the P wave must span at least one small box (40 msec)
- (4) No significant axis deviation because the left atrium is normally electrically dominant

## ECG challenge

Two patients provide an opportunity to apply these principles:

**A 75-year-old man** with pulmonary hypertension has an ECG as part of his yearly examination (**Figure 2**; click image to enlarge).



Based on the stepwise approach to evaluating an ECG, consider the following:

(1) Does the ECG indicate a **regular** heartbeat? Yes, the QRS complexes march out.

(2) Determine the patient's heart **rate** by finding a QRS complex on or near a dark line.

**Method A:** The number of large boxes between Rs is close to four. Four boxes puts the rate at 75 beats per minute.

**Method B:** Approximately seven QRS complexes occur in 6 seconds (30 large boxes), which estimates the heart rate at 70 beats per minute ( $7 \times 10 = 70$ ).

**Method C:** Dividing 300 by the number of large boxes between QRS complexes (4) yields an estimate of 75 beats per minute.

(3) A **P wave** appears before each QRS complex. Is the contour of the P wave the same in all leads? In lead II, the P wave is peaked and has a normal duration. The P wave in V<sub>1</sub> is biphasic, with no increase in the upslope of the first deflection.

(4) The **PR interval** spans approximately three small boxes (0.12 seconds), indicating a sinus rhythm.

(5) The **QRS complex** spans fewer than three small boxes, which is normal.

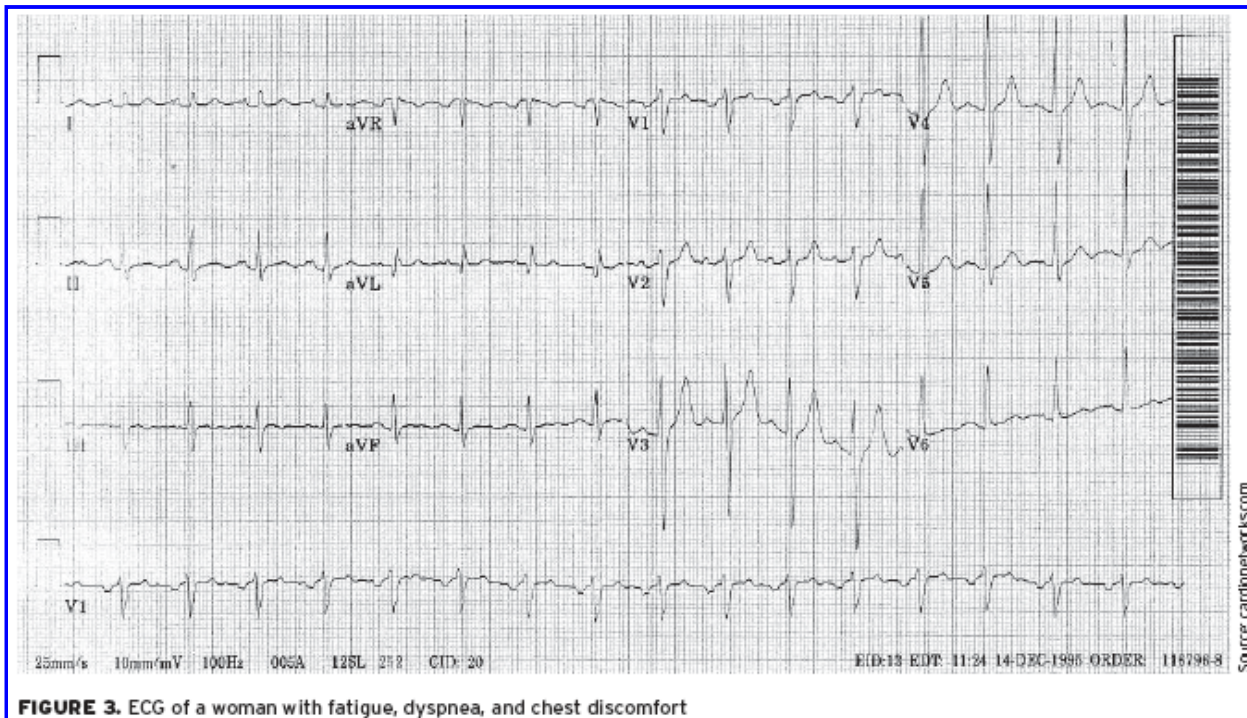
(6) The **ST segments** are neutral, so there is no ischemia.

(7) The **T wave** is positively deflected in all leads except the aVR.

(8) There are **no U waves**.

This ECG indicates that the patient is in sinus rhythm and has RAE.

**The second patient** is a 53-year-old woman who complains of fatigue, dyspnea, and mild chest discomfort. On auscultation, you hear a mid-diastolic low-pitched murmur. The ECG is shown in **Figure 3** (click image to enlarge).



**FIGURE 3.** ECG of a woman with fatigue, dyspnea, and chest discomfort



(1) Is this ECG **regular**? Yes, the QRS complexes march out.

(2) **Heart rate:**

**Method A:** The number of large boxes between Rs is close to three. Three boxes would put the rate at 100 beats per minute.

**Method B:** Approximately 10 QRS complexes occur in 6 seconds (30 large boxes), resulting in an estimated rate of 100 beats per minute ( $10 \times 10 = 100$ ).

**Method C:** Dividing 300 by the number of large boxes between QRS complexes (3) yields a heart rate of 100 beats per minute.

(3) There is a **P wave** for every QRS complex. Is the contour the same? A notched P wave in lead II has a prolonged duration. The P wave in  $V_1$  is biphasic, has an increased down slope in the terminal portion, and spans more than one small box (ie, more than 40 milliseconds in duration).

(4) The **PR interval** is approximately three small boxes, which is 0.12 seconds, indicating a sinus rhythm.

(5) The **QRS complex** spans fewer than three small boxes, which is normal.

(6) The **ST segments** are neutral; there is no ischemia.

(7) The **T wave** is positively deflected in all leads except the aVR.

(8) There are **no U waves**.

This ECG indicates that the patient is in sinus rhythm and has LAE.

## Discussion

Atrial chamber enlargement can occur in the presence of either increased resistance to blood flow (pressure overload or systolic overload) or increased quantity of blood within the chamber (volume overload or diastolic overload). Increased resistance to blood flow results in hypertrophy of the myocardial wall, and increased blood volume causes dilation of the chamber. The myocardial walls of the atria, which are thinner than the ventricular walls, generally respond to both types of overload.

## Clinical implications of atrial enlargement

While one atrium can be enlarged while the other remains normal, isolated enlargement of an atrium is rare. Atrial enlargement is commonly associated with disease of the ventricles or valvular structures. Enlargement of either atrium predisposes the patient to atrial flutter or atrial fibrillation.

The most common cause of RAE is pulmonary disease. Other causes of RAE include tricuspid or pulmonary valve disease, acute pulmonary embolism, or right ventricular failure or hypertrophy.

The most common cause of LAE is mitral valve abnormality, such as mitral valve stenosis or insufficiency. Another cause of LAE is left ventricular dysfunction. LAE is a common finding in left ventricular hypertrophy and one of the criteria required for diagnosis.

## Treatment

Once atrial enlargement has been diagnosed, identify the underlying cause. The etiology of atrial enlargement will determine its treatment and prognosis. [JAAPA](#)

---

**Jim Ginter** practices at Aurora Cardiovascular Services in Milwaukee, Wisconsin. **Patrick Loftis** practices emergency medicine and is clinical assistant professor in the Department of Physician Assistant Studies, Marquette University, Milwaukee, Wisconsin. The authors have no relationships to disclose relating to the contents of this article.