

Marquette University  
**e-Publications@Marquette**

---

School of Dentistry Faculty Research and  
Publications

Dentistry, School of

---

11-1-1978

# Replantation of an Avulsed Incisor: Case Report

Richard A. Abrams  
*Marquette University*

---

Published version. *Quintessence International*, No. 11 (November 1978): 85-87. [Publisher link](#). ©  
Quintessence Publishing 1978. Used with permission.

Original article:

## Replantation of an avulsed incisor: case report

Richard A. Abrams, D.D.S., M.P.H.

Assistant Professor, Head, Division of Community Dentistry, School of Dentistry, Marquette University

Address: 604 North 16th Street, Milwaukee, Wisconsin 53233

### Background

Replantation of intact avulsed teeth can be one of the most conservative procedures in dentistry. If it is successful, the patient is "ahead of the game"—if it is not, nothing has been sacrificed.

After evaluating seventy-one replanted teeth, Kemp et al. concluded that treatment of avulsed teeth by replantation is justified, despite the fact that it is usually not a permanent procedure.<sup>1</sup> Rabinowitch evaluated twenty-one replanted teeth for a six year period. Three of the twenty-one ultimately had to be extracted due to root resorption.<sup>2</sup> Other individuals have studied replantation of avulsed teeth, and the consensus is firmly in favor of attempting the procedure.<sup>3, 4, 5, 6, 7</sup>

### Case report

On July 9, 1973, a 21 year old well developed, well nourished, Caucasian male presented at the Dental Clinic on board the aircraft carrier USS John F. Kennedy. The patient presented with moderate oral hemorrhage, and reported that he "fell and lost his front tooth" about ten minutes ago. Upon clinical examination of the patient, it was determined that there was a small ( $1/2$  cm) laceration of the inner aspect of the upper lip, and a missing maxillary left central incisor. Radiographic ex-

amination (Fig. 1) revealed an empty alveolus, with no apparent fracture. No other pathology was observed.

Upon questioning, the patient related that he and several of his friends has looked around the room for the missing tooth, but were unable to locate it. Several of his friends were sent back to the scene of the accident to search for the tooth, and the patient was informed that if it were located, replantation could be attempted. In the mean time, the area of the maxillary left central incisor was infiltrated with 1.8 cc lidocaine HCl (2% with epinephrine 1:50,000), flushed with normal saline solution, and a gauze pack was placed to control hemorrhage.

After forty-five minutes, the avulsed tooth was located, and brought to the Dental Clinic. It was found to be intact, and was placed in a solution of normal saline for ten minutes. Holding the tooth with a  $2 \times 2$  gauze sponge moistened with normal saline solution, the apical foramen was slightly enlarged and undercut using  $33\frac{1}{3}$  bur in a high speed handpiece. Amalgam was then placed in the apical foramen to obtain a seal. To shorten the working time to facilitate replantation, no other endodontic procedure was performed at this time.

The maxillary left central incisor was then replaced in the alveolus, and

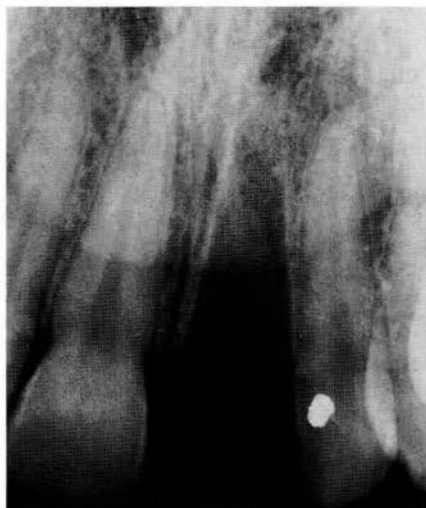


Fig. 1 Radiographic picture reveals an empty alveolus, with no apparent fracture of either alveolar bone or adjacent teeth

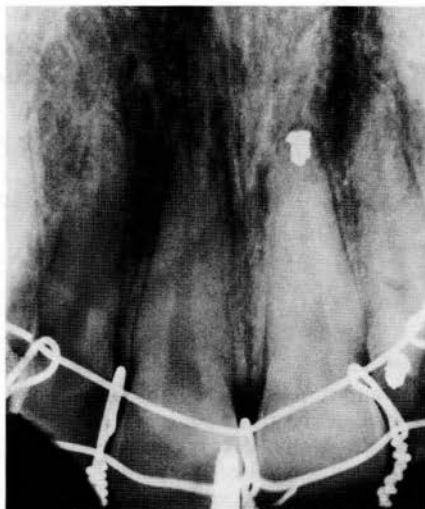

Fig. 2 Maxillary left central incisor was ligated in position with stainless steel ligature wire. The apex was sealed with amalgam, however no other endodontic procedures were performed at this time

ligated in position with stainless steel ligature wire (Fig. 2). Slight adjustment of the maxillary left central incisor was necessary to remove the tooth from occlusion. The patient was then placed on V-Cillin K (400,000 units, qid for ten days), Ananase (100,000 units, qid for four days), and Empirin No. 3 (prn pain).

The patient was observed frequently over a six week period, after which it was decided to remove the ligature wires. At that time, the area in question was completely asymptomatic. Clinically, no mobility, nor discoloration of the tooth was observed, and no pathology was noted on the X-ray.

Shortly after the ligature wires were removed, endodontic procedures were started. After the tooth was isolated with the rubber dam, an access opening was made on the lingual surface of the

incisor. The necrotic pulpal tissue was removed, and the canal was flushed with hydrogen peroxide. The canal was instrumented until the appearance of clean, white dentin was noted. Then, the canal was dried with paper points, and filled with gutta percha (lateral condensation technique) and Kerr root canal cement. The access opening was sealed with amalgam.

### Results

This patient has been followed routinely, and was last examined in March 1977. At that time, the tooth appeared clinically normal, with no discoloration evident, no mobility, and no periodontal problems. Radiographic examination (Fig. 3) confirms the clinical observations, revealing a normal appearance after three and one-half years, with no apparent pathology.

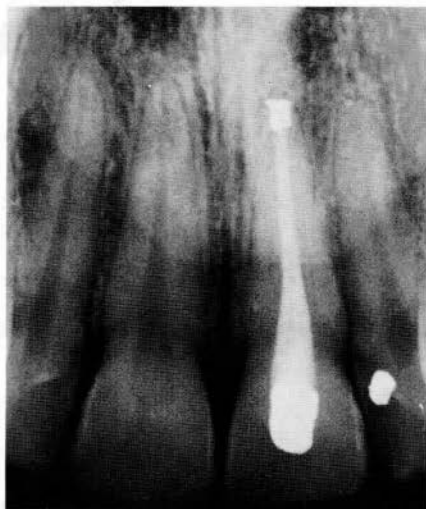

Fig. 3 After more than 3½ years, the radiographic picture confirms the clinical observation: a maxillary left central incisor, normal in appearance, with no apparent pathology present

### Summary

This report of a case demonstrates an avulsed maxillary central incisor which had been absent from the alveolus for approximately one and one-half hours, and was successfully replanted. There is a lack of visual, tactile, and radiographic evidence of pathosis after more than three and one-half years.

### Bibliography

1. Kemp, W. B., Grossman, L., and Phillips, J.  
Evaluation of 71 replanted teeth. *Journal of Endodontics* 3(1):30—35, Jan. 1977.
2. Rabinowitch, B. Z.  
Replantation of teeth and management of root fractures. *Dental Clinics of North America*, July 1962, p. 555.
3. Heithersay, G. S.  
Replantation of avulsed teeth. A review. *Australian Dental Journal* 20(2):63—72, April 1975.
4. Weine, F.  
Case reports — replantations. *Illinois Dental Journal* 42:657—662, Oct. 1973.
5. Wiedeman, C. L.  
Case report tooth replantation treatment after oral injury. *Dental Survey* 50:28—30, Febr. 1974.
6. Bellizzi, R.  
Replantation of avulsed anterior teeth: an unusual technique. *Oral Surgery, Oral Medicine, Oral Pathology* 38(4):614—617, Oct. 1974.
7. Boyne, P. J.  
Implants and transplants: review of recent research in this area of oral surgery. *The Journal of the American Dental Association* 87:1074 to 1080, Oct. 1973.

**WISIL**®

cobalt-chromium  
alloy

**KRUPP DENTAL**  
POSTFACH 6903 · D-4300 ESSEN 1