

Florida International University FIU Digital Commons

Nicole Wertheim College of Nursing and Health
Sciences

Nicole Wertheim College of Nursing and Health
Sciences

2-2-2018

Regional Anesthesia for Bilateral Carpal Tunnel Release

Debra S. Varela
Barry University

Johanna Newman
Barry University

Jorge A. Valdes
Florida International University, jvalde@fiu.edu

Follow this and additional works at: https://digitalcommons.fiu.edu/cnhs_fac

 Part of the [Medicine and Health Sciences Commons](#)

Recommended Citation

Varela, Debra S.; Newman, Johanna; and Valdes, Jorge A., "Regional Anesthesia for Bilateral Carpal Tunnel Release" (2018). *Nicole Wertheim College of Nursing and Health Sciences*. 20.
https://digitalcommons.fiu.edu/cnhs_fac/20

This work is brought to you for free and open access by the Nicole Wertheim College of Nursing and Health Sciences at FIU Digital Commons. It has been accepted for inclusion in Nicole Wertheim College of Nursing and Health Sciences by an authorized administrator of FIU Digital Commons. For more information, please contact dcc@fiu.edu.

Regional Anesthesia for Bilateral Carpal Tunnel Release

Debra S. Varela, DNP, CRNA¹

Johanna Newman, DNAP, CRNA²

Jorge A. Valdes, DNP, CRNA³

Affiliation:

1. Literature Review was conducted as partial fulfillment for the degree of Doctor of Nursing Practice in Anesthesiology through Barry University in Miami Florida and practicing CRNA at a critical access hospital in rural North Central Arkansas

2. CRNA Clinician at Anesco North Broward in Fort Lauderdale, FL

3. Clinical Assistant Professor of Anesthesiology at Florida International University in the College of Nursing Health Sciences

Funding/Conflict of Interest Disclosure: None

KEYWORDS: carpal tunnel syndrome, median nerve block, local anesthesia, lidocaine, epinephrine

Abstract

Carpal tunnel syndrome is the most common nerve entrapment neuropathy, and over 60% of diagnosed patients present with bilateral median nerve involvement. Bilateral upper extremity surgery presents unique anesthesia challenges, yet surgeons are increasingly interested in performing simultaneous bilateral carpal tunnel release (BCTR) procedures. The regional anesthesia techniques traditionally used for unilateral hand procedures are impractical for bilateral procedures, and general anesthesia is expensive and incurs added risk. A cost-effective and efficient anesthesia plan for BCTR is therefore needed. We conducted a literature search to support the administration of an efficient and safe anesthesia technique for BCTR utilizing local infiltration and median nerve block. Electronic searches were conducted to identify current pertinent information published in anesthesia, hand surgery, and plastic surgery journals within the past 5 years. The information gathered was assimilated to make an evidence-based recommendation for a BCTR anesthesia technique. BCTR is a more cost-effective and time-efficient treatment for bilateral carpal tunnel syndrome than a staged unilateral approach. Local anesthesia with median nerve block with or without sedation is a cost-efficient and safe anesthesia strategy for BCTR.

INTRODUCTION

Carpal tunnel syndrome (CTS) interferes with a patient's quality of life and has significant financial implications for patients, their employers, and the US health care system.^{1,2} CTS involves compression of the median nerve and is the most common nerve entrapment neuropathy with a prevalence of 3% to 5% in the general population.¹ Because the average age at the time of diagnosis is 45 to 60 years, CTS affects people in the workforce.¹ CTS is responsible for an average of 28 days away from work according to 2015 data from the Bureau of Labor Statistics.^{1,2} A reported 56% to 87% of those presenting with median nerve compression symptoms are diagnosed with bilateral involvement, especially patients with diabetes, hypothyroidism, obesity, and inflammatory arthritis.^{1,3,4} Carpal tunnel release (CTR) surgery incurs an estimated health care cost of \$2 billion annually in the United States,⁵ with more than 500,000 persons undergoing CTR surgery every year.⁶ Patients diagnosed with bilateral carpal tunnel syndrome (BCTS) are faced with the decision to undergo surgical intervention in a staged unilateral approach or a simultaneous bilateral approach. Studies have shown that bilateral carpal tunnel release (BCTR) is overwhelmingly more cost-effective and time-efficient than a staged unilateral approach.^{1,5,6} Bilateral hand procedures limit certain regional anesthesia techniques typically employed for unilateral upper extremity procedures, however, requiring reconsideration of more effective anesthesia options.⁷⁻⁹

METHODS

Electronic searches were conducted through MEDLINE (National Library of Medicine), CINAHL (EBSCO), and PUBMED (National Library of Medicine) for current pertinent information published in the anesthesia, hand surgery, and plastic surgery literature. The search was limited to 2012 through 2016, with the exception of large, multicenter landmark studies. Search sensitivity was increased by using the Boolean operators “OR” and “AND” to combine search categories. The words and phrases searched included the following: bilateral carpal tunnel syndrome/release, bilateral versus staged unilateral carpal tunnel release, median nerve block, regional anesthesia for bilateral hand procedures, local anesthesia with epinephrine and hand surgery, buffering of local anesthetics, general anesthesia versus regional anesthesia: cost and safety, anxiety and anesthesia, sedation, and monitored anesthesia care.

REVIEW OF THE LITERATURE

Bilateral Carpal Tunnel Release Versus Staged Unilateral Release

Surgical treatment of BCTS can be addressed in a simultaneous approach or a staged unilateral approach.^{1,4,6} The cost- and time-effectiveness of BCTR compared with staged unilateral carpal tunnel release (SCTR) has been well documented. A study evaluating cost-effectiveness published in November 2016 in the *Journal of the American Academy of Orthopedic Surgeons* showed BCTR to have a higher total effectiveness and lower cost than SCTR.⁶ A cost and time comparison study between SCTR and BCTR was also performed by Elfar et al,⁵ who reported a 22% increase in total amount billed including fees for the physician, facility, and anesthesia in the SCTR group compared with the BCTR group. The average total operating room time for SCTR procedures was 66 minutes compared with 40 minutes for BCTR procedures.⁵ Additionally, patients undergoing BCTR missed an average of 22 days from work, compared with 46 days for patients undergoing a staged unilateral approach.⁵ Physicians also benefit from the simultaneous BCTR option by requiring fewer postoperative visits (3.46 for SCTR vs 1.45 for BCTR), with higher remuneration per hour.⁴

The primary reason patients report choosing SCTR over BCTR is concern for independent postoperative self-care, whereas patients choosing BCTR over SCTR reported wanting to avoid 2 surgical procedures.¹ A prospective cohort study by Osei et al¹ conducted postoperative surveys of both SCTR and BCTR patients to compare self-care ability. The results revealed increased difficulty with household chores only during the first 2 postoperative days in the BCTR group, but no significant difference in personal hygiene performance between the groups.¹

Anesthesia Considerations for BCTR

Bilateral hand procedures limit the use of certain regional anesthesia techniques typically used for unilateral upper extremity procedures, such as brachial plexus block (BPB) and intravenous regional blocks (IVRBs).^{7,8} Local anesthesia toxicity and tourniquet pain are potential complications with these techniques.^{7,9} Postoperative concerns with these methods include bilateral motor blockade with BPB, and the lack of analgesia provided with IVRB following deflation of the tourniquet.^{7,9} Anesthesia techniques practical for consideration for BCTR are

general anesthesia, local anesthesia, and median nerve block with or without sedation.⁷⁻⁹

Both open and endoscopic surgical techniques for BCTR are considered minimally invasive procedures according to the clinical practice guidelines of the American Association of Orthopedic Surgeons.³ A pneumatic tourniquet for hemostasis has traditionally been used for this procedure, necessitating anesthesia management for tourniquet pain.^{10,11} Negating the noxious stimuli of a tourniquet eliminates the need for general anesthesia or heavy sedation, thus avoiding their associated risks and expense.¹⁰⁻¹² Costly preoperative testing may also be eliminated if general anesthesia is not indicated.^{10,11} Regional techniques and local anesthesia alternatives result in less postoperative pain and a shorter recovery room stay than general anesthesia.¹³

Within the past 10 years, wide acceptance of the use of epinephrine for hemostasis has been published in the hand surgery literature. A large multicenter prospective study conducted between 2002 and 2004 through Dalhousie University in Canada reviewed 3110 consecutive cases in which epinephrine was electively injected into the hand with no incidence of tissue loss.¹² The long-held belief that epinephrine in finger and hand surgery is contraindicated was dispelled.¹⁰⁻¹² The acceptance of epinephrine-containing local anesthetics in hand surgery enables local infiltration and median nerve block as an effective, safe anesthetic technique for BCTR.^{10,11}

Sedation and Patient Anxiety

In 2 separate patient satisfaction studies comparing patients undergoing CTR under local anesthesia only to local anesthesia with sedation, one by Rozanski et al¹⁴ and the other by Davison et al,¹⁵ the investigators found no difference in overall satisfaction with their procedure, with 93% of patients reporting satisfaction with whichever technique they received. A preponderance of available literature supporting the use of a local anesthesia only technique termed “wide awake local anesthesia no tourniquet” (WALANT) has been published by Lalonde et al.^{10-12,15} Comparison studies conducted by Lalonde’s group evaluating patient satisfaction between nonsedation and sedation techniques showed no significant differences in satisfaction; however, surgical conditions and local anesthesia techniques were not standardized between the groups.¹⁵ In the study conducted by Rozanski et al¹⁴ to specifically evaluate pain perception on injection and during the procedure between sedation and nonsedation groups, significantly higher pain on injection and during the surgery was reported in the local anesthesia only groups. Despite these findings, the authors supported the use of local anesthesia only owing to the reduced need for a thorough preoperative workup, intravenous access, intraoperative monitoring, and recovery room time compared with the sedation technique.^{14,15} Studies designed to evaluate patient satisfaction, anxiety, and comfort with equal surgical and local anesthesia techniques between sedated and nonsedated patients were not available in the reviewed literature. Patient anxiety related to regional anesthesia has been reported as primarily related to fear of pain, awareness, and not knowing what to expect.¹⁶⁻¹⁸ Preoperative consultation with patients describing the procedure, medical equipment, terminology, and postoperative expectations has been identified as a means to greatly decrease anxiety in regional anesthesia patients.¹⁶⁻¹⁸ The patient’s health status, as well as acceptance of increased pain during the injection

and procedure, are factors in proposing this regional anesthesia plan with or without sedation.^{14,15}

Comparison of Injection Technique

Two local anesthesia injection techniques have been described for carpal tunnel decompression procedures: the Altissimi and Mancini technique, in which a local anesthetic is infiltrated into the carpal tunnel to anesthetize the median nerve as well as subcutaneously for surgical analgesia, and the Gale technique, which involves only superficial infiltration without a median nerve block.^{19,20} A randomized controlled single-blinded trial reported in the *Journal of Hand Surgery* by Patil et al²⁰ evaluated analgesic levels between the 2 techniques for patients undergoing BCTR in a staged unilateral sequence separated by 4 to 8 weeks. The Gale technique was used on one hand, and the Altissimi and Mancini on the other.²⁰ Of the 20 patients evaluated, the Altissimi and Mancini technique was found to produce complete analgesia in all of the patients compared with the Gale technique, in which 30% of patients complained of intraoperative pain.²⁰ Similarly, a nonrandomized prospective interventional trial reported in the *Journal of the Institute of Medicine* by Sigdel et al¹⁹ concluded that the Altissimi and Mancini technique provides reliable intraoperative analgesia. Neither of the studies reported the incidence of median nerve injury with infiltration of the carpal tunnel.^{19,20}

Lidocaine is most commonly reported as the local anesthesia agent of choice for minor hand surgery procedures owing to its safety record compared with other local anesthesia agents.^{10,11} The addition of epinephrine to lidocaine serves to extend the block duration, acts to provide hemostasis, and raises the toxic dose limit, thus allowing for a greater volume to be used.^{10,11,15} The average duration of 1% lidocaine with 1:100,000 epinephrine is 4 to 5 hours, adequate to provide analgesia for the intraoperative and postoperative period for BCTR procedures.¹⁰ An upper limit of 7 mg/kg of lidocaine with epinephrine is widely accepted as a safe toxic dose limit allowing for ample volume of 1% lidocaine with 1:100,000 epinephrine to be used.^{10,11} The use of lidocaine with epinephrine is reported extensively as a safe local anesthesia throughout the dental and plastic surgery literature.^{10,11} Modifications to reduce pain on injection related to the initial needle stick and stinging affiliated with local anesthesia infiltration were identified in the literature reviewed. Such modifications included using a small 25- to 27-gauge needle for injection, introducing the needle perpendicularly to the skin, advancing the needle slowly behind the field of existing local anesthesia, and buffering the lidocaine with sodium bicarbonate to achieve pH normalization.²¹⁻²³ An original study by Frank and Lalonde²² concluded that 1% lidocaine with 1:100,000 epinephrine has an average pH of 4.2 to 4.7 and is reliably normalized to a target tissue pH of 7.38 to 7.62 with the addition of 1 mL 8.4% sodium bicarbonate to every 10 mL of local anesthetic (10:1 ratio).

Hands-on: Performing the Injection

For successful performance of the Altissimi and Mancini injection technique, the literature stresses the importance of reviewing the median nerve anatomy to avoid intraneural injury with a carpal tunnel injection. The median nerve becomes superficial at the distal forearm proximal to the wrist.²⁴ It

traverses the carpal tunnel, medial to the flexor carpi radialis tendon, and deep and radial to the palmaris longus (PL) tendon (**Figure 1**).²⁴ The median nerve innervates the palmar surface of the thumb, index, middle, and the lateral half of the ring finger, including the nail beds on the dorsal surface.²⁴ An atraumatic injection of the carpal tunnel can be accomplished with familiarization of median nerve anatomy (**Figure 1**),²⁴ and utilization of a 45-degree radial and distal needle angle just ulnar to the PL tendon (**Figure 2**).^{19,20,24}

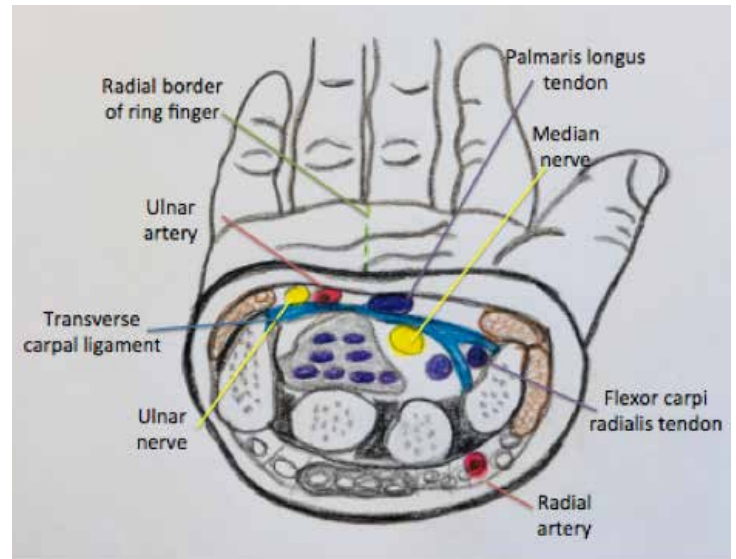


Figure 1. Cross Sectional Anatomy of Carpal Tunnel. Illustration Credit: Debar Varela, 2017.

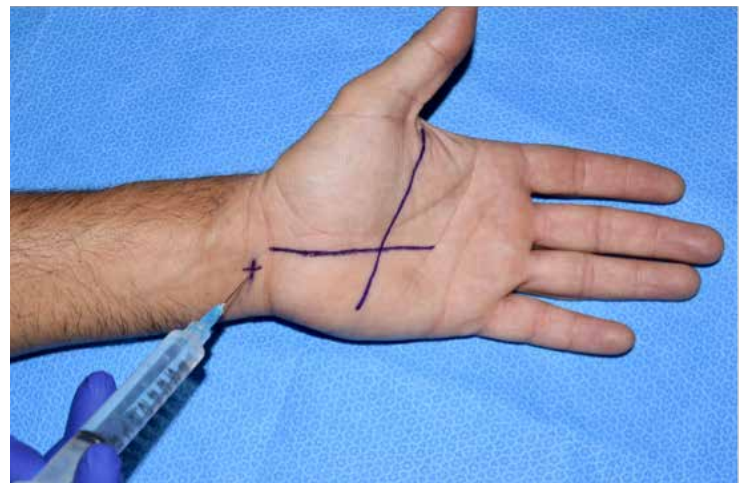


Figure 2. Modified Altissimi and Mancini^{19,20} carpal tunnel injection as described by Farhangkhoe et al²⁵ in line with the radial border of the ring finger at a 45-degree radial and distal angle. Superficial landmarks for infiltration: radial border of the ring finger from the proximal palmar crease to the distal wrist crease. The diagonal line depicts Kaplan's cardinal line, the distal most extent of an open or endoscopic carpal tunnel release, sparing the superficial palmar arch from transection.²⁶ Image credit: Debra Varela, 2016.

A modification of the Altissimi and Mancini technique, termed the “hole-in-one” technique, has been described and utilized extensively by Lalonde.²⁷ Reliable replication of the technique was highlighted in a study conducted at Dalhousie University in Canada by Farhangkhoei et al²⁵ in which 25 consecutive medical students (36%) and residents (64%) observed the injection one time and then independently demonstrated the technique on the next patient. Pain score data were collected immediately after the demonstration by asking the patient how many times pain was felt during the injection utilizing the “hole-in-one” technique.²⁵ Of the 25 patients injected, 66% felt pain on only the first stick, termed a “hole-in-one,” while 24% reported feeling 2 needle sticks, which was termed an “eagle.”²⁵ Technique standardization of the hole-in-one technique included the following. A total of 20 mL of 1% lidocaine with 1:100,000 epinephrine and 2 mL of 8.4% bicarbonate for each carpal tunnel injection was prepared.²⁷ A 27-gauge needle was first introduced in line with the ring finger at the distal wrist crease, at a 45-degree radial direction, and 10 mL was injected into the carpal tunnel for the median nerve block.^{25,27} The remaining 10 mL was infiltrated into the palm in line with the radial side of the ring finger (Figure 2),²⁶ with care given to advance the needle within the field of existing local anesthesia, avoiding needle contact with unanesthetized tissue.^{25,27} Kaplan’s cardinal line as depicted by the transverse palmar line (Figure 2) provides a reference point to the superficial palmar arterial arch. The Kaplan’s cardinal line landmark is referenced as the distal most extent of an open or endoscopic CTR by hand surgeons and ensures that the superficial palmar arch is free of transection.²⁶ The intersection of the palmar lines serves as a reference point for local infiltration for the incision site.²⁶ Pain level was described by the volunteer patient population as less than the pain experienced with local dental anesthesia by 84%, and 64% rated it as less pain than with the insertion of a 20-gauge intravenous needle used for providing sedation.²⁷ While the researchers conceded that the study may have been skewed by patients feeling obligated to support students, the technique was found to be easily replicated.²⁷

SUMMARY

The literature selected for review included descriptive nonexperimental, observational review, and case-control studies. The data supporting BCTR versus SCTR revealed cost and time savings for patients and surgeons.^{1,4-6} Documentation of the desire to perform BCTR in a simultaneous fashion and the limitations of certain anesthetic techniques with bilateral upper extremity surgeries validate the need for an efficient, evidence-based anesthesia plan.⁷⁻⁹

The acceptance of epinephrine-containing local anesthetics in the hand surgery literature has made performing hand procedures such as CTR without the use of a tourniquet possible, thereby negating the use of a pneumatic tourniquet and associated tourniquet pain.^{10-12,14,15} Much of the recent literature reviewed has cited or been authored by Lalonde and his associated researchers on the use of WALANT for hand surgeries including CTR. The cost- and time-effectiveness of WALANT has been documented in studies that compared cost, safety, and patient satisfaction.^{11,14,15,27} Lalonde et al have proposed that most CTR procedures can be performed with WALANT with resultant high patient satisfaction, improved safety, and decreased cost.^{10,11,15,21,25,27} CTR procedures in Canada are performed 90% of the time with local anesthesia only and no tourniquet.²⁷ In contrast, most CTR procedures in the United States are performed by use of a tourniquet either with sedation or with general anesthesia.²⁷

A gap in the literature was found to exist in the comparison of patient satisfaction with local anesthesia only with the same local anesthesia technique with sedation with regard to decreased anxiety and increased satisfaction with simultaneous BCTR procedures. Additionally, studies designed to quantify the level and type of sedation as related to patient satisfaction with CTR surgery were lacking. While expense and efficiency are important driving factors, patient comfort and psychological well-being are equally important considerations. Factors increasing anxiety in patients undergoing local anesthesia were addressed in a study by Caddick et al,¹⁶ who found that aside from obvious factors such as fear of pain, the use of “surgical jargon” and the operating room environment itself contribute to anxiety. Caddick et al¹⁶ suggested that an increase in patient anxiety during the perioperative period has an overall negative impact on patient recovery. Attempts to reduce the stressful aspects of the operative process could therefore result in a positive psychological and physical response to surgery.¹⁶

As local and regional anesthetic techniques are used more frequently with outpatient surgical procedures, consideration of factors beyond analgesia having an impact on patient comfort is required.^{17,18} Each patient is an individual, and a simple procedure in the eyes of one patient may result in emotional distress in another.¹⁷ Formulation of the anesthesia plan and preoperative consultation should be individualized according to the patient’s physical health and psychological needs.^{17,18} Future research into the effect of local anesthesia and median nerve block with sedation on anxiety and satisfaction with BCTR could add valuable information for anesthesia providers caring for these patients.

REFERENCES

1. Osei DA, Calfee RP, Stepan JG, Boyer MI, Goldfarb CA, Gelberman RH. Simultaneous bilateral or unilateral carpal tunnel release? A prospective cohort study of early outcomes and limitations. *J Bone Joint Surg Am.* 2014;96(11):889-896. <https://doi.org/10.2106/JBJS.M.00822>.
2. Bureau of Labor Statistics. Nonfatal Occupational Injuries and Illnesses Requiring Days Away From Work, 2015. US Department of Labor website. <http://www.bls.gov/news.release/pdf/osh2.nr0.htm>. Published November 10, 2016. Accessed November 16, 2016.
3. Keith MW, Masear V, Chung KC, et al. American Academy of Orthopaedic Surgeons clinical practice guideline on the treatment of carpal tunnel syndrome. *J Bone Joint Surg Am.* 2010;92(1):218-219. <https://doi.org/10.2106/JBJS.I.00642>.
4. Phillips P, Kennedy J, Lee T. Cost effective analysis of simultaneous versus staged bilateral carpal tunnel release. Presented at: American Association of Hand Surgeons Annual Meeting; January 21-25, 2015; Paradise Island, Bahamas. <http://meeting.handsurgery.org/abstracts/2015/104.cgi>.
5. Elfar JC, Foad MB, Foad SL, Stern PJ. A cost analysis of staged and simultaneous bilateral carpal tunnel release. *Hand (NY).* 2012;7(3):327-332. <https://doi.org/10.1007/s11552-012-9436-y>.
6. Park KW, Boyer MI, Gelberman RH, Calfee RP, Stepan JG, Osei DA. Simultaneous bilateral versus staged bilateral carpal tunnel release: a cost-effectiveness analysis. *J Am Acad Orthop Surg.* 2016;24(11):796-804. <https://doi.org/10.5435/JAAOS-D-15-00620>.
7. Sørensen AM, Dalsgaard J, Hansen TB. Local anaesthesia versus intravenous regional anaesthesia in endoscopic carpal tunnel release: a randomized controlled trial. *J Hand Surg Eur Vol.* 2013;38(5):481-484. <https://doi.org/10.1177/1753193412453664>.
8. Holborow J, Hocking G. Regional anaesthesia for bilateral upper limb surgery: a review of challenges and solutions. *Anaesth Intensive Care.* 2010;38(2):250-258.
9. Chalidis BE, Dimitriou CG. One portal simultaneous bilateral endoscopic carpal tunnel release under local anaesthesia. Do the results justify the effort? *Int Orthop.* 2013;37(8):1501-1505. <https://doi.org/10.1007/s00264-013-1951-0>.
10. Al Youha S, Lalonde DH. Al Youha S, Lalonde DH. Update/Review: changing of use of local anesthesia in the hand. *Plast Reconstr Surg Glob Open.* 2014;2(5):e150. <https://doi.org/10.1097/GOX.0000000000000095>.
11. Lalonde D, Martin A. Epinephrine in local anesthesia in finger and hand surgery: the case for wide-awake anesthesia. *J Am Acad Orthop Surg.* 2013;21(8):443-447. <https://doi.org/10.5435/JAAOS-21-08-443>.
12. Lalonde D, Bell M, Benoit P, Sparkes G, Denkler K, Chang P. A multicenter prospective study of 3,110 consecutive cases of elective epinephrine use in the fingers and hand: the Dalhousie Project clinical phase. *J Hand Surg Am.* 2005;30(5):1061-1067. <https://doi.org/10.1016/j.jhsa.2005.05.006>.
13. Corey JM, Bulka CM, Ehrenfeld JM. Is regional anesthesia associated with reduced PACU length of stay? A retrospective analysis from a tertiary medical center. *Clin Orthop Relat Res.* 2014;472(5):1427-1433. <https://doi.org/10.1007/s11999-013-3336-5>.
14. Rozanski M, Neuhaus V, Reddy R, Jupiter JB, Rathmell JP, Ring DC. An open-label comparison of local anesthesia with or without sedation for minor hand surgery. *Hand (NY).* 2014;9(4):399-405. <https://doi.org/10.1007/s11552-014-9670-6>.
15. Davison PG, Cobb T, Lalonde DH. The patient's perspective on carpal tunnel surgery related to the type of anesthesia: a prospective cohort study. *Hand (NY).* 2013;8(1):47-53. <https://doi.org/10.1007/s11552-012-9474-5>.
16. Caddick J, Jawad S, Southern S, Majumder S. The power of words: sources of anxiety in patients undergoing local anaesthetic plastic surgery. *Ann R Coll Surg Engl.* 2012;94(2):94-98. <https://doi.org/10.1308/003588412X13171221501267>.
17. Ruspantine P. The preoperative anesthesia evaluation--revisited. *AANA J.* 2015;83(2):83-84.
18. Mitchell M. Influence of gender and anaesthesia type on day surgery anxiety. *J Adv Nurs.* 2012;68(5):1014-1025. <https://doi.org/10.1111/j.1365-2648.2011.05801.x>.
19. Sigdel A, Uprety S, Govind KC. Modified Altissimi and Mancini technique for carpal tunnel decompression. *Journal of Institute of Medicine.* 2012;34(1):9-12. <http://dx.doi.org/10.3126/joim.v34i1.9116>
20. Patil S, Ramakrishnan M, Stothard J. Local anaesthesia for carpal tunnel decompression: a comparison of two techniques. *J Hand Surg Br.* 2006;31(6):683-686. <https://doi.org/10.1016/J.JHSB.2006.08.008>.
21. Strazar AR, Leynes PG, Lalonde DH. Minimizing the pain of local anesthesia injection. *Plast Reconstr Surg.* 2013;132(3):675-684. <https://doi.org/10.1097/PRS.0b013e31829ad1e2>.
22. Frank SG, Lalonde DH. How acidic is the lidocaine we are injecting, and how much bicarbonate should we add? *Can J Plast Surg.* 2012;20(2):71-73. <https://doi.org/10.1177/229255031202000207>.

23. Salati SA. Minimizing the pain in local anesthesia injection-a review. *J Pak Assoc Dermatol*. 2016;26(2):138-43.
24. Bodle, Ethan E. "Median Nerve Block." Overview, Indications, Contraindications 4 Sept. 2015, emedicine.medscape.com/article/1369028-overview. Accessed November 16, 2016.
25. Farhangkhoe H, Lalonde J, Lalonde DH. Teaching medical students and residents how to inject local anesthesia almost painlessly. *Can J Plast Surg*. 2012;20(3):169-172. <https://doi.org/10.1177/229255031202000315>.
26. Panchal AP, Trzeciak MA. The Clinical Application of Kaplan's cardinal line as a surface marker for the superficial Palmar arch. *Hand (NY)*. 2010;5(2):155-159. <https://doi.org/10.1007/s11552-009-9229-0>.
27. Lalonde DH. "Hole-in-one" local anesthesia for wide-awake carpal tunnel surgery . *Plast Reconstr Surg*. 2010;126(5):1642-1644. <https://doi.org/10.1097/PRS.0b013e3181f1c0ef>.