



THE AGA KHAN UNIVERSITY

eCommons@AKU

---

Section of Dental-Oral Maxillofacial Surgery

Department of Surgery

---

April 2019

# Association between variations In sella turcica dimensions and morphology and skeletal malocclusions

Erum Afzal

*Aga Khan University*, [erum.afzal@aku.edu](mailto:erum.afzal@aku.edu)

Mubassar Fida

*Aga Khan University*, [mubassr.fida@aku.edu](mailto:mubassr.fida@aku.edu)

Follow this and additional works at: [https://ecommons.aku.edu/pakistan\\_fhs\\_mc\\_surg\\_dent\\_oral\\_maxillofac](https://ecommons.aku.edu/pakistan_fhs_mc_surg_dent_oral_maxillofac)

---

## Recommended Citation

Afzal, E., Fida, M. (2019). Association between variations In sella turcica dimensions and morphology and skeletal malocclusions. *Journal of Ayub Medical College, Abbottabad*, 31(2), 172-177.

**Available at:** [https://ecommons.aku.edu/pakistan\\_fhs\\_mc\\_surg\\_dent\\_oral\\_maxillofac/104](https://ecommons.aku.edu/pakistan_fhs_mc_surg_dent_oral_maxillofac/104)

## ORIGINAL ARTICLE

## ASSOCIATION BETWEEN VARIATIONS IN SELLA TURCICA DIMENSIONS AND MORPHOLOGY AND SKELETAL MALOCCLUSIONS

Erum Afzal, Mubassar Fida

The Aga Khan University Hospital Karachi-Pakistan

**Background:** The growth of sella turcica is completed early in life, therefore it can be used as a stable landmark for the prediction of future skeletal malocclusions. This early diagnosis may help in planning less complicated treatment modalities. Therefore, this study aimed to evaluate the relationship between sella turcica dimensions and morphology with various skeletal patterns. **Methods:** A cross sectional study was conducted using the pre-treatment cephalograms of 180 subjects aged 13–19 years. The subjects were divided into two groups based on skeletal patterns. The dimensions of sella turcica and skeletal patterns were digitally measured using View Pro-X software. One-way ANOVA was applied to compare sella turcica dimensions among skeletal patterns. Sella dimensions and vertical growth patterns were compared using Post-hoc Tukey test. Chi-square test was applied to compare sella morphology among malocclusion groups. Results were taken as statistically significant at  $p$ -value of  $\leq 0.05$ . **Results:** Sella dimensions showed insignificant differences among sagittal groups whereas, significant differences were found for sella length ( $p \leq 0.02$ ) and depth ( $p \leq 0.03$ ) among the vertical groups. Multiple comparisons showed significant differences between sella length ( $p \leq 0.03$ ) and diameter ( $p \leq 0.04$ ) between normodivergent versus hyperdivergent groups. Moreover, significant differences were found in the sella turcica morphology among sagittal malocclusion ( $p \leq 0.03$ ). **Conclusions:** Increased dimensions of sella turcica were associated with hyperdivergent growth pattern. Bridging of the sella turcica was found to be prevalent in class III malocclusion.

**Keywords:** Sella Turcica; Maxillofacial Development; Vertical Dimension; Malocclusion

**Citation:** Afzal E, Fida M. Association between Variations in Sella Turcica Dimensions and Morphology and Skeletal Malocclusions. J Ayub Med Coll Abbottabad 2019;31(2):172–7.

## INTRODUCTION

The attractiveness of the face depends on harmonious relationships of craniofacial structures.<sup>1</sup> It is imperative to diagnose the disharmony in the stomatognathic system, reestablish function and improve overall facial appearance. A balanced facial profile has well-proportioned underlying skeletal structures. Any discrepancy between maxillary and mandibular bony bases may result in sagittal or vertical dysplasia.<sup>2</sup>

The prediction of direction and magnitude of facial growth before the onset of pubertal spurt can be a valuable asset and the resulting skeletal disharmony can be balanced as stated in the functional paradigm.<sup>3,4</sup> Early identification of developing skeletal malocclusions allows conservative orthopedic management.<sup>5,6</sup> In the past, various parameters have been proposed by investigators for the prediction of facial growth patterns. Bjork's<sup>7</sup> implant study proposed structural signs for the interpretation of mandibular rotations. Huggare<sup>8</sup> correlated the anatomy of cervical vertebrae with future divergence pattern. Other authors<sup>3,9,10</sup> have recommended the craniocervical angle, antegonial notch and frontal sinus as predictors

of future facial growth pattern. The sella turcica has also been investigated to determine whether it can forecast the development of skeletal malocclusion.<sup>11,12</sup>

Sella turcica, a saddle shaped concavity, is an important structure of the neurocranium bounded anteriorly by tuberculum sellae and posteriorly by dorsum sellae.<sup>13</sup> In orthodontics, the sella turcica serves as an anatomical reference to evaluate craniofacial growth and treatment changes by serial superimpositions.<sup>14</sup> The growth of sella turcica is completed in early childhood and various studies have used sella turcica dimensions and morphology to predict the facial growth and direction.<sup>15–18</sup> Alkofide<sup>11</sup> reported a larger diameter of the sella turcica in subjects with skeletal class III malocclusion as compared to class I and II. Similarly, Luong *et al*<sup>17</sup> stated increased transverse width and volume of the sella turcica in class III subjects as compared to class I and class II subjects. Meyer-Marcotty *et al*<sup>19</sup> found that sella turcica bridging is significantly associated with skeletal class III malocclusion.

The association between sella turcica dimension and morphology and skeletal malocclusions will help in early diagnosis of these skeletal patterns increasing the probability of

interceptive management. This may also reduce the future treatment burden and may lead to less complicated treatment modalities. Therefore, the aim of this study was to investigate the association of sella turcica dimensions and morphology with different facial growth patterns.

## MATERIAL AND METHODS

We conducted a cross-sectional study from September to October 2017 at the dental clinics of The Aga Khan University Hospital Karachi. Data were collected after screening the diagnostic records of 730 patients presenting for orthodontic treatment since 2013 till 2017. The sample size was calculated using OpenEpi Software with the findings of Yasa *et al.*<sup>20</sup> They reported mean depth of the sella turcica to be 8.91±1.11 mm in normodivergent individuals and 7.96±1.2 mm in hyperdivergent individuals. The alpha was set at 0.05 and power as 80%, giving us the sample size of 24 subjects in each group. We inflated this number to include a minimum of 30 subjects per subgroup. The sample was divided into two groups based on sagittal and vertical skeletal patterns. The sagittal group was further divided into class I, class II and class III subgroups based on the ANB angle and the vertical group into normodivergent, hypodivergent and hyperdivergent subgroups based on the sella-nasion to gonion-gnathion (SN-GoGn) angle.<sup>21</sup> This resulted in a total sample size of 180 subjects which were selected using non probability consecutive sampling. Male and female subjects were equally included in each subgroup to eliminate gender bias. Exemption was taken from the ethical review committee (ERC No.4939-17) preceding the study.

Subjects of Pakistani origin, aged 13–19 years with standardized pretreatment lateral cephalograms, no past orthodontic treatment or traumatic injuries were included in this study. Subjects with pathologies or corrective surgery in the craniofacial region were excluded. During selection of subjects in the sagittal groups, normodivergent subjects were recruited. Similarly, for the vertical group, class I subjects were selected. This was done to homogenize the subjects within the groups and reduce the number of variables which may affect the results.

Lateral cephalograms were recorded with head fixation parallel to the horizontal plane at 165 cm film to tube distance for the standardization of lateral cephalograms by trained technicians. The subjects were asked to bite in centric occlusion with their lips relaxed during the exposure using Orthoralix 9200 (Gendex–KaVo, Milan, Italy). The sella turcica was assessed on digitized lateral cephalograms using View Pro-X software (Rogan-

Delft, Veenendaal, The Netherlands) for precision and accuracy. Dimensions of the sella turcica were analyzed using the method proposed by Silverman<sup>22</sup> (Figure-1). Sella morphology was assessed according to the classification by Axelsson *et al.*<sup>23</sup> who have reported multiple variants of sella turcica (Figure-2). We only included subjects with complete osseous bridging of the sella turcica.<sup>19</sup>

SPSS-20 was used for data analysis. For continuous variables such as age, diameter, length and depth of sella turcica in each vertical and sagittal pattern, means and standard deviations were reported. The Shapiro Wilk test showed a normal distribution, hence parametric tests were applied. The sella turcica measurements in sagittal and vertical malocclusions between genders were tested using the independent sample *t*-test which showed non-significant differences, therefore results were not stratified accordingly. Sella turcica dimensions between different vertical and sagittal growth patterns were compared using the one-way analysis of variance (ANOVA). Post-hoc Tukey test was applied to compare sella turcica dimensions in vertical malocclusions. Sella turcica morphology was compared using Chi square test among different sagittal and vertical malocclusion groups. Results were taken as statistically significant at *p*-value  $\leq 0.05$ .

To assess intra-operator reliability, we randomly selected 30 lateral cephalograms which were digitally re-measured using an identical methodology after three weeks by the principal investigator. The intra-class correlation coefficient (ICC) showed values ranging from 0.85 and 1.00 between the two sets of measurements showing excellent agreement.

## RESULTS

The mean age of subjects was 16.3±2.7 years. Non-significant differences were found among sagittal subgroups with sella length ( $p=0.42$ ), diameter ( $p=0.99$ ) and depth ( $p=0.73$ ). (Table-1) Sella morphology among sagittal patterns revealed significant differences ( $p=0.03$ ). Furthermore, 50% of class III subjects were seen to have sella bridging. (Table-2)

The mean age of subjects was 15.8±2.5 years. Significant differences were found with sella turcica length ( $p=0.02$ ) and depth ( $p=0.03$ ) among the three vertical patterns. (Table-3a) Post-hoc Tukey showed significant differences in sella length ( $p=0.03$ ) and diameter ( $p=0.04$ ) between normo vs hyperdivergent vertical pattern. (Table-3b) Non-significant differences were found between sella morphology and vertical patterns ( $p=0.13$ ). (Table-4)

**Table-1: Sella turcica dimensions among sagittal malocclusion**

Sella dimension (mm)	Sagittal Malocclusion (n=90)			p-value*
	Class I (n=30) Mean±SD	Class II (n=30) Mean±SD	Class III (n=30) Mean±SD	
Length	6.1±1.8	6.6±1.9	5.9±2.3	0.42
Diameter	9.6±1.6	9.7±1.5	9.7±1.3	0.99
Depth	7.6±1.5	7.6±1.1	7.8±1.3	0.73

One-way ANOVA. n=90; \*p<0.05

**Table-2: Association of sella turcica morphology and sagittal malocclusion group**

Sella Morphology	Sagittal Malocclusion			p-value*	Freq. (%)
	Class I (%)	Class II (%)	Class III (%)		
Normal	36.6	43.3	33.3	0.032*	37.8
Oblique Anterior Wall	6.6	3.3	10		6.6
Irregularity	6.6	6.6	3.3		5.5
Bridging	36.6	13.3	50		33.3
Doubling of floor	13.3	16.6	0		10
Pyramidal shape	0	16.6	3.3		6.6

Chi Square test. n=90. \*p<0.05

**Table-3: Sella turcica dimensions among vertical malocclusion**

Sella dimensions (mm)	Vertical Malocclusion (n=90)			p-value*
	Normodivergent (n=30) Mean±SD	Hyperdivergent (n=30) Mean±SD	Hypodivergent (n=30) Mean±SD	
Length	6.6±1.9	8.0±2.3	7.7±1.7	0.02*
Diameter	9.6±1.0	10.5±1.4	9.7±1.4	0.54
Depth	7.0±1.1	7.3±1.5	6.9±1.6	0.03*

One-way ANOVA. n=90; \*p<0.05

**Table-4: Multiple comparisons among vertical malocclusion**

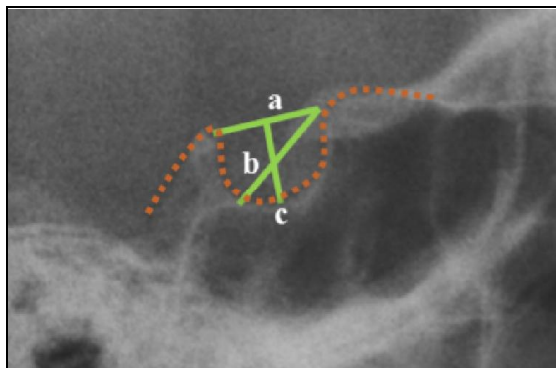
Sella dimensions (mm)	Normo-Hyper	Hypo-Hyper	Normo-Hypo
Length	0.03*	0.88	0.09
Diameter	0.04*	0.07	0.96
Depth	0.72	0.53	0.94

Post-hoc Tukey test. n=90. \*p<0.05

**Table-5: Association of sella turcica morphology and vertical malocclusion group**

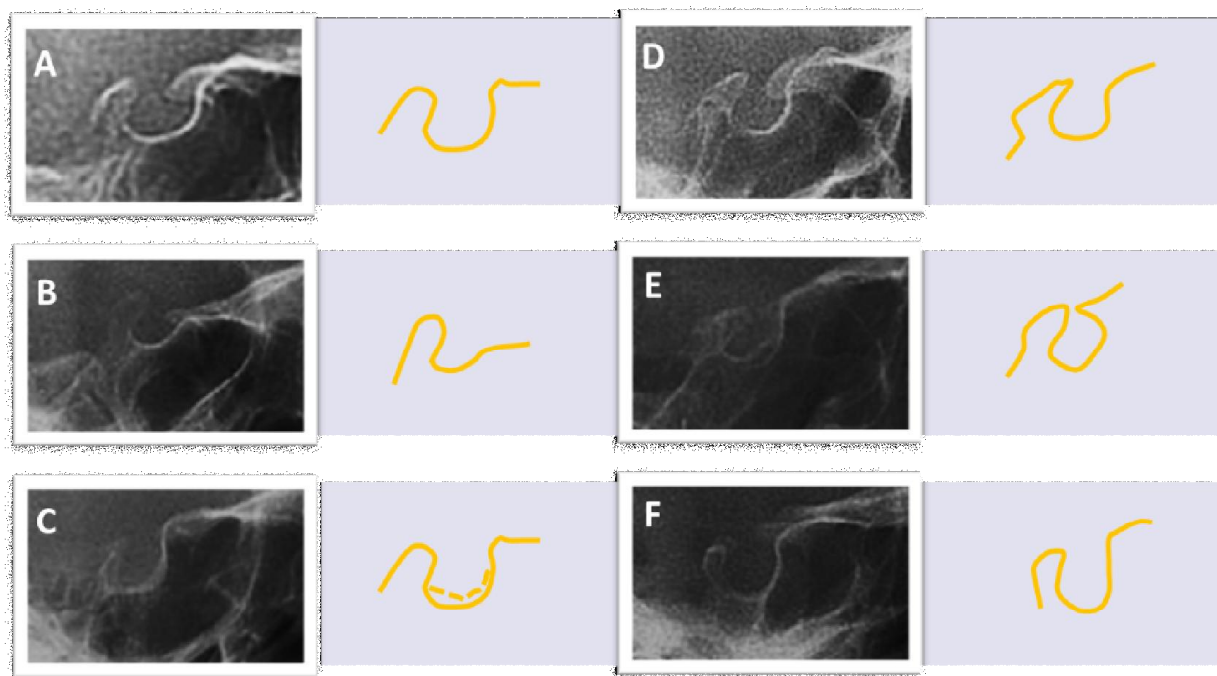
Sella Morphology	Vertical Malocclusion			p-value*	Freq. (%)
	Normodivergent (%)	Hyperdivergent (%)	Hypodivergent (%)		
Normal	26.7	33.3	56.6	0.134	38.8
Oblique Anterior Wall	16.6	16.6	16.6		16.6
Irregularity	10	3.3	0		4.4
Bridging	20	10	16.6		15.5
Doubling of floor	16.6	16.6	16.6		14.4
Pyramidal shape	10	20	0		10

Chi Square test. n=90. \*p<0.05



- a. Sella turcica length:**  
Distance from the tip of the dorsum sellae to the tuberculum sellae.
- b. Sella turcica depth:**  
A line dropped perpendicular from the length to the deepest point on the sella floor.
- c. Sella turcica diameter:**  
Distance from the tip of the tuberculum sellae to the farthest point on the posterior wall of the hypophyseal fossa.

**Figure-1: Dimensions of Sella Turcica<sup>22</sup>**



**Figure-2: Morphology of Sella Turcica<sup>23</sup>**

(A) Normal, (B) Oblique anterior wall, (C) Doubling of floor, (D) Irregularity in dorsum sella, (E) Bridging of sella turcica, (F) Pyramidal shape.

## DISCUSSION

Malformations in the facial area have been associated with abnormalities of the sella turcica which can be attributed to the fact that the craniofacial complex is primarily derived by migration of neural crest cells (NCC) to branchial arches.<sup>15,24</sup> The NCC migrate from the tuberculum sellae to the frontonasal, maxillary and palatine fields through the sonic hedgehog (SHH) gene pathway.<sup>15</sup> Point mutations in the signaling pathway may result in deformities in the craniofacial region.<sup>24</sup> Due to a common embryological origin, alterations in the sella turcica dimensions and morphology may be linked to skeletal aberrations.<sup>24</sup> Thus the focus of this study was to find an association between sella turcica size and shape with skeletal malocclusions and to use it as a predictor of facial growth patterns.

Our results showed the greatest sella turcica depth and diameter in class III malocclusion. Growth studies have shown that in patients with class III malocclusion, the continued growth of the posterior cranial base displaces the posterior wall of sella turcica in the caudal direction resulting in an increased depth and diameter of sella turcica.<sup>15,25</sup> In comparison, class II subjects in our study were found to have an increased length of sella. Studies of craniofacial development concluded that an increased growth of the anterior cranial base leads to class II malocclusion and may be the cause of increased length of the sella turcica.<sup>25-27</sup> There is a lack of

consensus between the association of the sella turcica's linear dimensions with sagittal skeletal relationships in literature.<sup>28-30</sup> A study conducted on the Iranian population reported a greater length of sella in class III individuals.<sup>31</sup> In contrast, a few studies have stated no significant differences in linear dimensions of sella turcica among sagittal malocclusions.<sup>11,17,19</sup>

In vertical malocclusions we found all the dimensions of sella turcica to be increased in hyperdivergent subjects with significant differences in sella length and depth as compared to normodivergent and hypodivergent growth patterns. Moreover, statistically significant differences in sella turcica length and diameter of normo vs hyperdivergent subjects were found. This may be attributed to the fact that an excessive growth of the posterior cranial fossa may cause hyperdivergence as it articulates with the mandible through the temporomandibular joint.<sup>25</sup> Therefore, an individual expressing greater vertical growth may have greater sella turcica depth and diameter.<sup>15,25</sup> A study conducted by Yasa *et al*,<sup>20</sup> has shown a greater diameter in hypodivergent and hyperdivergent subjects and only depth was increased in hyperdivergent subjects. In contrast, Rohria and Jain<sup>32</sup> reported no significant differences in sella turcica dimensions among vertical growth patterns.

Furthermore, we found 37.8% of subjects to have normal sella morphology in the sagittal group. Our results diverge from those of Alkofide<sup>11</sup> who

reported 67% of the Saudi population has normal sella morphology. Valizadeh *et al.*,<sup>29</sup> conducted a study on the Iranian population and found 24.4% of subjects with normal sella turcica morphology. In the vertical group, 38.8% of individuals in our study had normal sella morphology. A non-significant difference was found in sella turcica morphology and vertical malocclusion. In contrast, Yasa *et al.*,<sup>20</sup> observed 58% of subjects had normal sella shape and 18.7% of hypodivergent individuals had sella turcica bridging, whereas we found 58% of hypodivergent subjects had normal sella shape. The variation in results may be due to differences in the study populations.

Sella turcica morphology was found to be significant among sagittal malocclusions in our study. Literature have revealed a close relationship between sella turcica bridging and maxillomandibular skeletal discrepancies.<sup>33,34</sup> We observed that 50% of class III subjects had sella turcica bridging whereas Valizadeh *et al.*,<sup>29</sup> found this figure to be 43.3%. This is in contrast to the results stated by various other authors, as they reported no significant difference in sella turcica morphology and various sagittal growth patterns.<sup>19,34</sup> This inconsistency may be due to differences in the severity of skeletal malocclusion among racial groups.

A significant association was identified between sella turcica dimensions with hyperdivergent pattern and morphology with class III malocclusion. As class III and hyperdivergent growth patterns are the most challenging to control orthodontically, early identification and intervention can definitely help prevent complex treatment modalities in adulthood.<sup>35,36</sup> For example, high pull headgear can be used to control vertical development and its efficacy has been associated with early intervention.<sup>36</sup> Class III skeletal growth can be managed with chin cup wear to help control mandibular body length or with facemask to stimulate maxillary growth.<sup>35</sup>

This study used sella turcica which is an easily identifiable anatomical structure on lateral cephalogram and considered to be reliable and reproducible. Moreover, the study identifies that an altered morphology of the sella turcica in class III subjects and its increased dimensions in the hyperdivergent group can help alert the clinician to take conservative steps to prevent worsening of a developing skeletal malocclusions. This was a single center study which evaluated changes of sella turcica on a two dimensional radiograph at one point in time. We recommend a longitudinal study design with volumetric assessment of sella turcica using three dimensional imaging modality to reliably predict developing skeletal malocclusions.

## CONCLUSIONS

This study was designed to investigate the association of sella dimensions and morphology between the different facial growth patterns. Based on the results, it can be concluded that sella turcica dimensions are significantly associated with various vertical patterns. Increased dimensions of sella turcica were found in hyperdivergent growth pattern. Moreover, significant differences were seen among sella turcica morphology and various sagittal patterns with sella turcica bridging to be more prevalent in class III malocclusion.

**Conflict of Interest:** None

## AUTHORS' CONTRIBUTION

EA & MB: Contributed equally in conceptualization of the study and its design. EA: Conducted data collection and analysis. Data interpretation, write-up and proof reading was carried out by both the authors.

## REFERENCES

1. Nanda RS, Ghosh J. Facial soft tissue harmony and growth in orthodontic treatment. *Semin Orthod* 1995;1(2):67–81.
2. Downs WB. Variations in facial relationships: their significance in treatment and prognosis. *Am J Orthod* 1948;34(10):812–40.
3. Kolodziej RP, Southard TE, Southard KA, Casco JS, Jakobsen JR. Evaluation of antegonial notch depth for growth prediction. *Am J Orthod Dentofacial Orthop* 2002;121(4):357–63.
4. Moss ML. A theoretical analysis of the functional matrix. *Acta Biotheor* 1968;18(1):195–202.
5. Baccetti T, Franchi L, Toth LR, McNamara JA. Treatment timing for Twin-block therapy. *Am J Orthod Dentofacial Orthop* 2000;118(2):159–70.
6. Merwin D, Ngan P, Hagg U, Odont D, Yiu C, Wei SH. Timing for effective application of orthopedic force to the maxilla of anteriorly directed. *Am J Orthod Dentofacial Orthop* 1997;112(3):292–9.
7. Skieller V, Björk A, Linde-Hansen T. Prediction of mandibular growth rotation evaluated from a longitudinal implant sample. *Am J Orthod* 1984;86(5):359–70.
8. Huggare J. Association between morphology of the first cervical vertebra, head posture, and craniofacial structures. *Eur J Orthod* 1991;13(6):435–40.
9. Solow B, Siersbaek-Nielsen S. Cervical and craniocervical posture as predictors of craniofacial growth. *Am J Orthod Dentofacial Orthop* 1992;101(5):449–58.
10. Rossouw PE, Lombard CJ, Harris AM. The frontal sinus and mandibular growth prediction. *Am J Orthod Dentofacial Orthop* 1991;100(9):542–6.
11. Alkofide EA. The shape and size of the sella turcica in skeletal class I, class II, and class III Saudi subjects. *Eur J Orthod* 2007;29(5):457–63.
12. Yasa Y, Ocak A, Bayrakdar IS, Duman SB, Gumussoy I. Morphometric analysis of sella turcica using cone beam computed tomography. *J Craniofac Surg* 2017;28(1):70–4.
13. Bonneville JF, Dietemann JL. Radiology of the sella turcica. Springer Science & Business Media; 2012.
14. Houston WJ, Lee RT. Accuracy of different methods of radiographic superimposition on cranial base structures. *Eur J Orthod* 1985;7(2):127–35.
15. Kjaer I. Sella turcica morphology and the pituitary gland—a new contribution to craniofacial diagnostics based on

- histology and neuroradiology. Eur J Orthod 2012;37(1):28–36.
16. Björk A. Cranial base development: a follow-up x-ray study on the individual variation in growth occurring between the ages of 12 and 20 years and its relation to brain case and face development. Am J Orthod. 1955;41(3):198–225.
  17. Luong HM, Ahn JH, Bollu P, Chenin D, Chaudry K, Pourhamidi J. Sella turcica variations in skeletal class I, class II and class III adult subjects: a CBCT study. J Dent Oral Biol 2016;1(3):1–6.
  18. Abdel-Kader HM. Sella turcica bridges in orthodontic and orthognathic surgery patients. a retrospective cephalometric study. Aust Dent J 2007;23(1):30–5.
  19. Meyer-Marcotty P, Reuther T, Stellzig-Eisenhauer A. Bridging of the sella turcica in skeletal class III subjects. Eur J Orthod 2010;32(2):148–53.
  20. Yaşa Y, Büyük SK, Benkli YA, Arslan A, Topbaşı NM. The size and shape of the sella turcica in adolescent orthodontic patients with different vertical growth patterns. Clin Dent Res 2017;41(1):3–9.
  21. Steiner CC. Cephalometrics in clinical practice. Angle Orthod 1959;29:8–29.
  22. Silverman FN. Roentgen standards fo-size of the pituitary fossa from infancy through adolescence. Am J Roentgenol Radium Ther Nucl Med 1957;78(3):451–60.
  23. Axelsson S, Storhaug K, Kjær I. Post-natal size and morphology of the sella turcica. Longitudinal cephalometric standards for Norwegians between 6 and 21 years of age. Eur J Orthod 2004;26(6):597–604.
  24. Cordero DR, Brugmann S, Chu Y, Bajpai R, Jame M, Helms JA. Cranial neural crest cells on the move: their roles in craniofacial development. Am J Medical Genet A 2011;155A(2):270–9.
  25. Chin A, Perry S, Liao C, Yang Y. The relationship between the cranial base and jaw base in a Chinese population. Head Face Med 2014;10:31.
  26. Kerr WJ, Adams CP. Cranial base and jaw relationship. Am J Phys Anthropol 1988;77(2):213–20.
  27. Jarvinen S. Saddle angle and maxillary prognathism: a radiological analysis of the association between the NSAr and SNA angles. Brit J Orthod 1984;11(4):209–13.
  28. Soakar PC, Nawale S. The comparative study of size of sella turcica in different skeletal types in local population-an in vitro study. Indian J Appl Res 2014;4(10):160–2.
  29. Valizadeh S, Shahbeig S, Mohseni S, Azimi F, Bakhshandeh H. Correlation of shape and size of sella turcica with the type of facial skeletal class in an Iranian group. Iran J Radiol 2015;12(3):e16059.
  30. Shah AM, Bashir U, Ilyas T. The shape and size of the sella turcica in skeletal class I, II and III in patients presenting at Islamic International Dental Hospital, Islamabad. Pak Oral Dent J 2011;31(1):104–10.
  31. Moslemzadeh SH, Moghaddam N, Moghaddam SF, Raffighi A, Ghojatzadeh M, Rasouli F. Relationship between bridging and dimensions of sella turcica and antero-posterior skeletal malocclusions in children. Iran J Orthod 2016;11(2):e5738.
  32. Rohria R, Jain S. Sellar dimension in skeletal class II subjects with different growth patterns. J Pierre Fauchard Acad 2015;29(1):26–31.
  33. Jones RM, Faqir A, Millett DT, Moos KF, McHugh S. Bridging and dimensions of sella turcica in subjects treated by surgical-orthodontic means or orthodontics only. Angle Orthod 2005;75(5):714–8.
  34. Marşan G, Öztaş E. Incidence of bridging and dimensions of sella turcica in class I and III Turkish adult female patients. World J Orthod 2009;10(2):99–103.
  35. Takada K, Petdachai S, Sakuda M. Changes in dentofacial morphology in skeletal class III children treated by a modified maxillary protraction headgear and a chin cup: a longitudinal cephalometric appraisal. Eur J Orthod 1993;15(3):211–21.
  36. Sankey WL, Buschang PH, English J, Owen AH 3rd. Early treatment of vertical skeletal dysplasia: the hyperdivergent phenotype. Am J Orthod Dentofacial Orthop 2000;118(3):317–27.

Submitted: 19 April, 2018

Revised: 19 June, 2018

Accepted: 2 November, 2018

### Address for Correspondence:

Mubassar Fida, The Aga Khan University Hospital Karachi-Pakistan

Cell: +92 345 227 7584

Tel: +92 21-34861013-14, 34864755

Email: mubassar.fida@aku.edu