

Masthead Logo

eCommons@AKU

Section of Neurosurgery

Department of Surgery

March 2019

Choice of therapeutic anti-seizure medication in patients with brain tumour

Altaf Ali Laghari

Aga Khan University, altaf.laghari@aku.edu

Syed Ijlal Ahmed

Aga Khan University

Namra Qadeer

Aga Khan University

Muhammad Shahzad Shamim

Aga Khan University, shahzad.shamim@aku.edu

Follow this and additional works at: https://ecommons.aku.edu/pakistan_fhs_mc_surg_neurosurg

Recommended Citation

Laghari, A. A., Ahmed, S. I., Qadeer, N., Shamim, M. (2019). Choice of therapeutic anti-seizure medication in patients with brain tumour. *Journal of Pakistan Medical Association*, 69(3), 442-444.

Available at: https://ecommons.aku.edu/pakistan_fhs_mc_surg_neurosurg/186

Choice of therapeutic anti-seizure medication in patients with brain tumour

Altaf Ali Laghari,¹ Syed Ijlal Ahmed,² Namra Qadeer,³ Muhammad Shahzad Shamim⁴

Abstract

Seizures are common in patients with brain tumours, even though prophylactic anti-seizure treatment for all patients with brain tumours is not recommended. Newer anti-epileptic drugs have shown benefits that outweigh the side effects of treatment and can also be given in combination with traditional anti-epileptic drugs. The authors have reviewed the literature on the various combinations of anti-epileptics in patients with seizures and brain tumours.

Keywords: Seizures, anti-epileptic drugs, brain tumours.

Introduction

Seizures may be the presenting symptom of a brain tumour, which is reported in a substantial number of patients, especially those with intra-axial, supratentorial brain tumours. It is postulated that the tissue in and around brain tumours may exhibit epileptogenic properties due to dysregulated neuronal activity, impaired glial cell function, and modified vascularity.¹ The presence of abnormal, neoplastic tissue leads to structural and functional alteration of surrounding tissue due to oedema, vascular insufficiency, inflammation, and release of metabolically active molecules, all of which may predispose to seizure activity. Understanding these changes may lead to a better control of seizures in patients with brain tumours. In this article we aim to review literature addressing pharmaceutical management of seizures in patients with brain tumours. This review will not address the role of prophylactic anti-epileptics in patients with brain tumours.

Review Of Evidence

Valproic acid or valproate, is a conventional anti-epileptic drug with properties of a histone deacetylase inhibitor (HDACi). HDACi plays a key role in gene expression and epigenetic regulation and has also been used as an anticancer agent. Redjal et al.², report valproate to be

.....
Department of Surgery, Section of Neurosurgery, Aga Khan University Hospital, Karachi, Pakistan.

Correspondence: Muhammad Shahzad Shamim.
Email: shahzad.shamim@aku.edu

associated with improved survival in patients with high grade glioma and GBM in a dose-dependent manner. However, in patients with grade II and III gliomas, it is associated with an 18% increased risk of tumour progression or death, and every additional 100g of valproate raises the risk of progression or death by 10%. These are alarming observations and require further prospective validation. Van Breemen et al.³, studied the use of both valproate as first choice, and in combination with newer anti-epileptic levetiracetam. The combination of these two medications resulted in 81.5% responders, with 55.6% of patients showing a tangible decline in seizure frequency. They recommended that the combination of an older with newer drug, can be a useful therapeutic option in brain tumour patients with resistant seizures.

In another study Novy J et al.⁴, retrospectively reviewed the use of pregabalin (non-enzyme-inducing antiepileptic drug) in GBM patients with seizures. All subjects experienced at least a 50% seizure reduction. The authors recommended pregabalin as an effective anti-epileptic in patients with brain tumours and seizures. Its quick titration also makes it a good alternative in subjects experiencing frequent seizures and the drug can also be used in combination with other anti-epileptics like levetiracetam, lamotrigine, topiramate, gabapentin and valproic acid as a first-line treatment.⁴ However, so far it is not being used as a first line anti-epileptic drug.

Zonisamide (ZNS), a second-generation anti-epileptic drug, has demonstrated efficacy as an add-on in refractory epilepsy with simple and complex partial seizures, with or without secondary generalization. The pharmacokinetics of ZNS include rapid absorption, high bioavailability, and a long elimination half-life. The most common adverse effects of ZNS (somnolence, weight loss, and cognitive impairment) were mild to moderate and there were no interactions with concomitant anti-epileptic drugs. ZNS does not alter patients' perception of their quality of life and there also appears to be a significant improvement in distress related to cognitive disturbances and social functions.⁵

In patients with brain tumours, phenytoin used to be the drug of choice for prophylactic peri-operative

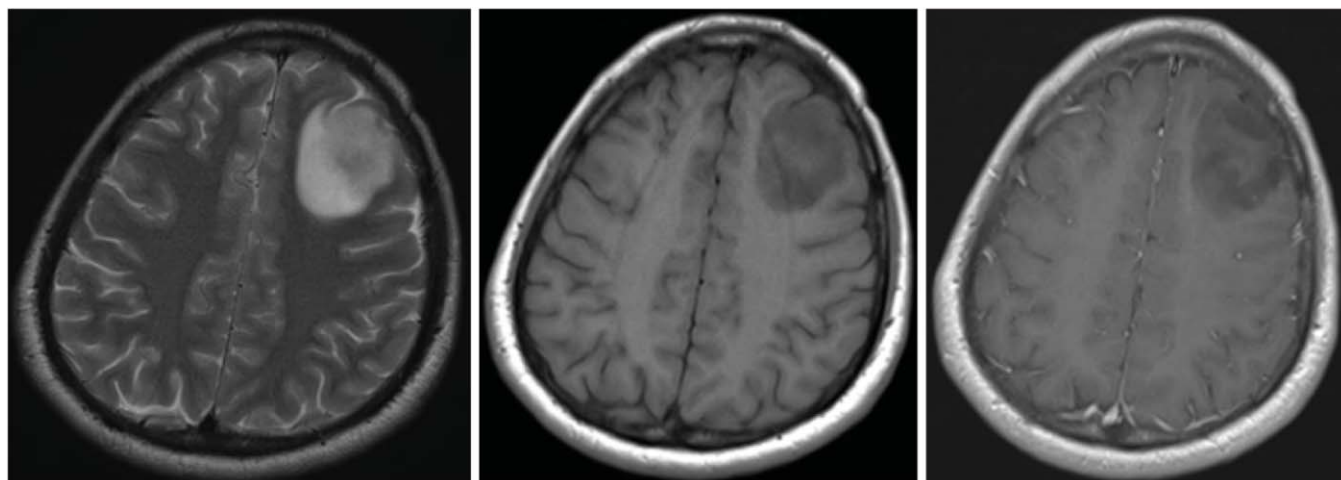


Figure- a

b

c

administration, as well as for seizure control. However, it was associated with drug interactions due to its induction of CYP P450 enzymes. In contrast, levetiracetam is not metabolized by the CYP complex in the liver and undergoes renal excretion with minimal drug interaction. In a phase 2 prospective randomized trial, Luchi et al.⁶, showed levetiracetam to have a significantly lower incidence of perioperative seizures (1.4%) compared to phenytoin (15.1%). In addition, levetiracetam appeared a safer drug, and treatment was completed in all patients, compared to phenytoin that had to be withdrawn in 6.8% of patients. Levetiracetam, in several studies including a meta-analysis, has shown efficacy comparable to phenytoin, with reduced cost and adverse effects.⁷ Also, due to the advantage of not having to check its serum levels, easy titration and minimal drug interactions, levetiracetam is fast becoming the first line anti-epileptic for brain tumour patients.

Tumour localization in the frontal lobe and levetiracetam treatment have been associated with high risk of neuropsychiatric adverse effects in patients with brain tumour related epilepsy. This leads to poor compliance and higher dropout rates, and therefore, these patients need to be closely monitored as outpatients.⁸ The other adverse effect to look for is somnolence, as reported by Rosati A et al.⁹, in a prospective study, where although 73 of 82 (91%) glioma patients were seizure free with levetiracetam as monotherapy, somnolence was occasionally reported in the initial period of therapy.

Finally, epigenetic modifications may occur in patients with GBM, such as changes in gene methylation and histone acetylation states. It has been proposed that secondary mechanism of action of anti-epileptic drugs, that also impact these epigenetic modifications, may play

a role in effectiveness of treatment and survival. Both valproate and carbamazepine have HDACi activities, while valproate and levetiracetam reduce the activity of MGMT, a DNA-repair molecule implicated in resistance to alkylating agents used for chemotherapy.¹⁰ The use of such drugs for purposes other than seizure control has at the moment, very little evidence to support its use, but does present an interesting area of research.¹¹

Conclusion

Seizures in patients with brain tumour can be managed effectively by the use of one of many anti-epileptic drugs, either as monotherapy, or as combinations. The choice of anti-epileptic drugs, depends on several factors and has to be individualized according to patients' response. Newer drugs such as levetiracetam, have better tolerance and safety profile, and may be employed either as monotherapy, or as an add-on with conventional anti-epileptic drugs.

Reference

1. Shamji MF, Fric-Shamji EC, Benoit BG. Brain tumours and epilepsy: pathophysiology of peritumoral changes. *Neurosurg Rev.* 2009;32:275-85.
2. Redjal N, Reinshagen C, Le A, Walcott BP, McDonnell E, Dietrich J, et al. Valproic acid, compared to other antiepileptic drugs, is associated with improved overall and progression-free survival in glioblastoma but worse outcome in grade II/III gliomas treated with temozolomide. *J Neurooncol.* 2016;127:505-14.
3. Van Breemen MSM, Rijsman RM, Taphoorn MJB, Walchenbach R, Zwinkels H, Vecht CJ. Efficacy of anti-epileptic drugs in patients with gliomas and seizures. *J Neurol.* 2009;256:1519-26.
4. Novy J, Stupp R, Rossetti AO. Pregabalin in patients with primary brain tumors and seizures: a preliminary observation. *Clin Neurol Neurosurg.* 2009;111:171-3.
5. Maschio M, Dinapoli L, Zarabla A, Maialetti A, Giannarelli D, Fabi A, et al. Zonisamide in Brain Tumor Related Epilepsy: An observational pilot study. *Clin Neuropharmacol.* 2017; 40:113-9.
6. Luchi T, Kuwabara K, Matsumoto M, Kawasaki K, Hasegawa Y, Sakaida T. Levetiracetam versus phenytoin for seizure prophylaxis

- during and early after craniotomy for brain tumours: a phase II prospective, randomized study. *J Neurol Neurosurg Psychiatry*. 2015;86:1158-62.
7. Zafar SN, Khan AA, Ghauri AA, Shamim MS. Phenytoin versus levetiracetam for seizure prophylaxis after brain injury- a meta-analysis. *BMC Neurology*. 2012;12:30.
 8. Bedetti C, Romoli M, Maschio M, Di Bonaventura C, Nardi Cesarini E, Eusebi P, et al. Neuropsychiatric adverse events of antiepileptic drugs in brain tumour-related epilepsy: an Italian multicentre prospective observational study. *Eur. J. Neurol*. 2017 ;24:1283-9.
 9. Rosati A, Buttolo L, Stefini R, Todeschini A, Cenzato M, Padovani A. Efficacy and safety of levetiracetam in patients with glioma: a clinical prospective study. *Arch Neurol* 2010;67:343-6.
 10. Rao AM, Quddusi A, Shamim MS. The significance of MGMT methylation in Glioblastoma Multiforme prognosis. *J Pak Med Assoc*. 2018;68:1137-1139.
 11. Gefroh AE, Grimes HA, Gidal BE. Antiepileptic drugs in patients with malignant brain tumor: beyond seizures and pharmacokinetics. *Acta Neurol Scand*. 2016;133:4-16.
-