



4-2007

Carotid Artery Stenting -Where do we Stand?

Ismail A. Khatri
Shifa International Hospital

Sara Qayyum
Shifa International Hospital

Ammar AlKawi
University of Medicine and Dentistry of New Jersey, Newark, NJ, USA

Jawad F. Kirmani
University of Medicine and Dentistry of New Jersey, Newark, NJ, USA

Follow this and additional works at: <https://ecommons.aku.edu/pjns>

 Part of the [Neurology Commons](#)

Recommended Citation

Khatri, Ismail A.; Qayyum, Sara; AlKawi, Ammar; and Kirmani, Jawad F. (2007) "Carotid Artery Stenting -Where do we Stand?," *Pakistan Journal of Neurological Sciences (PJNS)*: Vol. 2 : Iss. 1 , Article 6.
Available at: <https://ecommons.aku.edu/pjns/vol2/iss1/6>

CAROTID ARTERY STENTING -WHERE DO WE STAND?

Ismail A. Khatri ¹, Sara Qayyum ¹, Ammar AlKawi ², Jawad F. Kirmani ²

¹Section of Neurology, Shifa College of Medicine and Shifa International Hospitals, Islamabad, Pakistan; ²Department of Neurology and Neurosciences, University of Medicine and Dentistry of New Jersey, Newark, NJ, USA

Correspondence to: Dr. Khatri, Section of Neurology, Shifa International Hospitals Ltd., Pitras Bukhari Road, Sector H-8/4, Islamabad 46000, Pakistan. Tel: (92-51) 444-6801-30 Ext: 3175, 3025. Fax: (92-51) 486-3182. Email: ismailkhatri@yahoo.com

Pak J Neurol Sci 2007; 2(1):18-24

ABSTRACT

In the past few years, the use of carotid artery stenting (CAS) for the treatment of extracranial carotid occlusive disease has increased exponentially. It is perceived to be a safer and effective alternative to carotid endarterectomy (CEA). There is an extensive wealth of data on carotid endarterectomy, which is one of the most thoroughly studied and extensively performed vascular surgical procedures. Data available on CAS is still limited. Ongoing randomized trials comparing the two procedures are facing difficulties in patient recruitment because of large numbers of registries and extensive use of CAS. Proponents of CAS believe that stenting will become the default first-line therapy for patients with extra-cranial carotid occlusive disease. Opponents of CAS point to the lack of evidence from randomized, controlled studies, and favor CEA over carotid artery stenting by citing the extensive experience and well-established role of CEA. With many stakeholders involved in the care of patients with carotid artery disease and the rapidly growing popularity of the procedure, there is concern that trials attempting to answer this question may remain incomplete. This review discusses the history and evolution of carotid artery stenting, the method, the variety of stents used, the use of antiplatelet agents, and the available data on safety and efficacy.

Approximately 20% of all ischemic strokes and transient ischemic attacks (TIAs) are due to atherosclerotic stenosis of the internal carotid artery (ICA) segment that is close to the carotid bifurcation. For the prevention of such strokes, carotid artery stenting (CAS) is emerging worldwide as a less invasive alternative to carotid endarterectomy (CEA). Since the inception of the procedure a large number of patients have received CAS. Various specialists including neurologists, cardiologists, neurosurgeons, vascular surgeons, and radiologists are performing carotid artery stenting. A large number of registries are in place reporting findings on CAS. Several randomized trials have attempted to compare the efficacy and safety of CAS versus endarterectomy. Some of these were terminated prematurely while others are still in progress.

HISTORY OF CAROTID ENDARTERECTOMY

In 1953 DeBakey performed the first successful carotid endarterectomy for the treatment of occluded cervical carotid artery, which was followed by Eastcott who performed the first carotid endarterectomy we know of in

which the circulation of the brain was intentionally interrupted to remove a stenotic plaque.¹ From these initial experiences CEA evolved over the years and has come to be accepted as the standard treatment for carotid revascularization.

The North American Carotid Endarterectomy Trial (NASCET) was the first well designed multicenter randomized trial that demonstrated unequivocal benefit of surgery over best medical management in symptomatic patients with a severe carotid stenosis of 70% or greater.² Patients with symptomatic moderate carotid stenosis of 50-69% yielded only moderate but definitive reduction in the risk of stroke, while patients with stenosis of less than 50% did not benefit from surgery.^{2,3} The benefit of CEA in patients with e 70% was sustained at eight years of follow-up.³ There is thus Level I evidence from randomized studies that in properly selected patients CEA can reduce the relative risk of stroke by approximately 50% in both symptomatic and asymptomatic patients when compared with best medical management.^{4,5}

BEGINNING OF CAROTID ARTERY STENTING

In 1980 percutaneous transluminal balloon angioplasty for carotid artery stenosis was first reported.¹ Subsequently in 1987 findings on internal carotid angioplasty in 48 patients with de novo atherosclerosis or post-surgical restenosis were published.¹ Gil-Peralta et al⁶ performed 85 balloon angioplasties in 82 patients with symptomatic carotid stenosis of greater than 70% during a 4-year period and reported a technical success rate of 92% (residual stenosis <50%) with a 30-day mortality of 0% and major morbidity rate of 4.9% which compared favorably to the rates in ECST7 and NASCET.²

Despite showing favorable results, simple balloon angioplasties were associated with a number of complications such as vessel wall recoil, angiographically evident intimal dissection, and plaque dislodgement with particulate embolization. Promising results from trials of stent-assisted balloon angioplasties as opposed to simple balloon angioplasties in coronary arteries led to experimentation and trials of carotid angioplasty along with stenting. Further improvements resulted in the use of distal embolic capture devices, with the hope of improved outcomes.

PATIENT SELECTION

Treatment of carotid stenosis by endovascular techniques has the distinct advantage of being less invasive, thus avoiding a surgical incision. In the absence of long term follow-up results and randomized trials it is difficult and premature to define the indications of carotid angioplasty and stenting over carotid endarterectomy. The Stenting and Angioplasty with Protection in Patients at High Risk for Endarterectomy (SAPPHIRE) trial has shown non-inferiority of CAS when compared with CEA in high-risk symptomatic patients only.⁸ The Carotid Revascularization Endarterectomy versus Stenting Trial (CREST) is attempting to answer the same question in low risk patients.⁹ Several other trials are underway to answer this question.

In general, indications for carotid revascularization relating to symptomatic status and lesion severity are similar for endovascular and surgical strategies. A summary of proven and acceptable indications as given by Roubin et al¹⁰ is presented in Table 1.

Primary candidates for carotid artery stenting are patients with serious comorbid medical or anatomical conditions that increase the risk of open surgical procedures or general anesthesia. Results from SAPPHIRE and various prospective registries of carotid stenting in patients at high

Table 1: Indications for Carotid Artery Revascularization*

INDICATION LEVEL	SYMPTOMATIC STENOSIS	ASYMPTOMATIC STENOSIS
PROVEN	70-99% stenosis Periprocedural risk <6%	>60% stenosis Periprocedural risk <3% Life expectancy >5 years
ACCEPTABLE	50-69% stenosis Periprocedural complication risk <3%	>60% stenosis Periprocedural complication risk <3% Planned CABG
UNACCEPTABLE	<29% stenosis or Periprocedural complication risk >6%	<60% stenosis or Periprocedural risk >5% No indication for CABG

*Adapted from Roubin GS et al. *Circulation* 2006; **113**:2021-2030

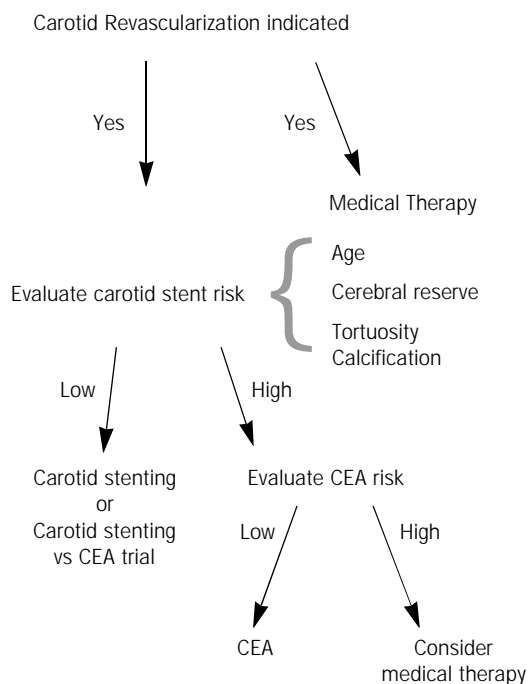
risk support these indications for CEA. Conditions characterized as high surgical risk include advanced age, significant cardiac and pulmonary disease, prior neck irradiation or radical surgery, restenosis after endarterectomy, contralateral carotid occlusion, high lesion behind the mandible, and low lesions that would require thoracic exposure.¹⁰ CARESS was a Phase-I trial that compared CAS with embolic protection and CEA in a broad risk population and found equivalent 30-day stroke or death risk in the two groups.¹¹ The 30-day stroke and death rates associated with CAS and CEA were not significantly different in a recently published meta-analysis. Lower rates of myocardial infarction and cranial nerve injury were observed with CAS compared with CEA.¹² Major trials such as CREST and SPACE comparing carotid artery stenting and CEA in low surgical risk patients are still in progress.^{13,14} Once these trials are complete, patient selection for CAS will become easier. However, recruitment in these trials is slow and the data may not be available for an additional 2 to 3 years.¹⁵ Roubin et al¹⁰ have suggested a decision-making algorithm (Figure 1).

METHOD

A complete neurologic history and examination is a prerequisite to any carotid stent procedure. A baseline brain CT or MRI scan should be obtained to document pre-existing infarction(s) and to exclude non-vascular neurologic disease such as tumor that may mimic TIA. Furthermore, baseline laboratory values including complete blood count, serum chemistries, blood urea nitrogen and creatinine, PT, APTT, INR as well as pre-procedural EKG and chest radiographs are obtained.

Patients fast from midnight before the procedure but are permitted to take their regular medications with sips of

Figure 1: Proposed new paradigm for decision making emphasizing risk stratification pertaining to carotid stenting*



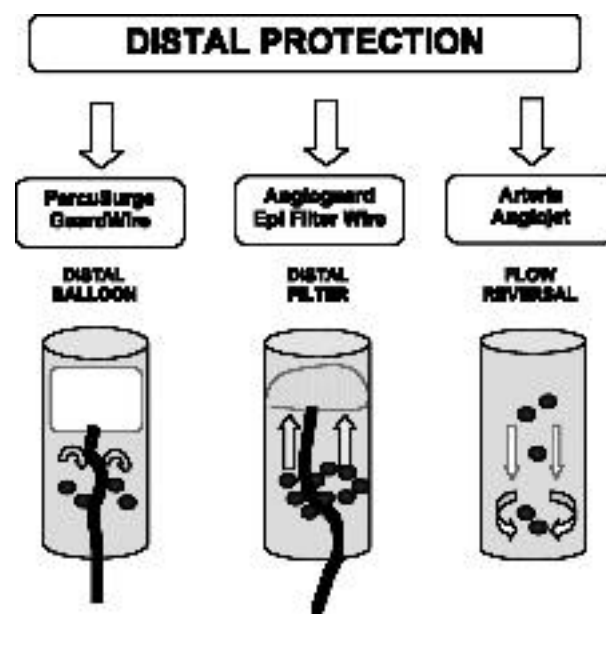
*Adapted from Roubin GS et al. Circulation 2006; 113:2021-2030

water. Oral antihypertensive medication is withheld on the day of the procedure. Peri-procedural adequately dosed antiplatelet therapy is the key. Patients must receive either a combination of clopidogrel 75 mg and aspirin 325 mg for 5 days before stenting, or alternatively a loading dose of clopidogrel (600 mg) and aspirin (650 mg) at least 4 hours before the procedure. Either heparin (70 IU/kg initial bolus targeting an ACT [Activated Clotting Time] of > 300 seconds) or bivalirudin is administered immediately with sheath insertion.¹⁰ Continuous monitoring of pulse oximetry, intra-arterial pressure and heart rhythm is essential, as is meticulous control of hemodynamics. To suppress bradycardic responses to balloon inflation and stent implantation, intravenous atropine (0.5 to 1.0 mg) should be administered just before balloon insufflation. Hypotension is especially notable in elderly patients with calcified stenosis but is benign and rarely requires measures such as volume expansion or intravenous pressor support. If a pressor is needed dopamine is the drug of choice. After relief of stenosis, any increase in blood pressure should be treated aggressively with intravenous anti-hypertensives such as nicardipine, hydralazine, or labetalol to avoid reperfusion injury. Before occlusive balloon deflation, and in cases where distal protection with an occlusive aspiration system is used, lowering of blood pressure before deflation protects the potential consequences of hyperperfusion.

The extent of diagnostic angiography is determined by anatomic information obtained from pre-procedural non-invasive studies; at a minimum, this should include accurate evaluation of lesion severity, length and characteristics such as calcification versus ulceration. Preliminary diagnostic angiography of both carotid arteries in a minimum of two planes is preferred with cervical and intracranial views.

The procedure is usually performed under conscious sedation with local anesthesia of the femoral artery region. A sheath is inserted into the common femoral artery with the sheath size dependent on the stent used and sheath length. A variety of stent delivery catheters are available. A distal protection device is now routinely used; it is carefully advanced across the lesion and deployed distally. Using a smaller diameter balloon, a pre-stent angioplasty is then performed. This creates enough room for the stent to cross safely. Once the stent is satisfactorily positioned, it is deployed by immobilizing the delivery catheter and retracting the outer sleeve (for self-expanding stents) or inflating the balloon (for balloon-expandable stents). Post-stent angioplasty is usually performed if residual stenosis after stent deployment is still >30%. Antero-posterior and lateral cervical and intracranial angiograms should be obtained after stent placement in all cases to exclude any embolic branch occlusion and to document new patterns of flow.

Figure 2: Basic principles and designs of distal/embolic protection devices



TYPES OF STENT

Various types of stent have been used in different clinical trials. These are broadly classified into self-expanding and balloon-expandable stents. They are either tubular in design or have a coiled sheet design.¹⁶ Examples of balloon-expandable stents are Palmaz-Schatz stent and Intrastent. Examples of self-expanding stents are Smart stent, Precise stent and Wallstent. NexStent was the first stent with a coiled sheet design.¹⁶ In the SAPPHIRE trial, Smart or Precise stents were used which are nitinol stents.⁸ The BEACH trial used Wallstent.¹⁷ With balloon-expandable stents there is concern of restenosis due to stent collapse from external compression.¹ Most registries are now using self-expanding nitinol stents and the balloon expandable stent for carotid stenting is no longer being used in most centers.¹⁸

DISTAL PROTECTION DEVICE

The greatest risk associated with CAS is periprocedural stroke resulting from the release, migration and embolization of debris during balloon angioplasty of the stenotic lesion. Theron et al, who used occlusion balloon to avoid distal migration of clots and plaque fragments, made the first attempt at distal protection during carotid artery angioplasty in 1990.¹⁹ A number of embolic protection devices are currently utilized in carotid artery stenting.¹⁸ There are three basic design principles of how most distal protection devices work. They could be distally occlusive, filter distally, or work through flow reversal (Figure 2).

In the past 5 years data from several large trials, series and registries of carotid artery stenting have reflected on the experience of embolic protection devices (EPDs) in CAS. These findings have confirmed that embolic complications decrease significantly when an EPD is employed. CAS with cerebral protection has been shown to be a safe, effective and durable treatment of carotid artery stenosis, yet there is no available Level I evidence to support the routine use of EPDs. However, in the absence of a reproducible estimation of the emboligenic risk posed by each carotid artery lesion, expert consensus supports the use of an EPD in all CAS procedures.¹⁹

ROLE OF ANTI-PLATELET AGENTS

The rationale for early anti-platelet therapy is to (i) prevent rapid thrombus formation immediately after arterial injury due to angioplasty and stenting; and (ii) prevention of potential embolization of thrombus fragments to distal sites.²⁰ Benefits of combined anti-platelet treatment in coronary artery stenting have long been established.²¹

Significant reduction in post-procedural myocardial infarction and stent thrombosis in coronary angioplasty studies has made dual anti-platelet therapy the standard of care.²² A meta-analysis of all trials that compared 2 oral anti-thrombotic strategies in patients undergoing coronary stent placement to determine which treatment optimally prevents adverse cardiac events in the 30 days following stent insertion showed that (a) cilostazol plus aspirin and (b) clopidogrel plus aspirin were statistically indistinguishable from ticlopidine plus aspirin in preventing major adverse cardiac events in the 30 days following cardiac stent placement.²³

The first randomized controlled trial to assess the benefits of combined anti-platelet therapy (using a regimen of aspirin and clopidogrel) in carotid artery stenting was terminated prematurely. In this study, patients were already on aspirin 75 mg daily and were randomized to receive either intravenous unfractionated heparin for 24 hours following the procedure, or clopidogrel. A loading dose of clopidogrel 300 mg was given 6-12 hours before the procedure and again as 75 mg 2 hours prior to the procedure. It was then continued as 75 mg daily for 28 days following stent placement. There was significant reduction in adverse neurological outcomes in the dual anti-platelet group without an additional risk of bleeding. Restenosis and bleeding complications were higher in the heparin group but did not reach statistical significance. The study was terminated prematurely due to increased bleeding complications in the heparin group, but the conclusion favored dual antiplatelet therapy.²¹

Another single center study compared the dual antiplatelet treatment ticlopidine 250 mg twice a day plus aspirin 325 mg with a combination of heparin 24-hour infusion and aspirin in patients who underwent CAS. This study also demonstrated that dual anti-platelet regimen has a statistically significant impact on reducing adverse neurological outcomes without an additional increase in bleeding complications. This study did not show any significant difference in either hemorrhagic complications or the thrombosis/occlusion rate between the two groups. This study was also terminated prematurely because of an important difference between the two groups in primary end-point favoring dual antiplatelet therapy.²⁴

CAROTID ARTERY STENTING - IS IT SAFE?

Carotid artery stenting is increasingly used in place of carotid endarterectomy even though few randomized trials have directly compared these alternatives. The initial series of CAS showed a high stroke rate compared with previously reported series of CEA; however, these studies predated the use of cerebral protection.⁴ The CAVATAS trial was the first large trial in which the risk of stroke or

death within 30 days of treatment was comparable in the two groups of CAS and CEA.²⁵ Results from CAVATAS lend support to the concept that endovascular techniques are better than surgery because they avoid risks related to the incision in the neck and the use of general anesthesia. This trial, however, also predated the use of distal protection devices.

The first randomized trial that compared CAS with distal protection device to CEA was the SAPPHIRE trial. The main finding of SAPPHIRE was that CAS with the use of an EPD was not inferior to carotid endarterectomy in the prevention of stroke, death or myocardial infarction among patients for whom surgery posed an increased risk. In the secondary analysis, the cumulative incidence of stroke, death and myocardial infarction as well as the cumulative incidence of cranial nerve palsy and revascularization and the length of stay, were lower among patients who received stents than among those who underwent surgery. The results are not generalizable to patients at low surgical risk. SAPPHIRE was terminated early because patient recruitment fell after non-randomized stent registries were established. The trial was designed to test non-inferiority of CAS versus CEA (and hence show equivalency); its results, therefore, cannot be extrapolated to assume superiority of CAS over CEA in high-risk patients.⁸

The ARChER (ACCULINK for revascularization of carotids in high-risk patients) trial was also conducted on high-risk patients. At 1 year, the incidence of major stroke and death was 2.5% in ARChER II (with EPD) and 3.87% in ARChER I (without a protection device).^{26,27} Several other trials have shown the rate of major cardiac events and rate of complications to be similar to those in SAPPHIRE and ARChER trials.²⁷ The CREST trial, currently underway, intends to answer the question of safety and efficacy of CAS as compared to CEA in low risk asymptomatic patients as well.^{9,13} Preliminary data from the lead-in phase of CREST suggests that CAS carries a low risk of stroke in young, low-risk patients - stroke risk for patients ages 60-69 was 1.3%; for patients aged 70-79 it was 5.4%, and in patients > 80 years old there was a combined stroke and death rate of 12%.⁹ These data strongly confirm previous reports suggesting that octogenarians have an excessive risk of stroke or death after CAS and that these patients should be strongly considered for CEA or medical therapy.

Certain other potential risk factors may make CAS less safe. These include decreased cerebral reserve, evidence of excessive tortuosity defined as ≥ 2 bend points that exceed 90° within 5 cm of the lesion, including the take-off of the internal carotid artery (ICA) from the common carotid artery (CCA) and heavy calcification defined as concentric calcification ≥ 3 mm in width and deemed by at least 2 orthogonal views to be circumferentially situated around the lesion.¹⁰

CAROTID ARTERY STENTING - IS IT EFFECTIVE?

Technical success with CAS resulting in >50% reduction in residual stenosis has been reported even in the very early series of CAS.⁶ Whether this translates into long-term benefit of having decreased ipsilateral stroke and overall mortality is yet to be established. The 30-day and 1-year results of most CAS trials are encouraging in this regard. However, until the long-term results of these trials are available it will be premature to reach conclusions.

There is some data to support cognitive benefits of CEA. A recent study showed similar cognitive benefits with improvement in cognitive and memory functions immediately after CAS.²⁸ In this study, patients also had MRIs with diffusion-weighted imaging (DWI) before and after the procedure. DWI lesions were seen in 40% of treated patients. The cognitive benefits were obvious despite DWI lesions. Improved perfusion in previously under-perfused areas was hypothesized to be the cause of improved cognitive functions. Limitations of the study included a small number of patients and limited follow-up.

REOCCLUSION AFTER CAROTID ARTERY STENTING

Stent endothelialization is a slow process and is known to take between 28 and 96 days to complete. During this time the exposed metallic stent continues to act as a source of platelet activation.²¹ Acute and subacute in-stent thrombosis following CAS is a well-known complication. Earlier studies have reported a frequency of 0.5 to 2%.²⁹ A case of >90% restenosis within the stent seven months after CAS is reported.³⁰ Another recent paper reported in-stent thrombosis after the acute phase but within 3 months of CAS in 3 patients. Of note, in all these patients antiplatelet therapy had been discontinued.²⁹ Overall - and unlike the coronary and intracranial circulations - the rates of long-term flow-limiting restenosis in larger vessels such as the carotid artery are extremely low.

CONCERNS ABOUT CAROTID ARTERY STENTING

Current concerns about CAS include the large number of specialties that are eager to provide CAS as a clinical service; however, there is lack of consensus about minimal eligibility criteria for performance of the procedure. Given the wide availability of catheter techniques and expertise in using them in other medical areas, especially cardiology, stenting will be offered to neurologically unselected patients who may not need it.³¹ In testing the benefits and risks of new treatments in different patient groups, registries are not acceptable because of their risks of bias. Unfortunately, randomized

trials of CAS versus CEA are having difficulty in recruiting patients and most of the new data is coming from registries.

CONCLUSION

The value of CEA has been established by a wealth of evidence from well designed, prospective, randomized trials. Carotid artery stenting is a very strong contender for carotid revascularization along side carotid endarterectomy. However, large-scale, well-designed, randomized trials comparing the two procedures are facing great hardship in recruiting patients. If these trials prove unequivocal efficacy and safety of carotid artery stenting, then CAS is likely to become the default procedure for treatment of eligible patients. Despite its promise, available information on the safety and efficacy of CAS cannot as yet be generalized.

REFERENCES

1. Phatourous CC, Higashida RT, Malek AM, et al. Carotid artery stent placement for atherosclerotic disease: rationale, technique, and current status. *Radiology* 2000; **217**:26-41
2. The North American Symptomatic Carotid Endarterectomy Trial Collaborators. Beneficial effect of carotid endarterectomy in symptomatic patients with high-grade stenosis. *N Engl J Med* 1991; **325**:445-453
3. Barnett HJ, Taylor W, Eliasziw M, et al. Benefits of carotid endarterectomy in patients with symptomatic moderate or severe stenosis. North American Symptomatic Carotid Endarterectomy Trial Collaborators. *N Engl J Med* 1998; **339**:1415-1425
4. Powell RJ. Pro: Carotid angioplasty and stenting will be the first line interventional therapy for stroke prevention in patients with extracranial carotid occlusive disease. *J Cardiothorac Vasc Anesth*. 2005; **19**:539-541
5. Cambria RP. Stenting for carotid-artery stenosis. *N Engl J Med* 2004; **351**:1565-1567
6. Gil-Peralta A, Mayol A, Marcos JR, et al. Percutaneous transluminal angioplasty of the symptomatic atherosclerotic carotid arteries. Results, complications, and follow-up. *Stroke* 1996; **27**:2271-2273
7. European Carotid Surgery Trialists' Collaborative Group. MRC European Carotid Surgery Trial: interim results for symptomatic patients with severe (70-99%) or with mild (0-20%) carotid stenosis. *Lancet* 1991; **337**:1235-1243
8. Yadav JS, Wholey MH, Kuntz RE, et al. Stenting and Angioplasty with Protection in Patients at High risk for Endarterectomy (SAPPHIRE) investigators. Protected carotid artery stenting versus endarterectomy in high-risk patients. *N Engl J Med* 2004; **351**:1493-1501
9. Hobson RW 2nd, Howard VJ, Roubin GS, et al. Carotid artery stenting is associated with increased complications in octogenarians: 30-day stroke and death rates in the CREST lead-in phase. *J Vasc Surg*. 2004; **40**:1106-1111
10. Roubin GS, Iyer SR, Halkin A, et al. Realizing the potential of carotid artery stenting. Proposed paradigms for patient selection and procedural technique. *Circulation* 2006; **113**:2021-2030
11. CaRESS Steering Committee. Carotid Revascularization using Endarterectomy or Stenting Systems (CaRESS), phase I clinical trial: 1-year results. *J Vasc Surg* 2005; **42**:213-219
12. Qureshi AI, Kirmani JF, Divani AA, et al. Carotid angioplasty with or without stent placement versus carotid endarterectomy for treatment of carotid stenosis: a meta-analysis. *Neurosurgery* 2005; **56**:1171-1181
13. Hobson RW II. CREST (Carotid Revascularization Endarterectomy versus Stent Trials): background, design, and current status. *Semin Vasc Surg* 2000; **13**:139-143
14. Major Ongoing Stroke Trials. Stent-Protected Percutaneous Angioplasty of the Carotid Versus Endarterectomy (SPACE). *Stroke* 2002; **33**:646-655
15. Hobson RW II, Brott TG, Roubin GS, et al. Carotid artery stenting: meeting the recruitment challenge of a clinical trial. *Stroke* 2005; **36**:1314-1315
16. Qureshi AI, Knape C, Maroney J, et al. Multicenter clinical trial of the NexStent coiled sheet stent in the treatment of extracranial carotid stenosis: immediate results and late clinical outcomes. *J Neurosurg* 2003; **99**:264-270
17. White CJ, Iyer SS, Hopkins LN et al; BEACH Trial Investigators. Carotid stenting with distal protection in high surgical risk patients: the BEACH trial 30-day results. *Catheter Cardiovasc Interv*. 2006; **67**:503-512
18. Goodney PP, Schermerhorn ML, Power RJ. Current status of carotid artery stenting. *J Vasc Surg* 2006; **43**:406-411
19. Schonholz CJ, Uflacker R, Parodi JC, et al. Is there any evidence that cerebral protection is beneficial? Clinical data. *J Cardiovasc Surg (Torino)* 2006; **47**:137-141
20. Chaturvedi S, Yadav JS. The role of antiplatelet therapy in carotid stenting for ischemic stroke prevention. *Stroke* 2006; **37**:1572-1577

21. McKeivitt FM, Randall MS, Cleveland TJ, et al. The benefits of combined antiplatelet treatment in carotid artery stenting. *Eur J Vasc Endovasc Surg* 2005; **29**:522-527
22. Leon MB, Baim DS, Popma JJ, et al. A clinical trial comparing three antithrombotic-drug regimens after coronary artery stenting. Stent Anticoagulation Restenosis Study Investigators. *N Engl J Med* 1998;**339**:1665-1671
23. Schleinitz MD, Olkin I, Heidenreich PA. Cilostazol, clopidogrel or ticlopidine to prevent sub-acute stent thrombosis: a meta-analysis of randomized trials. *Am Heart J* 2004; **148**:990-997
24. Dalainas I, Nano G, Bianchi P, et al. Dual antiplatelet regime versus acetyl-acetic acid for carotid artery stenting. *Cardiovasc Intervent Radiol* 2006; **29**:519-521
25. CAVATAS Investigators. Endovascular versus surgical treatment in patients with carotid stenosis in the Carotid and Vertebral Artery Transluminal Angioplasty Study (CAVATAS): a randomized trial. *Lancet* 2001; **357**:1729-1737
26. <http://www.strokecenter.org/trials/TrialDetail.aspx?tid=100&printView=true>
Accessed on June 21, 2006
27. Krajcer Z. Carotid artery stenting. *Tex Heart Inst J*. 2005; **32**:369-371
28. Grunwald IQ, Supprian T, Politi M et al. Cognitive changes after carotid artery stenting. *Neuroradiology* 2006; **48**:319-323
29. Buhk JH, Wellmer A, Knauth M. Late in-stent thrombosis following carotid angioplasty. *Neurology* 2006; **66**:1594-1596
30. Quinones-Baldrich WJ. Recurrent carotid stenosis after angioplasty and stenting. *J Vasc Surg* 2005; **41**:718
31. Thomas DJ. Protected carotid artery stenting versus endarterectomy in high-risk patients. Reflections from SAPPHERE. *Stroke* 2005; **36**:912-913