



4-2008

Embolization of An Intracranialarteriovenous Malformation Followed Byimmediate Surgical Resection: A Case Report

Imaad ur Rehman
Aga Khan University

Tanveer ul Haq
Aga Khan University

Rashid Jooma
Aga Khan University

Muhammad Azeemuddin
Aga Khan University

Zafar Sajjad
Aga Khan University

Follow this and additional works at: <https://ecommons.aku.edu/pjns>

Recommended Citation

Rehman, Imaad ur; Haq, Tanveer ul; Jooma, Rashid; Azeemuddin, Muhammad; and Sajjad, Zafar (2008) "Embolization of An Intracranialarteriovenous Malformation Followed Byimmediate Surgical Resection: A Case Report," *Pakistan Journal of Neurological Sciences (PJNS)*: Vol. 3 : Iss. 1 , Article 3.

Available at: <https://ecommons.aku.edu/pjns/vol3/iss1/3>

EMBOLIZATION OF AN INTRACRANIAL ARTERIOVENOUS MALFORMATION FOLLOWED BY IMMEDIATE SURGICAL RESECTION: A CASE REPORT

Imaad ur Rehman,¹ Tanveer ul Haq,¹ Rashid Jooma,² Muhammad Azeemuddin¹ and Zafar Sajjad¹

Departments of Radiology¹ and Surgery, ² Aga Khan University Hospital, Karachi, Pakistan

Correspondence to: Dr. Haq, Associate Professor of Radiology, Aga Khan University Hospital, Karachi 74800, Pakistan. Email: tanveer.haq@aku.edu

Pak J Neurol Sci 2008; 3(1):9-11

ABSTRACT

Intracranial arteriovenous malformations (AVMs) are now a recognized entity because of improvements in imaging diagnosis. They are relatively uncommon but can cause serious neurological symptoms or death. We report a case of a 22-year-old man who presented with left parietal hemorrhage and on cerebral angiography was found to have a small AVM in the left middle cerebral artery (MCA) territory. Glue embolization followed by immediate surgical resection of the AVM was carried out, resulting in complete cure.

Arteriovenous malformations (AVMs) consist of tangles of vessels of different wall thickness and diameter associated with arteriovenous shunting. In AVMs, arterioles and venules communicate directly without the interposition of a capillary bed. Ninety percent of intracranial AVMs are supratentorial.¹ They often have associated aneurysms.² Hemorrhage is the most dreaded presentation. Treatment and complete cure is challenging, especially for Spetzler grade IV and V.³ Glue embolization offers cure in some cases but most of the time it is adjuvant to surgery or gamma knife therapy. The following case report shows a comprehensive multidisciplinary approach to treat AVM in which embolization was immediately followed by surgical resection under the same anesthesia.

CASE REPORT

A 22-year-old man presented with headache, right sided weakness and slurred speech for one week. CT scan showed hemorrhage in the left parietal lobe (Figure 1). Cerebral angiography showed Spetzler Grade II AVM in the left parietal region. He was referred to our facility for elective embolization of AVM.

During embolization, the initial angiographic run revealed an approximately 1.2 cm-sized AVM nidus supplied by two

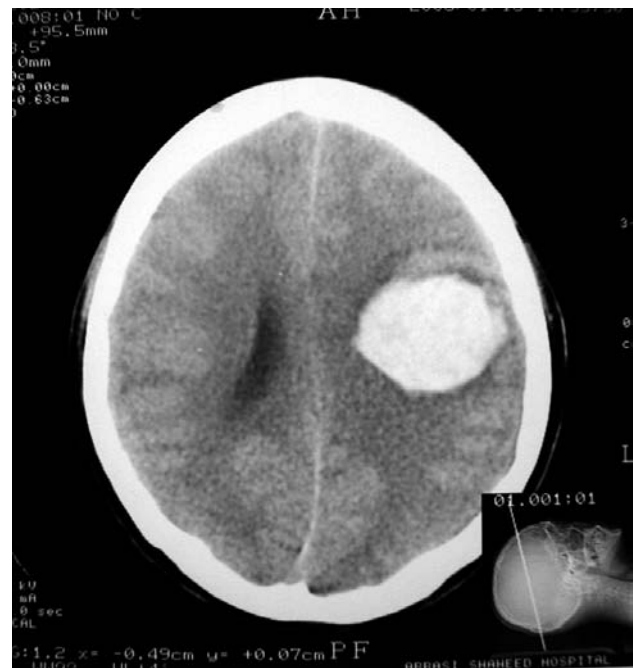

Figure 1. Left parietal hemorrhage.

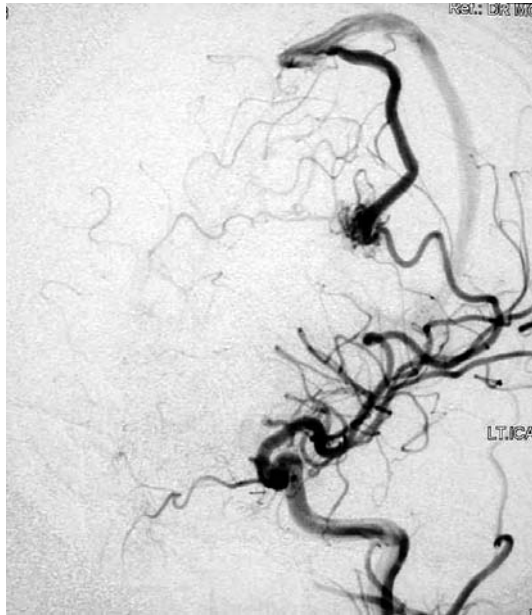


Figure 2. AVM with two arterial feeders (major and minor), a small nidus, and a draining vein.

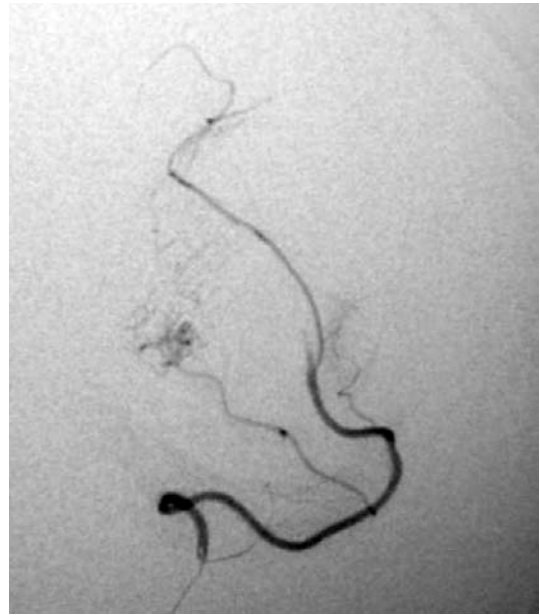

Figure 4. Post-embolization: tiny arterial feeder is still supplying the nidus

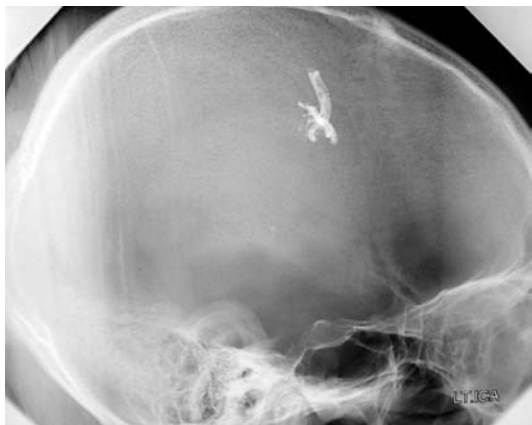

Figure 3. Histoacryl glue seen in AVM with reflux in draining vein.

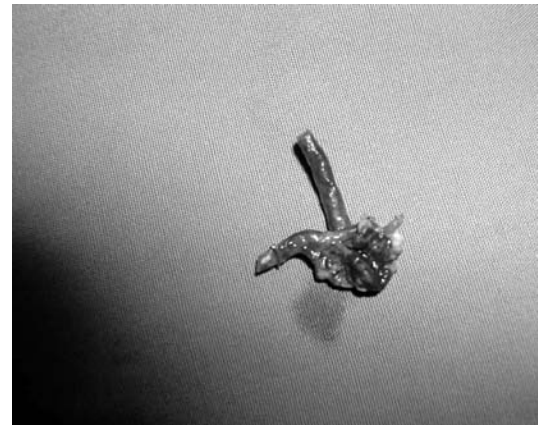

Figure 5. Surgically excised AVM specimen.

branches of the left middle cerebral artery (MCA) that was draining into a superficial cortical vein (Figure 2). With the help of a flow-guided microcatheter, the nidus was occluded via the major feeder with Histoacryl glue. Reflux of glue was noted into the draining vein (Figure 3).

A subsequent angiographic run revealed part of the nidus persistently filling up by a tiny proximal branch from the left MCA (Figure 4). It was not possible to manipulate the catheter through this tiny vessel despite multiple attempts. Due to reflux of glue into the draining vein, the risk of re-hemorrhage was significantly increased and immediate

surgery was planned. The patient was shifted to the operating room where left fronto-parietal craniotomy was performed under general anesthesia and successful excision of the left parietal AVM was done (Figure 5), along with evacuation of left parietal hematoma.

Following surgery, the patient was hemodynamically stable. Although he continued to have right-sided weakness and slurred speech, he was following commands (pre-procedural state). No endovascular or surgical complication was observed.

DISCUSSION

Arteriovenous malformations (AVMs) are the most common intracranial vascular malformation. Incidence of AVMs is one-seventh to one-tenth that of aneurysms, and AVMs occur in about 0.02% to 0.05% of the population. Varying degrees of thrombosis and calcification may be seen. Atrophy of the surrounding parenchyma caused by steal can be seen.

The usual presenting symptoms are seizures, progressive neurologic deficit, intractable headache, intracranial hemorrhage and hydrocephalus. About 64% of cases present by 40 years of age; 30% to 50% present secondary to hemorrhage. The risk of death from bleeding in a patient with an AVM is about 29%; an additional 20% to 30% of patients suffer neurologic deficits. Each bleeding episode carries a mortality rate of 10% to 15%.^{4,5} Hemorrhage from an AVM is usually related to an associated aneurysm, outflow restriction, or pure deep venous drainage.

For treatment of AVMs, the nidus of the lesion must be removed or obliterated. Surgical resection is the mainstay of treatment. Only when the surgical approach or actual removal of the AVM is risky is endovascular therapy contemplated. Because the endovascular cure rate for AVMs is only 5% to 10%, endovascular therapy usually is used for preoperative assistance, or to shrink the mass as much as possible before radiosurgery, which is another therapeutic option.

Embolization is a good adjuvant to surgery. Although a very large range of materials have been used to try and embolize intracranial AVMs, it was the introduction of acrylate adhesive agents that have had the most impact. Acrylate-based glues are now the mainstay of intracranial AVM embolization.

Endovascular therapy for intracranial AVMs is now employed widely with a high degree of success and relatively infrequent complications. Recently, the more predictable embolic agent onyx has been introduced which allows targeted delivery to the nidus. Risks associated with the use of these agents include stroke or cranial nerve dysfunction due to unintended branch occlusions, hemorrhage, obstruction of venous outflow due to reflux in the draining vein, and cementing of catheter in the vessel.⁶

In our case, reflux in the draining vein occurred which occluded outflow while inflow was still present by the other tiny arterial feeder. The patient's blood pressures were kept low during the procedure and there was a high

probability that as soon as blood pressures returned to normal, hemorrhage would recur. Therefore it was imperative that immediate surgery was planned for the resection of the AVM. Through this report, we also wish to highlight the multidisciplinary approach that must underpin any effective clinical approach to AVMs.

REFERENCES

1. Al-Rodhan NRF, Sundt TM, Piepgras DG, et al. Occlusive hyperemia: A theory for the hemodynamic complications following resection of intracerebral arteriovenous malformations. *J Neurosurg* 1993; **78**:167-175.
2. Brown RD, Wiebers DO, Torner JC, O'Fallon WM. Incidence and prevalence of intracranial vascular malformations in Olmsted County, Minnesota, 1965 to 1992. *Neurology* 1996; **340**:1812-18.
3. Spetzler RF, Martin NA. A proposed grading system for arteriovenous malformation. *J Neurosurgery* 1986; **65**:476-786
4. Jessurun GA, Kamphuis DJ, Zande FH, et al. Cerebral arteriovenous malformations in the Netherland Antilles: high prevalence of hereditary hemorrhagic telangiectasia-related single and multiple cerebral arteriovenous malformations. *Clin Neurol Neurosurg* 1993; **95**:193-198.
5. Albert P, Salgado H, Polaina M, et al. A study on the venous drainage of 150 cerebral malformations as related to hemorrhagic risks and size of the lesion. *Acta Neurochir (Wein)* 1990; **103**:30-34.
6. Debrun GM, Aletich V, Ausman JI, et al. Embolization of nidus of brain arteriovenous malformations with n-butylcyanoacrylate. *Neurosurgery* 1997; **40**:112-21.