



12-2011

# Snap, Crackle & Pop a Normal Variant of Increased Insertional Activity: May Be Misleading For Electromyographer

Ghulam Shabbir  
*Aga Khan University*

M Al Hakami  
*Armed Forces Hospital Southern Region Khamis Mushayt, Saudi Arabia*

Manzoor A.L  
*Aga Khan University*

Asad Ullah  
*Aga Khan University*

Mustafa Khan  
*Aga Khan University*

Follow this and additional works at: <https://ecommons.aku.edu/pjns>

 Part of the [Neurology Commons](#)

## Recommended Citation

Shabbir, Ghulam; Al Hakami, M; A.L, Manzoor; Ullah, Asad; and Khan, Mustafa (2011) "Snap, Crackle & Pop a Normal Variant of Increased Insertional Activity: May Be Misleading For Electromyographer," *Pakistan Journal of Neurological Sciences (PJNS)*: Vol. 6 : Iss. 4 , Article 7.

Available at: <https://ecommons.aku.edu/pjns/vol6/iss4/7>

# SNAP, CRACKLE & POP, A NORMAL VARIANT OF INCREASED INSERTIONAL ACTIVITY: MAY BE MISLEADING FOR ELECTROMYOGRAPHER

Ghulam Shabbir<sup>1</sup>, Mohd Al-Hakami<sup>2</sup>, Manzoor A. Lakhair<sup>1</sup>, Assadullah<sup>1</sup>, Mustafa Khan<sup>1</sup>

<sup>1</sup>Department of Neurophysiology Aga Khan University Hospital, Karachi, Pakistan

<sup>2</sup>Department of Medicine AFHSR, Khams Mushayt Kingdom of Saudi Arabia

Correspondence to: Ghulam Shabbir, Armed Forces Hospital Southern Region, Khams Mushayt, Kingdom of Saudi Arabia. Tel: 00966548177324, Email: ghulam.shabbir@hotmail.com

Pak J Neurol Sci 2011; 6(4): 24 - 26

## ABSTRACT

Four well built male patients were referred for nerve conduction studies and electromyography with query of possible neuromuscular problems. In all patients we noted, wide spread increased insertional activity (predominantly positive sharp waves) on needle examination, including frontalis muscle of the face, normal morphology of motor unit action potentials with normal recruitment and full interference pattern. One of the patients had an electrodiagnostic study done from another neurophysiologic centre which concluded a diffuse neurogenic process; differential diagnosis includes either anterior horn cells disorder or inflammatory myopathy. Our neurophysiologic data showed wide spread increased insertional activity on needle examination with normal nerve studies, indicating a normal variant called as snap, crackle and pop.

## INTRODUCTION

Historical aspect: The three elf<sup>1</sup> characters were originally designed by illustrator Vernon Grant and made their debut in 1933. The names of the elves are derived from a Rice Krispies radio ad. The ad said "Listen to the fairy song of health, the merry chorus sung by Kellogg's Rice Krispies as they merrily snap, crackle, and pop in a bowl of milk. If you've never heard food talking, now is your chance." Inspired by this ad, Grant drew three elves and named them snap, crackle, and pop.

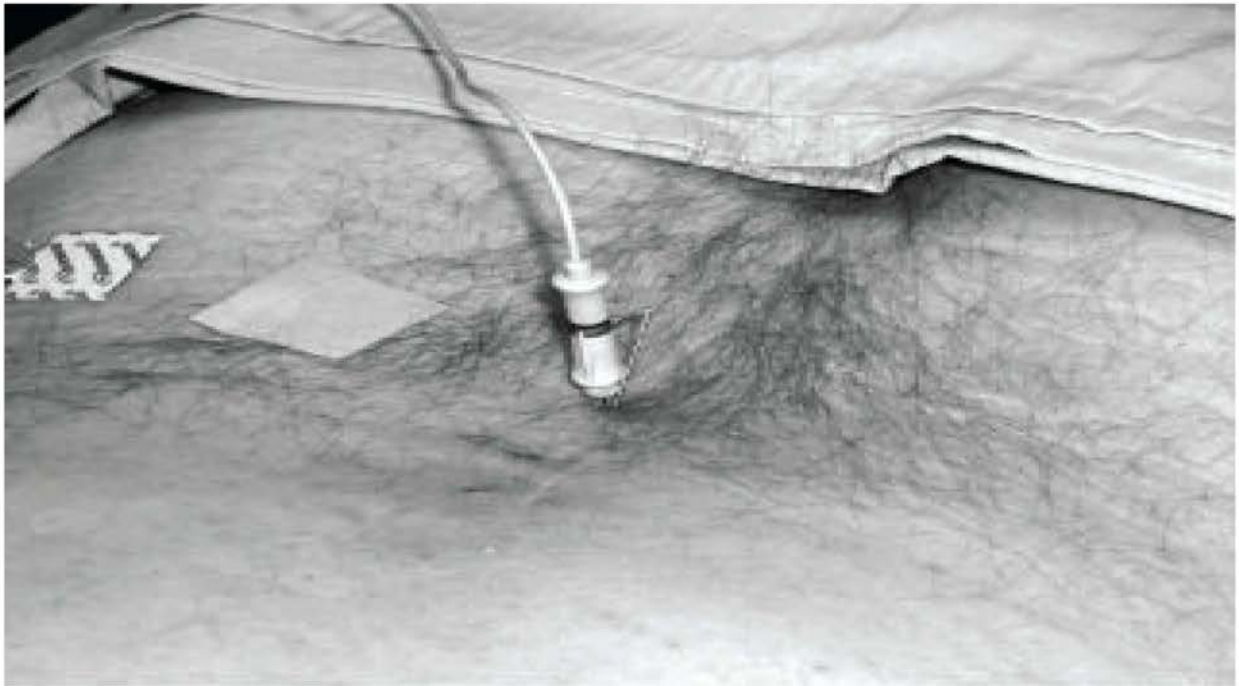
Neurophysiologic aspect: Placing needle recording electrode into muscle tissue and advancing it in quick but short intervals "JABS" results in brief bursts of electrical potentials. This results in a crispy sound, with a series of negative and positive spikes. These waves are referred as insertional activity, the total time duration of this activity after needle cessation has a mean of 48 +/- 18 milliseconds<sup>2</sup>. This time duration is different with type of needles, for monopolar needle is less than 230 milliseconds and less than 300 milliseconds for concentric needles. If this activity is more than 300-500 milliseconds, then its indicating pathology in nerve or muscle (neuropathic or myopathic process) and called as active denervation. Very rarely this prolongation in

duration of insertional activity as well as diffuse positive sharp waves and fibrillation potentials can be seen as a normal variant, which is called as Snap Crackle & Pop<sup>3</sup>. This is usually seen in young male patients, having history of bodybuilding (muscle making exercises)

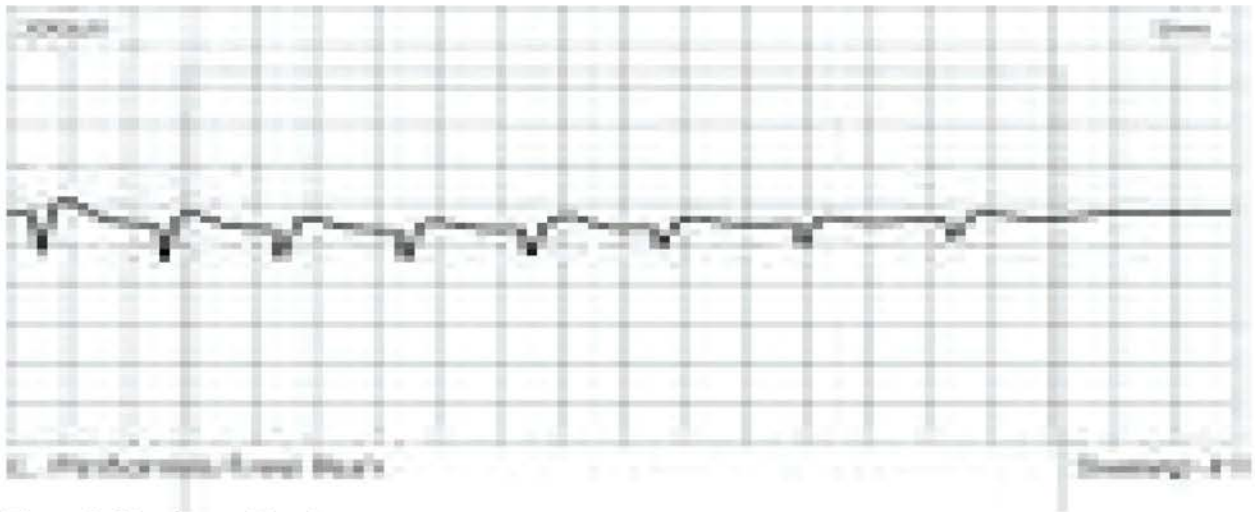
## CASE SERIES

**Patient 1:** 28 years old male patient with the history of hemodialysis through femoral cath, five days ago, now presented with right inguinal pain and difficulty in hip flexion. Clinical examination, well built muscle bulk, he was feeling pain in flexing the thigh over hip joint and local swelling with tenderness, rest of the examination was normal. Nerve conduction study, including the right femoral nerve was normal. Needle EMG assessment showed increased insertional activity, including genioglossus muscle, with normal morphology of motor unit action potentials, normal recruitment and full interference pattern, except the recruitment of right vastus medialis muscle because of pain, patient was not applying the proper force. (Figure 1 and figure 2 were taken after the written consent of patient.)

**Patient 2:** 35 years old overweight male patient was



**Figure 1:** Showing needle insertion



**Figure 2:** Showing positive sharp waves

---

retrospectively collected from the patient's records. He had been referred for pain and numbness in both hands; however, neurological examination was normal. Needle EMG assessment showed increased insertional activity, including genioglossus muscle, with normal morphology of motor unit action potentials, normal recruitment and full interference pattern. However nerve conduction studies revealed bilateral moderate carpal tunnel syndrome.

**Patient 4:** This gentleman was a 24 years old Kabaddi player who came for the assessment of some possible injury to left peroneal nerve during local match. Nerve conduction study was normal (study done within 8 days of injury) and suggested to repeat the study after two weeks duration. The needle EMG findings were same as those found in other patients described in this study.

## DISCUSSION

Very few cases of snap, crackle & pop were reported in literature, first case report published in 1988<sup>4</sup> and subsequently few more cases were reported and they labeled this as a normal variant.

As normal time duration of insertional activity varies among the individuals, races, regions and built of patients, in different studies the time duration is variable, ranging from 18-500 ms. Due to these facts, chances of erroneous interpretations are quite high. Snap, crackle & pop need more precise normative data of neurophysiologic laboratories, according to local population and more expertise.

## CONCLUSION

Electromyographer as well as the neurologist should be aware about the normal variants or artifacts like Snap Crackle & Pop, before diagnosing the patients with neurological disorders like motor neuron disease. Further larger studies may be more helpful in addressing the issue and any possible mechanisms underlying this normal variant in healthy young males.

## REFERENCES

1. <http://kelloggs.mediaroom.com/file.php/119/BIO+Snap!+Crackle!+Pop!>
2. Brown bulletin page 264.
3. Muscle Nerve 39:244-270,2009.
4. Arch. Phys. Med. Rehabil. 69 (1988).