



12-2011

# Cryptococcal Meningitis in a Patient with Diabetes Mellitus and Chronic Liver Disease Case Report with Neuroimaging

Abdul Salam

*Shifa International Hospital*

Arsalan Ahmad

*Shifa International Hospital*

Ayesha Junaid

*Shifa International Hospital*

Ismail A Khatri

*Shifa International Hospital*

Maimoona Siddiqui

*Shifa International Hospital*

Follow this and additional works at: <https://ecommons.aku.edu/pjns>

 Part of the [Neurology Commons](#)

## Recommended Citation

Salam, Abdul; Ahmad, Arsalan; Junaid, Ayesha; Khatri, Ismail A; and Siddiqui, Maimoona (2011) "Cryptococcal Meningitis in a Patient with Diabetes Mellitus and Chronic Liver Disease Case Report with Neuroimaging," *Pakistan Journal of Neurological Sciences (PJNS)*: Vol. 6 : Iss. 4 , Article 6.

Available at: <https://ecommons.aku.edu/pjns/vol6/iss4/6>

# CRYPTOCOCCAL MENINGITIS IN A PATIENT WITH DIABETES MELLITUS AND CHRONIC LIVER DISEASE - CASE REPORT WITH NEUROIMAGING

Abdul Salam<sup>1</sup>, Arsalan Ahmad<sup>1</sup>, Ayesha Junaid<sup>2</sup>, Ismail A. Khatri<sup>1</sup>, Maimoona Siddiqui<sup>1</sup>

<sup>1</sup>Division of Neurology, Shifa International Hospital, Islamabad

<sup>2</sup>Department of Pathology, Shifa International Hospital, Islamabad

Correspondence to: Arsalan Ahmad, Division of Neurology, Shifa International Hospital, Sector H-8/4, Islamabad, Pakistan. , Email: drarsalan65@yahoo.com Tel: (92-51) 460-3175

Pak J Neurol Sci 2011; 6(4): 19 - 23

## ABSTRACT

**Introduction:** Most cases of cryptococcal meningitis occur in patients with HIV infection. In the absence of HIV, neurological disease occurs most commonly in immunosuppressed patients and evolves subacutely like tuberculosis.

**Objective:** We report a case of cryptococcal meningitis in a patient with diabetes mellitus and chronic liver disease.

**Case Report:** A 69 years old woman, diagnosed with diabetes mellitus and chronic liver disease, presented with seizures, vertigo, nausea, tinnitus and episodes of weakness of left arm. Neurological examination showed mild weakness of the right side of the body with normal reflexes and bilaterally down-going plantars. MRI brain with contrast showed features consistent with leptomeningitis. The cerebrospinal fluid (CSF) showed lymphocytic pleocytosis. India ink preparation of CSF showed cryptococcus. She was treated with intravenous amphotericin B followed by oral fluconazole. **Conclusion:** Cryptococcal meningitis should be considered in the differential diagnosis of tuberculous (TB) meningitis and workup for fungal infections should be sent in immunocompromised as well as immunocompetent patients.

## INTRODUCTION

There is an increased incidence of cryptococcal meningitis in recent years, both in human immunodeficiency virus (HIV) positive and negative patients<sup>1</sup>. Cryptococcus neoformans and Cryptococcus gattii commonly cause severe infections of the central nervous system in patients who are immunodeficient but also increasingly in immunocompetent individuals. These two encapsulated yeast species can cause life-threatening infections of the central nervous system e.g., meningoencephalitis<sup>2</sup>.

Cryptococcal meningitis rarely occurs in healthy individuals with no obvious predisposing factors; therefore, specific treatment is not initiated until the organism is identified or a cryptococcal antigen is detected<sup>3</sup>. Cryptococcal meningitis should be considered in the differential diagnosis of chronic meningitis. Rapid diagnosis and timely treatment of cryptococcal meningitis is essential to reduce the mortality.

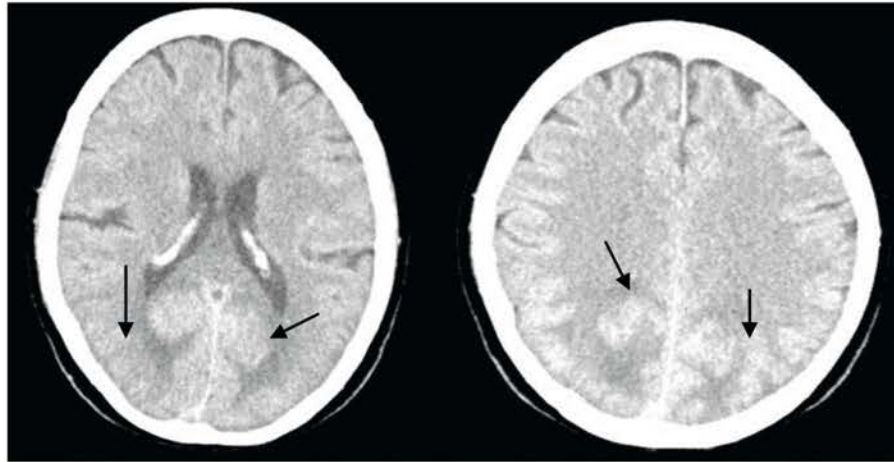
Recommended initial therapy is a combination of

amphotericin B and flucytosine for the first two weeks. Fluconazole is started after two weeks of combination therapy<sup>4</sup>. The majority of the patients with cryptococcal meningitis improve with adequate therapy<sup>5</sup>.

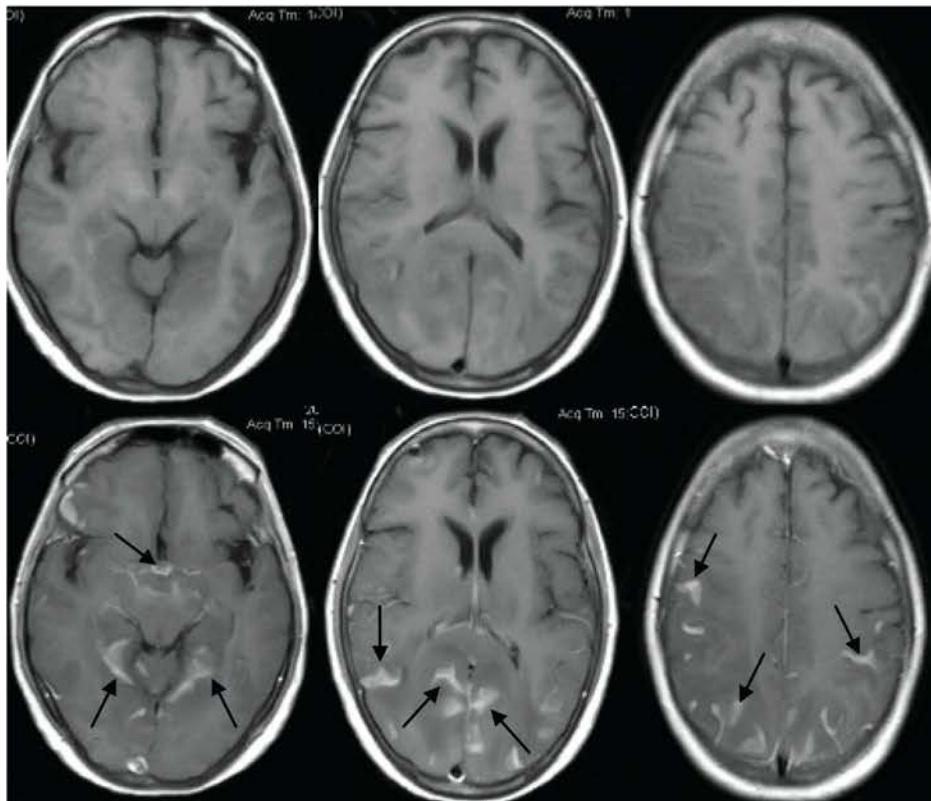
We report a case of Cryptococcus as the cause of meningitis, in a non-HIV patient with diabetes mellitus and chronic liver disease, who was initially misdiagnosed as tuberculous meningitis.

## CASE REPORT

A 69 years old woman presented with stiffness of whole body associated with up-rolling of eyes and frothing from the mouth for 10 minutes. There was no associated tonic clonic seizure, tongue bite, fecal or urinary incontinence. There was no weakness or numbness of any limb, no visual or speech problem. She had 3 similar episodes in last 2 weeks. Patient was a diagnosed case of chronic liver disease, diabetes mellitus and hypertension. On initial examination her blood pressure was 135/80 mm of Hg and



**Figure 1:** Axial non-contrast CT Brain images showing vasogenic edema in occipital lobes (arrows).



**Figure 2:** T1 weighted axial images without contrast (above) and with contrast (below) showing intense enhancement of cortical sulci in bilateral cerebral hemispheres and basal cisterns suggestive of leptomeningitis (arrows).

pulse was 82 beats per minute. She had no fever and was fully oriented in time, place and person. Her neurological examination was unremarkable except for slightly decreased effort related muscle power in all four limbs. There were no signs of meningeal irritation. The respiratory system, cardiovascular system, and abdominal examinations were all normal.

Laboratory investigations revealed platelets count of 89000, with normal WBC count of 6400/mm<sup>3</sup>. Liver function tests (LFTs) were deranged with ALT 76 and AST 115. Serum albumin was 3.07 mg/dl and serum sodium was 123 mEq/L with normal renal function tests. Unenhanced CT scan of the brain (figure 1) showed vasogenic edema in occipital lobes and in right subcortical white matter which could represent Posterior Reversible Encephalopathy Syndrome (PRES). EEG showed intermittent rhythmic delta slowing predominantly in left temporal region, with no electrographical seizure activity.

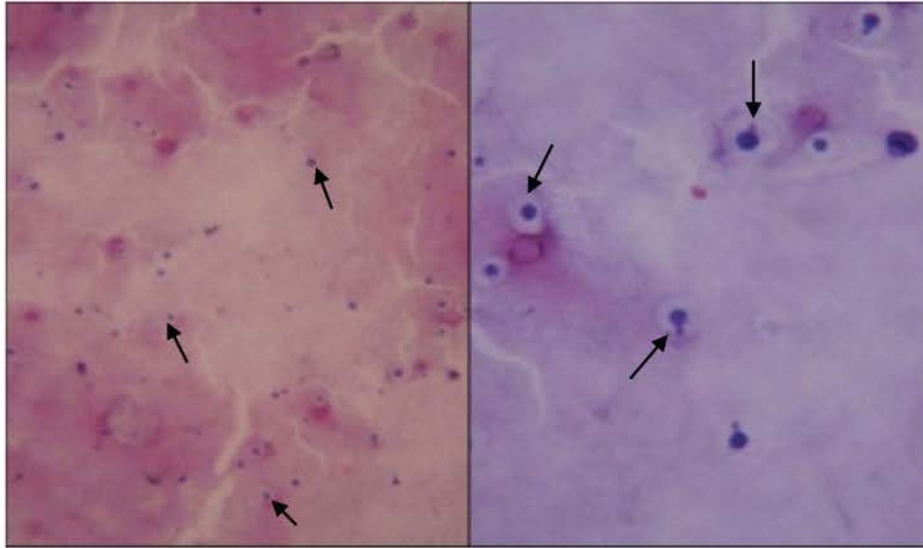
She was started on oral levetiracetam. Patient remained seizure free and was discharged on oral levetiracetam with advice of OPD follow up after 2 weeks. On follow up visit, she complained of vertigo, nausea, tinnitus and episodes of weakness of left arm lasting for few minutes to hours. Neurological examination showed symmetrical face, left pronator drift, muscle strength was MRC grade 4 in the left arm and leg, and 5/5 on right side. Deep tendon reflexes were bilaterally symmetrical and normal with flexor plantars. MRI brain with contrast (figure 2) showed intense, thick enhancement of cortical sulci in bilateral cerebral hemispheres and basal cisterns suggestive of leptomeningitis. Diagnostic lumbar puncture (LP) was performed which showed 40 leukocytes/ $\mu$ l (85% lymphocytes and 15% polymorphs). The CSF glucose was low (36 mg/dl) and proteins were 315 mg/dl. Modified antituberculous therapy (ATT) with rifampicin 300 mg once daily was started, along with intravenous dexamethasone (8 mg I/V q 6 h). LP repeated five days later considering possibility of carcinomatous meningitis, revealed 30 leukocytes/ $\mu$ l (95% lymphocytes and 5% polymorphs) with glucose of 54 mg/dl and proteins were 90 mg/dl. Few segments of fungus like structure were also seen on gram stain. India ink preparation showed Cryptococcus (figure 3). CSF culture also showed growth of cryptococcus. Patient received intravenous amphotericin B for 2 weeks. She was discharged on oral fluconazole (100 mg twice a day for 4 weeks). Patient did not come for follow-up.

## DISCUSSION

Meningitis and meningoencephalitis are the most common manifestations of CNS cryptococcosis and are usually subacute or chronic in nature. Cryptococcal meningitis mostly occurs in patients who are immunodeficient such as those with acquired immunodeficiency syndrome (AIDS). Among non-HIV persons, cryptococcal meningitis occurs in patients who are immunodeficient due to diabetes mellitus, cancer, solid organ transplants, chemotherapeutic drugs, hematological malignancies, etc. and rarely in healthy individuals with no obvious predisposing factors<sup>6</sup>. The patient in this case report was immunodeficient due to diabetes mellitus and chronic liver disease secondary to hepatitis C. In cryptococcal meningitis, classic meningitic findings such as fever and neck stiffness are less common. The most common symptoms are headache and altered mental status. Other findings are nausea and vomiting, focal deficits, hearing defects, seizures and choreoathetoid movements<sup>7</sup>. The initial presenting complaint in our patient was seizures with no other symptoms suggestive of meningitis and her neurological examination was normal. Subsequently, she developed vertigo, nausea, tinnitus and episodic left arm weakness.

Cryptococcal meningitis is considered in the differential diagnosis of tuberculous meningitis and carcinomatous/lymphomatous meningitis<sup>5</sup>. This exactly happened in case of our patient; she was first treated on the lines of tuberculous meningitis based on subacute nature of the disease, MRI findings (intense leptomeningeal enhancement) and CSF findings (lymphocytic pleocytosis with raised protein and low sugar levels). CSF which was repeated considering possibility of carcinomatous meningitis, showed cryptococcus by India ink stain and CSF fungal culture showed growth of cryptococcus. Neuroimaging of the brain is carried out in all suspected cases of chronic meningitis before a lumbar puncture. CT brain or MRI brain is usually normal but may reveal diffuse atrophy of the brain<sup>8</sup>. CSF routine analysis usually shows lymphocytic pleocytosis with raised protein and low sugar levels. The diagnosis of cryptococcal meningitis can be established with India ink stain in > 50% of the cases of cryptococcal meningitis in HIV-negative cases and in > 90% of patients with AIDS<sup>9</sup>. A positive fungal culture is the gold standard for diagnosis of cryptococcal infection and CSF samples shows fungal growth in almost all the cases<sup>10</sup>.

This is a fatal infection without treatment. Therefore, rapid diagnosis and treatment is required<sup>11</sup>. Most of the patients with cryptococcal meningitis improve with adequate therapy. HIV-positive individuals have higher mortality<sup>5</sup>. A high index of suspicion is needed for early



**Figure3:** India ink preparation of CSF on low power field (left) and high power field (right) showing classical halo of cryptococcus (arrows).

diagnosis. India ink stain and the cryptococcal antigen assay should be used for the diagnosis of cryptococcal meningitis. Early diagnosis and adequate treatment is helpful in saving the lives of patients.

Patient with cryptococcal infection needs timely and adequate antifungal therapy. Patients with cryptococcal meningitis but without AIDS should be given amphotericin B (0.7-1 mg/kg/day) alone or in combination with flucytosine (100 mg/kg/day in 4 divided doses). Amphotericin B can be administered alone for 6-10 weeks or in conjunction with flucytosine for 2 weeks, followed by fluconazole for a minimum of 10 weeks<sup>12</sup>. Duration of therapy is based on CSF examination results. CSF is examined weekly until culture conversion is documented and cultures remain negative for 4 weeks. In most cases, 6-10 weeks of therapy with amphotericin B is adequate.

## CONCLUSION

Cryptococcal meningitis is the most common, opportunistic CNS fungal infection in immunocompromised individuals. Cryptococcal meningitis should be considered in the differential diagnosis of chronic meningitis. This infection is fatal without treatment. Therefore, rapid diagnosis and treatment is required to reduce mortality. Many patients with cryptococcal meningitis would recover with timely and adequate antifungal therapy.

## REFERENCES

1. Gupta P, Malik S, Khare V, Banerjee G, Mehrotra A, Mehrotra S, et al. A fatal case of meningitis caused by *Cryptococcus neoformans* var. *grubii* in an immunocompetent male. *J Infect Dev Ctries.* 2011;5: 71-4.
2. Voelz K, Lammas DA, May RC. Cytokine Signaling Regulates the Outcome of Intracellular Macrophage Parasitism by *Cryptococcus neoformans*. *Infect Immun.* 2009; 77 : 3450-57.
3. Satpute MG, Telang NV, Litake GM, Niphadkar KB, Joshi SG. Prevalence of Cryptococcal Meningitis at a Tertiary care centre in Western India (1996-2005). *J Med Microbiol.* 2006; 55: 1301-02.
4. Bicanic T, Harrison TS. Cryptococcal meningitis. *Br Med Bull.* 2005; 72: 99-118.
5. Satishchandra P, Mathew T, Gadre G, Nagarathna S, Chandramukhi A, Mahadevan A, et al . Cryptococcal meningitis: Clinical, diagnostic and therapeutic overviews. *Neurol India.* 2007; 55: 226-32.
6. Mirza SA, Phelan M, Rimland D, Graviss E, Hamill R, Brandt ME, et al . The changing epidemiology of cryptococcosis: An update from population-based active surveillance in 2 large metropolitan areas, 1992-2000. *Clin Infect Dis.* 2003; 36: 789-94.
7. King JW, DeWitt, ML. Cryptococcosis. Available: <http://emedicine.medscape.com/article/215354-overview>. Accessed 08 August 2011.

- 
8. Santosh V, Yasha TC, Panda KM.. Pathology of AIDS: Study from a neuropsychiatric center from south India. *Ann Indian Acad Neurol* .1998; 1: 71-82.
  9. Pappas PG, Perfect JR, Cloud GA, Larsen RA, Pankey GA, Lancaster DJ, et al . Cryptococcosis in human immunodeficiency virus-negative patients in the era of effective azole therapy. *Clin Infect Dis*. 2001; 33: 690-9.
  10. Khanna N, Chandramuki A, Desai A, Ravi V, Santhosh V, Shankar SK, et al . Cryptococcosis in the immunocompromized host with special reference to AIDS. *Indian J Chest Dis Allied Sci*. 2000; 42: 311-5.
  11. Kumar S, Wanchu A, Chakrabarti A, Sharma A, Bambery P, Singh S. Cryptococcal meningitis in HIV infected: experience from a North Indian tertiary center. *Neurol India*. 2008; 56: 444–9.
  12. King JW, DeWitt, ML. Cryptococcosis. Available: <http://emedicine.medscape.com/article/215354-treatment>. Accessed 08 August 2011.