



THE AGA KHAN UNIVERSITY

eCommons@AKU

Section of Neurosurgery

Department of Surgery

January 2018

# Prognostic value of 1p/19q chromosomal codeletion in patients with oligodendroglioma

Altaf Ali Laghari

Aga Khan University, [altaf.alilaghari@aku.edu](mailto:altaf.alilaghari@aku.edu)

Usman Khalid

Aga Khan University

Namra Qadir

Aga Khan University

Muhammad Shahzad Shamim

Aga Khan University, [shahzad.shamim@aku.edu](mailto:shahzad.shamim@aku.edu)Follow this and additional works at: [https://ecommons.aku.edu/pakistan\\_fhs\\_mc\\_surg\\_neurosurg](https://ecommons.aku.edu/pakistan_fhs_mc_surg_neurosurg)

## Recommended Citation

Laghari, A., Khalid, U., Qadir, N., Shamim, M. (2018). Prognostic value of 1p/19q chromosomal codeletion in patients with oligodendroglioma. *Journal of the Pakistan Medical Association*, 69(1), 132-134.

**Available at:** [https://ecommons.aku.edu/pakistan\\_fhs\\_mc\\_surg\\_neurosurg/174](https://ecommons.aku.edu/pakistan_fhs_mc_surg_neurosurg/174)

## Prognostic value of 1p/19q chromosomal codeletion in patients with oligodendroglioma

Altaf Ali Laghari, Muhammad Usman Khalid, Namra Qadeer, Muhammad Shahzad Shamim

### Abstract

Oligodendrogliomas are common intra-axial primary brain tumours, and carry special significance due to several key features, which when present provide better prognosis compared to other intra-axial tumours. One of these features is presence of 1p/19q chromosomal codeletion that seems to not only be a marker of better prognosis but also signifies better response to chemotherapy. Herein the authors review the literature for evidence of the prognostic value of 1p/19q codeletion in OD.

**Keywords:** Glioma, Oligodendroglioma, chemotherapy.

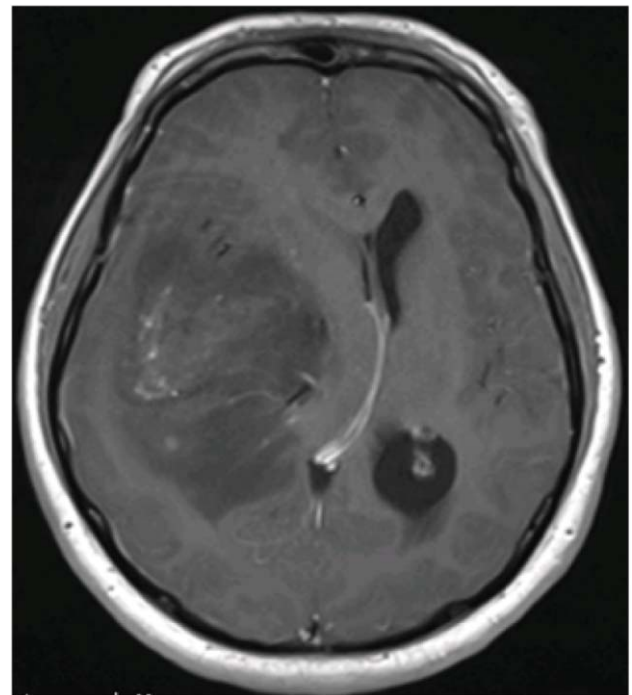
### Introduction

Oligodendrogliomas (OD) account for 10% of all gliomas and 4% of all primary brain tumours.<sup>1</sup> They are diffusely infiltrating tumours, arising from the white matter of cerebral hemispheres. These tumours characteristically show better prognosis compared to most other gliomas, especially in the presence of certain features such as young age at presentation, good performance status at presentation and after surgery, frontal location, and combined loss of 1p/19q.<sup>2</sup> 1p/19q chromosomal codeletion seems to not only be a marker of better prognosis but also signifies increased response to adjuvant therapy with selective drugs.<sup>3,4</sup> Longer progression free survival (PFS) has been noted amongst patients who had been treated for a confirmed 1p/19q codeleted OD, although improvement in overall survival (OS) has not been definitively established. Genetic analysis of these tumours is now recognized at the basis for classification of tumour type, and for the prediction of biological behaviour, and response to therapeutic modalities. There is extensive literature and numerous clinical trials exploring the relationship between prognosis of OD with 1p/19q codeletion. This review

focuses on a few of these articles to provide a brief yet holistic picture on the topic.

### Review Of Evidence

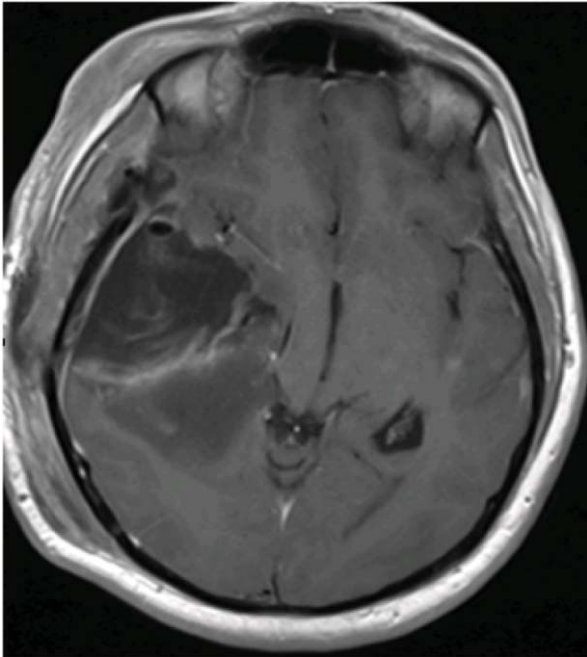
As early as 2000, Smith et al., demonstrated that 1p/19q chromosomal loss in pure OD was a statistically significant indicator of prolonged survival.<sup>5</sup> Cairncross et al.<sup>6</sup>, did an exhaustive research on 289 patients diagnosed with anaplastic OD and their response to radiotherapy (RT) alone compared to RT with procarbazine, lomustine, and vincristine (PCV) chemotherapy with the conclusion that PCV with RT did not prolong survival.<sup>6</sup> Jenkins et al., then through sequencing and following up 119 patients, predicted a better overall survival of approximately one year for patients with low grade OD featuring 1p/19q codeletion or translocation, especially those who received higher doses of RT.<sup>7</sup> Van den Brent et al., also conducted a major study in 2006 with a total of 368 patients with anaplastic OD enrolled and followed up for a median of



**Figure-1(a):** MRI T1WI with contrast showing a heterogeneously enhancing oligodendroglioma in right temporoparietal region.

.....  
Department of Surgery, Section of Neurosurgery, Aga Khan University Hospital, Karachi, Pakistan.

**Correspondence:** Muhammad Shahzad Shamim.  
Email: shahzad.shamim@aku.edu



**Figure-1(b):** Post-operative MRI T1WI with contrast scan of the same patient showing maximal safe resection.

60 months.<sup>8</sup> Patients were either given 33 cycles of RT or PCV with RT, OS was significantly higher in RT with PCV therapy although 36% of patients had to discontinue PCV due to toxicity. They concluded that although overall survival was unchanged, progression-free survival was significantly better in patients who had OD with 1p/19q chromosomal co-deletion. In 2012 Yip et al., further analyzed chromosomal mutations of 1p/19q and genes encoding isocitrate dehydrogenase (IDH) as diagnostic markers for ODs.<sup>9</sup> Lecavalier-Barsoumet al., in 2014, systematically reviewed treatment modalities for anaplastic oligodendrogliomas with the aim of establishing the predictive and prognostic value of markers such as 1p/19q co-deletion.<sup>10</sup> To this effect PCV prior to RT increased mean overall survival, with the subset of ODs with 1p/19q chromosomal codeletion showing increased sensitivity to combined PCV with RT. However, grade 3 and 4 toxicities were noted with PCV therapy and a conclusive replacement with temozolomide was unable to be ascertained. Li et al., in 2014 again, studied and followed a 100 cases of OD and were able to associate 1p/19q loss, as well as Sox-17 protein, to better prognosis.<sup>11</sup> Sabha et al., also investigated a cohort of 108 non-enhancing hemispheric grade II-III gliomas with results indicating that 1p/19q loss was predictive of overall survival but not progression free survival.<sup>12</sup> Interestingly IDH mutation was shown to be indicative of both and merits further studies. In 2016,

Hataet al., retrospectively analyzed the long-term outcome of a case series (36 patients) with OD treated with RT and procarbazine, nimustine, vincristine (PAV) therapy.<sup>3</sup> Their results showed that IDH mutation and 1p/19q loss were the prognostic factors to consider for OD, not WHO grade, furthermore there was a significantly better prognosis for patients with 1p/19q co-deletion. In 2017 Hacisalihoglu et al., followed through with a retrospective analysis of 41 anaplastic OD cases, 35 patients received standard radiotherapy whilst 26 patients then underwent additional chemotherapy with temozolomide.<sup>2</sup> In the 19 patients who had chromosomal 1p/19q co-deletion, progression free survival was noted to be significantly higher, regardless of treatment modality. Lastly McNamraet al., did a retrospective analysis on 106 patients in 2017 to determine treatment outcomes in patients diagnosed with gliomas with full or partial 1p/19q codeletion.<sup>13</sup> Of these patients, 66% had full 1p/19q chromosomal co-deletion and these were found to have better progression free survival than those with no co-deletion or 1p or 19q codeletion alone. In addition upfront therapy (in some cases with temozolamide alone) was found to have prognostic value similar to 1p/19q co-deletion.

## Conclusion

Chromosomal codeletion of 1p/19q is predictive of a favourable prognosis for patients regardless of treatment. Presence of co-deletion however is particularly indicative of sensitivity to PCV therapy, in conjunction with radiotherapy. Temozolomide is a promising alternative to PCV but as of this moment in time its efficacy compared to PCV in OD with 1p/19q co-deletion is not well established. In addition, studies seem split on whether 1p/19q loss provides better overall survival or progression free survival though most studies do point towards the latter.

## References

1. MirzaFA, Shamim MS. Extent of resection and timing of surgery in adult low grade glioma. *J Pak Med Assoc* 2017; 67: 959-961.
2. Hacisalihoglu P, Kucukodaci Z, Gundogdu G, Bilgic B. The correlation between 1p/19q codeletion, IDH1 mutation, p53 overexpression and their prognostic roles in 41 Turkish anaplastic oligodendroglioma patients. *TURK NEUROSURG* . 2017;27:682-9.
3. Hata N, Yoshimoto K, Hatae R, Kuga D, Akagi Y, Suzuki SO, et al. Deferred radiotherapy and upfront procarbazine-ACNU-vincristine administration for 1p19q codeleted oligodendroglial tumors are associated with favorable outcome without compromising patient performance, regardless of WHO grade. *Onco Targets Ther*. 2016;9:7123-31.
4. Van den Bent MJ, Reni M, Gatta G, Vecht C. Oligodendroglioma. *Crit Rev Oncol Hematol* . 2008;66:262-72.
5. Smith JS, Perry A, Borell TJ, Lee HK, O'Fallon J, Hosek SM, et al. Alterations of chromosome arms 1p and 19q as predictors of survival in oligodendrogliomas, astrocytomas, and mixed

- oligoastrocytomas. *J. Clin. Oncol: official journal of the American Society of Clinical Oncology.* 2000;18:636-45.
6. Cairncross G, Berkey B, Shaw E, Jenkins R, Scheithauer B, Brachman D, et al. Phase III trial of chemotherapy plus radiotherapy compared with radiotherapy alone for pure and mixed anaplastic oligodendroglioma: Intergroup Radiation Therapy Oncology Group Trial 9402. *J. Clin. Oncol: official journal of the American Society of Clinical Oncology.* 2006;24:2707-14.
  7. Jenkins RB, Blair H, Ballman KV, Giannini C, Arusell RM, Law M, et al. A t(1;19)(q10;p10) mediates the combined deletions of 1p and 19q and predicts a better prognosis of patients with oligodendroglioma. *Cancer Res.* 2006;66:9852-61.
  8. Van den Bent MJ, Carpentier AF, Brandes AA, Sanson M, Taphoorn MJ, Bernsen HJ, et al. Adjuvant procarbazine, lomustine, and vincristine improves progression-free survival but not overall survival in newly diagnosed anaplastic oligodendrogliomas and oligoastrocytomas: a randomized European Organisation for Research and Treatment of Cancer phase III trial. *J. Clin. Oncol: official journal of the American Society of Clinical Oncology.* 2006;24:2715-22.
  9. Yip S, Butterfield YS, Morozova O, Chittaranjan S, Blough MD, An J, et al. Concurrent CIC mutations, IDH mutations, and 1p/19q loss distinguish oligodendrogliomas from other cancers. *J PATHOL.* 2012;226:7-16.
  10. Lecavalier-Barsoum M, Quon H, Abdulkarim B. Adjuvant treatment of anaplastic oligodendrogliomas and oligoastrocytomas. *Cochrane Database Syst Rev*2014:CD007104.
  11. Li J, Miao N, Liu M, Cui W, Liu X, Li X, et al. Clinical significance of chromosome 1p/19q loss of heterozygosity and Sox17 expression in oligodendrogliomas. *Int J Clin Exp Pathol .* 2014;7:8609-15.
  12. Sabha N, Knobbe CB, Maganti M, Al Omar S, Bernstein M, Cairns R, et al. Analysis of IDH mutation, 1p/19q deletion, and PTEN loss delineates prognosis in clinical low-grade diffuse gliomas. *Neuro Oncol* 2014;16:914-23.
  13. McNamara MG, Jiang H, Lim-Fat MJ, Sahebjam S, Kiehl TR, Karamchandani J, et al. Treatment Outcomes in 1p19q Co-deleted/Partially Deleted Gliomas. *Can J Neurol Sci.* 2017;44:288-94.
-