



10-2011

# Interobserver Variation between Neuroradiologist and Radiology Resident in the MRI Evaluation of Lumbar Disc Herniation and Nerve Root Compression

Imaad ur Rehman  
*Aga Khan University*

Rana Shoaib Hamid  
*Aga Khan University*

Waseem Akhtar  
*Aga Khan University*

Rohana Nazqi  
*Aga Khan University*

Mirza Amanullah Beg  
*Aga Khan University*

*See next page for additional authors*

Follow this and additional works at: <https://ecommons.aku.edu/pjns>

 Part of the [Neurology Commons](#)

## Recommended Citation

Rehman, Imaad ur; Shoaib Hamid, Rana; Akhtar, Waseem; Nazqi, Rohana; Beg, Mirza Amanullah; and Ismail Siddiq, Haji (2011) "Interobserver Variation between Neuroradiologist and Radiology Resident in the MRI Evaluation of Lumbar Disc Herniation and Nerve Root Compression," *Pakistan Journal of Neurological Sciences (PJNS)*: Vol. 6 : Iss. 3 , Article 4.  
Available at: <https://ecommons.aku.edu/pjns/vol6/iss3/4>

---

# Interobserver Variation between Neuroradiologist and Radiology Resident in the MRI Evaluation of Lumbar Disc Herniation and Nerve Root Compression

## **Authors**

Imaad ur Rehman, Rana Shoaib Hamid, Waseem Akhtar, Rohana Nazqi, Mirza Amanullah Beg, and Haji Ismail Siddiq



# INTEROBSERVER VARIATION BETWEEN NEURORADIOLOGIST AND RADIOLOGY RESIDENT IN THE MRI EVALUATION OF LUMBAR DISC HERNIATION AND NERVE ROOT COMPRESSION

Imaad ur Rehman<sup>1</sup>, Rana Shoaib Hamid<sup>1</sup>, Waseem Akhtar<sup>1</sup>, Rohana Naqi<sup>2</sup>, Mirza Amanullah Beg<sup>1</sup>, Haji Ismail Siddiq<sup>2</sup>

<sup>1</sup>Department of Radiology, Aga Khan University Hospital, Karachi, Pakistan

<sup>2</sup>Aga Khan University Hospital, Karachi, Pakistan

Correspondence to: Dr. Rana Shoaib Hamid, Department of Radiology, Aga Khan University Hospital, Stadium Road, PO Box 3500, Karachi, 74800, Pakistan. Tel: 021-34862032, Email: drschoaib@hotmail.com

Pak J Neurol Sci 2011; 6(3): 8 - 12

## ABSTRACT

**Objective:** To analyze interobserver variation between a neuroradiologist and a senior radiology resident in the evaluation of disc bulge, disc herniation, and nerve compression. **Materials & Methods:** Retrospective analysis was made of medical records and images of 55 patients who underwent MRI of lumbar spine for suspected spinal stenosis from March 2010 till July 2010 at Aga Khan University Hospital was done. A fellowship trained neuroradiologist and senior resident evaluated the images separately. Both observers were unaware of patient's history and clinical findings. Lumbar discs at L3-L4, L4-L5 and L5-S1 levels were evaluated by both observers for presence or absence of disc bulge, disc herniation and nerve root compression. Findings of both observers were recorded on a performa and analyzed with SPSS version 16. **Results:** Total 165 lumbar discs were studied by both readers in 55 patients. For assessment of disc bulge, interobserver agreement was fair (Percentage agreement = 73.93 %;  $\kappa = 0.41$ ;  $p = 0.48$ ). For disc herniation, interobserver agreement was good. (Percentage agreement = 89.69 %;  $\kappa = 0.70$  ;  $p = 0.06$ ). For nerve root compression, interobserver agreement was good. (Percentage agreement = 87.2 %;  $\kappa = 0.73$ ;  $p = 0.36$ ) **Conclusion:** Good correlation between both observers in diagnosing spinal stenosis due to disc disease indicates that interpretation of MRI of lumbar spine by radiology residents does not hamper patient management.

## INTRODUCTION

Due to aging population and sedentary life style, degeneration of lumbar spine is becoming a frequent problem resulting in increasing referrals to neurosurgeons and physicians. Local data from Pakistan show that disc bulge or herniation is one of the most common reasons for back pain in patients with lumbar spondylosis.<sup>1,2</sup>

Magnetic resonance imaging (MRI) is increasingly used to assess patients with lumbar spine problems, particularly those with sciatica and intervertebral disc herniation. It has largely replaced

computerized tomography and myelography in the evaluation of low back pain and radiculopathy because of its ability to demonstrate excellent anatomic details and small disc herniations. The accuracy of MRI for predicting the presence of disk herniation at surgery is relatively high varying from 76% to 96%.<sup>4</sup>

Management of patients with low back pain either surgical or conservative depends upon the presence and severity of nerve root compression. Disk herniations of the same size may be asymptomatic in one patient and lead to severe nerve root compromise in another patient.<sup>5</sup> Therefore it is essential to evaluate the nerve roots for compression by herniating discs. In



a local study from Pakistan, Siddiqui AH et al reported prevalence of nerve root compression in patient with low back pain is 73 %.<sup>1</sup>

## MATERIALS & METHODS

This retrospective cross sectional study was carried out at Radiology department of Aga Khan University hospital from March 2010 till July 2010. On the basis of non probability purposive sampling 63 patients were selected who were referred for MRI with strong clinical suspicion of lumbar disc herniation and radiculopathy. Final sample comprised of 55 patients.

**Exclusion criteria:** Patients less than 18 years of age, patients with history of surgery, spinal infections or tumors were excluded from the study.

**Imaging technique:** All images were acquired with a 1.5 T MRI system (Magnetom Avanto, Siemens Corporation USA). The standard imaging protocol included T1 and T2 weighted sagittal images ( Slice thickness 4 mm, FOV 350x350mm, Image Matrix 672x896), T2 weighted axial images (slice thickness 4mm, FOV 230x230mm, Image Matrix 314x448). T2 weighted fat suppressed sagittal images (Slice thickness 4 mm, FOV 350 x 350 mm, Image Matrix 214 x 256).

**Image interpretation:** One fellowship trained neuro-radiologist and one senior resident evaluated the images on picture archiving and communication system (PACS). Both observers were unaware of patient's clinical history and each other's findings. The scans were interpreted in sagittal and axial planes. Lumbar discs at L3-L4, L4-L5 and L5-S1 levels were evaluated by both observers. Disc at each level was evaluated for presence or absence of disc bulge and disc herniation separately. No distinction was made between disc protrusion and extrusion; both were included in the term herniation.

Nerve roots from L3 to S1 levels were also evaluated for nerve compression. For nerve root compression a 5 point scale was used which was proposed by Van Rijn et al<sup>8</sup> 1: No nerve compression. 2: Possibly no root compression. 3: Indeterminate. 4: Possible nerve compression. 5: Definitely compression. For the purpose of analyses, these grades of nerve compression were simplified as "root compression" (possibly or definitely) or "no root compression" (all other categories).

**Data collection and analysis:** Findings of both observers were recorded on a performa, entered and analyzed

in SPSS 16. Interobserver agreement between neuro-radiologist and radiology resident for evaluation of bulging and herniated discs and nerve root compression was calculated by applying kappa statistics. Kappa value less than 0.4 was considered poor agreement. Value from 0.4 to 0.75 was considered fair to good agreement, and value above 0.75 was considered excellent agreement. Chi-square test was applied to see the association between neuro-radiologist and resident in image interpretations. P-value less than 0.05 was considered significant.

## RESULTS

Initially 63 patients were included but 8 patients were excluded from the study based on exclusion criteria and final sample consisted of 55 patients. (32 females; 23 males, age range 19 -76 years, mean age 46.1years  $\pm$ 15.1).

Total 165 lumbar discs were studied by both readers in these 55 patients. For determining presence or absence of disc bulge, the observers agreed in MRI findings in 122 patients (73.93%) and disagreed in 43 patients (26.06%). Interobserver agreement for assessment of disc bulge was fair ( $\kappa = 0.417$ ;  $p = 0.48$ ).

For assessment of disc herniation observers agreed on imaging findings in 148 patients (89.69%) and disagreed in 17. Interobserver agreement for assessment of disc herniation was good ( $\kappa = 0.70$ ;  $p = 0.06$ ). Figure 1 shows examples of agreement between both observers for disc bulge and disc herniation.

The agreement between both observers for presence or absence of nerve root compression was achieved in 144 patients (87.2%) while they disagreed in 21 patients. Interobserver agreement was good, ( $\kappa = 0.736$ ;  $p = 0.36$ ) as shown in Table 1. Figure 2 shows examples of disagreement between both observers for disc bulge and nerve root compression.

## DISCUSSION

For diagnostic radiology residents and fellows, image interpretation and the ability to make independent decisions on MRI studies while on call is one of the most important learning exercises.<sup>9, 10</sup> Since, MRI of the lumbar spine is a very frequently ordered examination by clinicians, It constitutes a significant portion of daily work routine during regular working hours in the



**TABLE 1:** Interobserver agreement in evaluation of disc bulge

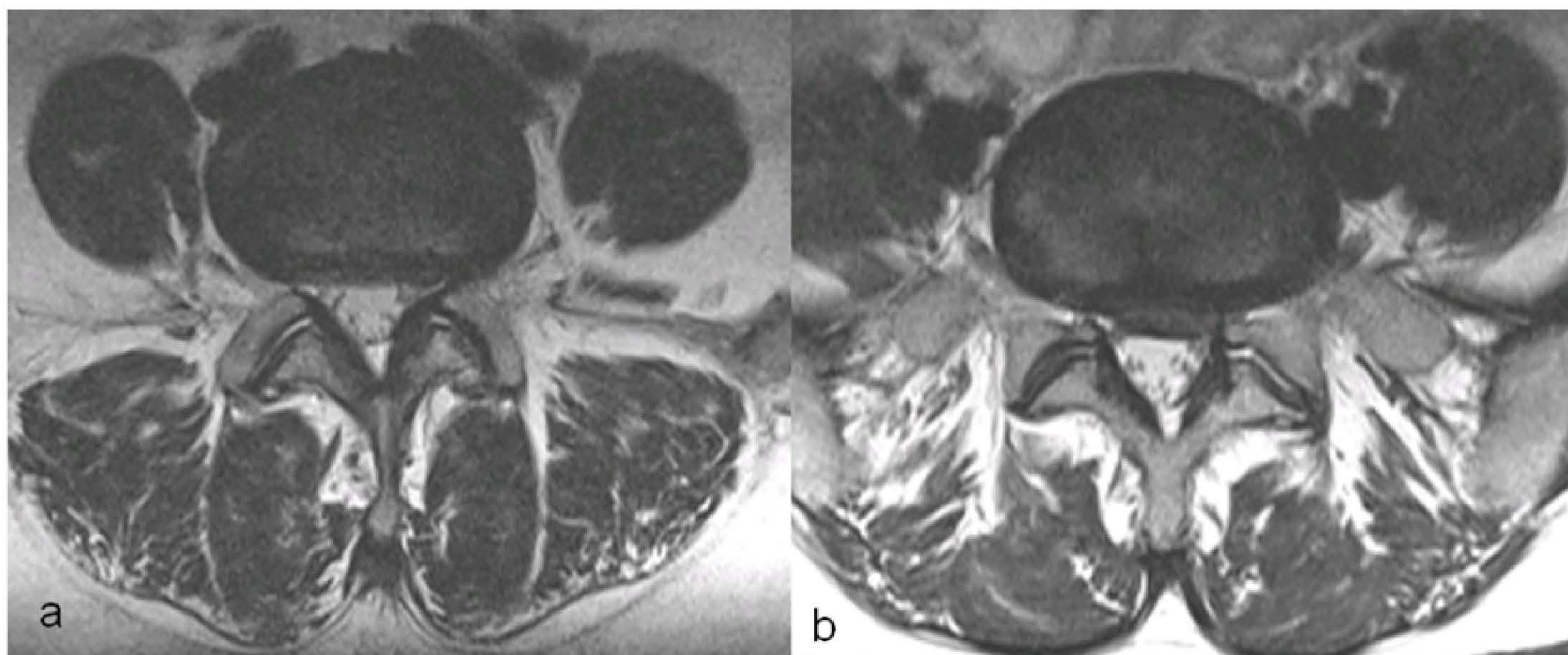
		Disc Bulge		
		Neuroradiologist		
Resident		No	Yes	Total
No		88	18	106
Yes		25	34	59
Total		113	52	165
Inter-observer agreement		Percentage agreement = 73.93% ; $\kappa = 0.410$ .; $p = 0.48$		

		Disc Herniation		
		Neuroradiologist		
Resident		No	Yes	Total
No		120	16	136
Yes		1	28	29
Total		121	44	165
Interobserver agreement		Percentage agreement = 89.69 % ; $\kappa = 0.70$ ; $p = 0.06$		

		Nerve Root Compression		
		Neuroradiologist		
Resident		No	Yes	Total
No		88	15	103
Yes		6	56	62
Total		94	71	165
Interobserver agreement		Percentage agreement = 87.2 % ; $\kappa = 0.73$ ; $p = 0.36$		



**Figure 1.** Examples of agreement between neuroradiologist and resident. Image (a) was interpreted as disc bulge by both observers. Image (b) was interpreted by both observers as disc herniation with nerve root compression.



day and during on-call hours in the night. Thus, in this study, we examined the interobserver variability on preliminary interpretations given by senior radiology residents and the final interpretations of attending neuroradiologists on MRI studies of the lumbar spine, particularly, in the evaluation of disk herniations and nerve root compression. We especially focused on the lower lumbar discs (L3-L4, L4-L5) because they are most commonly affected by degenerative stenosis, since, these segments are in a transition zone from the rigid sacrum to the mobile lumbar spine. Furthermore, the facet joints in this region have less sagittal orientation resulting in more rotatory strains.<sup>11</sup>

Although the interobserver variability in assessment of lumbar spinal stenosis on MRI has been assessed previously by in the past<sup>7, 12</sup> but in these studies the observers were neuroradiologists and the observer variability between resident and attending neuroradiologist was not evaluated.

We believe that assessment of discrepancies in radiology resident interpretations compared to those of attending neuroradiologist, is an important part of a quality assurance program as presence of major discrepancies in interpretation may potentially lead to adversely patient outcomes.

Van Rijn JC et al. in a study investigated the possible causes of interobserver disagreement in MRI evaluation. Their results showed that a lack of consensus on nomenclature of bulging discs was the main cause of disagreement between radiologists.<sup>8</sup>

Based on the need of standardized interpretation and reporting, different grading systems have been developed. The Combined Task Force of the North American Spine Society, American Society of Spine Radiology, and American Society of Neuroradiology has issued guidelines that provide standardization of terms to characterize disc herniation, as well as other disc pathologies.<sup>13</sup> But, despite the presence of grading systems, the reliability of the interpretation findings has a crucial influence on the validity of the data.<sup>14</sup>

Although we followed the same classification system for disc morphology and for grading of nerve root compression which was described by Van Rijn et al in prior studies<sup>8,12</sup> (disc bulge and herniation for disc morphology and grades 1-5 listed above in Materials & Methods) still, there were few other differences in the protocols of the two studies. Firstly, there was some difference in the image acquisition protocols as we did not acquired T1 weighted axial images and the axial

images of Van Rijn's study were acquired without angulation at the disc levels. Secondly, the interpretation of images in Van Rijn's study was done by two experienced neuroradiologists who were aware of patient's clinical history but in our study, one of the observers was a senior resident and both observers were unaware of patients' clinical symptoms and examination findings.

Our results for the reliability of the disc herniation and nerve root compression compares favorably to study of Van Rijn et al. The interobserver reliability for assessment of nerve root compression was better than reported by Lurie JD et al<sup>7</sup>

For the assessment of disc bulge, there was fair agreement between the resident and neuroradiologist ( $K = 0.417$ ). We attribute this difference in evaluation of disc bulge between observers in our study to the lack of consensus based nomenclature of bulging discs. The fair agreement, we believe, is still acceptable, since, disc bulges carry very little importance from management point of view as most patients are asymptomatic and are not likely to undergo surgery.

Potential limitations in our study includes that for the sake of simplicity of data collection and analysis, the images were interpreted by only one resident from most senior trainee batch and residents from junior batches were not involved in the study. The fact that this is a single centre data is also a limitation of our study.

## CONCLUSION

Good correlation was seen between neuroradiologist and radiology resident in diagnosing spinal stenosis due to disc disease indicating that the current practice of initial screening of MRI of lumbar spine by senior radiology residents does not hamper patient management.

## REFERENCES

1. Siddiqui AH, Rafique MZ, Ahmad MN, Usman MU. Role of magnetic resonance imaging in lumbar spondylosis. *J Coll Physicians Surg Pak.* 2005; 15(7):396-9.
2. Bhutta IA, Muddassir N, Mustafa J, Nawaz F, Parvez H. Magnetic Resonance patterns of lumbar disc disease. *J Rawal Med Coll Dec* 2004; 8(2):53-6.
3. Carlisle E, Luna M, Tsou PM, Wang JC. Percent



4. Jarvik JJ, Hollingworth W, Heagerty P, et al. The Longitudinal Assessment of Imaging and Disability of the Back (LAIDBack) study. *Spine* 2001;26:1158–1165)
5. Boos N, Dreier D, Hilfiker E, et al. Tissue characterization of symptomatic and asymptomatic disk herniations by quantitative magnetic resonance imaging. *J Orthop Res* 1997; 15:141–149.
6. Lurie JD, Doman DM, Spratt KF, Tosteson AN, Weinstein JN. Magnetic resonance imaging interpretation in patients with symptomatic lumbar spine disc herniations: comparison of clinician and radiologist readings. *Spine (Phila Pa 1976)*. 2009 Apr 1; 34(7):701-5
7. Lurie JD, Tosteson AN, Tosteson TD, Carragee E, Carrino JA, Kaiser J, Sequeiros RT, Lecomte AR, Grove MR, Blood EA, Pearson LH, Herzog R, Weinstein JN. Reliability of magnetic resonance imaging readings for lumbar disc herniation in the Spine Patient Outcomes Research Trial (SPORT). *Spine (Phila Pa 1976)*. 2008 Apr 20;33(9):991-8
8. van Rijn JC, Klemetsö N, Reitsma JB, Majoie CB, Hulsmans FJ, Peul WC, Stam J, Bossuyt PM, den Heeten GJ. Observer variation in MRI evaluation of patients suspected of lumbar disk herniation. *AJR Am J Roentgenol*. 2005 Jan; 184(1):299-303.
9. Ruchman RB, Jaeger J, Wiggins EF et al (2007) Preliminary radiology resident interpretations versus final attending radiologist interpretations and the impact on patient care in a community hospital. *AJR* 189:523–526.
10. Seltzer SE, Hessel SJ, Herman PG et al (1981) Resident film interpretation and staff review. *AJR* 137:129–133.
11. Michael B Furman, Kirk M Puttlitz, Robert Pannullo, Jeremy Simon Spinal Stenosis and Neurogenic Claudication [Online] [Updated June 2009, cited August 2010] Available from: URL: <http://emedicine.medscape.com/article/310528-overview>.
12. van Rijn JC, Klemetso N, Reitsma JB, Bossuyt PM, Hulsmans FJ, Peul WC, den Heeten GJ, Stam J, Majoie CB. Observer variation in the evaluation of lumbar herniated discs and root compression: spiral CT compared with MRI. *Br J Radiol*. 2006 May; 79(941):372-7.
13. Fardon DF, Milette PC. Nomenclature and classification of lumbar disc pathology. Recommendations of the Combined task Forces of the North American Spine Society, American Society of Spine Radiology, and American Society of Neuroradiology. *Spine* 2001; 26:E93 –113.
14. Pfirrmann CW, Dora C, Schmid MR, Zanetti M, Hodler J, Boos N. MR image-based grading of lumbar nerve root compromise due to disk herniation: reliability study with surgical correlation. *Radiology*. 2004 Feb; 230(2):583-8.