



THE AGA KHAN UNIVERSITY

eCommons@AKU

Department of Radiology

Medical College, Pakistan

April 2006

Median survival time of patients after transcatheter chemo-embolization for hepatocellular carcinoma

Zeeshan Haider

Haq ul

Aga Khan University, tanveer.haq@aku.edu

Khalid Munir

M Uzair Usman

Muhammad Azeemuddin

Aga Khan University, muhammad.azeemuddin@aku.edu

Follow this and additional works at: https://ecommons.aku.edu/pakistan_fhs_mc_radiol



Part of the [Radiology Commons](#)

Recommended Citation

Haider, Z., ul, H., Munir, K., Usman, M. U., Azeemuddin, M. (2006). Median survival time of patients after transcatheter chemo-embolization for hepatocellular carcinoma. *Journal of the College of Physicians and Surgeons Pakistan*, 16(4), 265-269.

Available at: https://ecommons.aku.edu/pakistan_fhs_mc_radiol/216

See discussions, stats, and author profiles for this publication at: <https://www.researchgate.net/publication/7156544>

Median survival time of patients after transcatheter chemo-embolization for hepatocellular carcinoma

Article in *Journal of the College of Physicians and Surgeons--Pakistan: JCPSP* · May 2006

Source: PubMed

CITATIONS

4

READS

256

5 authors, including:



Zishan Haider

Aga Khan University, Pakistan

23 PUBLICATIONS 188 CITATIONS

[SEE PROFILE](#)



Tanveer Ul Haq

Aga Khan University Hospital, Karachi

57 PUBLICATIONS 184 CITATIONS

[SEE PROFILE](#)



Muhammad Azeemuddin

Aga Khan University, Pakistan

66 PUBLICATIONS 327 CITATIONS

[SEE PROFILE](#)

Some of the authors of this publication are also working on these related projects:



Project

Case Report [View project](#)

MEDIAN SURVIVAL TIME OF PATIENTS AFTER TRANSCATHETER CHEMO-EMBOLIZATION FOR HEPATOCELLULAR CARCINOMA

Zishan Haider, Tanveer ul Haq, Khalid Munir, M. Uzair Usman and Muhammad Azeemuddin

ABSTRACT

Objective: To determine the effect on survival after transarterial chemoembolization (TACE) in patients with unresectable hepatocellular carcinoma (HCC).

Design: Longitudinal cohort study.

Place and Duration of Study: Radiology Department, The Aga Khan University Hospital, Stadium Road, Karachi, from December 1997 to September 2005.

Patients and Methods: Patients undergoing TACE procedure for HCC were prospectively followed. Fortythree patients were enrolled from December 1997 to March 2003 in the study and subjected to chemoembolization therapy. Eight out of 43 patients were excluded from the study, who lost to follow-up. All the patients were followed till their death. Median and mean survival were calculated.

Results: The median survival of these 35 patients was 410 days (13.6 months), with 95% confidence interval (236 days lower bound and 536 days upper bound). Mean survival time was 603 days (20.1 months) with 95% confidence interval (394 days lower bound and 812 days upper bound). There was significant difference in mean survival time (in days) by Child's Pugh class ($\chi^2 = 12.384$; $df=2$, p -value=0.002).

Conclusion: The study showed that TACE is an effective palliative treatment. TACE increases the median survival time.

KEY WORDS: *Hepatocellular carcinoma (HCC). Transarterial chemoembolization (TACE). Hepatoma median survival time.*

INTRODUCTION

Hepatocellular carcinoma (HCC) is one of the commonest cancers worldwide.¹ Hepatocellular carcinoma has become a common tumor in Pakistan. This cancer is related to hepatitis B and C virus infection in majority of the patients.² HCC is proven to be extremely lethal, with overall median survival time of 1.6 months without treatment.³ The largest concentration of the cases is found in Asia. Unfortunately, systemic chemotherapy and radiation are ineffective. Surgical resection has been the curative treatment in only 25-30% of cases of HCC because of tumor extension, multiplicity and underlying cirrhosis.⁴ Liver transplantation is applicable to only a small proportion of patients.

In these patients goal of palliative treatment is to prolong their survival by selective injection of chemotherapeutic agents using transarterial chemoembolization (TACE).⁵ Selective chemoembolization with the use of a mixture of iodized oil (lipiodal) and chemotherapeutic agents has been effective for unresectable HCC with good survival rates.⁶ Hepatic artery embolization, with combined chemotherapy, was developed in Japan during early 80's for unresectable HCC.

Such a treatment makes use of the hyper vascular nature of HCC.⁹ Antineoplastic agents are directly injected into the

hepatic artery, allowing high intratumoral concentrations of drugs and thereby reducing systemic side effects. The mixture of chemotherapeutic agents and iodized oil is almost completely retained in neoplastic nodules¹⁰ and can remain in HCC tissue for a long time.¹¹ Subsequent mechanical embolization of the artery, feeding the neoplasm, causes ischemic damage to the tumour¹² and prolongs the duration of the effects of chemotherapeutic agents. Transcatheter arterial chemoembolization (TACE) adds to the proven embolization effect, the efficacy of the stable regional delivery of high concentration of a chemotherapeutic agent.¹³⁻¹⁶ The prognosis of patients with HCC, though unfavorable, varies in different countries worldwide, probably because of a different combination of exposure to carcinogenic factors and consequent different severity of underlying disease.¹⁷ It can be difficult to assess the efficacy of TACE because multiple factors have been cited in different studies as measures of success. These factors include patient survival, imaging response (size reduction, fraction of tumor necrosis, lipiodal retention rate, biologic response (decrease in α -fetoprotein levels), quality of life, and symptomatic improvement.¹⁸ Given the short life expectancy of patients with HCC, the most relevant of these criteria for success is patient survival. Unfortunately, patient survival is also the most controversial of these factors.

This study was conducted to determine the effect on survival after transarterial chemoembolization (TACE) in patients with unresectable hepatocellular carcinoma (HCC).

.....
Department of Radiology, The Aga Khan University Hospital, Karachi.

Correspondence: Dr. Tanveer ul Haq, Associate Professor, Radiology Department, The Aga Khan University Hospital, Stadium Road, P.O Box 3500, Karachi, 74800. E-mail: tanveer.haq@aku.edu

Received August 09, 2004; accepted March 02, 2006.

PATIENTS AND METHODS

All patients who had established unresectable hepatocellular carcinoma (HCC), referred to Radiology Department from December 1997 to May 2003, were included in the study. The sampling technique was non probability convenient. HCC was confirmed by biopsy in majority of the cases. In few cases, TACE was done on the basis of typical radiological appearance of HCC and raised serum alpha fetoprotein levels above 400 micrograms/liter. A questionnaire was designed and the previous data was collected from medical records and radiological files. Laboratory investigations e.g. bilirubin, albumin, prothrombin time, alpha fetoprotein and radiological investigations e.g. CT scans, ultrasounds were reviewed before and after TACE. The classes were registered according to "Child Pugh classification." All cases were followed till demise. Only those patients were included in the study who had undergone TACE and were followed-up. The patients who did not come for follow-up after any TACE sitting were excluded from the study. Pre-procedure CT scans were essentially done to assess the vascular invasion, extension, nature and size of tumors for follow-up comparison. Post procedure CT scans and alpha fetoprotein were done after six weeks of every sitting. Repeat TACE were carried out if patient had either residual tumor vascularity, appearance of new lesion and lack of lipiodal retention. Repeat TACE was carried out at three months, six months or one year interval, if required at any stage. Consent was documented and informed prior to procedure of all patients.

TACE were performed in the angiography suite of Radiology Department of Aga Khan University Hospital (AKUH). Coagulopathy was corrected by transfusion of platelets and/or fresh frozen plasma (FFP) in patients if needed at any stage. Puncture of the femoral artery was done under local anesthesia. Catheterization of superior mesenteric artery, celiac artery and selective catheterization of branches of tumor vessels was carried out. Epirubicin (50 mg) and/or mitomycin C (2mg/cm tumor size) were given along with lipiodal (1cc/cm of tumor size) and gel foam. Polyvinyl alcohol particles were also given in some patients instead of gel foam where micro-catheter technique was used (Figure 1). Kaplan Meier method was used to determine the value of mean and median survival time with 95 percent confidence interval.

RESULTS

Fortythree patients with established HCC were recruited in the study, who were then subjected to TACE procedure. According to the exclusion criteria, 8 out of 43 patients were excluded from the study. There were 24 males and 11 females. Age range was 30 - 85 years with mean age of 55.5 years. There were 8 patients who had biopsy results available for HCC and 27 patients had typical CT scan appearance of HCC with raised alpha fetoprotein. Six out of 35 were non A, non-B cirrhosis whereas 27 were either hepatitis B or C positive. Two patients have had both hepatitis B and C.

A total of 42 lesions were treated with TACE among 35 patients. Single lesion was present in 19 patients whereas 16 patients had two or more than two lesions (multicentric hepatomas). Sixteen patients had tumor size of less than 5 cm and 19 patients had tumor size of more than 5 cm. Total of 63

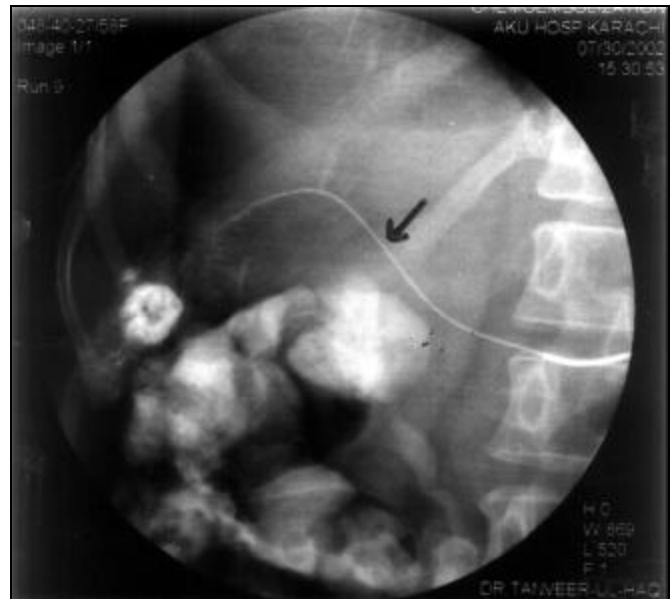

Figure 1: Selective catheterization performed with the use of a microcatheter (arrow) during TACE procedure.

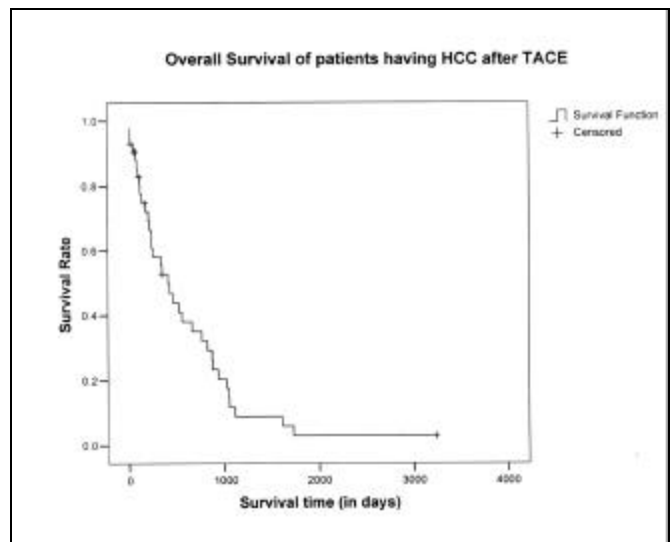


Figure 2: Survival time in days of patients having hepatocellular carcinoma (HCC) after TACE.

procedure sittings were done in 35 patients. In 22 patients there was only 1 sitting of TACE, 6 patients had 2 sittings, 5 had 3 sittings, one had 5 and another had 6 sittings of TACE. The median survival of these 35 patients was 410 days (13.6 months), with 95% confidence interval (236 days lower bound and 536 days upper bound) [Figure 2]. Mean survival time was 603 days (20.1 months) with 95% confidence interval (394 days lower bound and 812 days upper bound). There was significant difference in mean survival time (in days) by Child's Pugh class ($\chi^2 = 12.384$; $df = 2$ and p -value=0.002).

There were 12 patients who were classified as Child class A, 14 as B and 9 as C. Analysis showed a significantly longer median survival time with p -value of 0.002 relative to the severity of underlying disease (Child's A > B > C) which was 936 days (31.4 months) for Child class A, 236 days (8 months) for Child class B and 120 days (4 months) for Child class C (Table I). There was also difference in median survival time by tumor size (less than 5 cm > more than 5 cm). The median survival

time was 762 days (25.6 months) for the patients who had tumor size less than 5 cm. The median survival time was 345 days (11.6 months) for tumor size more than 5cm (Table II).

Table I: Child's class and median survival time.

Child's Pugh class/ No. of patients	A	B	C
	12	14	9
Median survival time	936 days (31.2 months)	236 days (7.8 months)	120 days (4 months)

Table II: Tumor size and median survival time.

Tumor size	Median survival time
Less than 5 cm	762 days (25.6 months)
More than 5 cm	345 days (11.6 months)

None of the patients had major complications after TACE. Eighteen patients developed pain during and immediately after TACE sitting and were managed accordingly. Twelve patients complained of nausea with settlement after conservative treatment. Eight patients had low grade fever. One patient experienced transient alopecia.

DISCUSSION

Hepatocellular carcinoma is a common form of malignancy in Asia. In some western countries, a high incidence rate is frequently seen among Asian immigrants as well.³ The causal factors in Asians are distinctly different from those in western patients, and chronic hepatitis B and C infections are the most common etiologies.⁵ The treatment for HCC remains difficult because of the advanced tumor stage at the time of diagnosis and concomitant cirrhosis. TACE is the most widely used therapy in patients with HCC who are considered to be unsuitable candidates for surgery.⁸

These tumors are mainly fed by hepatic artery. Injecting oil and chemo-mixture directly into the artery has a local and long-standing effect on the tumor and this was the rationale for TACE. In Pakistan, TACE is a relatively new procedure.

The purpose of conducting this study was to compare median survival time with other parts of the world and to identify effectiveness of therapy in our settings. Several well-designed case control and retrospective studies have convincingly demonstrated a benefit of TACE on patients with untreated or historical control subjects. Despite the promising findings reported by dozens of non-randomized trials, these results have yet to be supported by data from randomized control trials (RCTs). Almost all RCTs, however, failed to compare TACE patients with untreated control subjects. RCTs have compared TACE patients with control groups treated with hormone therapy²⁵, radiation therapy¹¹, and systemic chemotherapy.²⁰

Comparing this study with the studies in other parts of the world, it is worthy to consider Bronowicki et al.³¹ The median survival time in this study was 18 months compared to 13.6 months of our study. The difference may be due to large sample size of 127 patients, not including Child C patients and use of Cisplatin. Stefanini²², et al. had a sample size of 69 patients, Child's C patients were excluded and grouping done for lipiodol uptake in three groups. The median survival time in this study was 21 months, which may be due to the above mentioned differences. Ryder²¹ et al. showed relatively poor results of 9 months compared to this study. The reason may be that majority of the patients were dropped into exclusion criteria like patients with survival time of 10 weeks were excluded early from the study, 2 patients were alive (3 years) till the publishing of this study and one went for transplantation. Furthermore, 5 patients died due to complications during the procedure. These complications were not seen in the reported series.

Table III: Western series of TACE for hepatocellular carcinoma in comparison with our study.

Author	Year	Therapy	Number	Median survival (months)	P
Prospective, randomized Pelletier ²⁵	1990	Dox + Gel	21	4	NS
		Supportive care	21	6	
French group ²³	1995	Cis + Lip + Gel	50	19	0.13
		Supportive care	46	8	
Retrospective, matched historical controls Vetter ¹³	1991	Dox + Lip + Gel	30	12	<0.001
		Supportive care	30	3	
Bronowicki ³¹	1994	Dox, Cis, or Epi+Lip+Gel	127	18	<0.0001
		Supportive care	127	5	
Stefanini ²²	1995	Dox + Lip + Gel	69	21	<0.001
		Supportive care	64	3	
Retrospective, nonmatched controls Bronowicki ³²	1996	Dox, Cis, or Epi+Lip+Gel	42	36	<0.0001
		Supportive care	33	11	
Stuart ³³	1996	Dox + Lip + Gel	137	14	<0.01
		Supportive care	81	2	
Marcos-Alvarez ²⁰	1996	Dox + Lip + Gel	30	13	<0.05
		Supportive care	22	5	
Ryder ²¹	1996	Dox + Lip + Gel	67	9	N/A
		Non-Surgical therapy	118	3	
Rose ¹⁹	1998	Dox + Lip + Gel	35	9	<0.0001
		Supportive care	31	3	
AKUH	2005	Dox + Lip + Gel	35	13.6	<0.002

Dox = doxorubicin; Cis = cisplatin; Epi = epirubicin; Lip = lipiodol; Gel = gelatin-foam particles or powder; NS = not statistically significant; N/A = not applicable. AKUH=Aga Khan University Hospital (our study).

Many trials have also compared various forms of chemoembolization without including an untreated control group.²⁶ The true effect of TACE on survival can, therefore, not be ascertained because many patients included in the control groups were given some form of treatment. In addition, the review articles that have dealt with RCTs failed to exclude the trials in which control groups were actually treated, similarly, confounding their analyses.²⁷⁻²⁹ To-date, only 5 RCTs have compared some form of TACE to supportive care.³⁰ This study had to face a similar deficiency with respect to the control group, due to the fact that it was not possible to find a matched group (untreated). A similar group cannot be randomized once the treatment is internationally accepted. Therefore, the median survival of control group was compared from literature which ranged from 3 months to 8 months.¹⁷⁻²³ Okuda et al.²⁴ has shown overall median survival of 1.6 months. Many recent studies^{19-21,23,31-33} have shown a better survival with TACE due to refinements in the technique and more stringent selection criteria. Result of this study is almost similar to the average results of various studies (Table III).

Major confounding factors like size of the tumor and underlying cirrhosis were also addressed in this study. The outcome of patients in this study suggested that patients with severe disease (Child's C) had poor prognosis (120 days). If patients with Child's C were excluded from this study then the median survival time would have been better, that is 586 days. With the inclusion of Child's C patients in this study, the results are relatively poor. However, this still offers therapeutic possibilities to patients in advanced cirrhosis with HCC. TACE has generally been reported to be more effective in small tumors less than 4 cm^{10,11} or 5 cm.¹² In this study, it is obvious that median survival of patients with tumors less than 5 cm size, after TACE, is significantly better than patients having tumors more than 5 cm.

No major complications was observed in our study. There were some minor and mainly the so-called postembolization syndrome i.e., pain, nausea, vomiting and fever. The systemic effects of the chemo-agent were also negligible due to the local accumulation, slow release and lower dosages. Procedure tolerance of the patients was also quite good. The treatment also had a favorable impact on the quality of life, although, we don't have any quantitative analysis for such an observation.

CONCLUSION

The reported series shows that TACE is an effective palliative treatment for patients with unresectable HCC that increases the median survival time. Severity of underlying cirrhosis and size of the tumor are significant prognostic factors.

REFERENCES

- I. D'Agostino HB, Solinas A. Percutaneous ablation therapy for hepatocellular carcinomas. *AJR Am J Roentgenol* 1995; **164**: 1165-7.
- Khokhar N, Aijazi I, Gill ML. Spectrum of hepatocellular carcinoma at Shifa International Hospital, Islamabad. *J Ayub Med Coll (Abbottabad)*. 2003; **15**(4): 1-4.
- Xavier Bosch F. Global epidemiology of hepatocellular carcinoma. In: Okuda K, Tabor E, (edi). *Liver cancer*. New York: Churchill Livingstone, 1997; 13-28.
- The liver cancer study group of Japan. Survey and follow up study of primary liver cancer in Japan: report 14. *Acta Hepatol Jpn* 2000; **41**: 799-811.
- Lo CM, Ngan H, Tso WK, Liu CL, Lam CM, Poon RT, et al. Randomized controlled trial of transarterial lipiodol chemoembolization for unresectable hepatocellular carcinoma. *Hepatology* 2002; **35**: 1164-70.
- Takayasu K, Muramatsu Y, Maeda T, Iwata R, Furukawa H, Muramatsu Y, et al. Target transarterial oily chemoembolization for small foci of hepatocellular carcinoma using a unified helical CT and angiography system: analysis of factors effecting local recurrence and survival rates. *AJR Am J Roentgenol* 2001; **176**: 681-8.
- Levy I, Greig PD, Gallinger S, Langer B, Sherman M. Resection of hepatocellular carcinoma without pre-operative tumor biopsy. *Ann Surg* 2001; **234**: 206-9.
- Okuda S. Transcatheter arterial embolization for advanced hepatocellular carcinoma: the controversy continues (editorial). *Hepatology* 1998; **27**: 1743-4.
- Matsui O, Kadoya M, Kameyama T, Yoshikawa J, Takashima T, Nakanuma Y, et al. Benign and malignant nodules in cirrhotic livers: distinction based on blood supply. *Radiology* 1991; **178**: 493-7.
- Kan Z, Sato M, Ivancev K. Distribution and effect of iodized poppy seed oil in the liver after hepatic artery embolization: experimental study in several animal species. *Radiology* 1993; **186**: 861-6.
- Roul JL, Bourguet P, Bretagne JF. Hepatic artery injection of I-131-labeled lipiodol. I. Bio-distribution study results in patients with hepatocellular carcinoma and liver metastases. *Radiology* 1988; **168**: 541-5.
- Bruix J, Castells A, Montanya X. Phase II study of transarterial embolization in European patients with hepatocellular carcinoma: need for controlled trials. *Hepatology* 1994; **20**: 643-50.
- Vetter D, Wenger JJ, Bergier JM, Doffoel M, Bockel R. Transcatheter oily chemoembolization in the management of advanced hepatocellular carcinoma in cirrhosis: results of a western comparative study in 60 patients. *Hepatology* 1991; **13**: 427-33.
- Bruneton JN, Berboul P, Grimaldi C, Butori B, Rampal P, Delmont J, et al. Hepatic intra-arterial lipiodol and CT of hepatic tumors: diagnostic and therapeutic value. *Radiology* 1985; **157**: 313-6.
- Nakamura H, Hashimoto T, Oi H, Sawada S. Transcatheter oily chemoembolization of hepatocellular carcinoma. *Radiology* 1989; **170**: 783-6.
- Figueras J, Vallas C, Pamies JJ, Benasco C, Sancho C, Rafecas A, et al. Transcatheter arterial chemoembolization in the treatment of hepatocellular carcinoma. *Rev Esp Eufarm Dig* 1993; **83**: 215-9.
- Amorati P. Gross pathologic types of hepatocellular carcinoma in Italian patients: relationship with demographic environmental and clinical factors. *Cancer* 1993; **72**: 1557-63.
- Okuda K. Primary liver cancer. Quadrennial review lecture. *Dig Dis Sci* 1986; **31**(9 suppl): 133S-46S.
- Rose DM, Chapman WC, Brockenbrough AT, Wright JK, Rose AT, Meranze S, et al. Transcatheter arterial chemoembolization as primary treatment for hepatocellular carcinoma. *Am J Surg* 1999; **177**: 405-10.
- Marcos-Alvarez A, Jenkins RL, Washburn WK. Multimodality treatment of hepatocellular carcinoma in a hepatobiliary speciality center. *Arch Sug* 1996; **131**: 292-8.
- Ryder SD, Rizzi PM, Metivier E. Chemoembolization with lipiodol and doxorubicin: applicability in British patients with hepatocellular

- carcinoma. *Gut* 1996; **38**: 125-8.
22. Stefanini GF, Amorati P, Biselli M, Mucci F, Celi A, Arienti V, et al. Efficacy of transarterial targeted treatments on survival of patients with hepatocellular carcinoma: an Italian experience. *Cancer* 1995; **75**: 2427-34.
 23. A comparison of lipiodol chemoembolization and conservative treatment for unresectable hepatocellular carcinoma. Group d'Etude et de Traitement du Carcinome Hepatocellulaire. *New Eng J Med* 1995; **332**: 1256-61.
 24. Okuda K, Ohtsuki T, Obata H, Tomimatsu M, Okazaki N, Hasegawa H, et al. Natural history of hepatocellular carcinoma and prognosis in relation to treatment: study of 850 patients. *Cancer* 1985; **56**: 819-28.
 25. Pelletier G, Roche A, Ink O, Anciaux ML, Derhy S, Rougier P, et al. A randomized trial of hepatic arterial chemoembolization in patients with unresectable hepatocellular carcinoma. *J Hepatol* 1990; **11**: 181-4.
 26. Ikeda K, Inoue H, Yano T, Kobayashi H, Nakajo M, et al. Comparison of the anticancer effect of ADMOS alone and ADMOS with CDPP in the treatment of hepatocellular carcinoma by intra-arterial injection. *Cancer Chemother Pharmacol* 1992; **31**(suppl): S65-S8.
 27. Simonetti RG, Liberati A, Angiolini C, Pagliaro L. Treatment of hepatocellular carcinoma: a systematic review of randomized controlled trials. *Ann Oncol* 1997; **8**: 117-36.
 28. Trinchet JC, Ganne-Carrie N, Beaugrand M. Intra-arterial chemoembolization in patients with hepatocellular carcinoma. *Hepatogastroenterology* 1998; **45**: 1242-7.
 29. Trevisani F, De Notariis S, Rossi C, Bernardi M. Randomized control trials on chemoembolization for hepatocellular carcinoma: is there room for new studies? *J Clin Gastroenterol* 2001; **32**: 383-9.
 30. Bruix J, Llovet J, Castells A, Montana X, Bru C, Ayuso MC, et al. Transarterial embolization versus symptomatic treatment in patients with advanced hepatocellular carcinoma: results of a randomized, controlled trial in a single institution. *Hepatology* 1998; **27**: 1578-83.
 31. Bronowicki JP, Vetter D, Dumas F, Boudjema K, Bader R, Weiss AM, et al. Transcatheter oily chemoembolization for hepatocellular carcinoma: a 4 years study of 127 patients. *Cancer* 1994; **74**: 16-24.
 32. Bronowicki JP, Boudjema K, Chone L, Nisand G, Bazin C, Pflumio F, et al. Comparison of resection, liver transplantation and transcatheter oily chemoembolization in the treatment of hepatocellular carcinoma. *J Hepatol* 1996; **24**: 293-300.
 33. Stuart KE, Anand AJ, Jenkins RL. Hepatocellular carcinoma in the United States: prognostic features, treatment outcome, and survival. *Cancer* 1996; **77**: 2217-22.

