



THE AGA KHAN UNIVERSITY

eCommons@AKU

Department of Paediatrics and Child Health

Division of Woman and Child Health

September 2018

Fungal osteomyelitis in a patient with chronic granulomatous disease: Case report and review of the literature

Muhammad Khalid

Aga Khan University, muhammad.khalid@aku.edu

Syed Asad Ali

Aga Khan University, asad.ali@aku.edu

Follow this and additional works at: https://ecommons.aku.edu/pakistan_fhs_mc_women_childhealth_paediatr

 Part of the [Pediatrics Commons](#)

Recommended Citation

Khalid, M., Ali, S. (2018). Fungal osteomyelitis in a patient with chronic granulomatous disease: Case report and review of the literature. *Journal of the Pakistan Medical Association*, 68(9), 1387-1390.

Available at: https://ecommons.aku.edu/pakistan_fhs_mc_women_childhealth_paediatr/724

Fungal osteomyelitis in a patient with chronic granulomatous disease: Case report and review of the literature

Muhammad Khalid, Syed Asad Ali

Abstract

Chronic granulomatous disease (CGD) is the most common of the primary immunodeficiency in children. It is caused by single gene defect resulting in dysfunctional nicotinamide adenine dinucleotide phosphate (NADPH) oxidase complex causing recurrent bacterial and fungal infections. Here we present the case of a 9 year old boy who was a known case of CGD since three years of age. He presented with recent history of fever, left sided pain in the scapular region and difficulty in breathing. Chest imaging revealed developing left upper lobe consolidation and erosion of the 3rd posterior rib. The child underwent video assisted thoracoscopic surgery (VATS) and biopsy of the lesion. Histopathology revealed fungal hyphae which were confirmed to be *Aspergillus nidulans* on staining. He was successfully treated with voriconazole therapy. We will also review the literature on fungal osteomyelitis in CGD patients.

Keywords: chronic granulomatous disease, primary immunodeficiency, *Aspergillus nidulans*, osteomyelitis.

Introduction

Chronic granulomatous disease (CGD) is a rare genetic condition where nicotinamide adenine dinucleotide phosphate (NADPH) oxidase complex fails to generate reactive oxygen species (ROS) in the activated neutrophils, monocytes and macrophages.¹ CGD is a single gene defect; either X-linked recessive (XR - CGD) in 60% of the cases or autosomal recessive (AR - CGD) in 40% of the cases. Approximate incidence of CGD is 1 in 200,000 persons.²

Two thirds (75%) of the patients under five years of age present with recurrent infections. X-linked recessive CGD is more severe and early to present.³ The infections most commonly involve lungs, lymph nodes, skin, liver and gastrointestinal tract. Common pathogenic organism include *Aspergillus (fumigates, nidulans)*, *Staphylococcus aureus*, *Burkholderiacepacia*, *Salmonella species*, *Serratia marcescens*, *Mycobacterium tuberculosis* and *Nocardia*.⁴

.....
Aga Khan University Hospital, Karachi.

Correspondence: Muhammad Khalid. Email: khalidsaleem2001@hotmail.com

The first clue to investigate for this disorder comes from carefully obtained medical or family history of repeated and/or extraordinarily severe infections. Measurement of superoxide production by the activated phagocytes is the basis of diagnostic tests. These include nitrobluetetrazoleum (NBT) reduction and dihydrorhodamine (DHR) assay. Other adjunct diagnostic modalities are imaging techniques (CT, MRI and MR - spectroscopy), histopathology and culture sensitivity of biopsy specimens.⁵

Close medical follow-up, prophylactic antibiotic and antifungal therapy with aggressive treatment of acute infections form the basis of standard care for the patients with CGD. Trimethoprim-sulphamethoxazole and itraconazole are the agents of choice for prophylaxis. In some of the developed countries like USA interferon — gamma therapy is also used for prophylaxis. Definitive therapy for CGD is the stem cell transplantation.⁶

Here we present a case of *Aspergillus nidulans* pneumonia with posterior rib erosion in a nine year old boy who was a known case of CGD seen at Aga Khan University Hospital in July 2017. Histopathology and culture sensitivity of the biopsy specimen confirmed the diagnosis and the boy had uneventful recovery. Literature review of *Aspergillus* osteomyelitis in CGD patients is also presented.

Case Report

A nine year old boy presented in outpatient department with fever, left sided pain in scapular region and difficulty in breathing for three days. There was no history of trauma associated with pain. The boy was a diagnosed case of chronic granulomatous disease, based on nitrobluetetrazoleum test (NBT) and dihydrorhodamine (DHR) assay, since three years of age and his regular medication included Trimethoprim-sulphamethoxazole 5 mg/kg/day in two divided daily doses and Itraconazole 5 mg/kg oral solution once daily.

Clinical examination revealed a febrile boy with a temperature of 102°F. Respiratory system examination was significant with pain on deep inspiration, dull percussion note and decreased air entry in left upper

Table: Aspergillus osteomyelitis in CGD patients.

S. No	Reference	Age (year)/ Gender	Genotype	Year of publication	Aspergillus species	Site	Therapy	Outcome
1	Dellepiane et al ⁹	21 / M	gp91phox	2008	A. nidulans	5th, 6th, 7th thoracic vertebrae + ribs	LAMB* + caspofungin → caspofungin & voriconazole	Expired
2	Bukhari et al ¹⁴	5 / M	NA	2009	A. nidulans	Vertebrae	Voriconazole	Survived
3	Hodiamont et al ¹⁰	18 / M	gp91phox	2009	A. fumigatus	Right midfoot	Voriconazole → caspofungin → posaconazole	Survived
4	Al-Tawfiq et al ¹⁵	17 / M	NA	2010	A. fumigatus	6th & 7th cervical + 1st, 2nd, 3rd & 4th thoracic vertebrae	DAMB¥ → LAMB → caspofungin + itraconazole i.v. subsequent with voriconazole p.o. → Itraconazole p.o.	Survived
5	Mohammadpour M et al ⁸	9 / M	gp91phox	2010	A. fumigatus	Skull osteomyelitis (left supra - orbital)	DAMB + Itraconazole + IFN-γ → IV voriconazole → voriconazole p.o.	Survived
6	Chang H-M et al ¹¹	17 / M	p47-phox	2012	A. flavus	L3-L4 spondylo-discitis + paraspinal / epidural abscess	Amphotericin B → Voriconazole + IFN-γ	Survived
7	Bassiri-Jahromi S et al ¹²	13 / M	X-linked	2012	A. nidulans	Right tibia	IV voriconazole → PO voriconazole	Survived
8	Kepekli E et al ¹³	2.5 / M	X-linked	2014	Aspergillus spp.	Right 2 costal bones & cartilages with lung parenchyma	Voriconazole → Voriconazole + LAMB	Survived
9	Mamishi S et al ¹⁶	4.5 / F	NA	2016	A. fumigatus	9th & 10th posterior right ribs + Lung abscess → progressed to involve right 3rd rib, left 5th, 6th, 7th and 8th ribs	DAMB + IFN-γ → DAMB + IFN-γ + 5 - flurocytosine	Expired
10	Kutlug S et al ⁷	11 / M	gp91phox	2017	A. fumigatus	Talus & vertebral osteomyelitis	LAMB -> IV voriconazole -> Voriconazole + IFN-γ + G - CSF	Expired

*LAMB: Liposomal Amphotericin B, ¥: DAMB - deoxycholate Amphotericin B, E: p.o - per oral.

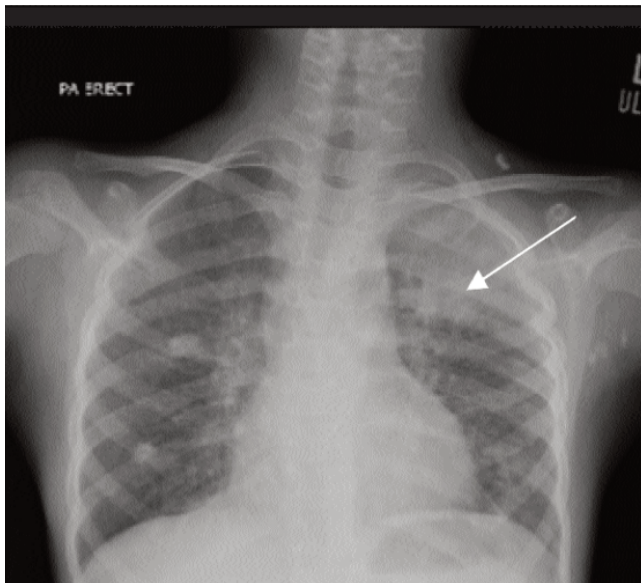


Figure-1: Opacification in left upper lobe (arrow) suggestive of consolidation.

segment anteriorly and tenderness at left scapular region posteriorly. There was no erythema or swelling at the left

scapular region. Other systemic examination was unremarkable. A clinical diagnosis of left sided lobar pneumonia (possible bacterial etiology) was made and he was empirically prescribed oral linezolid and ibuprofen three times daily and advised follow up after three days.

On follow up, the boy had no improvement in his symptoms. He was admitted in hospital, laboratory investigations were advised and the boy was put on broad spectrum intravenous antibiotics. Investigations revealed Hb 6.9 gm.%, TLC of 16200/mm³ with 63% neutrophils and 30% lymphocytes, platelets of 315,000/mm³. His chest X-ray showed left upper lobe consolidation (Figure-1). CT-chest with contrast showed consolidation in apical segment of left upper lobe with erosion of left 3rd rib posteriorly and mild left sided effusion (Figure-2). The child underwent an urgent VATS with biopsy. Histopathology of the biopsy revealed focal granulomatous response with few fungal hyphae highlighted on Periodic acid-Schiff-diastase (PASD) stain. The boy was put on intravenous voriconazole twice daily. After five days of intravenous voriconazole therapy fever and pain settled. The child was shifted to

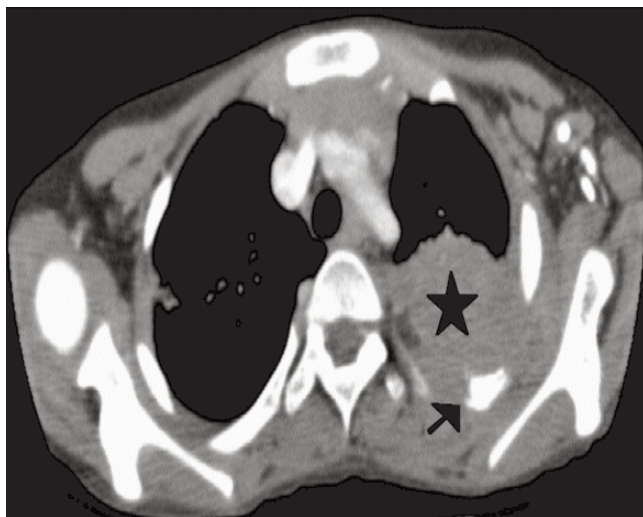


Figure-2: CT - chest showing left upper lobe consolidation (star) and erosion of third rib (arrow).

oral voriconazole and discharged home. Two weeks later culture and sensitivity of biopsy specimen grew *Aspergillus nidulans* sensitive to voriconazole. The therapy was continued as the boy was doing well on follow up. He was advised voriconazole for three months with Trimethoprim-sulphamethoxazole prophylactic therapy.

Literature Review: A literature review of *Aspergillus* osteomyelitis in patients with CGD in last ten years (2008 - 2017) was performed using the Medline / Pub Med and Google scholar databases. Searches were conducted using the terms "chronic granulomatous disease" "osteomyelitis" and "*Aspergillus*". References of the retrieved articles were reviewed for other cases.

We found ten other cases of *Aspergillus* osteomyelitis in CGD patients. Age ranged from 2.5 year to 21 years. Nine of the cases were male and seven patients had successful recovery from the episode of fungal osteomyelitis. The fungus identified was *A. fumigatus* in five cases it was, *A. nidulans* in three cases, *A. flavus* in one case and unspecified *Aspergillus* in one case. Seven patients received combined antifungal therapy, most common drug was Voriconazole followed by Amphotericin B and Interferon- γ . In four cases, the osteomyelitis involved ribs and vertebrae by the contiguous spread from lung parenchyma. In three cases lower limb was involved affecting foot in two cases and tibia in one case. There was one case of isolated skull osteomyelitis in a nine year old male child.⁸ Genotype of CGD was available in seven cases, four cases having mutation at gp91^{phox},⁷⁻¹⁰ one case with p47-phox¹¹ mutation and in two cases only X-

linked pattern was described without description of genetic locus.^{12,13}

Discussion

Patients with CGD are unable to kill certain catalase positive micro-organisms including certain bacteria and fungi. Among the bacteria most common are *Staphylococcus aureus* and *Enterobacteriaceae*. From the fungal group *Aspergillus* species are more common.¹⁷ As the patient did not respond to therapy within 72 hours, he was admitted and intravenous Meropenem was started meanwhile markers of fungal infection β -D-glucan and galactomannan were also obtained. β -D-glucan level turned to be 91.84 pg/ml (Normal 60 - 80 pg/ml) and galactomannan level was 0.106 (positive > 0.7). CT-scan chest was obtained because of persistent back pain, fever not responding to broad spectrum antibiotic with mildly raised fungal markers considering the possibility of fungal infection and osteomyelitis.

Although *Aspergillus fumigatus* is the dominant species, invasive fungal aspergillosis in CGD patients can also be caused by *Aspergillus nidulans* and *Aspergillus flavus*. Contribution to the infection with each organism was equal as studied by Dotis and Roilides.¹⁸ However, Henriët S, et al found that *A. nidulans* caused osteomyelitis in 74% of infections compared to 41% caused by *A. fumigatus* infections.¹⁹ It's not exceptional for the primary pulmonary infection in invasive aspergillosis to extend to an adjacent rib or vertebrae.^{17,20}

In our patient CT-chest revealed erosion of posterior third rib. Surgical debridement and biopsy of the lung tissue was obtained and sent for histopathology and culture sensitivity. Other common infection that can present similarly is tuberculosis, involving lung and bone simultaneously. Xpert MTB/RIF and acid fast bacillus (AFB) stain with culture sensitivity was also sent to rule out tuberculous etiology. Tuberculosis work up remained negative but histopathology showed few fungal hyphae. So we started intravenous voriconazole 200 mg / dose twice daily till the final culture report.

Post-operatively our patient made smooth recovery. His back pain and fever subsided five days after starting intravenous voriconazole. Similar case was reported in a 5-year-old boy, known case of CGD, where *Aspergillus* was the cause of osteomyelitis of the ribs. Treatment with Amphotericin B and INF- γ achieved effective response in the patient.²¹ Other pharmacological options to treat invasive fungal aspergillosis are Amphotericin B, caspofungin and posaconazole. Attributed to its superior tolerance and better survival Voriconazole is now

regarded as the drug of choice for invasive aspergillosis as compared to amphotericin.²²

Our patient was discharged home fever and pain free on oral voriconazole to be followed in outpatient department (OPD) on weekly basis. Two weeks later the final report of histopathology and microbiology confirmed *Aspergillus nidulans* grown from the biopsy specimen. Last seen in OPD six weeks after discharge, the patient is doing well on voriconazole therapy.

Conclusion

The clinicians must be vigilant about the spectrum of infections in patients with chronic granulomatous disease. Definitive speciation of invasive fungal infection in CGD is important. Early and accurate diagnosis can be reached by appropriate consultation with paediatric surgeon and microbiologists. Management of CGD has improved dramatically with antifungal prophylaxis and better antifungal drugs.

Disclaimer: None to declare.

Conflict of Interest: None to declare.

Funding Sources: Dr. Muhammad Khalid is trainee Fellow in Pediatric Infectious Diseases supported by Grant Number 1 D43 TW007585-01 from the National Institute of Health's Fogarty International Center.

References

- Holland SM. Chronic granulomatous disease. *Hematol Oncol Clin North Am.* 2013; 27:89-99.
- Segal BH, Veys P, Malech H, Cowan MJ. Chronic granulomatous disease: lessons from a rare disorder. *Biol Blood Marrow Transplant.* 2011; 17:S123-S31.
- Rawat A, Singh S, Suri D, Gupta A, Saikia B, Minz RW, et al. Chronic granulomatous disease: two decades of experience from a tertiary care centre in North West India. *J Clin Immunol.* 2014; 34:58-67.
- Marciano BE, Spalding C, Fitzgerald A, Mann D, Brown T, Osgood S, et al. Common severe infections in chronic granulomatous disease. *Clin Infect Dis.* 2015; 60:1176-83.
- Chiriaco M, Salfa I, Di Matteo G, Rossi P, Finocchi A. Chronic granulomatous disease: clinical, molecular, and therapeutic aspects. *Pediatr Allergy Immunol.* 2016; 27:242-53.
- Cole T, Pearce MS, Cant AJ, Cale CM, Goldblatt D, Gennery AR. Clinical outcome in children with chronic granulomatous disease managed conservatively or with hematopoietic stem cell transplantation. *J Allergy Clin Immunol.* 2013; 132:1150-5.
- Kutlug S, Sensoy G, Birinci A, Saraymen B, Köker MY, Yildiran A. Seven chronic granulomatous disease cases in a single-center experience and a review of the literature. *Asian Pac J Allergy Immunol.* 2018; 36:35-41.
- Mohammadpour M, Mamishi S, Oaji M, Pourpak Z, Parvaneh N. Successful treatment of fungal osteomyelitis with voriconazole in a patient with chronic granulomatous disease. *Iran J Pediatr.* 2010;20:487.
- Dellepiane RM, Tortorano AM, Liotto N, Laicini E, Di Landro G, Carnelli V, et al. Invasive *Aspergillus nidulans* infection in a patient with chronic granulomatous disease. *Mycoses.* 2008; 51:458-60.
- Hodiamont CJ, Dolman KM, Ten Berge IJ, Melchers WJ, Verweij PE, Pajkrt D. Multiple-azole-resistant *Aspergillus fumigatus* osteomyelitis in a patient with chronic granulomatous disease successfully treated with long-term oral posaconazole and surgery. *Med Mycol.* 2009; 47:217-20.
- Chang H-M, Yu H-H, Yang Y-H, Lee W-I, Lee J-H, Wang L-C, et al. Successful treatment of *Aspergillus flavus* spondylodiscitis with epidural abscess in a patient with chronic granulomatous disease. *Pediatr Infect Dis J.* 2012; 31:100-1.
- Bassiri-Jahromi S, Doostkam A. Fungal infection and increased mortality in patients with chronic granulomatous disease. *Med Mycol J.* 2012; 22:52-7.
- Kepenekli E, Soysal A, Kuzdan C, Ermerak NO, Yüksel M, Bakir M. Refractory invasive aspergillosis controlled with posaconazole and pulmonary surgery in a patient with chronic granulomatous disease: case report. *Ital J Pediatr.* 2014; 40:2.
- Bukhari E, Alrabiaah A. First case of extensive spinal cord infection with *Aspergillus nidulans* in a child with chronic granulomatous disease. *J Infect Dev Ctries.* 2009; 3:321-3.
- Al-Tawfiq JA, Al-Abdely HM. Vertebral osteomyelitis due to *Aspergillus fumigatus* in a patient with chronic granulomatous disease successfully treated with antifungal agents and interferon-gamma. *Med Mycol.* 2010; 48:537-41.
- Mamishi S, Zomorodian K, Saadat F, Jalali SZ, Geramishoar M. Osteomyelitis and lung abscess due to *Aspergillus fumigatus* in a chronic granulomatous disease patient. *Curr Med Mycol.* 2016; 2:37-41.
- Falcone EL, Holland SM. Invasive fungal infection in chronic granulomatous disease: insights into pathogenesis and management. *Curr Opin Infect Dis.* 2012; 25:658-69.
- Dotis J, Roilides E. Osteomyelitis due to *Aspergillus* species in chronic granulomatous disease: an update of the literature. *Mycoses.* 2011; 54:e686-96.
- Henriet SS, Verweij PE, Warris A. *Aspergillus nidulans* and chronic granulomatous disease: a unique host-pathogen interaction. *J Infect Dis.* 2012; 206:1128-37.
- Blumental S, Mouy R, Mahlaoui N, Bougnoux M-E, Debré M, Beauté J, et al. Invasive mold infections in chronic granulomatous disease: a 25-year retrospective survey. *Clin Infect Dis.* 2011; 53:e159-e69.
- Mamishi S, Zomorodian K, Saadat F, Gerami-Shoar M, Tarazooie B, Siadati SA. A case of invasive aspergillosis in CGD patient successfully treated with Amphotericin B and INF- γ . *Ann Clin Microbiol Antimicrob.* 2005; 4:4.
- Herbrecht R, Denning DW, Patterson TF, Bennett JE, Greene RE, Oestmann JW, et al. Voriconazole versus amphotericin B for primary therapy of invasive aspergillosis. *N Engl J Med.* 2002; 347:408-15.